

Chylous reflux in the lungs and pleurae¹

HERBERT C. MAIER

3 East 71st Street, New York, N.Y. 10021, U.S.A.

Lymphangiectasis of varying extent may be present in some cases of chronic pulmonary disease. Often the dilated lymphatic channels are not identified because pulmonary fibrosis and emphysema together with secondary inflammatory changes obscure the lymph vessel pathology. When chylothorax is associated with such chronic pulmonary pathology, attention may be drawn to the lymphatic system. The presence of a chylothorax is usually attributed to obstruction or injury of the thoracic duct, whereas in some cases chylous reflux into the lungs and pleurae via abnormal lymph channels in the lungs and pleurae as well as in the mediastinum may cause the chylothorax. In rare instances a patient may actually expectorate chylous fluid which seeps into the bronchi from the abnormal peribronchial lymphatics. A detailed analysis of reported cases together with some personal experience has demonstrated that pathological changes in the pulmonary and pleural lymphatic vessels are more common than is usually appreciated. The normal remarkable regenerative potential which is usually evident after experimental interruption of the lymphatics apparently is lacking in some humans due to genetic and other factors. Thus pathological changes, difficult to simulate experimentally, may be encountered. Lymphangiectasis is often found not to be limited to a single organ if complete studies of the lymphatic system are made.

Although chylous reflux into an organ, serous cavity, or limb is a rare occurrence among the considerable number of patients who have various types of lymph vessel pathology, chyle may serve as a visual tracer and thus focus attention on some lymph flow disturbances. In cases of lymphoedema of internal organs the observation of clear lymph fails to attract the attention it deserves. This is particularly true in the lungs, where respiratory function is vitally influenced by a proper balance between interstitial fluid formation and lymph drainage in both acute and chronic pathological conditions. A detailed analysis of cases of chylous reflux has served to point to features of lymphatic pathology which are not readily duplicated by experimental observations in animals. It appears evident that in some cases of chylous accumulations which are not due to trauma or neoplastic obstruction of large lymph channels, the patient with such so-called idiopathic lymph vessel pathology has a diffuse tissue disturbance. Hence the lymphatic regenerative capacity and response to lymphatic obstruction in these patients is probably not the same as in a normal human. This factor may likewise thwart attempts

to produce a similar pathological lesion in experimental animals.

Lymph vessels accompany the pulmonary arteries and bronchi and extend along their branches. Lymph channels are also present in the intersegmental pulmonary septa, where they accompany the pulmonary veins. The visceral pleura contains a rich lymphatic network. Valves within the lymph vessels determine the direction of lymph flow under normal conditions. The frequency of such valves varies in different parts of the pulmonary lymphatic system. When congenital or acquired lesions of the lymphatic vessels occur, the function of these valves may no longer be normal and the direction of lymph flow may be altered. Also the development of abnormal lymphatic pathways may result in unusual lymphatic networks as seen in both congenital and acquired conditions.

Dilatation of those intrapulmonary lymph vessels which accompany the pulmonary veins in the pulmonary septa is recognized frequently in cardiac lesions which result in pulmonary venous hypertension. Less well recognized, however, are the dilated lymph channels that accompany the pulmonary arteries and bronchi in a variety of chronic pulmonary diseases, except when such

¹ This study was aided by a grant from the Stony Wold Corporation

lymph channels are distended by neoplastic or granulomatous tissue which facilitates their identification. When these peribronchial lymphatic channels are filled with only fluid lymph, a definite distinction between lymph vessels and veins may not be so obvious. Therefore the dilatation of the peribronchial lymphatics in some chronic pulmonary diseases often goes unrecognized. Yet unusual dilatation of these peribronchial lymph vessels may in rare instances advance to such a stage that chylous reflux into these greatly dilated lymph vessels with incompetent valves may be possible.

When the lymphatics of the visceral or parietal pleura become distended and the pressure in the subpleural lymph channels mounts, a pleural effusion may occur unless the pleural space is obliterated by a previous pleuritis. If the intrapulmonary lymphatic system is so abnormal that chylous reflux into the lung can occur, and there is an associated dilatation of the lymphatics of the visceral pleura, a chylothorax rather than a simple pleural effusion may ensue. In some rare instances of lymphangiectasis, chylothorax may result from chyle seeping from the parietal pleura.

Reflux of chyle into the lungs can occur only when widely dilated lymph channels in the lungs have such free communication with branches of the thoracic duct that a retrograde flow of chyle is possible. In such instances the valves within the dilated lymph channels are rendered incompetent. Since experiments have demonstrated the difficulty of maintaining lymphatic obstruction by ligation or excision of lymphatics in the experimental animal, it appears that chylous reflux is probably not possible unless there is also present a congenital defect or a latent deficiency in lymphatic regeneration potential in the same individual. Some investigators regard the process as a neoplasia (Cornog and Enterline, 1966).

Thrombophlebitis of the subclavian or innominate veins has been a definite forerunner of the clinically manifest pulmonary pathology in some cases. Several years may elapse between the initial lymphatic obstruction in the mediastinum or neck and the development of recognized pulmonary lymphangiectasis. Whether the lungs of such patients were originally normal is often questionable. Associated pathological changes are present in the blood vessels in some cases, and some of the patients have lymphoedema of an extremity. In view of the evidence of genetic factors, it may be that chylous reflux is possible only if pathological processes in addition to those of the lymphatic vessels are operative.

Although the prognosis has often been poor in those rare cases of pulmonary lymphangiectasis in which the pathological process is so advanced that the diagnosis can be readily established, there is probably no sharp line of differentiation between these rare cases of gross chylous reflux and the large number with varying degrees of lymph stasis in the lungs without chylous reflux. In some patients the amount of chylous fluid seeping into the lungs may be small. One such patient, in whom we established a diagnosis of pulmonary fibrosis by a lung biopsy over 15 years ago, continues to do well; in that patient the 'milky' expectoration was never large and chylothorax has not occurred.

The presence of chyle can only be recognized grossly if the dilated lymphatic channels or the fluid accumulation in a serous cavity is examined at a time when sufficient fatty material has recently been absorbed from the intestinal tract. Because of the preoperative fasting state, we have occasionally noted striking changes between the chylous fluid aspirated the day before operation and the serous-appearing fluid found at the time of thoracotomy. Also the distended subpleural lymphatics may be less obvious in the fasting or terminal state. The use of lyophilic dyes may be of help if used in such situations. When an infant dies a few hours after birth with bilateral pleural effusions and pathological demonstration of congenital lymphangiectasis of the lung, it is not known whether chylothorax might have been evident later if the infant had survived.

Chylopericardium may be present in association with chylothorax; and rarely the pericardium is the only serous cavity involved. In some of these unusual cases the mechanism of chylous transudation into the pericardial cavity may be similar to that present in some cases of so-called idiopathic chylothorax. Obstruction to lymph drainage from the heart may be potentially dangerous aside from the production of cardiac tamponade. Cardiac arrest during operation may occur. The investigations of Miller, Pick, Kline, and Katz (1964) on the pathological alterations in the heart resulting from lymph stasis in the myocardium are of interest in this regard.

In discussions of chylothorax, a consideration of the source of the chyle is usually limited to traumatic and obstructive lesions of the thoracic duct or other large lymphatic channels within the mediastinum. The possibility that occasionally chylous fluid in the pleural cavity might be due at least in part to reflux of chyle into the lungs and pleura and hence into the pleural space is rarely

discussed. That chylous ascites may result from obstruction to the passage of chyle from the intestinal tract is recognized. Since chyle is normal in abdominal lymphatics and the thoracic duct in the post-absorptive period of digestion, noting chyle in these regions is not unusual. When chyle is found in portions of the body or within lymph channels in which under normal conditions only clear lymph is encountered, the presence of this chylous reflux may go unrecognized.

Some studies by Kinmonth and Taylor (1954) on the lymphatic circulation in lymphoedema of the legs help in analysing the pathology of the lymphatics within the lung. In a report of patients with *idiopathic* lymphoedema of the lower limbs, studied by various methods, they demonstrated that lymphatic stasis existed and that the lymphatics were dilated, valveless, and incompetent. No evidence of lymphatic obstruction was found in those cases which were unassociated with neoplasm or trauma. In some there was a chylous reflux into the leg. In these rare cases white vesicles appeared on the thigh, and fluid withdrawn from the lower leg resembled cream and had a high fat and protein content. The swelling of the leg was associated with chylous ascites. A few cases of chylothorax associated with chylous reflux into the legs are on record. In a report on chylous reflux, Kinmonth and Taylor (1964) stated that 19 patients with chylous complications were found among 650 patients with *primary* lymphoedema. This study did not include patients with diseases of the lymphatic system recognized as secondary to neoplasms, trauma, filariasis, or other conditions known to obstruct lymphatics. They divided their cases into two groups—those with megalymphatics and those with deficiency of lymphatic development. Among the five in the latter group there was no instance of vesicles on the skin or external fistulae; each of these five had oedematous limbs, but the chyle was found only in a serous cavity (peritoneum or pleura). One patient had chyle in both the peritoneal and pleural cavities, and another had chyle in one pleural cavity. These authors stated, 'In no case could any fistulae be found on exploration of the affected serous cavities, the chylous effusion occurring apparently as a transudate'. The single case in their series with recurrent left-sided chylothorax and swollen legs remained free of chylothorax six years after pleurodesis.

The radiological appearance of the lungs in cases of lymphatic stasis and chylous reflux will vary, depending on the associated pulmonary pathology and the acuteness or chronicity of the

lymph stasis. At the time that chylous fluid is seeping into the air passages in sufficient amount to be demonstrable, the usual finding is a diffuse, fine, reticulo-nodular density which is more prominent in the lower portions of the lungs. In most instances the pulmonary lesions have appeared to be rather similar in each lung, provided that pleural factors did not influence the lung lesions or obscure the pulmonary field. Varying degrees of associated emphysema and fibrosis are usually seen. In a personal case in which radiological observations are available from the time of apparent onset of illness until the terminal stage, a fine, diffuse infiltration of the lung fields with small bilateral pleural effusions was noted at first. These findings were less marked after a few days. Two years later, however, the bilateral reticulo-nodular lung densities were more prominent and there was then bilateral chylothorax of considerable magnitude.

It is premature to draw more than tentative conclusions concerning the pathophysiology of chylous reflux into the lungs and pleura. Thrombophlebitis of veins in the area where the thoracic duct joins the venous system is established as a forerunner of the chylous reflux in some of the cases; but one wonders whether the vascular obliterative process remained limited to the veins or involved also some of the lymph channels. This thought arises because ligation of the thoracic duct or thrombosis of these same veins does not usually result in pulmonary or pleural changes such as are here under discussion. Some pre-existing defect which limits the regenerative potential of that individual's lymphatic system seems to be present in those who progress to the advanced stage of chylous reflux. The frequent association of blood vessel abnormalities, such as haemangiomas, is noteworthy. Endocrinopathy may also at times be an associated finding.

When a thrombophlebitis of the subclavian or innominate vein is noted in connexion with the development of chylous reflux into the lungs, the question arises whether the obliterative process in the vein obstructed only the thoracic duct or whether the right lymphatic duct or other sites of communication between lymph channels and veins were also impaired. Venous angiography has demonstrated that a complete thrombotic obliteration of the involved vein may not be present even when a major degree of lymph blockade has been produced. This is consistent with our clinical observation that in a case of venous thrombosis in this area which led to chylous reflux only meagre evidence of venous

obstruction was present. Hence the venous thrombosis may easily go unrecognized. Mild trauma to the clavicular region was the aetiological factor of the venous thrombosis and subsequent lymphatic obstruction in one of my patients, and other cases in which trauma may have been concerned are on record. Often the trauma was so relatively mild that the question arose whether it played any part in initiating the pathological process. That even slight trauma might have been of importance is better understood if it is appreciated that a resultant limited venous thrombosis could still be of significance if crucial areas of the vein walls were involved. On the other hand, trauma may be suspected as the aetiological agent when the condition is due to abnormalities in lymphatic development. This statement applies to some cases of chylothorax in the newborn. In several cases reported in the literature the venous thrombosis with chylothorax occurred in the post-partum period.

In the future a more detailed study of the sputum of patients suspected of expectorating chyle must be made. In the patient reported by Löffler and Jaccard (1954), certain examinations performed on the chylous expectoration are of interest. Microscopically it was noted that lymphocytes were the overwhelming cellular element present. A chemical analysis of the sputum showed that 55% of the dried sediment was an ether-extractable lipoid. The amount of chyle in their patient's expectoration was sufficient to lead to the development of yellow bronchial casts. An interesting clinical feature of some of the cases reported in the literature is the occurrence of 'asthma'. This diagnosis may be erroneous when there is no previous history of asthma. It seems to be related to the partial obstruction of the air passages by the plugs of chylous material. It is often a late occurrence.

As more complete gross and microscopical studies of the tissues of all organs are undertaken, more evidence of the occasional widespread nature of the lymph vessel defect may become evident. In patients with lymphoedema of one extremity, another extremity or organ which shows no obvious gross abnormality may yet show abnormal lymph channels on lymphangiography or on microscopical examination. In cases of developmental defect of the lymphatic system there is sometimes evidence that a failure of the various lymph channels to connect with one another, rather than some other obstructive mechanism, is the important element. In one of the patients with congenital lymphangiectasis re-

ported by McKendry, Lindsay, and Gerstein (1957), in which chylothorax and markedly dilated lymph vessels in the pleura and pulmonary septa were present, a post-mortem radiological study of the thoracic duct showed no dilatation or obstruction of that channel.

Lampson (1948) is credited with having successfully treated the first case of chylothorax by ligation of the thoracic duct. He titled his report 'Traumatic Chylothorax', but a critical analysis of his case reveals findings which illustrate how easily the pulmonary pathology in a case of chylothorax may be overlooked. In Lampson's patient there was no definite history of trauma, and the onset of illness was thought to be a pneumonia accompanied by severe paroxysms of coughing productive of sputum. The patient had apparently more dyspnoea than a moderate-sized unilateral chylothorax would ordinarily produce. All the radiographs showed a diffuse, fine infiltration, the nature of which was never established. The appearance of the pulmonary surface at operation was not described. At thoracotomy chyle was seen to come from the mediastinum. Following ligation of the thoracic duct, the left chylothorax never recurred, but in an addendum to the report it is stated that the patient developed severe 'asthma' and died without necropsy examination some two years later.

In some of the cases of chylothorax reported in the literature in which a thoracotomy was performed, the surgeon has been unable to determine the source of the chylothorax. Attention was usually concentrated on the mediastinum and thoracic duct, and even though no leakage from the thoracic duct or mediastinal pleura was seen, there is often no mention of the appearance of the pleural aspect of the lung. In a case of chylothorax included in the report of McKendry *et al.* (1957), however, at surgical exploration of the thorax 'there was a generalized serous weeping of the entire pleural surface'.

Before summarizing the features of the reported and personally observed cases in which definite evidence of chylous reflux into the lung was evident, it is important to stress that the presence of chylous fluid should not be regarded as a criterion of a specific pathological entity. These cases are selected for special consideration merely because they illustrate the advanced degree of pathological changes in the lymph vessel that may develop in the lungs of certain individuals. Although these patients may possess an unusual generalized abnormality of their lymphatics and hence be prone to develop a pathological picture which might not

occur in other circumstances, yet it seems that a detailed investigation of such cases would broaden our concept of intrathoracic lymphatics. Certainly the analysis of the pathophysiology of cases of so-called 'idiopathic chylothorax' is incomplete unless the intrapulmonary and pleural channels are considered as the possible source of such chylous accumulations. A failure to do this has delayed clarification of the routes by which chyle may seep into serous cavities. In the future more information will be obtained by the greater use of lymphangiography. Chyle is actually a poor substance to rely upon as a guide to abnormal lymph vessel distribution for several reasons. First, retrograde chyle flow occurs only in some advanced cases; it is not evident in the much more common cases with abnormalities in the lungs, such as pulmonary fibrosis, in which lymphatic abnormalities may also be present. Secondly, even when the lymph channels are so dilated and abnormal that chylous reflux might occur, no chyle may be evident unless examination of the tissues is performed at a time when maximum absorption of fatty material from the intestine is occurring. Thirdly, the chyle is diluted with other lymph to varying degrees and hence the observed fluid may vary widely in its chylous component; there is no line of distinction between chyle and chylous fluid. Finally, expectorated chylous fluid is usually not distinguished from ordinary yellow purulent sputum.

The patients with evidence of chylous reflux into the lungs and pleura have usually been women with an onset of thoracic symptoms in early or middle adult life. Some had a history of pulmonary disease, such as pneumonia, spontaneous pneumothorax, or occasional haemoptyses, before the clinical demonstration of obvious abnormalities in the lymph vessels. The significance of the lymphangiectasis in the development of the pulmonary lesion is frequently obscure; when associated with fibrosis it is often unknown whether the pulmonary fibrosis or the lymphatic disturbance is the primary feature. Hence, the date of onset of the pathological process is difficult to determine.

Those women without a definite history of trauma, who have evidence of chylous seepage into the lungs and pleura, appear to me to have a high incidence of gynaecological abnormalities. This is of interest in view of the known relationship between ovarian dysgenesis and congenital lymphoedema. Some patients with chylous reflux into the lungs have had a thrombosis of the veins in the region of the entrance of the thoracic duct.

When traumatic injury to the thoracic duct itself has definitely occurred, chylous reflux into the lungs should not be expected. Although trauma has been suspected in some of the published cases, it was usually uncertain what role it played except when it caused thrombosis.

As the techniques of lymphangiography improve, and as such diagnostic methods are applied more frequently, both clinically and in conjunction with post-mortem examinations, we can anticipate a greater knowledge of the pathology of lymphatic vessels. Retrograde injections, however, are frequently not possible because of the effective construction of the lymphatic valves in normal states. But when chylous reflux occurs, such retrograde injections might be possible and instructive.

Brzek, Křen, and Bartoš (1965) reported on retrograde lymphography of the thoracic duct performed on 20 hospital inpatients. In three, it was possible to fill the entire thoracic duct together with the cisterna chyli and its lumbar tributaries. In seven, only the thoracic portion of the duct was filled. In 10, competence of the valves prevented filling of the thoracic duct. Anastomoses were demonstrated in the middle portion of the duct on three occasions. Obviously the nature of the illnesses present in the studied patients would influence the incidence and nature of the thoracic duct visualization.

More detailed studies of the distribution of the dilated lymphatics in various types of pulmonary pathology will be necessary before final statements can be made about what parts of the pulmonary lymphatic system are most dilated in the various lesions associated with lymphangiectasis. When lymph stasis is secondary to pulmonary venous hypertension, the septal pulmonary lymphatics are particularly prominent. Such is the case in severe mitral stenosis and in some chronic lesions obstructing the pulmonary veins. In cases of chylous reflux, however, the lymphatic channels accompanying the bronchi appear to be particularly large and the radiological findings are not the same as those seen with pulmonary venous hypertension.

The therapy for a given case of non-traumatic chylothorax depends on the nature of the pathological process. In some cases obliteration of the pleural space, following either thoracentesis or surgical pleurodesis, may be satisfactory. In others, with persistent chylothorax, ligation of the thoracic duct or other large lymph channels may appear to arrest the condition. If any related pulmonary lesion is present, however, the prognosis is uncertain because the lymphatic abnormality in

the lung may continue to progress. When chylous reflux into the lungs is established, therapy thus far has been unsatisfactory unless the chylous reflux is minimal. When chyle continues to accumulate in all serous cavities, the outlook has been poor but a future better understanding of the pathophysiology may indicate the value of surgical lymphovenous anastomoses.

CASE REPORTS

CASE 1 A. V. was first admitted to Lenox Hill Hospital in 1948 when she was 47 years old. At that time she gave a history of chest discomfort, haemoptysis, and recurrent spontaneous pneumothorax during the previous four and a half years. The chest complaint consisted principally of attacks of smothering substernal pain followed by a small haemoptysis. These episodes would usually occur with sexual intercourse or while doing heavy work. There had been five episodes of spontaneous pneumothorax on the left side accompanied by left shoulder pain. Her menstrual periods had always been irregular. A hysterectomy had been performed for uterine fibroids one year previously and oestrogen therapy had been given since then.

At a bronchoscopy performed on 3 June 1948 generalized redness of the mucous membrane of the right main stem bronchus and all the visualized segmental bronchi on the right side was noted. The left main stem bronchus appeared to be relatively normal. A bronchoscopic diagnosis of chronic bronchitis involving chiefly the right lung was made. A culture was taken for bacteriological studies and for fungi, but these yielded nothing significant.

The patient was readmitted to hospital on 7 May 1952 with the history that she had had about six episodes of left-sided chest pain and shortness of breath. These episodes were often accompanied by a small haemoptysis and were apparently associated with the development of a spontaneous pneumothorax.

Approximately a year and a half before this second admission she had been admitted to hospital for bronchitis and 'asthma'. There were no typical asthmatic attacks at any time.

In the summer of 1951 the patient noticed shortness of breath, and in August 1951 she began to cough up milky material at night; this was accompanied by a wheezing sensation in the chest. This continued until January 1952, when pneumonia was diagnosed at the time of an acute illness. After this she had no further expectoration of milky material but did develop severe dyspnoea. Examination by her physician revealed the presence of a left-sided chylothorax (the pleural fluid aspirated in April 1952 showed a high fat content but was negative for bacteria or fungi, and was also negative for malignant cells).

During the weeks immediately before admission to hospital there were a few episodes of expectoration

of milky fluid and an occasional small haemoptysis. The patient had had no history of industrial exposure. An electrocardiogram was normal.

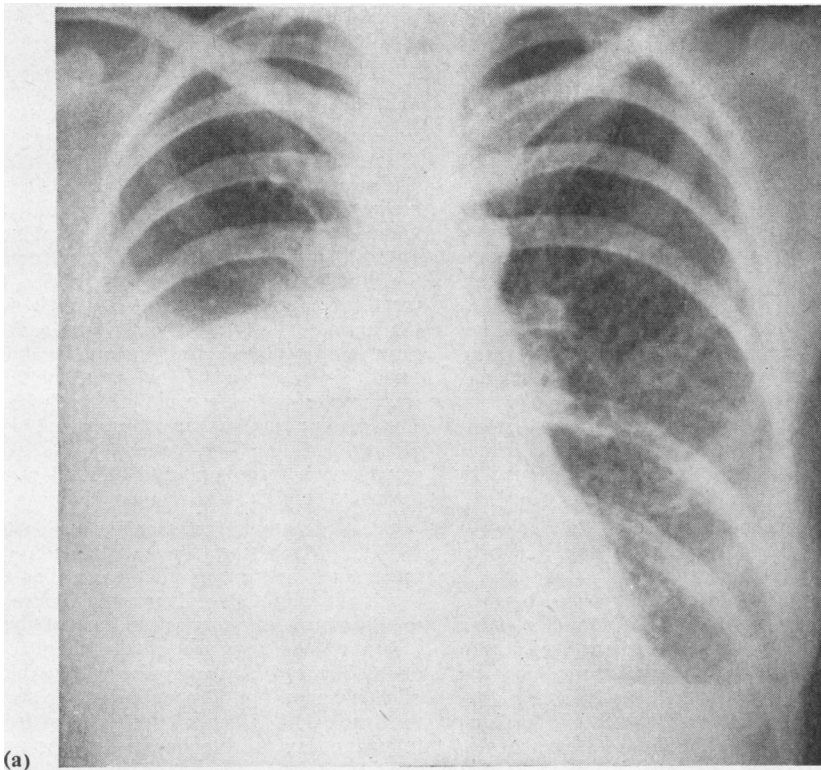
Because of persistence of the left-sided chylothorax a left thoracotomy was performed on 26 May 1952 and a large amount of chylous fluid was found in the left pleural cavity. There was diffuse injection of the visceral and parietal pleura, and the lower portion of the left lung was relatively airless. The remainder of the lung showed numerous superficial blebs with areas of fibrosis in between. Many of these blebs were so thin-walled that they appeared to be transparent (at this time these blebs were considered to be air-containing). No lymphadenopathy was present. The mediastinal structures appeared to be normal. There were no visceroparietal adhesions.

The chylous fluid was evacuated and a biopsy of the airless section of the basal portion of the lower lobe, and another of the emphysematous apex of the same lung, was performed. The chest incision was closed with intrapleural drainage. A diagnosis of fibrosis and emphysema of the lung was made on the basis of the lung biopsies. The microscopical report on the biopsy taken from the portion of the lung with the cyst-like areas made no reference to the presence of dilated lymphatics, but later re-examination of these slides showed markedly dilated pulmonary and pleural lymphatics.

Following the surgical procedure the patient had a febrile course associated with a relatively rapid pulse, but she gradually improved and was discharged from hospital on the 25th postoperative day.

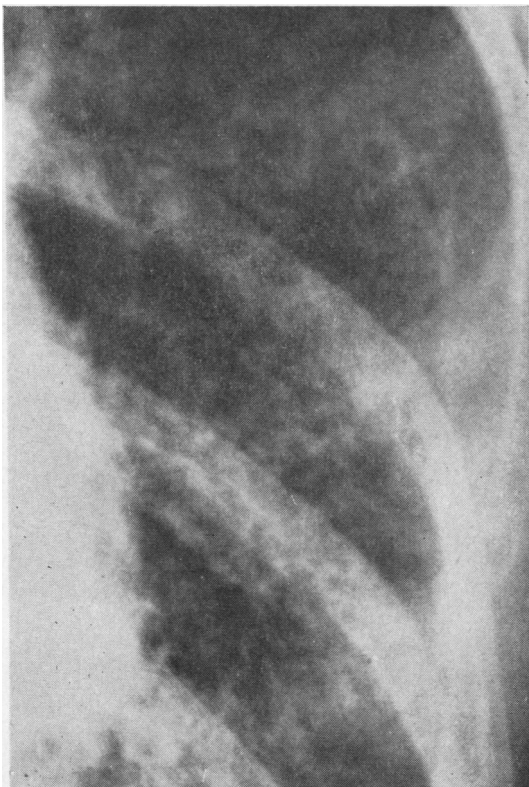
She was again admitted to hospital in October 1952, at which time she gave a history that shortly after the operation in which the left pleural space was obliterated and the chylothorax abolished, she again began to cough up milky fluid. A repeat bronchoscopy at this time showed the mucosa of the right bronchus to be covered by a dry, mucus-like material. Difficulty in good visualization of the left lower lobe bronchus was thought to be due to pulmonary fibrosis. The bronchoscopist, a man of experience, noted that 'the type of material observed in the bronchial tree is unusual'.

The final hospital admission was in February 1954. The patient stated that she had had no symptoms for about two weeks after discharge from hospital, but then (about five weeks after obliteration of the left pleural cavity) she again had a cough productive of milky material. This expectoration of milky fluid continued until October 1953, when it suddenly ceased; when the expectoration stopped, she became dyspnoeic and shortly after that was found to have a right-sided chylothorax (Fig. 1). Since the chylothorax did not respond to repeated aspirations, it was decided to treat this by surgical obliteration of the pleural cavity. On 26 February 1954 a right thoracotomy was performed. The liquid in the right pleural space at the time of operation was turbid, thin fluid which was not nearly as milky as the three litres that had been removed by thoracentesis the previous day



(a)

FIG. 1. Case 1. (a) Radiograph shows a large right pleural effusion (chylothorax). The diffuse reticular densities in the left lung have increased since the left thoracotomy and pleurodesis were performed 20 months previously. (b) Detailed view of portion of left lung field. These diffuse densities are produced by a combination of pulmonary fibrosis, lymphangiectasis, congestion, and inflammation.



(b)

(the patient had been on a diet low in fat and had a period without any food before operation). At operation the right lung was less air-containing than normal; it was diffusely thickened without nodulation. Minimal pinpoint sites of air leakage developed during manipulation. There was prominence of the lymphatics. Fibrosis of the lung was most marked at the base of the lower lobe. There was no hilar adenopathy. Mediastinal exploration showed no fibrous mediastinitis. The wall of the oesophagus was not thickened. The pericardium appeared to be normal. The thoracic duct was not seen.

The biopsy of the right lung, taken at this operation, was reported as showing a fibrotic pleura in which many channels of varying sizes, lined by endothelial cells, were recognized to be lymphatic channels. Some chronic inflammatory reaction was also present.

Following this operation there was much shortness of breath and difficulty in raising milky material. Three days postoperatively a small left pneumothorax was evident. This pneumothorax increased in size the following day and was treated by closed catheter drainage. There was recurrent difficulty with air leakage from both lungs and increased difficulty with

fluid in the tracheobronchial tree. The patient died on 12 March 1954.

At necropsy the pleural surface of each lung showed many small blebs with thin transparent walls; the blebs measured 1 to 3 mm. in diameter and contained a thin, colourless fluid. The cut surface of the lungs showed numerous cyst-like spaces similar to those seen on the pleural surface. The parenchyma was indurated and poorly aerated. The bronchi contained casts of coagulated grey-white material. The thoracic duct was not identified. On microscopic examination of the lungs many of the alveolar spaces were found to be filled with lymphocytes, whereas other alveoli contained serum, red blood cells, and large cells filled with haemosiderin. The cyst-like spaces were lined with endothelium and were dilated lymphatics. The pulmonary septa were thickened by fibrosis.

CASE 2 D. L. was in good health until the age of 36 years. In September 1953 she sustained a brief compression of the clavicular region of the thorax which was followed within a day or two by shortness of breath. A chest radiograph on 15 September showed small bilateral pleural effusions and a fine diffuse reticular infiltration of both lungs which was more marked in the lower lung fields (Fig. 2). There was also slightly increased prominence of the hilar shadows. Another radiograph four days later showed

less pleural fluid and a decrease in the diffuse pulmonary infiltration (Fig. 3), but later there was increasing evidence of bilateral pleural effusions and episodes of difficulty in breathing. In 1955 there was also evidence of fluid in the abdomen. In August 1955 further pleural fluid was noted and the reticulo-nodular densities in the lungs were increased (Fig. 4). In September 1955 it was first determined that the fluid was chyle. In October 1955 a hysterectomy for fibroids was performed and chyle was found in the peritoneal cavity. The chylous ascites continued after the gynaecological operation and chyle continued to leak from the abdominal incision. The chyle was now reappearing rapidly in both pleural cavities. The cardiac shadow was obscured by the adjacent pleural densities. The patient had a non-productive cough when large amounts of fluid were present in the chest (Fig. 5).

The patient was first seen by me on 21 December 1955, at which time she had dilated veins over the upper anterior thorax and breasts. The findings were consistent with diffuse lymphatic blockage secondary to thrombosis of veins at the base of the neck in the region of the entrance of the thoracic and lymph ducts. She had a weak pulse with a blood pressure of 90/60 mm. Hg. The next day she was transferred to Lenox Hill Hospital for further treatment. The following day the blood pressure was not obtainable

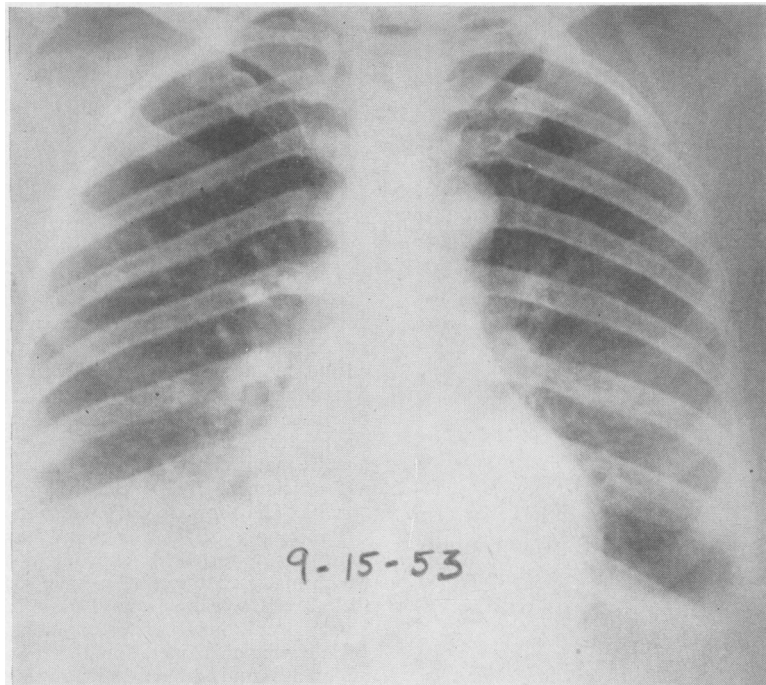


FIG. 2. Case 2. Radiograph several days after venous thrombotic obstruction to lymph drainage. Bilateral pleural effusions and a fine diffuse pulmonary infiltration are present.

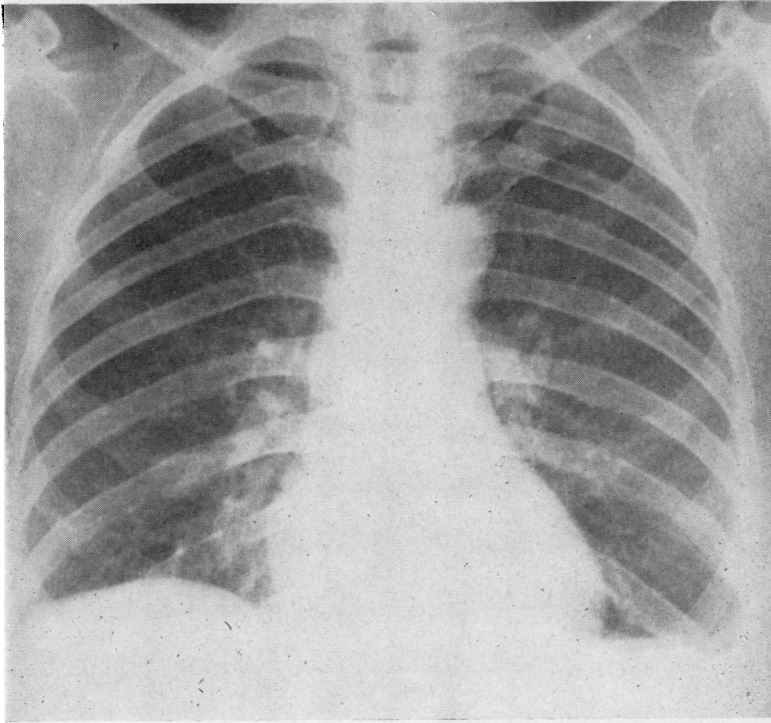


FIG. 3. *Case 2. Radiograph taken four days after that shown in Fig. 2 reveals a decrease in pulmonary infiltration and less pleural fluid.*

but improved somewhat after a large amount of chylous fluid had been aspirated from each pleural cavity. An operative procedure, to explore the thoracic duct for a possible shunt, was planned but the patient sustained a cardiac arrest on the induction of anaesthesia and only temporarily responded to thoracotomy, drainage of a chylopericardium, and cardiac massage. The lung showed a diffuse pulmonary fibrosis and emphysema with dilatation of the pleural lymphatics. There was no evidence of mediastinal lymphadenopathy or neoplasm. Necropsy was not permitted.

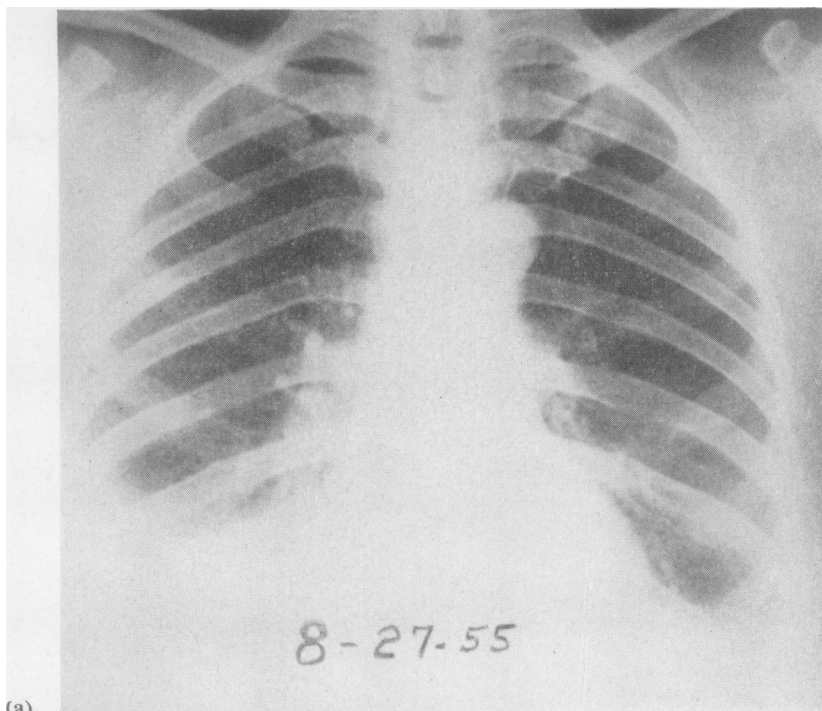
CASE 3 E. B., gravid 9, was 32 years old in 1951 when she was seen because of cough, occasional wheeze, some shortness of breath, and intermittent fever. At times milky fluid was expectorated; this occurred especially with the menses. Chest radiographs showed bilateral pulmonary fibrosis (Fig. 6). A lung biopsy in 1951 showed extensive fibrosis of the lungs and pleura with dilatation of the pleural and peripheral intrapulmonary lymphatics and pleural lymph follicles. In 1953 the shortness of breath improved after treatment with cortisone. Later an ovarian cyst was removed and following this operation there was a sustained improvement in respiration and general well-being. Cortisone therapy was given

intermittently in the ensuing years. In 1966 the patient reported by letter that she felt well.

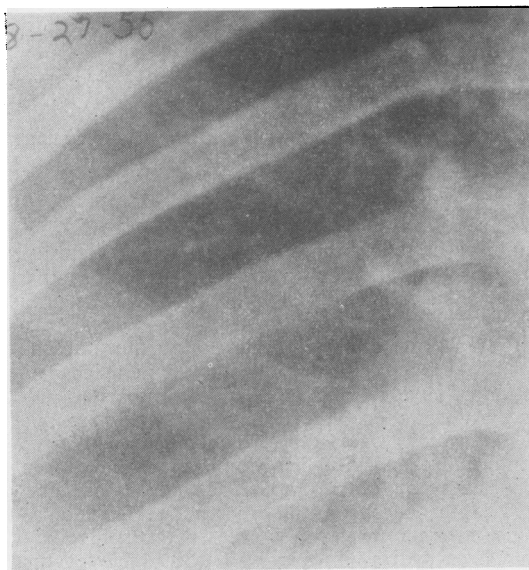
REVIEW OF THE LITERATURE

A number of reports have appeared in the literature indicating the variety of clinical manifestations that may be noted in cases of chylothorax in which significant lymphangiectasis of the lungs has also been present. In some of these the chylous reflux into the lungs was of sufficient degree to result in the expectoration of chylous fluid. In some the associated pulmonary fibrosis or hypertrophy of smooth muscle within the lungs was an outstanding feature. Diffuse pathological changes in the lymph vessels have been evident in many of the reports. The cases are presented in the chronological order of publication, as some of the more recently observed patients have had newer investigative procedures not available at the time of the earlier reports.

Delarue, Depierre, and Roujeau (1950) reported a case of pulmonary lymphangiectasis with chylous pneumonia. They stated that, to their knowledge, the medical literature contained no similar case at that time. Their female patient was first seen in 1945, at which time she complained of several episodes of nocturnal dyspnoea, unassociated with expectoration



(a)



(b)

FIG. 4. Case 2. (a) Radiograph almost two years later shows an increase in the fine stringy infiltration of the lungs and some bilateral pleural effusion (chylothorax). (b) Detailed view of portion of lung field. The fine infiltrate was not obvious if the chest film was even slightly overexposed.

or fever. The episodes were like asthmatic attacks, but no allergic aetiology was discovered. In March 1948, when the patient was 40 years old, she was delivered of a baby following a normal pregnancy. Eight hours after delivery she had severe pain in the left arm, and oedema of the left arm and left anterior thoracic region was noted. A diagnosis of phlebitis was made. A venogram later confirmed the presence of obliteration of the subclavian vein and the development of considerable collateral circulation.

In August 1948 attacks of dyspnoea again occurred. These attacks might occur as often as two or three times during a night and were associated with tachycardia, but without expectoration. Cardiac drugs did not help. The patient became anorexic and lost a kilogram in weight. Chest radiographs showed diffuse reticulo-nodular opacities in both lung fields, most marked near the bases. There was also liquid at the left base which was proved to be chyle. The blood pressure and electrocardiogram, as well as the blood count, were normal. The fine diffuse opacities in the lung fields were noted to be increased on subsequent radiographs. In January 1950 the patient was expectorating 'white cheese'. At this time also oedema of the left leg was present. The patient became progressively worse and died of respiratory insufficiency in March 1950. A necropsy revealed that the right pleural cavity was obliterated by a dense pleuritis. On this side the patient had never had a chylothorax, but during the last months of life radiographs had shown a marked intrapulmonary density. This right

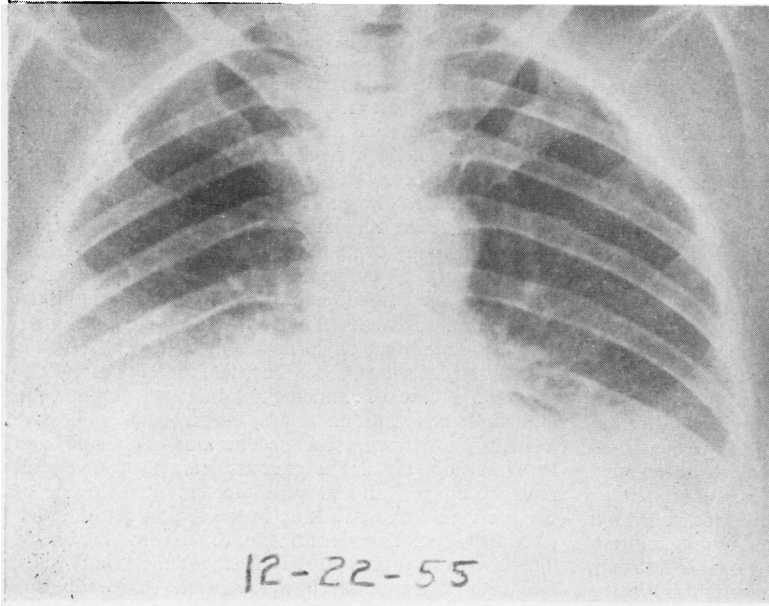


FIG. 5. *Case 2. Large bilateral chylothorax which obscures evidence of chylopericardium. The diffuse pulmonary infiltrate has increased.*

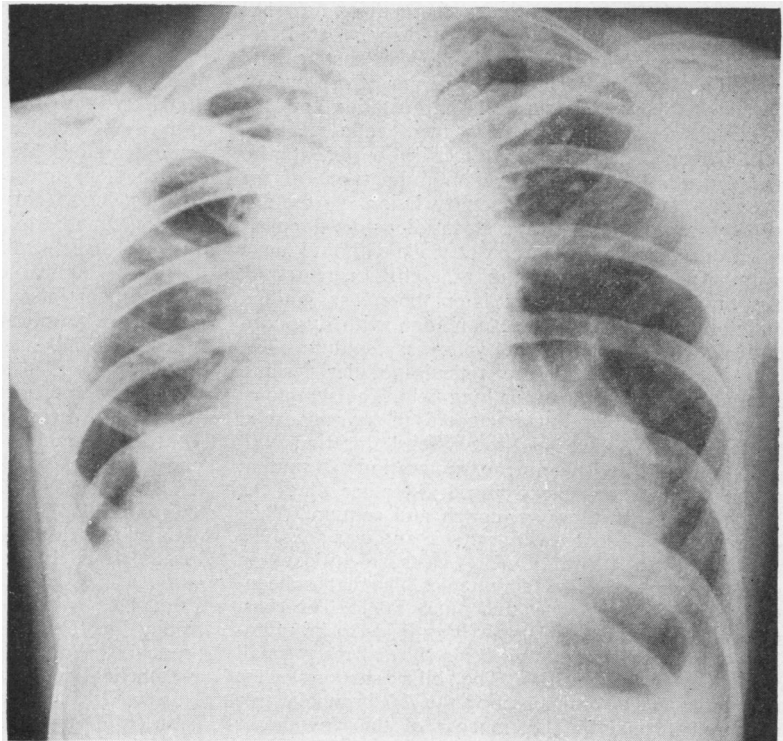


FIG. 6. *Case 3. Radiograph shows advanced pulmonary fibrosis, most marked in the hilar portions of the lungs, with peripheral pulmonary emphysema which obscures the pulmonary infiltrates. Pre-operatively the hilar masses were incorrectly assumed to be largely due to hilar lymphadenopathy.*

lung was heavy and non-crepitant on post-mortem examination, and was more than three times the normal weight. The surface of the lung showed cyst-like vesicles. The lung parenchyma showed hepatization. The upper lobe was less dense than the lower but also showed innumerable small vesicles. By contrast, the left lung, which was on the side of the chylothorax, weighed only one-third as much as the right lung, but the appearance of the surface was similar to that of the opposite lung. Microscopic examination revealed markedly dilated lymphatics throughout the lungs, with fibrosis, emphysema, and pneumonitis.

Brandt (1952) reported a 48-year-old woman who developed a chylothorax post partum. Four years later she had shortness of breath, and two years later, again post partum, she had recurrent chylothorax. Radiographs showed a diffuse fine nodular infiltration of the lower portion of both lungs. The patient died after operation performed to ligate the thoracic duct. Necropsy showed a marked diffuse angiomatous process in the lungs and thoracic lymph nodes. Brandt did not regard the process as a true malignant tumour.

Reinhardt (1953) reported a 30-year-old woman who had been diagnosed as having sarcoidosis on the basis of radiological findings in the lungs. The patient had been well until 28 years of age, when she began to have repeated episodes of 'collapse'. Several weeks later she expectorated large quantities of sputum which was milky and yellow-red in colour. The patient was afebrile. There was venous obstruction to the left arm. A right chylothorax was demonstrated six months later. The patient developed wasting and increasing dyspnoea and died after three years. Reinhardt suggested surgical implantation of the thoracic duct into a vein as a therapeutic measure.

Löffler and Jaccard (1954) described a patient who had expectorated chyle in whom radiographs of the chest showed a miliary pulmonary lesion. At the age of 28 years this woman had an insidious development of a left-sided pleural effusion of chyle without known cause. After eight thoracenteses the effusion regressed, but one and a half years later there was gradual deterioration in her general condition with dyspnoea and cough productive of yellowish sputum. The radiograph showed diffuse reticulo-nodular lesions, especially in the right lower lung field. The symptoms gradually increased but fluctuated in severity, with exacerbations of two to three weeks' duration with dyspnoea and considerable expectoration of sputum which at times was blood-tinged. At other times the patient was almost free of cough and sputum. When examined the patient was dyspnoeic and was coughing up from 100 to 300 ml. of yellow casts which floated in water and appeared like thin noodles. The material contained many lymphocytes and much lipid. The chest radiographs showed the upper lung fields to be radiolucent, but both lower lung fields showed many small reticulo-nodular densities. The hilar shadows were not enlarged. On bronchoscopy the left bronchial tree appeared normal but the mucosa of the right lower lobe was reddened. The authors commented on the

association of the disappearance of the chylothorax with the subsequent appearance of the unusual sputum and the miliary type of lung shadows.

Brewer (1955) reported a 37-year-old housewife who complained of 'draining sinuses' in the right leg of 27 years' duration. For the last 12 years there had been recurrent right-sided chylous effusion, which occurred when the right thigh did not drain adequately. The patient entered hospital complaining of weakness, chills, and fever. Examination revealed a swollen right thigh with many draining blebs over which the patient was wearing a colostomy bag. Chest radiographs showed a right-sided pleural effusion. An abdominal exploration revealed dilated lymph vessels and small sacculles containing chyle in the mesentery.

Listerud, Harkins, Loe, Thomas, and Nyhus (1958) reported a case of coincidental bilateral chylothorax and chylous ascites in a 37-year-old man who gave a history of having an oedematous left hand and forearm since birth. The patient died after four operative procedures, and at post mortem no evidence of the thoracic duct was found in the region of the upper abdomen, posterior mediastinum, or in the neck. There was no thrombosis of the subclavian veins. Sections of the small bowel showed chronic lymph stasis. Sections of the liver showed widening of the space between the liver cells. A lung section showed recent bronchopneumonia with dilatation of lymphatic channels along vascular and bronchial walls.

The significant findings in the cases discussed by Laipply and Sherrick (1958) included the following. In one case in which the thoracic duct had been ligated just above the diaphragm, as therapy for recurrent left chylothorax at a time when biopsy of the left lung revealed normal pulmonary tissue, necropsy two and a half years later revealed multiple emphysematous blebs and tiny cysts, some of which contained air under pressure, while others contained chylous fluid. This patient had developed a right chylopneumothorax over two years after the thoracic duct was ligated. She, like other cases of this group, died with clinical evidence of increasing dyspnoea. This patient also showed hyperplasia of smooth muscle in the interstitial tissue of the lung, the walls of the bronchi and bronchioles, and the lymphatics. Smooth muscle proliferation was also noted in the pulmonary and mediastinal lymph nodes, especially around the peripheral lymph sinuses. Sections taken from the region of the thoracic duct showed similar smooth muscle proliferation.

The second patient, reported by Laipply and Sherrick, died during induction of anaesthesia for a planned ligation of the thoracic duct as treatment for a left chylothorax. Necropsy revealed numerous cystic spaces, giving the lung a honeycombed appearance. This case also showed smooth muscle hypertrophy in the interalveolar septa, lymphatics, and bronchi. Within the smooth muscle nodules, endothelial-lined spaces were noted.

Justin-Besançon, Péquignot, Galey, Renault, and Even (1963) reported a 43-year-old woman who complained of dyspnoea and mucoid sputum with blood-

streaking. There was a diffuse lesion in both lungs and a right chylothorax. Lymphangiography revealed dilatation of the lumbar lymphatics with stasis. A lung biopsy showed lymphangiectasis with fibrosis and muscular hypertrophy. The patient had respiratory insufficiency with findings of severe hypoxaemia but a normal carbon dioxide tension. Pulmonary function did not improve after surgical obliteration of the pleural space.

Godart, Collette, and Dalem (1964) reported a 38-year-old woman who complained of fatigue and respiratory difficulty. The presence of a right chylothorax was demonstrated. There was no history of trauma, infection, or neoplasm to explain the aetiology of the chylothorax. On thoracoscopy a dilated vena azygos was noted. Lymphangiography with injection of radiopaque material into the lower extremities (which appeared normal) was done. At the time of the injection immediate resistance to the progress of the contrast medium was noted, and it was also ascertained that 24 hours later the iodine-containing material was still stagnant in the iliac region. The thoracic duct was not seen. It was felt that rupture of the thoracic duct could not be the explanation, since that would not have caused such a resistance to the progress of the contrast fluid. It was decided to produce pleural symphysis by continued pleural drainage, since previously the chyle had reaccumulated rapidly after each thoracentesis. Four months later a radiograph of the chest showed the right pleural space to be obliterated, but a pleural collection along the lateral chest wall on the left side was now present. At this same later date radiography of the abdomen showed that the Lipiodol which had been injected into the foot four months previously had refluxed into a series of small cavities in the lumbosacral region. These findings of dilated cystic lymphatics in the abdomen proved the presence of a malformation of the lymphatic vessels. It was concluded that the thoracic duct was either absent or obstructed.

Lamotte, Mathey, Segrestaa, and Logeais (1965) reported a 49-year-old woman who had a diffuse reticulo-nodular infiltration in both lungs and 'asthma' prior to developing complications following a thyroid operation. A left chylothorax developed which responded to surgical obliteration of the pleural space. Biopsy of the lung showed dilated pleural and pulmonary lymphatics. Gradual improvement followed the pleurectomy. The thoracic duct was not ligated because it was appreciated that this intervention is not advisable in some cases of lymphangiectasis causing chylothorax.

Fréour, Couraud, Germouty, Chomy, Warin, Mage, and Moukdarath (1966) presented an adult with a left chylothorax on whom angiographic and lymphangiographic studies had been performed. These examinations showed partial stenosis of the left innominate vein and a complex network of lymph channels between the thoracic duct and the intercostal axillary and pulmonary areas. The chylothorax apparently resulted from these abnormal lymph channels causing

chyle to seep into the left pleural cavity; the right pleural cavity had been obliterated by an old pleuritis. The lymphangiogram showed reflux into the lung.

Humbert, Zakarian, Delmont, Desnanot, Clérambault, and Picaut (1966) reported two cases of idiopathic chylothorax; one of these patients developed an exudative enteropathy after ligation of the thoracic duct and pleurectomy. Lymphangiography after operation revealed stagnation in dilated retroperitoneal lymphatics.

Davies (1967) reported a congenital lymphangiectasis of a middle lobe which first caused symptoms in a man at the age of 48 years, when he began to cough up casts of the middle lobe bronchial tree. These white casts were studied regarding structure, histochemistry, and cytology. The casts had a small mucopolysaccharide content and no fibrin was detected. Microscopically they contained many lymphocytes and histiocytes. The lobe showed a cobble-stone pleura with a coarse network of distended pleural lymphatics, and the intrapulmonary septal lymphatics were also dilated. Lymph was seen to leak from the transected peribronchial tissues at the time of lobectomy, and chylothorax was a post-operative complication which required a pleurodesis. The lobe involved by lymphangiectasis showed some hypoplasia of the blood vessels and a reduced number of alveoli, all pointing to a developmental fault. Infection and pulmonary fibrosis were absent. This case is interesting because it is an example of pulmonary lymphangiectasis of limited extent and hence first caused symptoms in adult life in the absence of infection. Most cases of lymphangiectasis first recognized in adult life are complicated by secondary infection at the time the lung is studied microscopically.

DISCUSSION

Although it appears probable that maldevelopment of the lymphatic vessels may be a feature of those advanced cases of lymphangiectasis that develop chylous reflux, cases of congenital pulmonary lymphangiectasis and cases of non-traumatic chylothorax diagnosed in the neonatal period have not been included in this report. Most cases of diffuse pulmonary lymphangiectasis clinically manifest in infancy die in the neonatal period. Little is known about the lungs in later life of those who survived a chylothorax occurring in infancy. That lesser degrees of congenital pulmonary and pleural lymph vessel abnormalities occur and are not recognized in childhood appears to be probable. Genetic and prenatal factors may be important in the development of some types of intrapulmonary and pleural lymphangiectasis first clinically manifest in adult years. This concept is the most logical explanation of the pathological changes in the pulmonary lymphatics of those rare patients who develop chylous reflux into the lungs. Hence it

appears most likely that both constitutional and acquired factors combine to produce the advanced lymphangiectasis such patients may manifest. Unless the dual influences of prenatal and later acquired factors are borne in mind, the limitations to experimental production of similar lesions in normal animals will not be recognized. A fundamental deficiency in the development of lymph channels may be manifested by the presence of dilated channels with inadequate valves with resultant stasis, or by a lack of development of adequate channels, or the failure of proper connexions to develop between various channels leading to obstruction to lymph drainage. Such maldevelopment may be evident as a congenital defect or become manifest in the process of tissue regeneration or following infection.

The recently reported studies on intestinal lymphangiectasis reveal a pathophysiological pattern that parallels some of the observations on pulmonary lymphangiectasis. When the submucosal lymphatics of the intestine are dilated there may be an abnormal loss of serum proteins into the intestinal lumen. Rarely this transudated fluid may be recognized as chylous when obtained by an indwelling intestinal tube. Thus a process of lymph seepage is seen similar to that which occurs when a patient expectorates chylous material which has seeped into the bronchial tree. In the cases of both intestinal and pulmonary lymphangiectasis there is accumulating evidence of genetic factors and findings, indicating that the pathological process in the lymphatic system may be diffuse and involve more than one organ or region of the body. Secondary infection may be responsible for the first clinical awareness of a pre-existing lymphatic maldevelopment. Also any factor that raises the venous pressure may result in an increase in lymph vessel pressure and thus lead to increased lymph stasis and transudation into the tissues and serous cavities. Whether this is clear lymph or chylous fluid depends mainly on the source of the lymph. If the venous pressure is high, red blood cells may be found in the lymph.

On comparing the microscopic findings of the lungs of infants with lymphangiectasis with those of adults with marked dilated lymphatics one notes a difference in the prominence of smooth muscle. Whereas muscle hypertrophy is not a usual feature of lymphangiectasis of the newborn, it is often a feature together with fibrosis in the pulmonary parenchyma of adults with lymphangiectasis. This suggests that the muscular proliferation develops later than the lymphatic over-

growth. Cornog and Enterline (1966) have written a paper entitled 'Lymphangiomyoma, a benign lesion of chyloferous lymphatics synonymous with lymphangiopericytoma', in which they stated that the lesion is a hamartoma. They point out that a percentage of the cases they selected had a mass in the mediastinum often in relationship to the thoracic duct and they feel that the condition is an abnormal growth. Others have considered the lesion as a diffuse malignant disease.

A number of pathologists have been interested in the musculature of the lungs in chronic pulmonary diseases. Liebow, Loring, and Felton (1953) made a broad evaluation of this subject by reviewing over 400 surgical lung specimens removed for a variety of pathological conditions. They noted that whereas muscular hypertrophy or hyperplasia was rare in the lungs resected for tuberculosis or neoplasms, such an increase in muscular components was not rare in emphysema and chronic suppurative diseases. Liebow called to our attention the marked proliferation of smooth muscle which may be found in some cases of pulmonary fibrosis. At times this muscular hypertrophy may attain a surprising prominence. The source of this muscular hyperplasia is open to some conjecture. Hypertrophy of muscle around bronchi is a recognized occurrence in some lungs showing pulmonary emphysema. The diffuse disposition of smooth muscle throughout the lung in some cases of advanced pulmonary fibrosis without much associated emphysema requires a broader concept. Liebow stated that masses of muscle may be associated with proliferated or dilated lymphatics in the lung and that extensive lymphatic proliferation may occasionally be a feature of chronic pulmonary disease. A peculiar microcystic formation of the respiratory passages may be an associated finding. Proliferated muscle fibres may be a part of the thickened wall of the lymphatics, or exist apparently free in the alveolar connective tissue stroma. Sheets of smooth muscle fibres may be observed in the pleura and in the pulmonary septa in association with lymphatic proliferation. The marked prominence of the lymphatics of the visceral pleura in such cases correlates with the chylothorax which may develop.

When bilateral pulmonary lymphangiectasis is present with unilateral chylothorax, at bronchoscopy a difference in the degree of congestion of the bronchi on the two sides may be noted. The bronchial tree on the side without the chylothorax may be the more congested since here the lymph pressure is higher because decompression of the lymphatics by seepage of lymph into the pleural

space has not occurred. This difference between the two sides may result because the pleural space is obliterated by adhesions on the side without chylothorax. Similarly at necropsy in cases with bilateral pulmonary lymphangiectasis but unilateral chylothorax a much heavier lung may be found on the side without chyle in the one pleural cavity which is obliterated by adhesions.

Only a few cases of isolated chylopericardium have been reported. In the case of Groves and Effler (1954) the chylopericardium was associated with a superior mediastinal hygroma. No direct communication linking the thoracic duct or the hygroma and the pericardial sac was identified at operation. In the case reported by Madison and Logue (1957) also no communication with the thoracic duct was established at operation, but some large lymphatic channels were found in the adjacent mediastinum. None of these channels had an obvious communication with the pericardium. In both these cases the thoracic duct was ligated, in addition to excision of the lymphatic channels adjacent to the pericardium, with resultant cure of the chylopericardium. Hudspeth and Miller (1966) reported a case of massive isolated chylopericardium in which ingested lipophilic dye and radioactive fat were demonstrated in the chyle in the pericardium. The thoracic duct appeared normal on lymphangiography. At operation no communication between the thoracic duct and the pericardium was demonstrated, but ligation of the thoracic duct and pericardial fenestration resulted in disappearance of the chylothorax.

TREATMENT

When chylothorax is chiefly due to seepage of chylous fluid and lymph from the visceral pleura the therapeutic problem is more complicated than when a chylothorax is the result of chyle leaking from the thoracic duct or other large mediastinal lymph channel. When a chylothorax develops secondary to chylous reflux in the lung and pleura, any procedure that completely obliterates the pleural space but does not also diminish the chylous reflux into the lung might tend to aggravate the intrapulmonary lesions and increase the lymph or chyle seepage into the lungs. Therefore it might be thought that thoracic duct ligation, rather than pleurodesis, would be indicated as the therapeutic measure in these unique cases. Evidence is already at hand to indicate that the pulmonary lesions may progress after ligation of a thoracic duct. Moreover, in several cases with pulmonary lymphangiectasis the surgeon was un-

able to identify a thoracic duct, and the thoracic duct has not always been found *post mortem* in cases with marked pulmonary lymphangiectasis. It is desirable that the collateral lymphatic channels that develop following ligation of the thoracic duct should not increase the lymph flow into the lungs. Until more information is obtained by lymphangiography during life and also during post-mortem investigations, knowledge about the varied lymphatic pathways and their functional efficacy in these patients will remain inadequate for guiding the most logical therapy.

Although this discussion on therapy has centred on measures to treat the chylothorax associated with the pulmonary disease, in most cases with lymphangiectasis in adults the exact role that the lymph vessel abnormality plays in the pathological process and progression of symptoms is as yet undetermined. These lungs in adults almost always show pulmonary fibrosis and often diffuse smooth muscle hyperplasia, either or both of which may be extensive, and these pathological changes may be of major importance. Unfortunately, in many of the reported cases of advanced pulmonary fibrosis with smooth muscle hyperplasia no information is given about the lymphatics. Rarely a chylothorax may result from the seepage of lymph into the pleural cavity from a lymphangioma or haemolymphangioma of the thoracic wall with involvement of the parietal pleura, as in the case reported by Sztaba and Vondrat (1965). In such a case therapy is directed towards excision of the lymphangioma as far as is feasible.

REFERENCES

- Brandt, M. (1952). Über Angiomyomatose der Lungen mit Wabenstruktur. *Virchows Arch. path. Anat.*, 321, 585.
- Brewer, L. A. (1955). Surgical management of lesions of the thoracic duct. *Amer. J. Surg.*, 90, 210.
- Brzek, V., Křen, V., and Bartoš, V. (1965). Retrograde Lymphographie des Ductus thoracicus. *Fortschr. Röntgenstr.*, 102, 125.
- Cornog, J. L., Jr., and Enterline, H. T. (1966). Lymphangiomyoma: a benign lesion of chyliferous lymphatics synonymous with lymphangiopericytoma. *Cancer (Philad.)*, 19, 1909.
- Davies, G. M. (1967). Lymph-casts of the bronchi. *Brit. J. Dis. Chest*, 61, 45.
- Delarue, J., Depierre, R., and Roujeau, J. (1950). Lymphangiectasie pulmonaire et pneumonie chyleuse. *Sem. Hôp. Paris*, 26, 4906.
- Fréour, P., Couraud, L., Germouty, J., Chomy, P., Warin, J. F., Mage, J., and Moukdarath, N. (1966). Sur un chylothorax spontané de l'adulte (Étude lymphographique et angiographique). *J. franç. Méd. Chir. thor.*, 20, 281.
- Godart, S., Collette, J., and Dalem, J. (1964). Pathologie chirurgicale des vaisseaux lymphatiques. *Acta chir. belg.*, 63, Suppl. 1, p. 3.
- Groves, L. K., and Effler, D. B. (1954). Primary chylopericardium. *New Engl. J. Med.*, 250, 520.
- Hudspeth, A. S., and Miller, H. S. (1966). Isolated (primary) chylopericardium. Diagnosis and surgical treatment. *J. thorac. cardiovasc. Surg.*, 51, 528.
- Humbert, P., Zakarian, S., Delmont, J. P., Desranot, Carrier Clérambault, and Picaut, R. (1966). Étude de deux cas de chylothorax spontanés apparemment idiopathiques dont l'un avec entéro-pathie exsudative. *J. franç. Méd. Chir. thorac.*, 20, 357.

- Justin-Besançon, L., Péquignot, H., Galey, J. J., Renault, P., and Even, P. (1963). Lymphangiectasies pulmonaires diffusées acquises avec insuffisance respiratoire et chylothorax. *Sem. Hôp. Paris*, 39, 1179.
- Kinmonth, J. B., and Taylor, G. W. (1954). The lymphatic circulation in lymphedema. *Ann. Surg.*, 139, 129.
- — (1964). Chylous reflux. *Brit. med. J.*, 1, 529.
- Laipply, T. C., and Sherrick, J. C. (1958). Intrathoracic angiomyomatous hyperplasia associated with chronic chylothorax. *Lab. Invest.*, 7, 387.
- Lamotte, M., Mathey, J., Segrestaa, J. M., and Logeais, Y. (1965). Lymphangiectasies pulmonaires diffusées acquises. *Sem. Hôp. Paris*, 41, 2364.
- Lampson, R. S. (1948). Traumatic chylothorax. *J. thorac. Surg.*, 17, 778.
- Liebow, A. A., Loring, W. E., and Felton, W. L. (1953). The musculature of the lungs in chronic pulmonary disease. *Amer. J. Path.*, 29, 885.
- Listerud, M. B., Harkins, H. N., Loe, R. H., Thomas, G. I., and Nyhus, L. M. (1958). Coincident bilateral chylothorax and chylous ascites. *Amer. J. Surg.*, 96, 438.
- Löffler, W., and Jaccard, G. (1954). Über einen Fall von Chyloptoe mit pseudomiliarem Lungenbild. *Schweiz. med. Wschr.*, 84, 1335.
- Madison, W. M., Jr., and Logue, B. (1957). Isolated ("primary") chylopericardium, due to anomalous communications with the thoracic duct, of unknown causation. *Amer. J. Med.*, 22, 825.
- McKendry, J. B. J., Lindsay, W. K., and Gerstein, M. C. (1957). Congenital defects of the lymphatics in infancy. *Pediatrics*, 19, 21.
- Miller, A. J., Pick, R., Kline, I. K., and Katz, L. N. (1964). The susceptibility of dogs with chronic impairment of cardiac lymph flow to staphylococcal valvular endocarditis. *Circulation*, 30, 417.
- Reinhardt, K. (1953). A propos d'un cas de lymphangiectasie pulmonaire. *Radiol. clin. (Basel)*, 22, 162.
- Sztaba, R., and Vondrat, W. (1965). Hémolympangiome thoracique avec chylothorax chez le nouveau-né. *Ann. Chir. infant.*, 6, 21.