

Cryptogenic obliterative bronchiolitis in adults

CW TURTON, G WILLIAMS, M GREEN

From the Brompton Hospital, London

ABSTRACT Patients referred for assessment of severe chronic airflow obstruction over a three-year period were reviewed, and when all smokers and ex-smokers, those with asthma, chronic bronchitis, emphysema, and other specific pulmonary diagnoses were excluded 10 patients remained. Their clinical, lung function, and bronchographic features were consistent with obliterative bronchiolitis. Nine were women, five had rheumatoid arthritis, and five had survived for more than 10 years after first symptoms. Obliterative bronchiolitis has not previously been considered as a cause of chronic airflow obstruction but the distinctive features suggest that it is a true disease entity.

There are several well-recognised causes of chronic airflow obstruction, notably cigarette smoking, asthma, chronic bronchitis, and emphysema. However, some patients do not fit into any of these categories and the nature of their disorder remains mysterious. We set out to define such patients (by exclusion of all other recognised causes of chronic airflow obstruction) to see if they had common characteristics. Ten such patients were identified among those referred for assessment of chronic airflow obstruction over a period of three years. These 10 patients have similarities of clinical history, radiology, and lung function tests which lead us to conclude that they have obliterative bronchiolitis. Recently Geddes *et al*¹ described a rapidly progressive form of obliterative bronchiolitis occurring in six patients with collagen vascular disorders, and eight similar cases have since been described.²⁻⁶ However this condition has not previously been considered as a cause of chronic airflow obstruction in adults,⁷ although it is recognised to occur after infection in children⁸ and in adults,^{9,10} after exposure to toxic fumes^{11,12} and in association with chronic bronchitis and emphysema.¹³

Methods and results

CRITERIA

Patients referred to the Lung Function Unit with chronic airflow obstruction and FEV₁ less than 60% predicted between July 1977 and June 1980 were

reviewed, a total of 2094. All those who had recognised causes of chronic airflow obstruction were excluded as follows.

Asthma

Patients were excluded if there was a history of chest symptoms in childhood, attacks of wheezy breathlessness, allergic rhinitis, eczema, or a positive family history. All patients were given a trial of salbutamol inhalation and were excluded if FEV₁ or FVC increased by more than 15%. Peak expiratory flow (PEF) rates were recorded four times daily for at least one week using a Wright peak flow meter. Patients with PEF variability of more than 50 l/min were considered to have asthma. All patients had a therapeutic trial of prednisolone, 30 mg daily or more for at least two weeks, and improvement in PEF of more than 50 l/min or 20% (whichever was least) after prednisolone was considered to be evidence of asthma.

Chronic bronchitis

All current and ex-smokers were excluded since cigarette smoking has been reported to be associated with chronic airflow obstruction in the absence of mucus hypersecretion.¹⁴ Patients who satisfied the Medical Research Council criteria¹⁵ for chronic bronchitis were also excluded.

Emphysema

Emphysema is defined in pathological terms and so cannot be excluded definitely in life, but patients were excluded if the chest radiograph showed low flat diaphragms and attenuation of peripheral

Address for reprint requests: Dr M Green, Brompton Hospital, Fulham Road, London SW3 6HP.

vascular markings in four of six zones,¹⁶ or if lung function tests showed *both* hyperinflation (total lung capacity, TLC, by plethysmograph greater than 115% predicted) and reduced gas transfer coefficient (Kco less than 85% predicted).

Other causes

Patients with chronic airflow obstruction associated with bronchiectasis, extrinsic airway compression, sarcoidosis, cryptogenic fibrosing alveolitis, eosinophilic granuloma, pulmonary haemosiderosis, re-lapsing polychondritis, tracheobronchial amyloidosis, or any specific pulmonary diagnosis were also excluded.

This rigorous process of exclusion left a group of 10 patients who showed certain clinical, radiological, and lung function similarities which will be described below. We believe these features are compatible with a diagnosis of obliterative bronchiolitis.

CLINICAL FEATURES

Clinical details of the 10 patients are shown in the table. There were nine women and one man, aged from 27 to 67 years at presentation. All were breathless on exertion and had at least moderate limitation of exercise tolerance. Eight patients complained of cough but none expectorated sputum regularly. Four gave a history of wheeze but this was not paroxysmal or episodic and was not associated with changes of peak expiratory flow rate. The duration of symptoms varied from three months to 15 years. One patient died (necropsy not carried out), the others being followed for up to four years. Five patients had suffered from rheumatoid arthritis for between two and 11 years before chest symptoms developed. All these had been treated with non-steroid anti-inflammatory drugs and three had also received penicillamine. The five patients without clinical rheumatoid arthritis had negative rheumatoid factors and anti-nuclear antibodies. Three patients had histories of respiratory infection immediately before the onset of their breathlessness.

None had been exposed to smoke or fumes. The abnormal physical signs noted were auscultation of inspiratory crackles in five patients and a mid-inspiratory squeak in four. Wheeze was not a prominent feature and there were no signs of cardiac failure. One patient (case 7) was atopic. Alpha-1-antitrypsin levels were normal in all.

IMAGING

The plain chest radiographs were reviewed by a specialist in chest radiology. Three patients showed transient local fine linear infiltrations, and three patients had some diffuse attenuation of peripheral vascular shadows, although this was not associated with hyperinflation. Otherwise the films were judged to show no significant abnormalities.

Ventilation-perfusion lung scans (using Krypton 81 and Xenon 133) were performed in five patients. One was normal, while four showed several matched non-segmental defects of both ventilation and perfusion.

Three patients (numbers 3, 5, and 8) underwent bronchography. These were technically satisfactory. In each case they showed obstruction of peripheral airways, reduced branching and no normal alveolar filling pattern. An example is shown in fig 1.

LUNG FUNCTION TESTS

Dynamic lung volumes (FEV₁ and FVC) and maximal expiratory and inspiratory flow-volume loops were recorded using an Ohio spirometer. Total lung capacity and inspiratory airways resistance, Raw, were measured in a body plethysmograph (Fenyves and Gut, Basle, Switzerland). Lung volume accessible to a single inhalation of helium (V_A) and the diffusing capacity for carbon monoxide (DL) were determined using a Respirimeter (PK Morgan, Chatham) and the carbon monoxide coefficient derived.¹⁷ Predicted values were calculated from sex, age, and height.¹⁸ Dynamic lung compliance was measured¹⁸ in five patients (numbers 1, 3, 8, 9, and 10).

Table *Clinical features*

Case number	1	2	3	4	5	6	7	8	9	10
Age at presentation (yr)	67	43	41	60	40	27	27	60	56	55
Sex	F	F	F	M	F	F	F	F	F	F
Duration of symptoms at time of presentation (yr)	0.6	0.5	1.5	2.0	13.0	8.0	0.3	10.0	10.0	15
Duration of follow-up (yr)	1.5*	3.5	2.0	4.0	0.8	2.0	1.0	0.5	4.0	3.5
Associated rheumatoid arthritis (duration in years)	2	2	11	—	—	—	3	10	—	—
Preceding chest infection	—	—	+	+	—	+	—	—	—	—
History of cough	+	+	—	+	+	—	+	+	+	+
History of wheeze	+	—	—	—	+	+	—	—	+	—
Inspiratory squeak auscultated	+	—	+	—	—	—	+	+	—	—
Inspiratory crackles auscultated	—	+	+	+	—	—	+	+	—	—

*Indicates death.

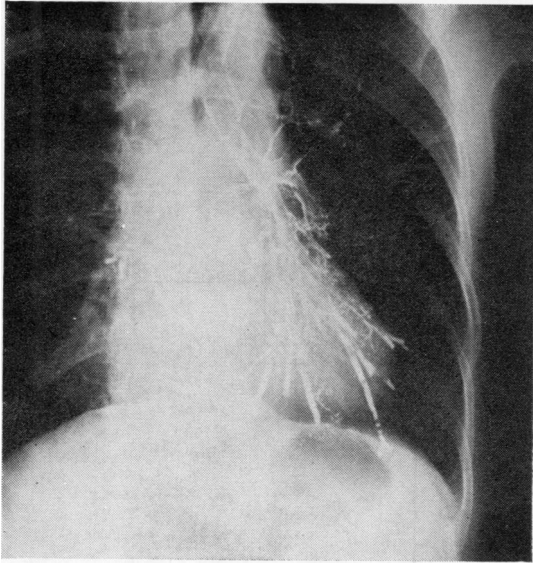


Fig 1 Left-sided bronchogram from case 9. There is marked lack of side branches from subsegmental bronchi and generalised obliteration of airways smaller than 3 mm. The normal alveolar filling pattern is absent.

Figure 2 shows the results of lung function tests. FEV_1 was reduced considerably while FVC was decreased to a lesser degree, and all patients had low $FEV_1/FVC\%$. TLC varied from 70 to 123% predicted but lung volumes by single breath helium dilution were appreciably smaller. Residual volume (RV) was high in all subjects which is reflected by the increased $RV/TLC\%$.

Figure 3 shows the difference between TLC and V_A which has been used as a measure of gas trapping¹⁷ and reflects impaired gas mixing in the lungs. In normal subjects this difference is less than 0.5 litres, but all of the patients with obliterative bronchiolitis had increased trapped gas volumes. Raw was increased in all subjects.

The mean DL was reduced but K_{CO} was not (fig 4). Flow-volume loops showed reduced flows at low lung volumes and severe volume-dependent airflow obstruction¹⁷ in all cases—fig 5 shows a characteristic example. Compliance was no greater than the mean predicted value in any of the five patients in which it was measured, and in two was near the lower limit of the normal range ($0.103 \text{ l.cmH}_2\text{O}^{-1}$ (1.03 l kPa^{-1}) in patient 9 and $0.115 \text{ l.cmH}_2\text{O}^{-1}$ (1.15 l kPa^{-1}) in patient 1).

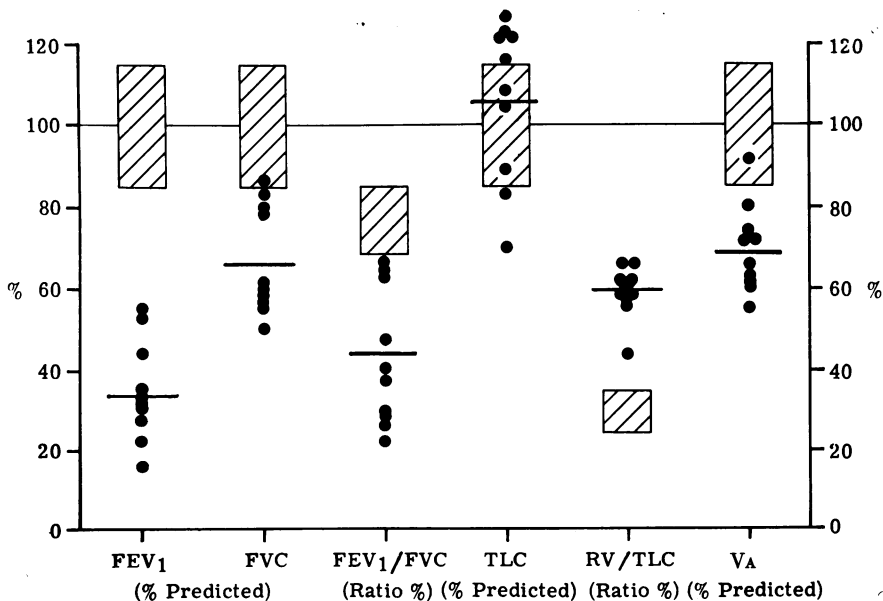


Fig 2 Lung function tests. Values of FEV_1 , FVC, TLC, and V_A are expressed as percentage of predicted values. FEV_1/FVC and RV/TLC are expressed as ratios percent. Bars represent the mean values and hatched areas the predicted normal range.

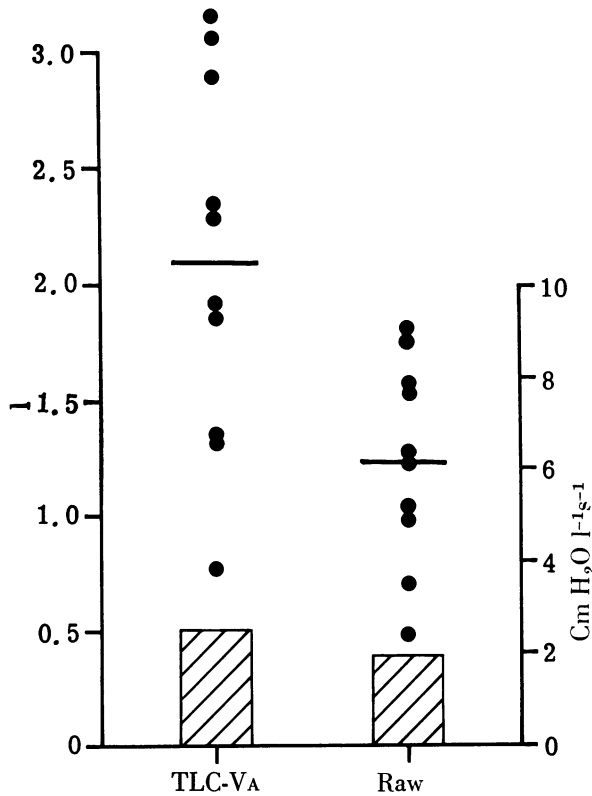


Fig 3 Lung function tests. TLC-Va is expressed in litres and Raw as $\text{cmH}_2\text{O.litres}^{-1}.\text{s}^{-1}$ ($1 \text{ cmH}_2\text{O litre}^{-1}.\text{s}^{-1} = 0.1 \text{ kPa.l}^{-1}.\text{s}$). Bars represent the mean values and hatched areas the predicted normal range.

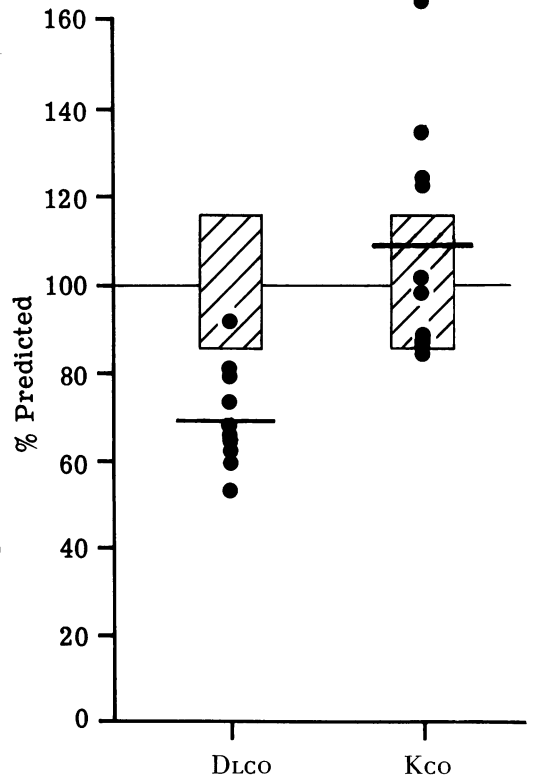


Fig 4 Lung function tests. DLCO and Kco are expressed as percentages of predicted values. Bars represent mean values and hatched areas the predicted normal range.

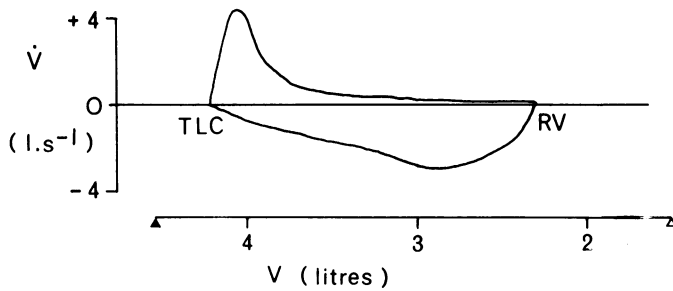


Fig 5 Flow-volume loop from case 2. The shape suggests severe volume dependent airways obstruction. Δ indicates predicted RV and \blacktriangle predicted TL.

Discussion

These 10 patients were identified by a rigorous process of exclusion. We did not attempt to analyse or to characterise in detail the diagnoses of the other patients since we were only concerned to exclude all patients with other possible causes of chronic airflow obstruction. Thus the cigarette smokers with chronic airflow obstruction may have been a heterogeneous group with different causes of airways

obstruction, including perhaps some with obliterative bronchiolitis.

We believe the 10 patients described here have features compatible with a diagnosis of chronic obliterative bronchiolitis on the basis of their histories, lung function tests, and radiology. Open lung biopsy was not felt to be clinically justifiable in view of their chronic illness and breathlessness. This group of patients had very similar features clinically, on lung function, and radiographically,

to those described by Geddes *et al.*¹ However the disease deteriorated rapidly in Geddes' series and thus at necropsy pathological evidence that the underlying defect was indeed obliterative bronchiolitis could be obtained. Our patients presented with breathlessness and some had an unproductive cough. An inspiratory squeak or crackles were auscultated in some but wheeze was not predominant. The chest radiographs were unremarkable. Lung function tests showed an obstructive ventilatory defect with little hyperinflation but considerable gas trapping, which was reflected by a low FVC and DL but normal Kco. The diagnosis was confirmed in some by bronchography which showed changes similar to those reported in obliterative bronchiolitis,^{1 19} and distinct from the abnormalities described in chronic bronchitis and emphysema.²⁰

The pattern of lung function abnormality is of interest, even though confident physiological localisation of airway damage can be difficult. The reduced FEV₁/FVC% and high Raw show that there is an obstructive ventilatory defect, but such changes occur when larger airways are affected. However, the reduced FVC, VA, and DLCO, and increased trapped gas volume suggests either damage to lung parenchyma or occlusion of small airways. The normal Kco shows that gas transfer in the alveoli reached by ventilating gas is normal and the normal TLC and compliance are not consistent with generalised emphysema or fibrosis.²¹ Lung function therefore is consistent with small airway obstruction and occlusion, as well as some flow limitation in larger airways. Since FVC is low but TLC normal we conclude that the air spaces distal to obstructed airways are ventilated by collateral air drift.

The pattern of lung function abnormality differed from a group of smokers who developed a comparable degree of airflow obstruction (matched for Raw) without mucus hypersecretion or emphysema. The latter groups had smaller FVC, lower FEV₁/FVC%, higher VA, lower trapped gas volumes, and lower Kco (unpublished observations). Such functional differences suggest that the pathology might also differ.

The marked reduction of FVC is compatible with the hypothesis that in this group vital capacity reflects the degree of medium and small airways closure.²² Such a mechanism might explain the reduced FVC found in chronic airflow obstruction resulting from other causes, and indeed it may be that in patients with airflow obstruction but normal Kco the FVC is a useful measure of the degree of impairment of smaller airways.

Obliterative bronchiolitis is known to occur as part of the pathological process in other conditions such as chronic bronchitis and asthma. Since these

patients and those of Geddes *et al.*¹ had no evidence of known causative processes, it seems reasonable to distinguish them as a separate disease entity of unknown aetiology. For this reason we suggest the term "cryptogenic" to describe such patients. Both bronchograms in our patients and histology and pathology in those of Geddes *et al.*¹ have shown that the airways are obliterated hence "obliterative". This process seems similar to the obliterative bronchiolitis described in children in whom it usually follows adenovirus infection.⁷ Bronchi smaller than about 3 mm as well as bronchioles appear to be involved but the term obliterative bronchitis would be misleading, and broncho-bronchiolitis cumbersome, so "bronchiolitis" as suggested by Geddes *et al.*¹ is used for convenience and also by analogy with the comparable disorder in children.

Cryptogenic obliterative bronchiolitis is thus another cause of the more general "small airways disease" coined by Hogg *et al.*²³ to emphasise the involvement of peripheral airways in chronic bronchitis, emphysema, and bronchiectasis. The patients described by Macklem *et al.*²⁴ as having chronic obstructive disease of the small airways subsequently turned out to have conditions such as bronchiectasis or emphysema,²⁵ and so most would not have fulfilled our criteria for cryptogenic obliterative bronchiolitis, even though the small airways were involved. In addition to small airway occlusion our cases had some associated irreversible larger airway narrowing. This may suggest that the disease is diffuse, with particular damage to the smaller airways.

The patients described here are similar to those reported by Geddes *et al.*¹ but contrast in two important respects. Firstly, the patients in this series did not follow a fulminating course. Relatively mild cases occurred and five patients have now survived for up to 10 years. Thus the condition can cause chronic disability lasting many years. Although it cannot at present be cured, correct diagnosis may allow its natural history to be studied in more detail and perhaps therapies evolved. Secondly, the disease can occur in patients without clinical or serological evidence of rheumatoid arthritis or other collagen vascular disorders. Patients with cryptogenic obliterative bronchiolitis differ from those with bronchiolitis after infection in children⁸ or exposure to fumes in adults¹² in having minimal radiographic changes and less active histopathology with concentric fibrous narrowing¹ rather than cellular infiltration.

The airflow obstruction of cryptogenic obliterative bronchiolitis is essentially irreversible since, by the defining criteria used, reversibility was diagnosed as asthma. Slight responses to inhaled broncho-

dilators were recorded in some patients and were of a similar order to those seen in patients with chronic obstructive bronchitis or emphysema. Such responses may be associated with a small degree of symptomatic relief, particularly after intercurrent viral infections.

The aetiology of this disease is unknown. Some patients gave a history of respiratory infection immediately before the onset of their symptoms but no particular organism was implicated. Various infections can result in obliterative bronchiolitis in children and perhaps in some adults epithelial damage by viruses can progress to fibrosis, and obliteration instead of the usual resolution.²⁶ This might be liable to occur particularly in subjects with altered host defences, such as in rheumatoid arthritis. Possibly some infectious agents can themselves alter immune responses in predisposed individuals. Recent reports^{3 5 6} have implicated penicillamine treatment but most of the patients in this series had never been treated with this drug, suggesting that other factors may be more important.

Obliterative bronchiolitis is not diagnosed often, perhaps because of the frequent uncritical use of the term "chronic obstructive airways/lung/pulmonary disease". All of these patients had less specific diagnoses made previously by experienced chest physicians. Although the condition appears to be unusual it may be less rare than suggested by the previous literature. Other cases may occur in those with less severe airflow obstruction and among smokers.

The diagnosis of obliterative bronchiolitis has been based on the finding of chronic airflow obstruction in non-smokers in the absence of evidence of asthma, chronic bronchitis, or emphysema. The similarity of the clinical features, the distinctive lung function changes, and the characteristic abnormalities seen on bronchography all suggest that obliterative bronchiolitis is a true disease entity and not a variant of asthma or emphysema. The diagnosis should be considered in adults when irreversible airflow obstruction develops in the absence of another cause.

References

- Geddes DM, Corrin B, Brewerton DA, Davies RJ, Turner-Warwick M. Progressive airway obliteration in adults and its association with rheumatoid disease. *Q J Med* 1977;**46**:427-44.
- Murphy DMF, Fairman RP, Lapp NL, Morgan WKC. Severe airway disease due to inhalation of fumes from cleansing agents. *Chest* 1976;**69**:372-6.
- Epler GR, Snider GL, Gaensler EA, Cathcart ES, Fitzgerald MX, Carrington CB. Bronchiolitis and bronchitis in connective tissue diseases. *JAMA* 1979;**242**:528-23.
- Bates DV. Bronchiolitis: introduction to discussion. In: Sadoul P, Milic-Emili J, Simonsson BG, Clark TJH, eds. *Small airways in health and disease*. Amsterdam: Excerpta Medica, (ICS 485) 1979:97-8.
- Stein HB, Patterson AC, Offer RC, Atkins CJ, Teufel A, Robinson HS. Adverse effects of D-penicillamine in rheumatoid arthritis. *Ann Intern Med* 1980;**92**:24-9.
- Cordier JF, Falconnet M, Moulin J, Brune J, Touraine R. Bronchiolite sévère et polyarthrite rhumatoïde: rôle très probable de la D-pénicillamine dans deux observations. *Lyon Med* 1980;**244**:113-4.
- Wohl MEB, Chernick V. Bronchiolitis. *Am Rev Respir Dis* 1978;**118**:759-81.
- Becroft DMO. Bronchiolitis obliterans, bronchiectasis and other sequelae of adenovirus type 21 infection in young children. *J Clin Pathol* 1971;**24**:72-82.
- Blumgart HL, MacMahon HE. Bronchiolitis fibrosa obliterans: a clinical and pathological study. *Med Clin North Am* 1929;**13**:197-214.
- McAdams AJ. Bronchiolitis obliterans. *Am J Med* 1955;**19**:314-22.
- Lowry T, Schuman LM. Silo-fillers' disease: a syndrome caused by nitrogen dioxide. *JAMA* 1956;**162**:153-60.
- Ramirez J, Dowell AR. Silo-fillers' disease-nitrogen dioxide induced lung injury. *Ann Intern Med* 1971;**74**:569-76.
- Matsuba K, Thurlbeck WM. Disease of the small airways in chronic bronchitis. *Am Rev Respir Dis* 1973;**107**:552-8.
- Fletcher C, Peto R, Tinker C, Speizer FE. The natural history of chronic bronchitis and emphysema. London: Oxford University Press, 1976.
- Medical Research Council. Definition and classification of chronic bronchitis for clinical and epidemiological purposes. *Lancet* 1965;**1**:775-9.
- Thurlbeck WM, Simon G. Radiographic appearance of the chest in emphysema. *Am J R* 1978;**130**:429-40.
- Denison D. Physiology. In: Clark TJH, ed. *The clinical investigation of lung disease*. London: Chapman and Hall, 1981: in press.
- Cotes JE. *Lung function*. Fourth edition. Oxford: Blackwell Scientific Publications, 1979.
- Fraser RG, Pare JAP. *Diagnosis of diseases of the chest*. Vol 3. Second edition. Philadelphia: Saunders, 1979: 1538.
- Reid LM. Correlation of certain bronchographic abnormalities seen in chronic bronchitis with pathological changes. *Thorax* 1955;**10**:199-204.
- Fulmer JD, Roberts WC, Von Gal ER, Crystal RG. Small airways in idiopathic pulmonary fibrosis. *J Clin Invest* 1977;**60**:595-610.
- Green M. The small airways. In: Besser GM, ed. *Advanced medicine*. Vol 13. Tunbridge Wells: Pitman Medical, 1977:278-88.
- Hogg JC, Macklem PT, Thurlbeck WM. Site and nature of airway obstruction in chronic obstructive lung disease. *N Engl J Med* 1968;**278**:1355-60.
- Macklem PT, Thurlbeck WM, Fraser RG. Chronic obstructive disease of small airways. *Ann Intern Med* 1971;**74**:167-77.
- Thurlbeck WM. *Chronic airflow obstruction in lung disease*. Philadelphia: Saunders, 1976:21-2.
- Green M. Bronchiolitis. In: Sadoul P, Milic-Emili J, Simonsson BG, Clark TJH, eds. *Small airways in health and disease*. Amsterdam: Excerpta Medica, (ICS 485) 1979:90-4.