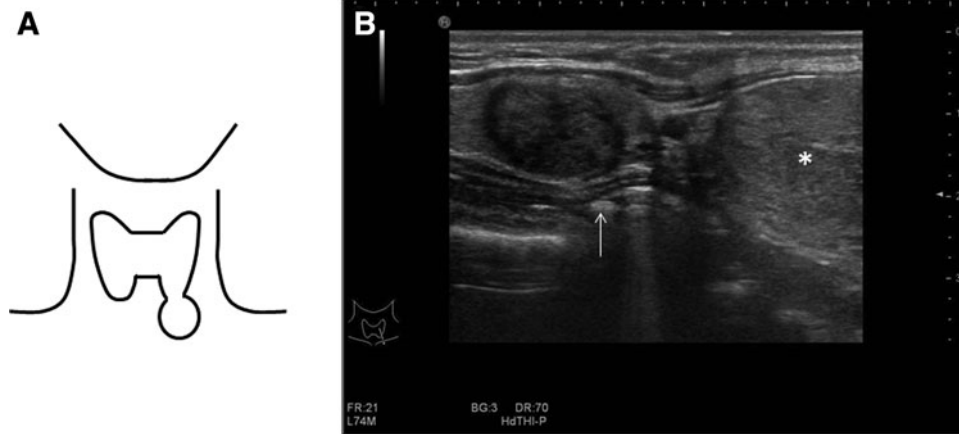


## Supplementary Data



**SUPPLEMENTARY FIG. S1.** (A) Schematic representation of the position of the nodule. (B) Longitudinal B-mode ultrasound (US) image showing the left inferior pole of the thyroid (white arrow) with a small (Thy2) nodule next to a symptomatic (Thy2) nodule attached to it and partly plunging (asterisk).