

Nodular, non-cirrhotic liver associated with portal hypertension in a patient with rheumatoid arthritis

M. HARRIS, R. M. RASH, AND I. W. DYMOCK

From the Department of Pathology, University of Manchester, and the Departments of Geriatric Medicine and Medicine, University Hospital of South Manchester

SYNOPSIS A patient with rheumatoid arthritis developed portal hypertension and died from bleeding oesophageal varices. The liver was small and showed a nodular, non-cirrhotic pattern similar to that described by Blendis *et al* (1970 and 1974) in association with Felty's syndrome. This appears to be the first report of a patient with this liver lesion associated with rheumatoid arthritis in the absence of Felty's syndrome. The liver lesions described here are compared with partial nodular transformation and nodular regenerative hyperplasia; in spite of some differences it is not proven that these are distinct entities and further study is required to settle this question.

In a recent study of the liver changes in Felty's syndrome, abnormalities ranging from lymphocytic infiltration to macronodular cirrhosis were described (Blendis, Ansell, Lloyd Jones, Hamilton, and Williams, 1970). Included in the eight cases where histology was available was one (case 5) in which there was nodularity without fibrosis causing portal hypertension. This abnormality had not been previously described but since then a more detailed account of this patient plus four additional patients, all of whom had Felty's syndrome, has been published (Blendis, Parkinson, Shilkin, and Williams, 1974); three of these five patients had portal hypertension.

In this paper we report a further patient with rheumatoid arthritis whose liver showed a similar nodularity and who also had portal hypertension. This appears to be the first recorded example of this association where the patient did not also have Felty's syndrome.

Case Report

The patient was a woman aged 79 years who had been diagnosed as having rheumatoid arthritis 40 years previously but who had been free from arthritic symptoms for several years.

On 8 March, 1973 she was admitted to hospital with swelling of the abdomen which had first been

noticed one year previously. On examination the positive findings were of massive ascites, ankle and sacral oedema, and gangrene of two finger tips. There was inactive rheumatoid arthritis of the hands and wrists; skin nodules were absent. At no time was the liver palpable and there was no lymph node enlargement.

The ascites was tapped to relieve abdominal discomfort, and 3 litres of clear, pale yellow fluid removed. On 11 March 1973 coffee ground vomiting occurred and on 5 April an EEG was reported as being abnormal and compatible with a metabolic encephalopathy.

The ascites recurred despite diuretic therapy and was tapped on several further occasions. Foetor hepaticus was noted on 18 May and although therapy for liver failure was given there was steady deterioration, death occurring on 1 June following several episodes of melaena. The clinical diagnosis was hepatic cirrhosis with portal hypertension and bleeding from oesophageal varices.

INVESTIGATIONS

Haemoglobin: 9.5 g/dl (red cells hypochromic); white cell counts: 7.2×10^9 and 8.9×10^9 per l; platelets: 155×10^9 and 126×10^9 per l; ESR: 10 mm in first hour.

Serum bilirubin: 14 $\mu\text{mol/l}$ rising to 34 $\mu\text{mol/l}$; alkaline phosphatase: 440 KA units per l falling to 190; LDH and SGOT normal.

Received for publication 10 September 1974.

Plasma NH_3 (on 19 March): 168 μ mol/l (normal 13-34); serum albumin 26 g/l, serum globulin 32 g/l.

Prothrombin activity 45%; factor V 70%, factor VII 90%, factor X 70%.

LE cells ($\times 3$) negative; antinuclear factor positive; smooth muscle antibodies negative; mitochondrial antibodies: negative.

SCAT negative; F II latex test positive (titre > 1 in 640).

Hepatitis B antigen negative. Liver scan compatible with cirrhosis and portal hypertension. Needle biopsy of liver (taken after death) no diagnostic features.

Necropsy

The finger joints showed rheumatoid deformities and a section through a metacarpo-phalangeal joint showed replacement of the articular cartilage by fibrous pannus and minimal chronic inflammatory cell infiltration.

The liver was very small, weighing 592 g. The

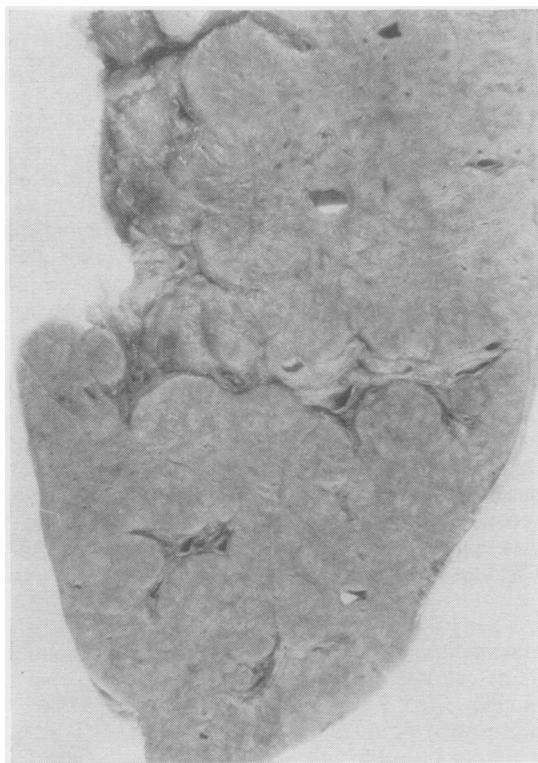

Fig 1 The cut surface of the liver after fixation showing variably sized, ill defined nodules.

capsule was slightly thickened and opaque, the outer surface of the liver having an ill defined nodular pattern. On the cut surface this ill defined nodularity was also apparent, the nodules measuring up to 1.3 cm diameter and lacking any definite fibrous boundaries; they were most obvious beside large portal septa but were also present throughout the parenchyma (fig 1). The gallbladder, bile ducts, pancreas, and portal and hepatic veins were normal.

Evidence of portal hypertension was present, there being ascites (600 ml of serous fluid), slight congestive splenomegaly (spleen weight 191 g), and varices with mucosal ulceration in the lower oesophagus. The stomach, small intestine, and colon were filled with altered blood.

In the cardiovascular system there were changes which may have been associated with the rheumatoid process. These were organizing fibrinous pericarditis; two small non-bacterial vegetations on the tricuspid valve; obliterative endarteritis of the digital arteries associated with gangrene of the finger tips (as described in rheumatoid disease by Bywaters, 1957).

No other abnormalities were noted in the cardiovascular system or elsewhere.

Histology of the Liver (Figs 2 and 3)

Many sections were examined using haematoxylin and eosin, Masson's trichrome, van Gieson and reticulin stains, and all showed a basically similar pattern. The nodularity was finer than the macroscopic appearances had suggested and was due to changes in the texture and arrangement of the liver cell plates. Within the nodules the liver cells were relatively large with pale staining cytoplasm and were arranged in broad, closely packed trabeculae separated by narrow sinusoids. At the periphery of the nodules the liver cells appeared atrophic, and their cytoplasm was more eosinophilic; they were arranged in narrow trabeculae separated by relatively wide sinusoids, sometimes appearing to pass circumferentially around the nodules. In some areas small portal tracts occupied the centres of the nodules producing the pattern of reversed lobulation but this was not present in all regions. Some portal tracts showed fibrosis; this was variable in degree and although in places it was marked and tended to accentuate the nodularity, in general the lobular architecture was readily discernible and connective tissue stains did not demonstrate fine or coarse fibrous septa at the periphery of the parenchymal nodules. There was thus no evidence of a true cirrhosis. Some portal tracts showed moderate lymphocytic infiltration. Scattered areas of recent parenchymal cell necrosis were present which were thought to be attributable to terminal shock.

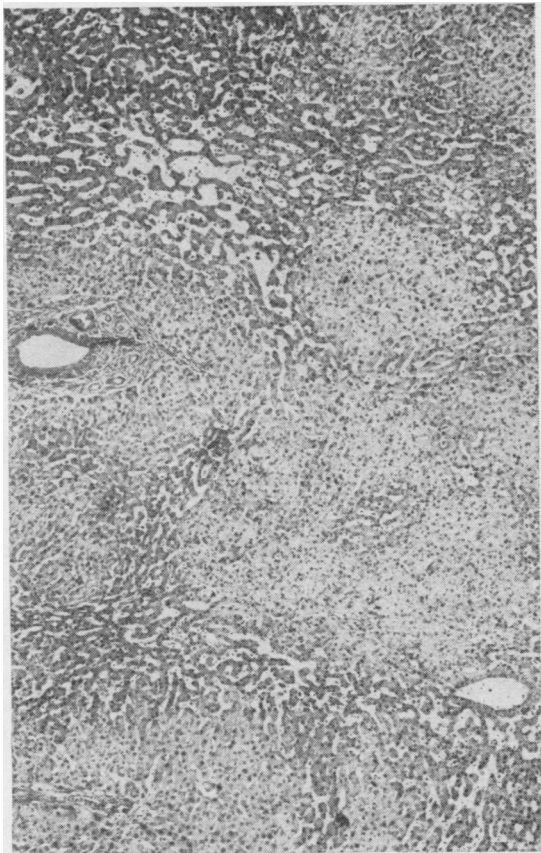


Fig 2 Several nodules of compactly arranged pale staining liver cells are bounded by darker stained trabeculae separated by dilated sinusoids. Masson's trichrome (MT) $\times 55$.

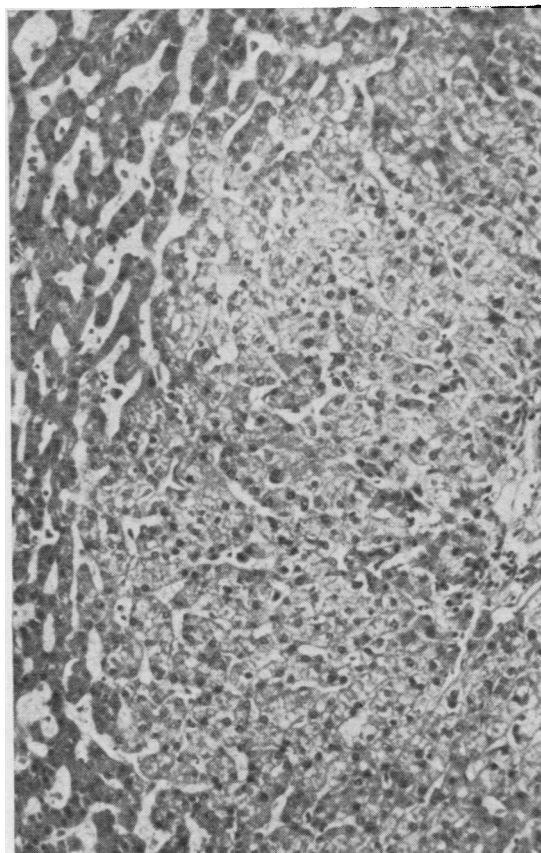


Fig 3 The edge of a nodule showing pale staining cells within the nodule (right) and circumferentially arranged trabeculae at its periphery (left). Note the absence of a fibrous septum from the edge of the nodule. MT $\times 150$.

Discussion

The histological features found in this patient's liver resemble those observed in the five patients described by Blendis *et al* (1974), although the size of the liver appears to be different. Blendis *et al* (1974) stated that the livers in all of their cases were clinically enlarged (necropsy weights were not quoted) whereas in the present case the liver weight was greatly reduced. Clinically, the main differences are the inactivity of the rheumatoid process and the absence of Felty's syndrome in the present patient. The latter is of particular interest because in all five previously reported cases there was an association with Felty's syndrome, and, although Blendis *et al* stated that a causal relationship was not proven, it was considered that the conditions were 'truly related' because no examples of the liver lesion

could be found in necropsy series of 51 cases of rheumatoid arthritis, 21 cases with other connective tissue disorders, 14 cases with splenomegaly from blood dyscrasia or lymphoma, nor in 100 consecutive necropsies at one hospital. The case reported here suggests that the association may be with the rheumatoid process rather than exclusively with Felty's syndrome, although on the evidence of the six examples so far described it appears to be more common in Felty's syndrome.

However, the extreme rarity of the association raises the further question as to whether the liver changes really do constitute part of the spectrum of rheumatoid disease (with or without Felty's syndrome), or whether the liver lesions are a rare independent entity fortuitously associated with rheumatoid disease in the patients so far described. In this connexion, it is relevant to examine des-

criptions of other conditions of the liver in which there is nodularity without cirrhosis to try to determine if other cases having similar liver pathology occur independently of rheumatoid disease. Two conditions appear to merit consideration, namely, nodular regenerative hyperplasia (Steiner, 1959) and partial nodular transformation (Sherlock, Feldman, Moran, and Scheuer, 1966).

In nodular regenerative hyperplasia the histological changes in the liver appear to be similar to those under consideration here, although in the four cases reported in Steiner's paper where weights were given they ranged from 1300 to 1720 g, a sharp contrast with the very small liver in the present instance. Steiner considered the lesions to represent a regenerative phenomenon associated with parenchymal damage from various causes, the commonest being passive hyperaemia. No reason for chronic hepatic congestion was present either in the patient described here (the tricuspid valve vegetation was trivial and the cusps themselves normal) nor, apparently, in the cases reported by Blendis *et al.* Steiner does not mention rheumatoid arthritis in his paper nor does he describe the occurrence of portal hypertension in his patients.

On the other hand, portal hypertension was present in all four cases of partial nodular transformation described by Sherlock *et al.* However, none of these patients had rheumatoid disease and the liver pathology differed from the cases under consideration here in that the nodules were not uniformly distributed throughout the liver, tending to be found mainly around hilar tissue. The weights of the livers in three of Sherlock's cases were 1200, 1200, and 1400 g.

Thus, there appear to be some grounds for regarding these three described varieties of nodular, non-cirrhotic liver disease as distinct entities but the evidence is far from conclusive and the question must remain open until further examples of these types of liver disease are described and their association with rheumatoid disease (with or without

Felty's syndrome) and portal hypertension clarified statistically. However, Blendis *et al.* (1974) appear to accept that the liver lesion in their patients is best classified as nodular regenerative hyperplasia.

It is noteworthy that a precise anatomical diagnosis of the liver condition may be impossible to establish even when a needle biopsy is performed. The liver biopsy in our patient was unhelpful and this was also so in two of the three cases of Blendis *et al.* (1974) where needle biopsy was performed. Furthermore Scheuer (1973) comments that needle biopsy is unlikely to demonstrate the diagnostic features of partial nodular transformation. The reason for this is probably that large areas of liver tissue are necessary to appreciate the altering pattern of the parenchymal cells which defines the nodules, and such a sample is only likely to be obtained at open wedge biopsy or necropsy.

The mechanism whereby the nodules form in any of these conditions is far from clear, although the possibility that disordered regeneration as postulated by Steiner in nodular regenerative hyperplasia might play a part in all three conditions cannot be ruled out.

We are indebted to Dr P. J. Scheuer for his comments on the liver sections and to Dr E. Freeman for access to the clinical records. The photomicrographs were taken by Mr G. Humberstone.

References

- Blendis, L. M., Ansell, I. D., Lloyd Jones, K., Hamilton, E., and Williams, R. (1970). Liver in Felty's syndrome. *Brit. med. J.*, **1**, 131-135.
- Blendis, L. M., Parkinson, M. C., Shilkin, K. B., and Williams, R. (1974). Nodular regenerative hyperplasia of the liver in Felty's syndrome. *Quart. J. Med.*, n.s., **43**, 25-32.
- Bywaters, E. G. L. (1957). Peripheral vascular obstruction in rheumatoid arthritis and its relationship to other vascular lesions. *Ann. rheum. Dis.*, **16**, 84-103.
- Scheuer, P. J. (1973). *Liver Biopsy Interpretation*, 2nd ed., p. 87. Baillière, London.
- Sherlock, S., Feldman, C. A., Moran, B., and Scheuer, P. J. (1966). Partial nodular transformation of the liver with portal hypertension. *Amer. J. Med.*, **40**, 195-203.
- Steiner, P. E. (1959). Nodular regenerative hyperplasia of the liver. *Amer. J. Path.*, **35**, 943-953.