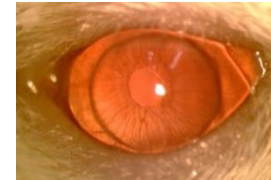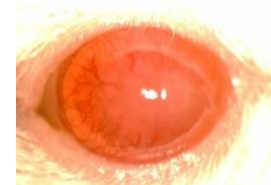


SDC, Figure 1

0	Clear
1	Minimal superficial opacity: pupil margin and iris vessels readily visible through the cornea
2	Minimal stromal opacity: pupil margin and iris vessels visible
3	Moderate stromal opacity: only pupil margin visible
4	Intense stromal opacity: only a portion of pupil margin visible
5	Maximum stromal opacity: anterior chamber not visible



Accepted



Rejected

SDC Fig 1- Transplants were examined weekly with a slit-lamp microscope and grafts with opacity scores >2 after two weeks, which remained above 2 for at least two consecutive weeks, were considered as rejected.