

The pathology of idiopathic retroperitoneal fibrosis

M. J. MITCHINSON

From the Department of Pathology, Tennis Court Road, Cambridge

SYNOPSIS The salient pathological findings in 40 patients with idiopathic retroperitoneal fibrosis are summarized. The findings tend to confirm previous suggestions that this chronic inflammatory disease is potentially widespread, predominantly peri-aortic, associated with systemic disturbances, and of some fundamental interest. The name 'systemic idiopathic fibrosis' is suggested for the disease complex. The study suggests that damage to the wall of the aorta and its large branches might be the cause.

Idiopathic retroperitoneal fibrosis is a well known but uncommon cause of ureteric obstruction (Webb and Dawson-Edwards, 1967; Saxton, Kilpatrick, Kinder, Lessof, McHardy-Young, and Wardle, 1969). Although a small proportion of cases appear to be due to methysergide ingestion (Graham, 1967) the cause of the majority is unknown. Because descriptions of the morbid anatomy and histology are still incomplete a series of 40 patients was studied, with particular attention to the pathology (Mitchinson, 1969a). The clinical observations are summarized elsewhere (Mitchinson, 1970).

Source of Material

The 40 cases were collected by canvassing numerous hospitals, mainly in Britain, for unpublished examples of fibrosis of unknown cause in the lower abdomen (see Table). Several patients were excluded from the series because it appeared that neoplasm, irradiation, or endometriosis was the cause of the fibrosis. One patient was excluded because the fibrosis appeared to be methysergide-induced.

In all 40 cases, histological sections of biopsy specimens were examined by the author; sections of seven nephrectomy specimens were also examined. Fourteen of the patients have died;

all but two were the subject of necropsy. One of the necropsies was performed by the author. In the other 11 cases necropsy reports and histological sections were examined; most necropsies also provided photographs or gross specimens. The following summary of the pathology is based on the above data and on descriptions made at surgery.

Pathological Findings

The fibrosis appeared to encircle the lower abdominal aorta in all necropsy cases (Fig. 1); extension below the pelvic brim was unusual, although a tongue of fibrosis between sacrum and rectum was seen in two cases. At the bifurcation the fibrosis appeared to follow the course of the common iliac vessels, often surrounding them completely. This impression was supported by operation notes on some other patients. At least one necropsy showed clearly that the aorta was completely surrounded, the vena cava incompletely so (see also Lund and Pedersen, 1960; Nezelof, Watchi, Xerri, Auvert, and Couvelaire, 1967).

There was relatively little lateral extension of the fibrosis. It is important to note that the fibrosis draws the ureters towards the aorta; it does not extend laterally to involve them. Many published pyelograms demonstrate this

adequately, but more impressive are surgical notes such as those of Harrow and Sloane (1962) who described a right ureter fixed in the groove between inferior vena cava and aorta. This is another suggestion that the periaortic tissues are the source of the disease. The appearances suggest that the anatomy of the early stages of the disease is as shown in Figures 2 and 3.

Both ureters were indrawn by fibrosis in 10 necropsies (Fig. 4); in one, probably an early case (10), only one ureter was involved; the other necropsy (20) showed no ureteric involvement.

Superiorly, the extent of fibrosis was variable; usually it did not extend as far as the renal

arteries. Three necropsies, however, showed periaortic fibrosis in the thorax, and evidence of this was also present in at least one of the living patients. In one necropsy (6) the whole aorta, from origin to bifurcation, was surrounded. When the fibrosis strayed from the aortic axis it was usually in physical continuity with the periaortic lesion and usually surrounded a major aortic branch, eg, the coeliac axis.

Forward extension into the small bowel mesentery (Clouse, 1964; Chew, Jarzylo, and Valberg, 1966; Webb and Dawson-Edwards, 1967) was seen only once (18) in this series, but displacement of the duodenum was seen in three necrop-

Case No.	Age/Sex	Necropsy Performed	Site of Fibrosis Other than Lower Abdomen	Other Disease ¹	Follow-up Period (years)
1	71F	N	Mediastinum & upper abdomen (periaortic)	Polyarthritis, polyneuropathy, right common iliac artery thrombosis, right femoral vein thrombosis	3/12
2	54M	—	—	Psoriasis	5
3	45M	—	—	Diabetes mellitus	10
4	54M	N	—	Secondary hyperparathyroidism	6
5	53M	—	—	—	6
6	64M	N	Mediastinum & upper abdomen (periaortic); around a coronary artery	—	1/12
7	42M	—	—	'Migraine'—no specific therapy, adrenal cortical insufficiency	11
8	50M	—	—	'Epididymoorchitis', left femoral vein thrombosis, vasomotor headaches	11
9	59M	—	—	Possible healed diverticulitis	4
10	64M	N	—	Undescended left testis, death due to thrombosis of inflamed coronary artery	1/12
11	55M	—	—	—	14
12	43M	N	Upper abdomen (periaortic)	Joint pains, amyloidosis, orchitis	3
13	36M	—	—	Thrombophlebitis of leg	5
14	64M	N	—	Small carcinoma of prostate at necropsy	12
15	47M	—	—	Right common iliac vein thrombosis	2
16	42F	—	Riedel's thyroiditis	Keloid scar	5
17	71M	—	—	Paget's disease of bone	2
18	69M	—	Mesentery	Leg vein thrombosis, benign prostatic hyperplasia, died of 'myocardial infarct'	3
19	47M	—	—	—	2
20	41F	N	Mediastinum	—	1/12
21	51M	N	—	Duodenal ulcer, thrombosis of right femoral vein, pulmonary emboli	9
22	53F	N	Upper abdomen (paraortic)	Splenic vein thrombosis	8/12
23	83M	N	—	—	1/52
24	68M	—	—	'Epididymitis'	6
25	73M	—	—	—	6/12
26	40M	—	—	—	6
27	39M	—	—	Leiomyoma of scrotum, migraine	2
28	43M	—	—	—	4
29	55F	N	—	—	5
30	77M	—	—	Died of postoperative pneumonia	1/12
31	37M	—	—	Coronary insufficiency	5
32	52M	—	—	—	7
33	64F	—	—	—	2
34	17M	—	—	—	2
35	26M	—	—	—	4
36	66M	—	—	—	8/12
37	54F	—	—	—	2/12
38	53F	—	—	—	1
39	50F	N	—	—	3/12
40	51F	—	Probably 'Riedel's thyroiditis'; mediastinum	Thrombophlebitis of legs, polyarthritis of rheumatoid type, leg ulcers	3

Table Summary of cases forming the basis of the present study

¹Hydronephrosis, mild chronic pyelonephritis, renal hypertension and its sequelae, and iatrogenic disease were all common in this series. They are not included in the table, but are discussed elsewhere (Mitchinson, 1970), together with other secondary manifestations of the disease.

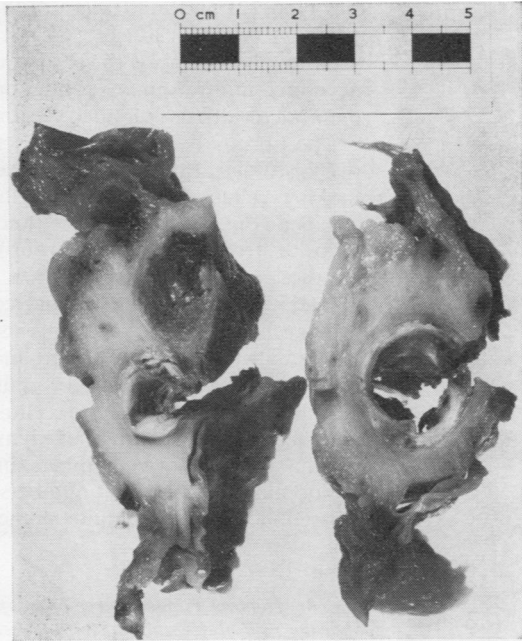


Fig. 1 *Transverse sections across lower abdominal aorta (right picture) and proximal parts of common iliac vessels (left picture) from a necropsy specimen. The lateral extent of fibrosis, the incidental involvement of the vena cava at the edge of the fibrosis, and a left common iliac artery thrombosis can be seen.*

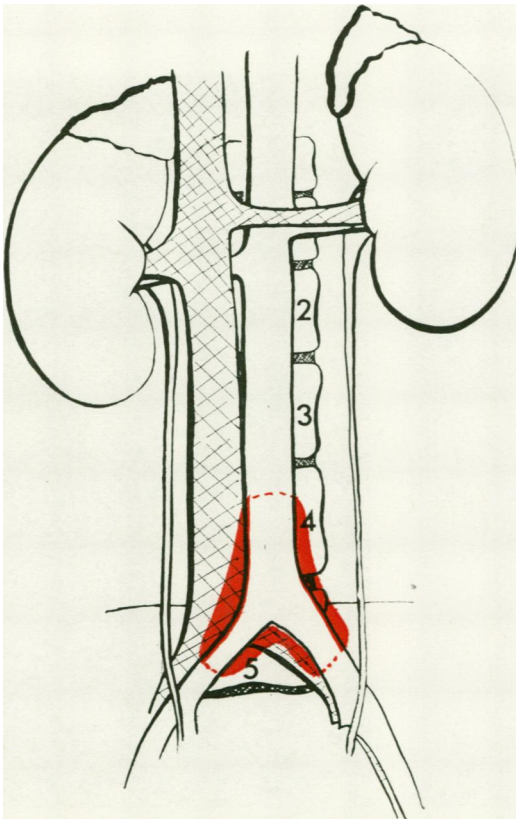


Fig. 2 *Distribution of inflammation and fibrosis in early stages.*

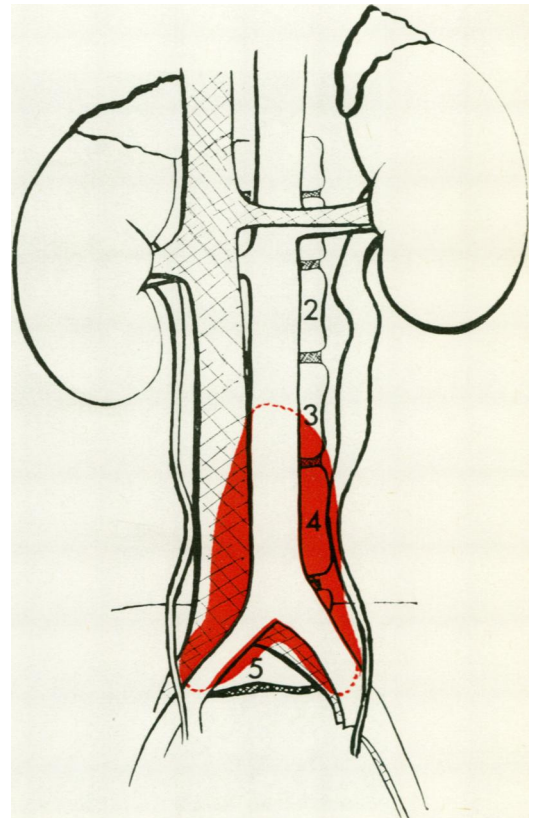
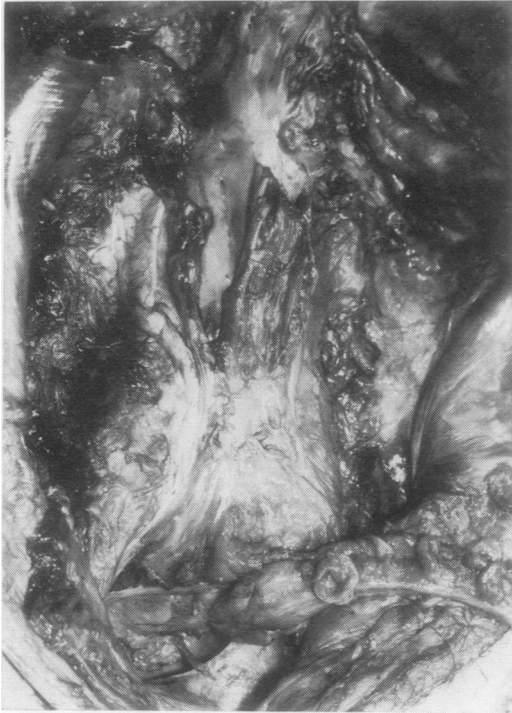

Fig. 3 *Distribution of inflammation and fibrosis in a typical stage of clinical presentation.*



sies (1, 6, 12) and infiltration of the pelvic mesocolon in two (12, 20). It was not clear whether such involvement was due to paraarterial spread or direct infiltration of contiguous tissue; intimate descriptions of such lesions are sparse.

The fibrous tissue in all cases showed one of two histological patterns. In 11 cases it was old-looking, relatively avascular, acellular, and often calcified (Fig. 5); in all others (and in two earlier biopsies from the above group) the collagen bundles were interspersed with an equal or greater volume of inflammatory cells and mucopolysaccharide (Fig. 6). In this more active type small blood vessels were more numerous, but much fewer than seen in granulation tissue. The infiltrate in the more cellular group was pleomorphic, consisting of lymphocytes and plasma cells in large numbers in all 23 cases, eosinophils (in smaller numbers) in 15, and Russell bodies, often quite numerous, in nine.

Fig. 4 Necropsy appearances of a typical case, showing medial deviation of both ureters towards the aortic bifurcation. The vena cava has been partly opened. The right ureter has been partly dissected from surrounding tissue.

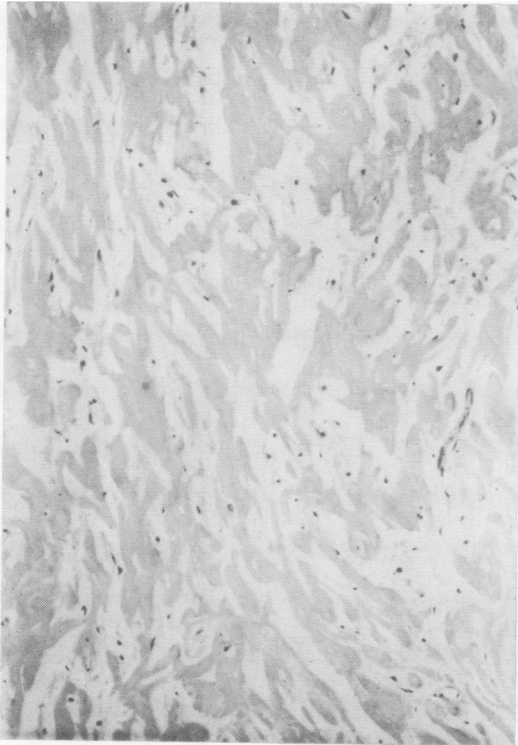

Fig. 5 Fibrous tissue of 'older' appearance (haematoxylin and eosin, $\times 125$), as seen in 11 cases.

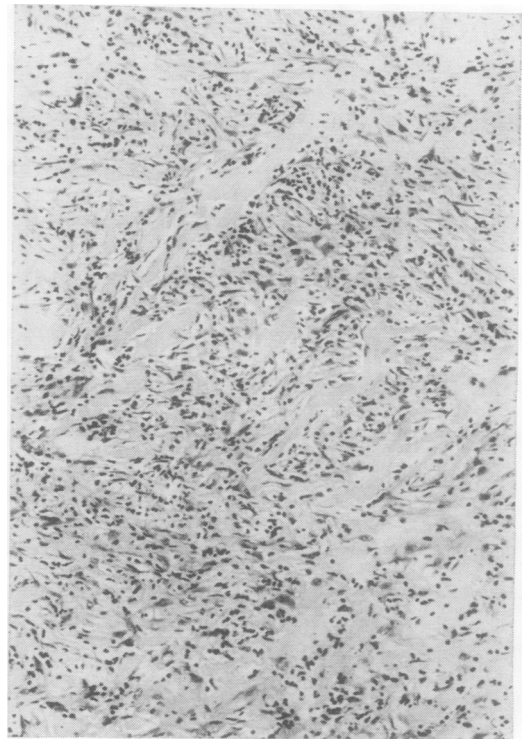


Fig. 6 Inflammatory and fibrous tissue of 'active' appearance (H & E, $\times 125$), as seen in 23 cases.

Most cases showed an admixture of moderate numbers of large elongated mononuclear cells of uncertain type (possibly fibroblasts) and small numbers of mast cells. Frozen sections in two cases showed abundant sudanophil lipid in macrophages. Neutrophil leucocytes were absent. The appearances of serial biopsies in two patients (16, 29) suggested that the more active type of inflammation matured spontaneously or after steroid therapy into the 'older' type. Small veins within the fibrous tissue were invaded by inflammatory cells, or partly or completely obliterated by fibrosis in at least 15 cases.

In adipose tissue just outside the fibrotic area there were frequently small collections of lymphocytes, but no evidence of necrosis, vasculitis, or lymphatic blockage. Adipose cells appeared to break down only after being encircled by collagen.

Adjacent skeletal muscle was commonly invaded by the chronic inflammatory and fibrotic process. Large veins (including vena cava) were invaded and often showed fibrous intimal thickening which occasionally led to complete occlusion. Venous changes were not seen outside the fibrotic mass, suggesting they were secondary to the periaortic lesion rather than its cause.

The normal wide muscular lymphatics of the periaortic region had apparently been obliterated

by the fibrosis, but immediately lateral to (and in one case, above) the fibrosis they were normal.

Sections of aorta were few; they showed severe abdominal atherosclerosis, often with protrusion of atherosclerotic debris through attenuated media into the fibrotic adventitia. Only four thoracic aortas had been sectioned; all but one showed severe intimal fibrous thickening and some infiltration, in the intima and around the vasa vasorum of the adventitia and outer media, by plasma cells and lymphocytes (6, 21, 22). In the aorta most extensively surrounded by fibrosis (6) this infiltrate was dense (Fig. 7); here and in case 21 it was accompanied by Russell bodies. It is important to note that in case 21 there was no periaortic fibrosis at this level; this suggests that the aortitis might precede the adventitial fibrosis. It is therefore advisable in future necropsies to section the aorta at many levels to examine this phenomenon further.

Small arteries were usually normal but in a few cases they were inflamed.

1 ACUTE INFLAMMATION

Case 31 showed polyarteritis nodosa-like lesions in biopsies of retroperitoneal tissue; case 22 showed at necropsy widespread acute vasculitis resembling anaphylactoid purpura.

2 CHRONIC INFLAMMATION

Three patients (10, 16, 22) showed, either at nephrectomy or necropsy, medium-sized arteries with active chronic panarteritis. The intima was thickened by young fibromuscular tissue, and a mainly lymphocytic and histiocytic infiltrate was maximal in the outer intima and junction of media and adventitia.

3 DIFFUSE THICKENING

The medium-sized arteries of five patients showed conspicuous diffuse thickening of the intima by fibromuscular connective tissue resembling that seen in type 2 above, but lacking the inflammatory cells.

Medium-sized arteries are not usually included in retroperitoneal biopsies, so changes described above as types 2 and 3 could only be seen at necropsy or nephrectomy. The three types of arterial changes approximate to the range of appearances seen in connective tissue diseases such as rheumatoid arthritis (Gardner, 1965).

Acute arteritis found at biopsy may be a secondary phenomenon; type 3 may be no more than a variant of endarteritis obliterans but type 2 is unusual and may be of significance in the aetiology.

Sections of ureter at the level of involvement showed oedema and mainly lymphocytic infiltration of the submucosa. A few also showed some fibrosis in the muscularis, but none gave the



Fig. 7 Thoracic aorta in combined retroperitoneal and mediastinal fibrosis (H & E, $\times 125$). The inflamed media is shown above, the fibrotic intima below.

impression of direct invasion by the fibrotic process, and none were mechanically blocked by fibrous tissue. This may explain why corticosteroids may rapidly relieve the recently 'blocked' ureter.

Ten necropsies showed essentially normal thyroid. Two biopsies of thyroid in patients with goitre showed inflammation and fibrosis very similar to that seen in the retroperitoneal tissues. One of these (16) was surgically and pathologically 'Riedel's thyroiditis', with involvement of nearby muscles. The other (40) was apparently an early stage of the same disease, without obvious muscle infiltration. Both showed dense infiltrates of lymphocytes and plasma cells, large numbers of Russell bodies, and venous obliteration, as seen in the periaortic tissues.

The heart showed changes attributable to uraemia, hypertension, or coronary atherosclerosis. Only in case 10 was there definite evidence of coronary arteritis.

Skeletal muscles were not abnormal except for occasional invasion of psoas by the fibrosis and, in case 1, unexplained peripheral neuropathy leading to muscular atrophy.

Testicular atrophy and fibrosis were noted in two necropsies; hydrocoeles were found in three. Probably insufficient attention has been paid to the testis, as several patients were said to suffer from 'epididymoorchitis' at some stage of their illness. Whether this phenomenon is due to interference with blood supply is not yet known, but is likely.

Relevant renal disease was restricted to the sequelae of hydronephrosis and varying degrees of chronic pyelonephritis and four cases of minor nephrocalcinosis.

Lymph nodes and nerves were encircled by fibrosis, but not invaded.

Suprarenals, in all three cases where they were examined histologically, showed tiny foci of lymphocytic infiltration in the cortex.

No significant abnormalities were found in bowel, female genital organs, liver, lymph nodes, lungs, brain, prostate, pancreas, bladder, skin, or other organs.

Aetiology

There was no supporting evidence for the cause being colonic disease (Chisholm, Hutch, and Bolomey, 1954), lymphoma (Kendall and Lakey, 1961), or sarcoidosis (Ullmann and Dacso, 1968). Nerves and joints in the region of the fibrosis have been inadequately examined; there is no evidence at present to suggest that they might be the source of the disease.

LEAKAGE OF URINE (HINMAN, 1960)

When normal urinary outflow is obstructed

urine leaks through forniceal ruptures (Stapor, 1967). This leads to a characteristic inflammatory condition called 'peripelvic urine granuloma' (Hamperl and Dallenbach, 1957) which may cause perirenal and upper periureteric fibrosis (Ohlsen, 1965). Peripelvic urine granuloma was seen in five cases in the present series; two had nephrostomies, but in three it was almost certainly the result of the ureteric obstruction. It may be held responsible for secondary fibrosis around the kidney, but cannot explain the typical periaortic distribution of idiopathic retroperitoneal fibrosis, still less its distant manifestations (Mitchinson and Bird, 1970).

TRAUMA (MACLEAN, 1954)

Relative lack of haemosiderin, and the constant origin and mode of spread of the disease have ruled out this suggestion.

INFECTION (MILLER, LIPIN, MEISEL, AND LONG, 1952; AND OTHERS)

This suggestion stems from the misapprehension that urinary infection frequently precedes this disease. The present series showed that infection usually only followed surgical interference.

Infection of the gonad spreading via gonadal veins or lymphatics (Shaheen and Johnston, 1959) is a possible cause of a few reported cases where fibrosis is maximal in the true pelvis but is an unlikely cause of typical idiopathic retroperitoneal fibrosis.

Microbiological and histological examination have so far failed to demonstrate infection by bacteria, viruses, protozoa, or fungi.

LYMPHATIC OBSTRUCTION (MATHISEN AND HOLTA, 1966)

The broad muscular lymphatics of the para-aortic region are often obliterated in this disease by the inflammation and fibrosis, but lymphatic obstruction is a most unlikely cause. The progression is upwards rather than downwards, and occasionally departs from the lymphatic axis (eg, to the aortic valve ring). Occasional patients have normal lymphangiograms. A few necropsies in this series have demonstrated normal lymphatics and lymph nodes just lateral to or just above the fibrosis. Nevertheless lymph nodes and lymphatics (especially just above the fibrosis) merit more pathological attention than they have received.

VITAMIN E DEFICIENCY

Vitamin E-deficient animals sometimes develop inflammation and fibrosis of the retroperitoneal adipose tissue (Jones, Gresham, Lloyd, and Howard, 1965). Serum vitamin E levels in six of the present series were within normal limits.

VENOUS OBSTRUCTION

This was seen only within the fibrotic areas, and was apparently secondary to the inflammation nearby.

ADIPOSE TISSUE INFLAMMATION

(COPPRIDGE, ROBERTS, AND HUGHES, 1955; MITCHINSON, 1965)

Rare inflammatory diseases of adipose tissue such as systemic Weber-Christian disease show a similar anatomical distribution but adipose tissue necrosis was not a feature of the cases in the present series, and on histological grounds (mode of progression, content of inflammatory infiltrate) can now be discarded as a possible cause.

TOXOPLASMOSIS

Random toxoplasma dye test titres on 13 of the patients showed a slightly increased incidence of positive titres (Mitchinson, 1969b). There was no histological evidence to suggest toxoplasmosis, but it is perhaps worthwhile repeating the toxoplasma dye test in subsequent patients.

LEAKAGE OF BLOOD FROM THE AORTA

(HACKETT, 1958; AND OTHERS)

Leaking aortic aneurysms may cause fibrosis which occasionally blocks the ureters (Goodwin, Fonkalsrud, Goldman, Kaufman, Martin, Riley, Roe, Schapiro, and Wilkerson, 1966); the lack of haemosiderin in most sections precludes this as a cause of idiopathic retroperitoneal fibrosis. However, medial aortic damage was often severe in the present series, and atheromatous material protruded into the adventitia in some cases. Some of the lipids in atherosclerotic plaques are undoubtedly fibrogenic (Abdulla, Adams, and Morgan, 1967), but the frequency of such adventitial protrusions in patients with no periaortic fibrosis probably excludes this as a simple cause. It would also be difficult to explain the characteristic inflammatory response on this basis alone. The cell population suggests an allergic phenomenon—perhaps an allergen from the intima, eg, a lipoprotein, might be escaping through the damaged media.

The early localization of the periaortic fibrosis to the most severely atherosclerotic region of the aorta is possibly coincidence, but suggests that the above mechanism demands further investigation.

CONNECTIVE TISSUE DISEASE (PUGH, 1960; AND OTHERS)

The disease is inflammatory, affects mainly connective tissue, is accompanied by disturbance of plasma proteins and occasionally by arteritis or arthritis of 'rheumatoid' type; it is corticosteroid sensitive. The similarities to the 'connec-

tive tissue diseases' are striking, but so far lack confirmation using conventional methods. It is, however, noteworthy that some connective tissue diseases may lead to aortitis.

At present this suggestion appears to be one of the most compelling, but until others have been completely excluded it is important to remember that this 'merely links to a group of conditions of obscure aetiology yet another equally obscure' (Kay, 1963).

METHYSERGIDE (GRAHAM, 1964)

A small proportion of patients treated for migraine with methysergide develop retroperitoneal fibrosis which resembles the idiopathic form clinically and pathologically, but usually seems to be completely cured by withdrawal of the drug. To judge from histological appearances the drug-induced disease shares a final common pathway with the idiopathic form. There are many possible ways in which methysergide might produce the condition (Graham, 1967; Mitchinson, 1969a); such suggestions have to take into account that methysergide may also produce pulmonary, cardiac, and proximal aortic lesions culminating in fibrosis (Graham, 1967) and spasm of large arteries, probably including the aorta (Conley, Boulanger, and Mendeloff, 1966).

The problem is a complicated one, especially because of inadequate knowledge of the actions of serotonin and its antagonists (including methysergide). At present only speculation is possible, but in view of other observations in the present series it is important to consider that methysergide might cause spasm of the aorta (or possibly its vasa vasorum), leading to aortic wall damage and leakage into the adventitia, in the way previously suggested as one likely cause for the idiopathic form of the disease. This is a mechanism which more than any other demands early investigation.

Possibly Related Diseases

Idiopathic retroperitoneal fibrosis has not been shown to have anything in common with systemic sclerosis, isolated 'retractile mesenteritis', nodular fasciitis, 'perinephritis plastica', 'periureteritis obliterans', and Peyronie's disease.

Some other fibrotic diseases have been reported coincident with typical retroperitoneal fibrosis. They have not yet been shown to be causally related or histologically similar. These include Dupuytren's contracture (two coincident cases), keloid (two), and nodular pulmonary fibrosis (two).

There remain five conditions which have been reported as coincident with retroperitoneal fibrosis and often with each other (Comings, Skubi, van Eyes, and Motulsky, 1967), show

histological similarity, and probably will be shown to have the same cause.

Idiopathic mediastinal fibrosis has the best claim to be related. Not only is it more frequently associated than any other condition, but also it is usually in physical continuity through the diaphragm. The four examples in the present series confirm this impression, showing also a similar histological appearance. Although it frequently compresses the superior vena cava or invades lung or heart, mediastinal fibrosis appears to be predominantly periaortic in distribution in this series.

Aortitis of unknown cause, whether or not it is loosely grouped as Takayasu's disease, or associated with connective tissue diseases (especially 'rheumatoid' or 'ankylosing' spondylitis), bears a distinct histological resemblance in many cases to some of the aortas in the present series. Many of such types of aortitis, which are at present imperfectly classified, are associated with fibrotic adventitial thickening differing only in volume or in anatomical distribution from typical idiopathic retroperitoneal fibrosis, which can obstruct the ureter when it is still less than a centimetre thick.

Riedel's thyroiditis is very rare, and consists of fibrosis of part or the whole of the thyroid together with adjacent structures including muscle (Woolner, McConahey, and Behrs, 1957). It has been seen in a total of four patients with retroperitoneal fibrosis, and is also occasionally coincident with mediastinal fibrosis, sclerosing cholangitis, or pseudo-tumour of the orbit. Two of the patients in the present series showed inflammation of the thyroid; one of these was identical to Riedel's thyroiditis, the other suggesting an earlier stage of the condition. It is difficult to escape the conclusion, from histological similarity and observed coincidence, that this form of thyroiditis is closely related to idiopathic retroperitoneal fibrosis; it is more difficult to explain how unless, as de Courcy suggested in 1942, Riedel's thyroiditis is initially a perivascular disease.

Pseudo-tumour of the orbit occasionally shows large numbers of plasma cells and Russell bodies (Hogan and Zimmerman, 1962). Like sclerosing cholangitis (Comings *et al*, 1967) it has previously been reported in association with Riedel's thyroiditis and mediastinal and retroperitoneal fibrosis, but was not seen in the present series. It seems likely that both these diseases may be closely related in some way.

Conclusions

Idiopathic retroperitoneal fibrosis around the aortic bifurcation may be associated with similar inflammatory and fibrotic lesions at distant sites which may or may not be in physical

continuity. The disease is well characterized and appears to be homogeneous, including those cases precipitated by methysergide. It is associated with disturbance of plasma proteins but produces its most severe effects by blocking nearby hollow organs. The aorta and its branches and nearby veins are sometimes narrowed by surrounding fibrosis; when the ureters are surrounded, hydronephrosis, eventual loss of renal function, and hypertension may follow. Some cases of aortitis, idiopathic mediastinal fibrosis, Riedel's thyroiditis, pseudo-tumour of the orbit, and sclerosing cholangitis are probably of similar cause, and it would be logical to include them under a heading such as 'systemic idiopathic fibrosis'.

The cause is unknown. More detailed clinical investigation and pathological observations are required to elucidate it. The present study suggests that damage to the aortic wall might be the underlying abnormality. The adventitial inflammation and spreading fibrosis might be secondary to aortitis, such as by leakage of some allergen through the damaged wall. The original aortic damage might be due to methysergide or other vasoactive agents in some cases, and to aortitis similar to that seen in connective tissue diseases in the majority.

Some of the cases in the series have already been reported (Jones and Alexander, 1966; Turner-Warwick, Nabarro, and Doniach, 1966; Jose, 1967); to these authors, and to other surgeons, physicians, and pathologists too numerous to name, my thanks are due for permission to study their patients. I am grateful to the Department of Medical Photography, Addenbrooke's Hospital, for Figures 1 and 4-7.

References

- Abdulla, Y. H., Adams, C. W. M., and Morgan, R. S. (1967). Connective tissue reactions to implantation of purified sterol, sterol esters, phosphoglycerides, glycerides and free fatty acids. *J. Path. Bact.*, **94**, 63-71.
- Chew, C. K., Jarzylo, S. V., and Valberg, L. S. (1966). Idiopathic retroperitoneal fibrosis with protein-losing enteropathy and duodenal obstruction successfully treated with corticosteroids. *Canad. med. Ass. J.*, **95**, 1183-1188.
- Chisholm, E. R., Hutch, J. A., and Bolomey, A. A. (1954). Bilateral ureteral obstruction due to chronic inflammation of the fascia around the ureters. *J. Urol. (Baltimore)*, **72**, 812-816.
- Clouse, M. E. (1964). Bilateral ureteral obstruction. *J. Amer. med. Ass.*, **188**, 299-301.
- Comings, D. E., Skubi, K. B., Van Eyes, J., and Motulsky, A. G. (1967). Familial multifocal fibrosclerosis. *Ann. intern. Med.*, **66**, 884-892.
- Conley, J. E., Boulanger, W. J., and Mendeloff, G. L. (1966). Aortic obstruction associated with methysergide maleate therapy for headaches. *J. Amer. med. Ass.*, **198**, 808-810.
- Coppridge, W. M., Roberts, L. C., and Hughes, J. (1955). Sclerosing lipogranuloma. *Sth. med. J. (Bgham, Ala.)*, **48**, 827-833.
- Courcy, J. L. de (1942). A new theory concerning the etiology of Riedel's struma. *Surgery*, **12**, 754-762.
- Gardner, D. L. (1965). In *Pathology of the Connective Tissue Diseases*. Edward Arnold, London.

- Goodwin, W. E., Fonkalsrud, E. W., Goldman, R., Kaufman, J. J., Martin, D. C., Riley, J. M., Roe, C. W., Schapiro, A. E., and Wilkerson, J. A. (1966). Diagnostic problems in retroperitoneal disease. *Ann. intern. Med.*, **65**, 160-184.
- Graham, J. R. (1964). Methysergide for prevention of headache; experience in five hundred patients over three years. *New Engl. J. Med.*, **270**, 67-72.
- Graham, J. R. (1967). Cardiac and pulmonary fibrosis during methysergide therapy for headache. *Amer. J. med. Sci.*, **254**, 1-12.
- Hackett, E. (1958). Idiopathic retroperitoneal fibrosis; a condition involving the ureters, the aorta, and the inferior vena cava. *Brit. J. Surg.*, **46**, 3-9.
- Hamperl, H., and Dallenbach, F. D. (1957). The extravasation and precipitation of urine in the hilus of the kidneys. *J. Mt Sinai Hosp.*, **24**, 929-934.
- Harrow, B. R., and Sloane, J. A. (1962). Idiopathic retroperitoneal fibrosis. *J. Amer. med. Ass.*, **182**, 38-43.
- Hinman, F., Jr. (1960). Quoted by Ormond, J. K. Idiopathic retroperitoneal fibrosis. *J. Amer. med. Ass.*, **174**, 1565.
- Hogan, M. J., and Zimmerman, L. E. Eds. (1962). In *Ophthalmic Pathology*, p. 765. Saunders, Philadelphia and London.
- Jones, D., Gresham, G. A., Lloyd, H. G., and Howard, A. N. (1965). Yellow fat in the wild rabbit. *Nature (Lond.)*, **207**, 205-206.
- Jones, E. A., and Alexander, M. K. (1966). Idiopathic retroperitoneal fibrosis associated with an arteritis. *Ann. rheum. Dis.*, **25**, 356-360.
- Jose, J. S. (1967). Idiopathic retroperitoneal fibrosis. Notes on its diagnosis, management and pathogenesis. *Brit. J. Urol.*, **39**, 431-43.
- Kay, R. G. (1963). Retroperitoneal vasculitis with perivascular fibrosis. *Brit. J. Urol.*, **35**, 284-291.
- Kendall, A. R., and Lakey, W. H. (1961). Sclerosing Hodgkin's disease vs. idiopathic retroperitoneal fibrosis. *J. Urol. (Baltimore)*, **86**, 217-221.
- Lund, F., and Pedersen, J. (1960). Periureteritis fibrosa (Gerota's fasciitis). *Acta med. scand.*, **167**, 105-110.
- MacLean, J. T. (1954). Unusual conditions of the ureter and kidney. *Brit. J. Urol.*, **26**, 127-138.
- Mathisen, W., and Holta, A. L. (1966). Idiopathic retroperitoneal fibrosis. *Surg. Gynec. Obstet.*, **122**, 1278-1282.
- Miller, J. M., Lipin, R. J., Meisel, H. J., and Long, P. H. (1952). Bilateral ureteral obstruction due to compression by chronic retroperitoneal inflammation. *J. Urol. (Baltimore)*, **68**, 447-451.
- Mitchinson, M. J. (1965). Systemic idiopathic fibrosis and systemic Weber-Christian disease. *J. clin. Path.*, **18**, 645-649.
- Mitchinson, M. J. (1969a). *Systemic idiopathic fibrosis*. M.D. dissertation.
- Mitchinson, M. J. (1969b). The toxoplasma dye test in idiopathic retroperitoneal fibrosis. *Lancet*, **2**, 602.
- Mitchinson, M. J. (1970). Clinical aspects of idiopathic retroperitoneal fibrosis. To be published.
- Mitchinson, M. J., and Bird, D. R. (1970). Urinary leakage and retroperitoneal fibrosis. *J. Urol. (Baltimore)*. In press.
- Nezclof, C., Watchi, J. M., Auvert, J., Xerri, A., and Couvelaire, R. (1967). Sur l'incidence uréterale de la fibrose rétroperitoneale idiopathique extensive (à propos de 15 cas). *J. Urol. Nephrol.*, **73**, 193-229.
- Ohlsén, L. (1965). Retroperitoneal fibrosis due to leakage of urine. A contribution to the etiology of idiopathic retroperitoneal fibrosis. *Acta Soc. Med. upsalien.*, **70**, 231-240.
- Pugh, R. C. B. (1960). Pathology of fibrotic lesions. *Proc. roy. Soc. Med.*, **53**, 685-689.
- Saxton, H. M., Kilpatrick, F. R., Kinder, C. H., Lessof, M. H., McHardy-Young, S., and Wardle, D. F. H. (1969). Retroperitoneal fibrosis: a radiological and follow-up study of fourteen cases. *Quart. J. Med.*, **38**, 159-181.
- Shaheen, D. J., and Johnston, A. (1959). Bilateral ureteral obstruction due to envelopment and compression by an inflammatory retroperitoneal process: report of 2 cases. *J. Urol. (Baltimore)*, **82**, 51-57.
- Stapor, K. (1967). Calycorenal backflow. *Brit. J. Urol.*, **39**, 753-758.
- Turner-Warwick, R., Nabarro, J. D. N., and Doniach, D. (1966). Riedel's thyroiditis and retroperitoneal fibrosis. *Proc. roy. Soc. Med.*, **59**, 596-598.
- Ullmann, A. S., and Dacso, M. R. (1968). Multifocal idiopathic fibromatosis. *Dis. Chest.*, **53**, 657-659.
- Webb, A. J., and Dawson-Edwards, P. (1967). Non-malignant retroperitoneal fibrosis. *Brit. J. Surg.*, **54**, 508-518.
- Woolner, L. B., McConahey, W. M., and Bearrs, O. H. (1957). Invasive fibrous thyroiditis (Riedel's struma). *J. clin. Endocr.*, **17**, 201-220.