

Normal osteoid tissue

VINITA RAINA

From the Department of Morbid Anatomy, Institute of Orthopaedics, London

SYNOPSIS The results of a histological study of normal osteoid tissue in man, the monkey, the dog, and the rat, using thin microtome sections of plastic-embedded undecalcified bone, are described. Osteoid tissue covers the entire bone surface, except for areas of active resorption, although the thickness of the layer of osteoid tissue varies at different sites and in different species of animals.

The histological features of osteoid tissue, apart from its amount, are the same in the different species studied.

Distinct bands or zones are recognizable in some layers of osteoid tissue, particularly those of greatest thickness, and their significance is discussed.

Some of the histological features of the calcification front are described.

Osteoid tissue is defined as unmineralized bone tissue. Its presence in large amounts is a distinctive histological feature of osteomalacia (Sissons and Aga, 1970), but it is also present in smaller quantities in normal conditions and is then usually regarded as representing an initial stage in the formation of calcified bone tissue.

It was Virchow, in 1851, on the basis of a histological study of human bone specimens partially or completely decalcified in hydrochloric acid, who first put forward the concept that mineralization occurs subsequent to the formation of unmineralized organic bone matrix: he also introduced the term 'osteoid' ('like bone') to describe the unmineralized bone which he observed. Tomes and De Morgan (1853), studying undecalcified ground sections of foetal bones, also noted that bone was not calcified when first deposited, and Müller (1858) made similar observations. The work of Pommer (1885), using undecalcified sections as well as sections decalcified in hydrochloric acid or Müller's fluid, served to establish the importance of osteoid tissue as an essential stage in bone formation. Wieland (1909), using undecalcified sections of newborn and premature infants, observed that osteoid tissue was regularly present, and applied the term 'physiological osteoid' to it. Later, Baker (1950), using celloidin sections of bone which had been partially decalcified in Müller's fluid, stained with haematoxylin and eosin, showed that osteoid tissue could be seen in such material as layers of pink-staining material on the surface of the blue-staining bone.

The concept of osteoid tissue as a necessary stage in bone formation was not accepted by all workers. von Recklinghausen (1910) believed that the presence of osteoid tissue was the result of withdrawal of bone mineral from calcified bone ('halisteresis'). This concept, though not generally accepted, has been revived in recent years in connexion with the removal of bone mineral from the immediate vicinity of osteocytes in calcified bone (Belanger, Robichon, Migicovsky, Copp, and Vincent, 1963). McLean and Bloom (1940) and Bloom, Bloom, and McLean (1941), also criticized the idea of osteoid tissue as a necessary stage in bone formation, but for a different reason. In undecalcified sections of the bones of growing rats, and of pigeons during egg laying, they failed to find much osteoid tissue, and concluded that under optimal conditions of supply and transport of bone minerals, bone matrix calcified rapidly. For them, the presence of osteoid tissue indicated a general deficiency in the availability of bone minerals, or a local interference in their supply.

More recent studies with undecalcified sections (Frost, Villanueva, and Roth, 1960; Garner and Ball, 1966; Sissons, Holley, and Heighway, 1967; Morgan, Lever, Patterson, Woods, Pulvertaft, and Fourman, 1967) have confirmed the presence of osteoid tissue in normal bone, and have provided information on the actual amount present. Electron microscopy, too, has been used to demonstrate the existence of osteoid tissue as a stage in normal osteogenesis (Robinson and Cameron, 1956; Scott and Pease, 1956).

Materials and Methods

The present investigation was carried out to confirm the presence of osteoid tissue in normal bone in a variety of animal species, and to explore its histological structure and staining reactions as seen in thin sections of plastic-embedded undecalcified bone which can now be prepared using a heavy metallurgical microtome.

Specimens from human patients (iliac crest samples from necropsies following death from injury or acute illness), rats (tibia and femur), monkeys (radius and ribs), and dogs (ribs) were available.

Materials for histological study, including both cortical and cancellous bone, were fixed in neutralized formalin, dehydrated, and embedded in methyl methacrylate (Sissons, 1968). Sections, 5 microns or less in thickness, were cut using a heavy duty metallurgical microtome (the Jung model K microtome), and were stained by a number of techniques (haematoxylin and eosin, von Kossa, solochrome cyanin, Masson trichrome stain, van Gieson

connective tissue stain, Gordon and Sweet's method for reticulin, periodic acid-Schiff reaction, Azure A) to show the general morphology of the tissue, the distinction between osteoid tissue and calcified bone, the connective tissue elements and the presence of mucopolysaccharides. Polarization microscopy was also used to study collagen fibres.

Results

In all the material studied, sections stained with haematoxylin and eosin showed a layer of pink-staining osteoid tissue covering part of the bone surface and separating the osteoblasts from the blue-staining bone tissue (Fig. 1). Thinner sections, approximately 2 microns in thickness, could be prepared only with specimens of cancellous bone, and in these a thin but virtually continuous layer of osteoid tissue was found to cover the bone surface except where active resorption was taking place. This layer of osteoid tissue was approximately 1 micron in thickness, and could be seen only at a high magnification (Fig. 2): it was covered by small

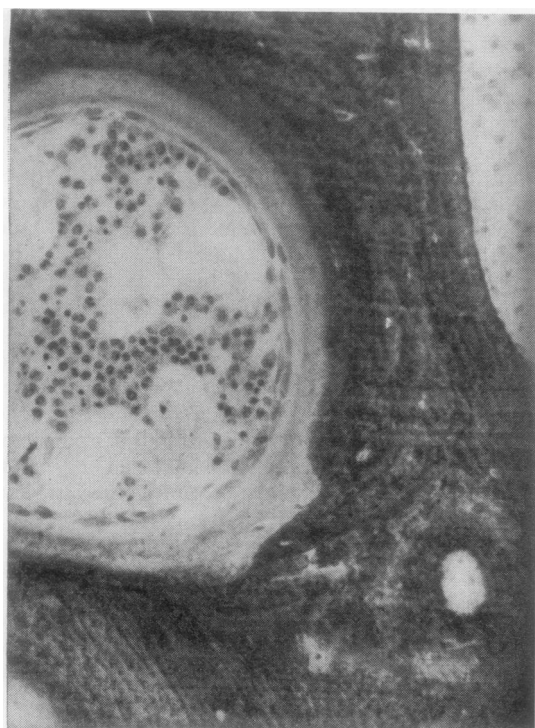

Fig. 1 Human cancellous bone of iliac crest showing a layer of pale staining osteoid tissue lining the trabecular surface. Undecalcified, 5 μ section (H & E \times 165).

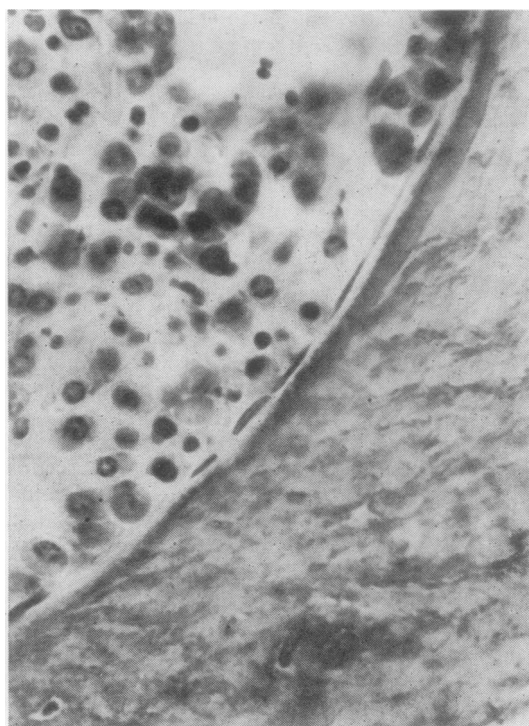


Fig. 2 Human cancellous bone of iliac crest showing a very thin layer (1 to 2 μ) of osteoid tissue covering the trabecular surface. Undecalcified, 2 μ (H & E \times 630).

spindle-shaped osteoblasts. On occasional surfaces the osteoid tissue was thicker, and could be seen at a low magnification: these surfaces were usually covered by active cuboidal or columnar osteoblasts. Failure to demonstrate mineral in this pink-staining layer of tissue with the von Kossa reaction confirmed that it was osteoid tissue.

The thickness of the osteoid layers covering the bone surfaces varied in the different species studied. In the rat, the osteoid layers were very thin and barely discernible, even in thin sections. In the monkey, the maximum thickness was approximately 10 microns. In the dog (compact bone only), the osteoid layers lining osteons were fairly thick and readily seen, and their maximum thickness was approximately 20 microns. In the human material (compact and cancellous bone), the maximum thickness of the osteoid layers was approximately 20 microns.

The osteoid tissue occasionally showed two distinct zones, particularly in the human and the dog material where the layers of osteoid tissue were thickest and where they were covered by active osteoblasts. The zones could be observed with most of the staining reactions used (haematoxylin and eosin, solochrome cyanin, connective tissue stains), the superficial zone adjacent to the osteoblasts staining less intensely than the deeper zone. With Azure A, the superficial zone gave an orthochromatic reaction while the deep zone was metachromatic. When seen with the polarizing microscope, the collagen fibres of the two zones did not differ in structure or arrangement.

The collagen fibres in the osteoid tissue had a lamellar arrangement which appeared identical with that of calcified bone tissue. This was apparent in sections stained with connective tissue stains: with the polarizing microscope the collagen fibres of the osteoid tissue were birefringent, and showed a lamellar arrangement. The Gordon and Sweet technique for reticulin fibres failed to give a positive reaction in osteoid tissue.

The periodic acid-Schiff reaction of osteoid tissue was always negative, while calcified bone gave a positive reaction. In general, osteoid tissue was metachromatic when stained with Azure A, but where a superficial pale-staining zone could be identified in a haematoxylin and eosin section this was found to be orthochromatic. The calcified bone showed a weak metachromasia.

The calcification front—a line of granular staining at the junction of osteoid tissue and calcified bone—was studied with particular attention. It was particularly conspicuous where the layers of osteoid tissue were thickest. With haematoxylin and eosin, it appeared as a line of basophilic granular material

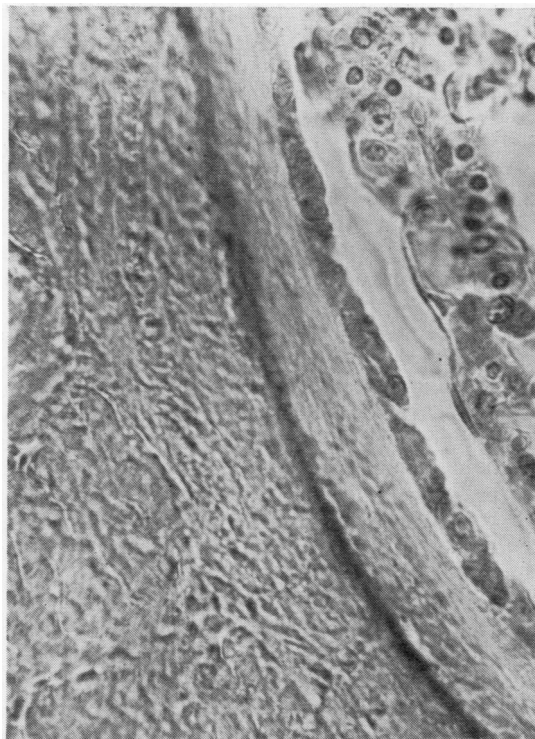


Fig. 3 Human cancellous bone of iliac crest showing calcification front as a dark staining line between osteoid tissue and calcified bone. Osteoid tissue is lined by active osteoblasts. Undecalcified 3μ section. Solochrome cyanin stain ($\times 630$).

between the pink-staining osteoid tissue and the underlying calcified bone. As described by Matrajt and Hicco (1966), it showed very clearly in sections stained with solochrome cyanin, appearing as a dark red or purple line of granular material between the orange-staining osteoid tissue and the blue-staining calcified bone (Fig. 3). The calcification front could be identified in each of the species studied, although it was less distinct in the rat where the layers of osteoid tissue are very thin.

Discussion

The observations described establish that the presence of osteoid tissue is a normal feature of bone structure, and are consistent with the view that bone formation involves two distinct stages—the elaboration of the matrix and its subsequent mineralization. Widespread covering of the bone surface by a layer of osteoid tissue of varying thickness was observed in each of the species studied, although the thickness of the layer of osteoid tissue varied in

different species. In man, sites of active bone formation are identified by the presence of a relatively thick layer of osteoid tissue, usually 3-10 microns in thickness. Inactive bone surfaces are covered by a thinner layer of osteoid tissue, 2 microns or less in thickness. In the rat, the layers of osteoid tissue are very thin, and they may not be apparent unless very thin sections are examined. The failure of some workers to observe osteoid tissue in the bones of normal rats (Weidenreich, 1923; McLean and Bloom, 1940) could well be due to this.

At the ordinary microscopic level, osteoid tissue is devoid of mineral material, and the onset of calcification appears to be at the calcification front. This narrow zone between osteoid tissue and calcified bone reacts intensely with several stains, including solochrome cyanin, and substances such as phosphates (Johnson, 1964), zinc (Haumont, 1961), and lipids (Irving, 1963a and b) have been demonstrated in it. It represents an area of active mineralization, and is where tetracyclines are localized during life (Milch, Rall, and Tobie, 1958).

Osteoid tissue has been described as a homogeneous tissue (Weinman and Sicher, 1955), although the work of Juster, Oligo, and Laval-Jeantet (1967) has indicated the presence of a number of zones with different morphological features. The present observations confirm, to some extent, a zonal variation in structure, although the details are not quite the same as those reported by the previous workers. A superficial clear zone, consisting mainly of collagen, and a deep more intensely staining zone, where a positive metachromatic reaction indicates the presence of acid mucopolysaccharides, is described. This suggests that osteoid tissue undergoes certain chemical changes between its elaboration by osteoblasts and the onset of calcification. It is to be noted, however, that the superficial clear zone is not seen in all osteoid layers, possibly because the acid mucopolysaccharides, which are responsible for the more intense staining of the deeper osteoid tissue, appear very soon after the collagen fibres are formed.

The work described is taken from a thesis submitted for the PhD degree of the University of London. It was carried out in the Department of Morbid Anatomy of the Institute of Orthopaedics, Royal National Orthopaedic Hospital, London, under the supervision of Dr H. A. Sissons to whom I owe grateful thanks.

References

- Baker, S. L. (1950). The general pathology of bone. In *A Text Book of X-Ray Diagnosis*, 2nd ed., vol. 4, edited by S. C. Shanks and P. Kerley. Lewis, London.
- Belanger, L. F., Robichon, J., Migicovsky, B. B., Copp, D. H., and Vincent, J. (1963). In *Mechanisms of Hard Tissue Destruction*, edited by R. F. Sognnaes. American Association for the Advancement of Science, Washington, D.C.
- Bloom, W., Bloom, M. A., and McLean, F. C. (1941). Calcification and ossification. Medullary bone changes in the reproductive cycle of female pigeons. *Anat. Rec.*, **81**, 443-475.
- Frost, H. M., Villanueva, A. R., and Roth, H. (1960). Measurement of bone formation in a 57 year old man by means of tetracyclines. *Henry Ford Hosp. Bull.*, **8**, 239-254.
- Garner, A., and Ball, J. (1966). Quantitative observations on mineralised and unmineralised bone in chronic renal azotemia and intestinal malabsorption syndrome. *J. Path. Bact.*, **91**, 545-561.
- Haumont, S. (1961). Distribution of zinc in bone tissue. *J. Histochem. Cytochem.*, **9**, 141-145.
- Irving, J. T. (1963a). The sudanophil material at sites of calcification. *Arch. oral Biol.*, **8**, 735-745.
- Irving, J. T. (1963b). Calcification of the organic matrix of enamel. *Arch. oral Biol.*, **8**, 773-774.
- Johnson, L. C. (1964). In *Bone Biodynamics* (Henry Ford Hospital International Symposium, 1963), edited by H. M. Frost. Little, Brown, Boston; Churchill, London.
- Juster, M., Oligo, N., and Laval-Jeantet, M. (1967). Liséré proeuses et tissu ostéolde. In *L'Ostéomalacie*, edited by D. J. Hioco, p. 39. Masson, Paris.
- McLean, F. C., and Bloom, W. (1940). Calcification and ossification. Calcification in normal growing bone. *Anat. Rec.*, **78**, 333-359.
- Matrajt, H., and Hioco, D. (1966). Solochrome cyanine R as an indicator dye of bone morphology. *Stain Technol.*, **41**, 97-100.
- Milch, R. A., Rall, D. P., and Tobie, J. E. (1958). Fluorescence of tetracycline antibiotics in bone. *J. Bone Jt Surg.*, **40A**, 897-910.
- Morgan, D. B., Lever, J. V., Paterson, C. R., Woods, C. G., Pulvertaft, C. N., and Fourman, P. (1967). In *L'Ostéomalacie*, edited by D. J. Hioco. Masson, Paris.
- Müller, H. (1858). Ueber die Entwicklung der Knochensubstanz, nebst Bemerkungen über der Bau rachitischer Knochen. *Z. wiss. Zool.*, **9**, 147-233.
- Pommer, G. (1885). *Untersuchungen über Osteomalacie und Rachitis*. F. C. W. Vogel, Leipzig.
- Recklinghausen, F. D. von (1910). *Untersuchungen über Rachitis und Osteomalacie*. G. Fischer, Jena.
- Robinson, R. A., and Cameron, D. A. (1956). Electron microscopy of cartilage and bone matrix at the distal epiphyseal line of the femur in the newborn infant. *J. biophys. biochem. Cytol.*, **2**, Suppl., 253-260.
- Scott, B. L., and Pease, D. C. (1956). Electron microscopy of the epiphyseal apparatus. *Anat. Rec.*, **126**, 465-495.
- Sissons, H. A. (1968). Preparation of undecalcified bone sections. *Ass. clin. Path. Broadsheets*, **62**.
- Sissons, H. A., and Aga, V. (1970). Pathology of metabolic bone disease. In *Symposium Ossium* (European Association of Radiology), edited by A. M. Jelliffe and B. Strickland, pp. 285-288. Livingstone, Edinburgh and London.
- Sissons, H. A., Holley, K. J., and Heighway, J. (1967). In *L'Ostéomalacie*, edited by D. J. Hioco. Masson, Paris.
- Tomes, J., and De Morgan, C. (1853). Observations on the structure and development of bone. *Phil. Trans.*, **143**, 109-140.
- Virchow, R. (1851). Die Identität von Knochen-, Knorpel- und Bindegewebskörperchen, sowie über Schleimgewebe. *Verh. phys.-med. Ges. Würzb.*, **2**, 150-162.
- Weidenreich, F. (1923). Knochenstudien. I. Ueber Aufbau und Entwicklung des Knochens und den Charakter des Knochengewebes. *Z. Anat. Entwickl.-Gesch.*, **69**, 382-466.
- Wieland, E. (1909). Klinische und anatomische untersuchungen über sogen. angeborene und über frühzeitig erswerbene Rachitis. *Jb. Kinderheilk.*, **70**, 539-613.
- Weinman, J. P., and Sicher, H. (1955). In *Bones and Bones. Fundamentals of Bone Biology*, 2nd ed. Mosby, St Louis.