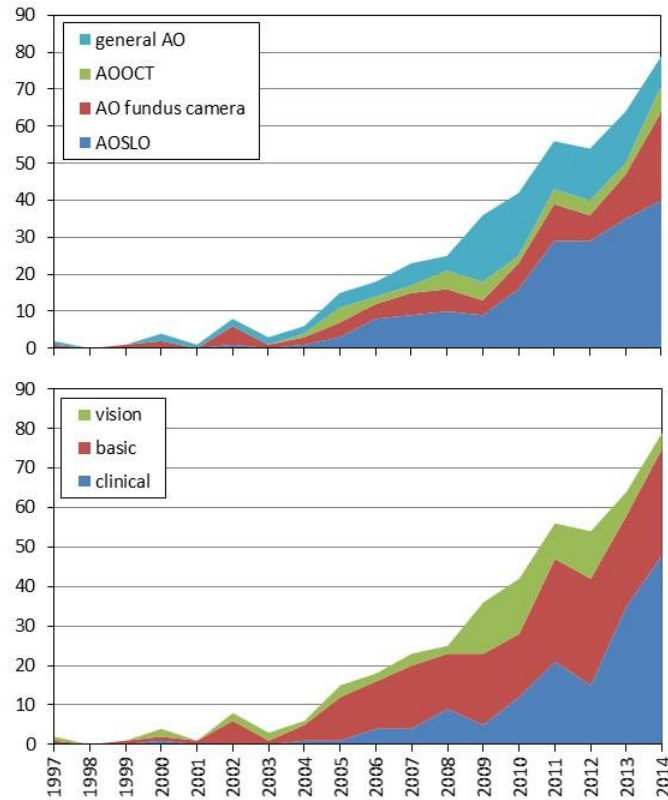


Supplemental information



Supplemental Figure 1: These charts plot eye and vision related AO papers published to the end of 2014. General AO papers are those whose results are generally applicable to any AO modality (e.g.: use of woofer tweeter deformable mirrors to optimize AO correction). Papers reporting combined technologies (e.g. AOSLO and AOOCT were divided equally between their respective categories). Clinical science papers were defined as those that report AO retinal images or AO data acquired from patients with disease. Basic science papers are those that report a new AO-based technology, a new imaging target, a novel AO image analysis, or report on a basic property of retinal structure or physiology (e.g. mapping of the trichromatic cone mosaic). Vision applications include those studies that use AO to study how optics and blur affect vision, but do not involve retinal imaging in any form.

Supplemental Table 1: AO clinical publications tabulated by disease and retinal location imaged

Inner Retinal Disease and Neuropathies

Glaucoma:

Nerve fiber layer: ([Chen et al 2015](#), [Scoles et al 2014a](#), [Takayama et al 2012](#))

Lamina cribrosa: ([Akagi et al 2012](#), [Lombardo et al 2013c](#), [Sredar et al 2013](#))

Cones: ([Choi et al 2008](#), [Werner et al 2011](#))

Epiretinal membrane: ([Lombardo et al 2013b](#), [Ooto et al 2011b](#), [Scoles et al 2014a](#))

Gunn's dots: ([Paques et al 2015](#), [Scoles et al 2014a](#))

Optic nerve drusen with non arteric ischemic optic neuropathy (cone imaging): ([Choi et al 2008](#), [Scoles et al 2014a](#))

Optic atrophy: ([Gocho et al 2013a](#), [Scoles et al 2014a](#))

Optic neuritis: ([Scoles et al 2014a](#))

Multiple sclerosis: ([Scoles et al 2014a](#))

Parkinson's disease: ([Scoles et al 2014a](#))

Retinal Vasculature Disease

Diabetes

Vasculature: ([Arichika et al 2014a](#), [Burns et al 2014](#), [Chui et al 2014](#), [Deak & Schmidt-Erfurth 2013](#), [Dubow et al 2014](#), [Lombardo et al 2013a](#), [Pinhas et al 2014](#), [Scoles et al 2014a](#), [Stepushina & Bol'shunov 2011](#), [Tam et al 2012](#), [Tam et al 2011](#))

Hard exudates: ([Burns et al 2014](#), [Roorda et al 2006](#))

Cones: ([Lombardo et al 2014](#), [Tam et al 2012](#))

Hypertension: ([Arichika et al 2014b](#), [Chui et al 2014](#), [Koch et al 2014](#), [Pinhas et al 2014](#), [Stepushina & Bol'shunov 2011](#))

Branch retinal vein occlusion: ([Akagi-Kurashige et al 2014](#), [Chui et al 2014](#), [Scoles et al 2014a](#))

Central vein occlusion: ([Chui et al 2014](#))

Central macular arteriovenous malformation: ([Telander et al 2010](#))

Retinal vasculitis: ([Errera et al 2014](#))

Hyperlipidemia: ([Pinhas et al 2014](#))

Sickle cell disease: ([Pinhas et al 2014](#))

Ocular Toxicity and Trauma

Ocular siderosis: ([Faure et al 2014](#))

Hydroxychloroquine retinal toxicity: ([Jacob et al 2015](#), [Stepien et al 2009](#))

Chloroquine maculopathy: ([Bae et al 2014](#))

Response to surgeries

Laser photocoagulation for hemiretinal vein occlusion and proliferative diabetic retinopathy: ([Han et al 2012](#))

Macular translocation for AMD: ([Muthiah et al 2014](#))

Retinal detachment surgery: ([Saleh et al 2014](#))

Ocular trauma

Blunt force: ([Flutter et al 2014](#), [Langlo et al 2014](#), [Stepien et al 2012](#))

Solar retinopathy: ([Roorda et al 2006](#))

Laser injury: ([Kitaguchi et al 2009](#))

Macular holes: ([Debellemaniere et al 2014](#), [Hansen et al 2015](#), [Kitaguchi et al 2008](#), [Ooto et al 2012](#), [Ooto et al 2014](#), [Scoles et al 2014a](#), [Yokota et al 2013](#))

Outer retinal disease (not including inherited retinal degenerations with known gene mutations)

Age-related macular degeneration (AMD)

Photoreceptors and/or drusen: ([Boretzky et al 2012](#), [Godara et al 2010c](#), [Land et al 2014](#), [Meadway et al 2014](#), [Mrejen et al 2014b](#), [Obata & Yanagi 2014](#), [Querques et al 2014](#), [Querques et al 2012](#), [Zayit-Soudry et al 2013](#), [Zhang et al 2014](#))

Retinal pigment epithelium: ([Rossi et al 2013b](#))

Geographic atrophy: ([Gocho et al 2013b](#), [Zayit-Soudry et al 2013](#))

Inner retina: ([Scoles et al 2014a](#))

Macular telangiectasia type 2: ([Jacob et al 2015](#), [Massamba et al 2011](#), [Ooto et al 2011a](#), [Ooto et al 2013](#), [Scoles et al 2014a](#), [Wang et al 2015](#))

Albinism: ([Godara et al 2010a](#), [Marmor et al 2008](#), [McAllister et al 2010](#), [Wilk et al 2014](#))

Central serous chorioretinopathy: ([Ooto et al 2010](#), [Scoles et al 2014a](#))

Birdshot choroidoretinopathy: ([Scoles et al 2014a](#))

Rubella retinopathy: ([Scoles et al 2014a](#))

Inflammatory retinopathies

AZOOOR: ([Merino et al 2011](#), [Mkrtchyan et al 2012](#), [Nakao et al 2014](#))

Acute macular neuroretinopathy: ([Garnier et al 2015](#), [Hansen et al 2013](#), [Mrejen et al 2014a](#))

Acute posterior multifocal placoid pigment epitheliopathy: ([Hong et al 2014](#), [Jacob et al 2015](#), [Mrejen et al 2013](#))

Unilateral acute idiopathic maculopathy: ([Ooto et al 2011c](#))

Multiple evanescent white dot syndrome: ([Boretzky et al 2013](#))

Other maculopathies

Bilateral maculopathy: ([Godara et al 2010b](#))

Central ring scotoma: ([Joeres et al 2008](#))

Bull's eye maculopathy: ([Bessho et al 2008](#))

Inherited retinal degenerations

RHO (autosomal dominant retinitis pigmentosa): ([Choi et al 2006](#), [Duncan et al 2007](#), [Menghini et al 2015](#), [Park et al 2014](#))

CNBA3, *CNGB3*, *GNAT2*, *PDE6C* (achromatopsia): ([Carroll et al 2008](#), [Dubis et al 2014](#), [Genead et al 2011](#), [Merino et al 2011](#), [Scoles et al 2014b](#), [Sundaram et al 2014](#), [Vincent et al 2013b](#))

OPN1LW/*OPN1MW*/*OPN1SW*

(blue cone monochromacy): ([Carroll et al 2010](#), [Cideciyan et al 2013](#), [Rossi et al 2013a](#))

(red-green color vision defects): ([Carroll et al 2009](#), [Carroll et al 2012](#), [Carroll et al 2004](#), [Makous et al 2006](#), [McClements et al 2013](#), [Rha et al 2010](#), [Wagner-Schuman et al 2010](#))

(tritan defects): ([Baraas et al 2007](#))

REP1 (Choroideremia): ([Morgan et al 2014](#), [Scoles et al 2014a](#), [Syed et al 2013](#))

RS1 (X-linked retinoschisis): ([Duncan et al 2011a](#))

CLRN1 (Ushers type III): ([Ratnam et al 2013](#))

CDHR1 (autosomal recessive retinal degeneration): ([Duncan et al 2012](#))

FAM161A (autosomal recessive retinal degeneration): ([Duncan et al 2014](#))

SNRNP200 (autosomal dominant retinitis pigmentosa): ([Bowne et al 2013](#))

CYP4V2 (Bietti crystalline dystrophy): ([Gocho et al 2014](#))

NR2E3 (enhanced S-cone syndrome): ([Park et al 2013](#))

KCNV2 (cone dystrophy): ([Vincent et al 2013a](#))

[GRM6](#) (congenital stationary night blindness): ([Godara et al 2012](#))
[GRK1](#) (Oguchi disease): ([Godara et al 2012](#))
[Peripherin/RDS](#) (retinal degeneration): ([Duncan et al 2011b](#))
[RLBP1](#) (retinitis punctata albescens): ([Dessalces et al 2013](#))
[RDH5](#) (fundus albipunctatus): ([Makiyama et al 2014](#), [Song et al 2014](#))
 Mitochondrial DNA [T8993C](#) (NARP): ([Gelfand et al 2011](#), [Yoon et al 2009](#))
[ABCA4](#) (Stargardt's disease): ([Chen et al 2011](#), [Pang et al 2015](#), [Scoles et al 2014a](#), [Xue et al 2007](#))
[BEST1](#) (Best's vitelliform dystrophy): ([Kay et al 2013](#), [Scoles et al 2014a](#))
[RPGR](#) (cone rod dystrophy) ([Duncan et al 2007](#))
[RPGR](#) (X-linked retinitis pigmentosa): ([Menghini et al 2015](#))
[ABCA4](#) (autosomal recessive retinitis pigmentosa): ([Menghini et al 2015](#))
[RPGR](#) and [RP2](#) (female carriers of XLRP): ([Pyo et al 2013](#))
[CEP290](#) (Leber's congenital amaurosis): ([Scoles et al 2014a](#))
 Cone-rod dystrophy: ([Choi et al 2006](#), [Duncan et al 2007](#), [Scoles et al 2014a](#), [Wolffing et al 2006](#))
 Rod-cone dystrophy: ([Choi et al 2006](#))
 Occult macular dystrophy: ([Kitaguchi et al 2011](#), [Tojo et al 2013](#))
 Oligocone trichromacy: ([Michaelides et al 2011](#))

- Akagi-Kurashige Y, Tsujikawa A, Ooto S, Makiyama Y, Muraoka Y, et al. 2014. Retinal microstructural changes in eyes with resolved branch retinal vein occlusion: an adaptive optics scanning laser ophthalmoscopy study. *American Journal of Ophthalmology* 157: 1239-49
- Akagi T, Hangai M, Takayama K, Nonaka A, Ooto S, Yoshimura N. 2012. In vivo imaging of lamina cribrosa pores by adaptive optics scanning laser ophthalmoscopy. *Invest Ophthalmol.Vis.Sci.* 53: 4111-19
- Arichika S, Uji A, Murakami T, Unoki N, Yoshitake S, et al. 2014a. Retinal hemorheologic characterization of early-stage diabetic retinopathy using adaptive optics scanning laser ophthalmoscopy. *Invest Ophthalmol Vis Sci* 55: 8513-22
- Arichika S, Uji A, Yoshimura N. 2014b. Adaptive optics assisted visualization of thickened retinal arterial wall in a patient with controlled malignant hypertension. *Clinical ophthalmology* 8: 2041-3
- Bae EJ, Kim KR, Tsang SH, Park SP, Chang S. 2014. Retinal damage in chloroquine maculopathy, revealed by high resolution imaging: a case report utilizing adaptive optics scanning laser ophthalmoscopy. *Korean J.Ophthalmol.* 28: 100-07
- Baraas RC, Carroll J, Gunther KL, Chung M, Williams DR, et al. 2007. Adaptive optics retinal imaging reveals S-cone dystrophy in tritan color-vision deficiency. *J.Opt.Soc.Am.A Opt.Image Sci.Vis.* 24: 1438-47
- Bessho K, Fujikado T, Mihashi T, Yamaguchi T, Nakazawa N, Tano Y. 2008. Photoreceptor images of normal eyes and of eyes with macular dystrophy obtained in vivo with an adaptive optics fundus camera. *Jpn.J.Ophthalmol.* 52: 380-85
- Boretzky A, Khan F, Burnett G, Hammer DX, Ferguson RD, et al. 2012. In vivo imaging of photoreceptor disruption associated with age-related macular degeneration: A pilot study. *Lasers Surg.Med.* 44: 603-10
- Boretzky A, Mirza S, Khan F, Motamedi M, van Kuijk FJ. 2013. High-resolution multimodal imaging of multiple evanescent white dot syndrome. *Ophthalmic Surg.Lasers Imaging Retina* 44: 296-300

- Bowne SJ, Sullivan LS, Avery CE, Sasser EM, Roorda A, et al. 2013. Mutations in the small nuclear riboprotein 200 kDa gene (SNRNP200) cause 1.6% of autosomal dominant retinitis pigmentosa. *Molecular Vision* 19: 2407-17
- Burns SA, Elsner AE, Chui TY, Vannasdale DA, Jr., Clark CA, et al. 2014. In vivo adaptive optics microvascular imaging in diabetic patients without clinically severe diabetic retinopathy. *Biomed. Opt. Express* 5: 961-74
- Carroll J, Baraas RC, Wagner-Schuman M, Rha J, Siebe CA, et al. 2009. Cone photoreceptor mosaic disruption associated with Cys203Arg mutation in the M-cone opsin. *Proc.Natl.Acad.Sci.U.S.A* 106: 20948-53
- Carroll J, Choi SS, Williams DR. 2008. In vivo imaging of the photoreceptor mosaic of a rod monochromat. *Vision Research* 48: 2564-68
- Carroll J, Dubra A, Gardner JC, Mizrahi-Meissonnier L, Cooper RF, et al. 2012. The effect of cone opsin mutations on retinal structure and the integrity of the photoreceptor mosaic. *Invest Ophthalmol.Vis.Sci.* 53: 8006-15
- Carroll J, Neitz M, Hofer H, Neitz J, Williams DR. 2004. Functional photoreceptor loss revealed with adaptive optics: an alternate cause of color blindness. *Proc.Natl.Acad.Sci.U.S.A* 101: 8461-66
- Carroll J, Rossi EA, Porter J, Neitz J, Roorda A, et al. 2010. Deletion of the X-linked opsin gene array locus control region (LCR) results in disruption of the cone mosaic. *Vision Research* 50: 1989-99
- Chen MF, Chui TY, Alhadeff P, Rosen RB, Ritch R, et al. 2015. Adaptive optics imaging of healthy and abnormal regions of retinal nerve fiber bundles of patients with glaucoma. *Invest Ophthalmol Vis Sci* 56: 674-81
- Chen Y, Ratnam K, Sundquist SM, Lujan B, Ayyagari R, et al. 2011. Cone photoreceptor abnormalities correlate with vision loss in patients with Stargardt disease. *Invest Ophthalmol.Vis.Sci.* 52: 3281-92
- Choi SS, Doble N, Hardy JL, Jones SM, Keltner JL, et al. 2006. In vivo imaging of the photoreceptor mosaic in retinal dystrophies and correlations with visual function. *Invest Ophthalmol.Vis.Sci.* 47: 2080-92
- Choi SS, Zawadzki RJ, Keltner JL, Werner JS. 2008. Changes in cellular structures revealed by ultra-high resolution retinal imaging in optic neuropathies. *Invest Ophthalmol.Vis.Sci.* 49: 2103-19
- Chui TY, Dubow M, Pinhas A, Shah N, Gan A, et al. 2014. Comparison of adaptive optics scanning light ophthalmoscopic fluorescein angiography and offset pinhole imaging. *Biomed. Opt. Express* 5: 1173-89
- Cideciyan AV, Hufnagel RB, Carroll J, Sumaroka A, Luo X, et al. 2013. Human cone visual pigment deletions spare sufficient photoreceptors to warrant gene therapy. *Hum.Gene Ther.* 24: 993-1006
- Deak GG, Schmidt-Erfurth U. 2013. Imaging of the parafoveal capillary network in diabetes. *Curr.Diab.Rep.* 13: 469-75
- Debellemanniere G, Koehl A, Delbosc B, Saleh M. 2014. [High-resolution retinal imaging using adaptive optics of a full thickness macular hole]. *Journal francais d'ophtalmologie* 37: 502-3
- Dessalces E, Bocquet B, Bourien J, Zanlonghi X, Verdet R, et al. 2013. Early-onset foveal involvement in retinitis punctata albescens with mutations in RLBP1. *JAMA Ophthalmol.* 131: 1314-23
- Dubis AM, Cooper RF, Aboshiha J, Langlo CS, Sundaram V, et al. 2014. Genotype-dependent variability in residual cone structure in achromatopsia: toward developing metrics for assessing cone health. *Invest Ophthalmol Vis Sci* 55: 7303-11
- Dubow M, Pinhas A, Shah N, Cooper RF, Gan A, et al. 2014. Classification of human retinal microaneurysms using adaptive optics scanning light ophthalmoscope fluorescein angiography. *Invest Ophthalmol.Vis.Sci.* 55: 1299-309

- Duncan JL, Biswas P, Kozak I, Navani M, Syed R, et al. 2014. Ocular Phenotype of a Family with FAM161A-associated Retinal Degeneration. *Ophthalmic Genet.*: 1-9
- Duncan JL, Ratnam K, Birch DG, Sundquist SM, Lucero AS, et al. 2011a. Abnormal cone structure in foveal schisis cavities in X-linked retinoschisis from mutations in exon 6 of the RS1 gene. *Invest Ophthalmol.Vis.Sci.* 52: 9614-23
- Duncan JL, Roorda A, Navani M, Vishweswaraiah S, Syed R, et al. 2012. Identification of a Novel Mutation in the CDHR1 Gene in a Family With Recessive Retinal Degeneration. *Archives of Ophthalmology* 130: 1301-08
- Duncan JL, Talcott KE, Ratnam K, Sundquist SM, Lucero AS, et al. 2011b. Cone Structure in Retinal Degeneration Associated with Mutations in the peripherin/RDS Gene. *Invest Ophthalmol.Vis.Sci.* 52: 1557-66
- Duncan JL, Zhang Y, Gandhi J, Nakanishi C, Othman M, et al. 2007. High-resolution imaging with adaptive optics in patients with inherited retinal degeneration. *Invest Ophthalmol.Vis.Sci.* 48: 3283-91
- Errera MH, Coisy S, Fardeau C, Sahel JA, Kallel S, et al. 2014. Retinal vasculitis imaging by adaptive optics. *Ophthalmology* 121: 1311-12
- Faure C, Gocho K, Le Mer Y, Sahel JA, Paques M, Audo I. 2014. Functional and high resolution retinal imaging assessment in a case of ocular siderosis. *Documenta Ophthalmologica* 128: 69-75
- Flatter JA, Cooper RF, Dubow MJ, Pinhas A, Singh RS, et al. 2014. Outer retinal structure after closed-globe blunt ocular trauma. *Retina* 34: 2133-46
- Garnier MB, Castelbou M, Tumahai P, Montard M, Delbosc B, Saleh M. 2015. [Acute macular neuroretinopathy and adaptive optics imaging. A case report.]. *Journal francais d'ophtalmologie*: [Epub ahead of print]
- Gelfand JM, Duncan JL, Racine CA, Gillum LA, Chin CT, et al. 2011. Heterogeneous patterns of tissue injury in NARP syndrome. *Journal of neurology* 258: 440-8
- Genead MA, Fishman GA, Rha J, Dubis AM, Bonci DM, et al. 2011. Photoreceptor structure and function in patients with congenital achromatopsia. *Invest Ophthalmol.Vis.Sci.* 52: 7298-308
- Gocho K, Kameya S, Akeo K, Kikuchi S, Usui A, et al. 2014. High-Resolution Imaging of Patients with Bietti Crystalline Dystrophy with CYP4V2 Mutation. *J.Ophthalmol.* 2014: 283603
- Gocho K, Kikuchi S, Kabuto T, Kameya S, Shinoda K, et al. 2013a. High-resolution en face images of microcystic macular edema in patients with autosomal dominant optic atrophy. *Biomed.Res.Int.* 2013: 676803
- Gocho K, Sarda V, Falah S, Sahel JA, Sennlaub F, et al. 2013b. Adaptive optics imaging of geographic atrophy. *Invest Ophthalmol.Vis.Sci.* 54: 3673-80
- Godara P, Cooper RF, Sergouniotis PI, Diederichs MA, Streb MR, et al. 2012. Assessing retinal structure in complete congenital stationary night blindness and Oguchi disease. *American Journal of Ophthalmology* 154: 987-1001
- Godara P, Dubis AM, Roorda A, Duncan JL, Carroll J. 2010a. Adaptive optics retinal imaging: emerging clinical applications. *Optometry and Vision Science* 87: 930-41
- Godara P, Rha J, Tait DM, McAllister J, Dubis A, et al. 2010b. Unusual adaptive optics findings in a patient with bilateral maculopathy. *Archives of Ophthalmology* 128: 253-54
- Godara P, Siebe C, Rha J, Michaelides M, Carroll J. 2010c. Assessing the photoreceptor mosaic over drusen using adaptive optics and SD-OCT. *Ophthalmic Surg.Lasers Imaging* 41 Suppl: S104-S08
- Han DP, Croskrey JA, Dubis AM, Schroeder B, Rha J, Carroll J. 2012. Adaptive optics and spectral-domain optical coherence tomography of human photoreceptor structure after short-duration [corrected] pascal macular grid and panretinal laser photocoagulation. *Archives of Ophthalmology* 130: 518-21
- Hansen S, Batson S, Weinlander KM, Cooper RF, Scoles DH, et al. 2015. Assessing photoreceptor structure after macular hole closure. *Retinal cases & brief reports* 9: 15-20

- Hansen SO, Cooper RF, Dubra A, Carroll J, Weinberg DV. 2013. Selective cone photoreceptor injury in acute macular neuroretinopathy. *Retina* 33: 1650-58
- Hong IH, Park SP, Chen CL, Kim HK, Tsang SH, Chang S. 2014. Cone photoreceptor abnormalities correlate with vision loss in a case of acute posterior multifocal placoid pigment epitheliopathy. *Ophthalmic Surg.Lasers Imaging Retina* 45: 74-78
- Jacob J, Paques M, Krivosic V, Dupas B, Couturier A, et al. 2015. Meaning of visualizing retinal cone mosaic on adaptive optics images. *Am J Ophthalmol* 159: 118-23 e1
- Joeres S, Jones SM, Chen DC, Silva D, Olivier S, et al. 2008. Retinal imaging with adaptive optics scanning laser ophthalmoscopy in unexplained central ring scotoma. *Archives of Ophthalmology* 126: 543-47
- Kay DB, Land ME, Cooper RF, Dubis AM, Godara P, et al. 2013. Outer retinal structure in best vitelliform macular dystrophy. *JAMA Ophthalmol.* 131: 1207-15
- Kitaguchi Y, Fujikado T, Bessho K, Sakaguchi H, Gomi F, et al. 2008. Adaptive optics fundus camera to examine localized changes in the photoreceptor layer of the fovea. *Ophthalmology* 115: 1771-77
- Kitaguchi Y, Fujikado T, Kusaka S, Yamaguchi T, Mihashi T, Tano Y. 2009. Imaging of titanium:sapphire laser retinal injury by adaptive optics fundus imaging and Fourier-domain optical coherence tomography. *American Journal of Ophthalmology* 148: 97-104
- Kitaguchi Y, Kusaka S, Yamaguchi T, Mihashi T, Fujikado T. 2011. Detection of photoreceptor disruption by adaptive optics fundus imaging and Fourier-domain optical coherence tomography in eyes with occult macular dystrophy. *Clin.Ophthalmol.* 5: 345-51
- Koch E, Rosenbaum D, Brolly A, Sahel JA, Chaumet-Riffaud P, et al. 2014. Morphometric analysis of small arteries in the human retina using adaptive optics imaging: relationship with blood pressure and focal vascular changes. *J.Hypertens.* 32: 890-98
- Land ME, Cooper RF, Young J, Berg E, Kitchner T, et al. 2014. Cone Structure in Subjects with Known Genetic Relative Risk for AMD. *Optometry and Vision Science* 91: 939-49
- Langlo CS, Flatter JA, Dubra A, Wirostko WJ, Carroll J. 2014. A lensing effect of inner retinal cysts on images of the photoreceptor mosaic. *Retina* 34: 421-22
- Lombardo M, Parravano M, Lombardo G, Varano M, Boccassini B, et al. 2014. Adaptive optics imaging of parafoveal cones in type 1 diabetes. *Retina* 34: 546-57
- Lombardo M, Parravano M, Serrao S, Ducoli P, Stirpe M, Lombardo G. 2013a. Analysis of retinal capillaries in patients with type 1 diabetes and nonproliferative diabetic retinopathy using adaptive optics imaging. *Retina* 33: 1630-39
- Lombardo M, Scarinci F, Ripandelli G, Cupo G, Stirpe M, Serrao S. 2013b. Adaptive optics imaging of idiopathic epiretinal membranes. *Ophthalmology* 120: 1508-09
- Lombardo M, Serrao S, Devaney N, Parravano M, Lombardo G. 2013c. Adaptive optics technology for high-resolution retinal imaging. *Sensors.(Basel)* 13: 334-66
- Makiyama Y, Ooto S, Hangai M, Ogino K, Gotoh N, et al. 2014. Cone abnormalities in fundus albipunctatus associated with RDH5 mutations assessed using adaptive optics scanning laser ophthalmoscopy. *American Journal of Ophthalmology* 157: 558-70
- Makous W, Carroll J, Wolfing JI, Lin J, Christie N, Williams DR. 2006. Retinal microscotomas revealed with adaptive-optics microflashes. *Invest Ophthalmol.Vis.Sci.* 47: 4160-67
- Marmor MF, Choi SS, Zawadzki RJ, Werner JS. 2008. Visual insignificance of the foveal pit: reassessment of foveal hypoplasia as fovea plana. *Archives of Ophthalmology* 126: 907-13
- Massamba N, Querques G, Lamory B, Querques L, Souied E, Soubrane G. 2011. In vivo evaluation of photoreceptor mosaic in type 2 idiopathic macular telangiectasia using adaptive optics. *Acta Ophthalmol.* 89: e601-e03
- McAllister JT, Dubis AM, Tait DM, Ostler S, Rha J, et al. 2010. Arrested development: high-resolution imaging of foveal morphology in albinism. *Vision Research* 50: 810-17

- McClements M, Davies WI, Michaelides M, Carroll J, Rha J, et al. 2013. X-linked cone dystrophy and colour vision deficiency arising from a missense mutation in a hybrid L/M cone opsin gene. *Vision Res* 80: 41-50
- Meadway A, Wang X, Curcio CA, Zhang Y. 2014. Microstructure of subretinal drusenoid deposits revealed by adaptive optics imaging. *Biomed.Opt.Express* 5: 713-27
- Menghini M, Lujan BJ, Zayit-Soudry S, Syed R, Porco TC, et al. 2015. Correlation of outer nuclear layer thickness with cone density values in patients with retinitis pigmentosa and healthy subjects. *Invest Ophthalmol.Vis.Sci.* 56: 372-81
- Merino D, Duncan JL, Tiruveedhula P, Roorda A. 2011. Observation of cone and rod photoreceptors in normal subjects and patients using a new generation adaptive optics scanning laser ophthalmoscope. *Biomed.Opt.Express* 2: 2189-201
- Michaelides M, Rha J, Dees EW, Baraas RC, Wagner-Schuman ML, et al. 2011. Integrity of the cone photoreceptor mosaic in oligocone trichromacy. *Invest Ophthalmol.Vis.Sci.* 52: 4757-64
- Mkrtchyan M, Lujan BJ, Merino D, Thirkill CE, Roorda A, Duncan JL. 2012. Outer retinal structure in patients with acute zonal occult outer retinopathy. *American Journal of Ophthalmology* 153: 757-68, 68
- Morgan JJ, Han G, Klinman E, Maguire WM, Chung DC, et al. 2014. High-resolution adaptive optics retinal imaging of cellular structure in choroideremia. *Invest Ophthalmol.Vis.Sci.* 55: 6381-97
- Mrejen S, Gallego-Pinazo R, Wald KJ, Freund KB. 2013. Acute posterior multifocal placoid pigment epitheliopathy as a choroidopathy: what we learned from adaptive optics imaging. *JAMA Ophthalmol.* 131: 1363-64
- Mrejen S, Pang CE, Sarraf D, Goldberg NR, Gallego-Pinazo R, et al. 2014a. Adaptive optics imaging of cone mosaic abnormalities in acute macular neuroretinopathy. *Ophthalmic surgery, lasers & imaging retina* 45: 562-9
- Mrejen S, Sato T, Curcio CA, Spaide RF. 2014b. Assessing the cone photoreceptor mosaic in eyes with pseudodrusen and soft Drusen in vivo using adaptive optics imaging. *Ophthalmology* 121: 545-51
- Muthiah MN, Keane PA, Zhong J, Gias C, Uppal G, et al. 2014. Adaptive optics imaging shows rescue of macula cone photoreceptors. *Ophthalmology* 121: 430-31
- Nakao S, Kaizu Y, Yoshida S, Iida T, Ishibashi T. 2014. Spontaneous remission of acute zonal occult outer retinopathy: follow-up using adaptive optics scanning laser ophthalmoscopy. *Graefes Arch.Clin.Exp.Ophthalmol.:* [Epub ahead of print]
- Obata R, Yanagi Y. 2014. Quantitative analysis of cone photoreceptor distribution and its relationship with axial length, age, and early age-related macular degeneration. *PLoS One* 9: e91873
- Ooto S, Hangai M, Sakamoto A, Tsujikawa A, Yamashiro K, et al. 2010. High-resolution imaging of resolved central serous chorioretinopathy using adaptive optics scanning laser ophthalmoscopy. *Ophthalmology* 117: 1800-9, 09
- Ooto S, Hangai M, Takayama K, Arakawa N, Tsujikawa A, et al. 2011a. High-resolution photoreceptor imaging in idiopathic macular telangiectasia type 2 using adaptive optics scanning laser ophthalmoscopy. *Invest Ophthalmol.Vis.Sci.* 52: 5541-50
- Ooto S, Hangai M, Takayama K, Sakamoto A, Tsujikawa A, et al. 2011b. High-resolution imaging of the photoreceptor layer in epiretinal membrane using adaptive optics scanning laser ophthalmoscopy. *Ophthalmology* 118: 873-81
- Ooto S, Hangai M, Takayama K, Ueda-Arakawa N, Hanebuchi M, Yoshimura N. 2012. Photoreceptor damage and foveal sensitivity in surgically closed macular holes: an adaptive optics scanning laser ophthalmoscopy study. *American Journal of Ophthalmology* 154: 174-86
- Ooto S, Hangai M, Takayama K, Ueda-Arakawa N, Makiyama Y, et al. 2014. High-resolution imaging of photoreceptors in macular microholes. *Invest Ophthalmol.Vis.Sci.* 55: 5932-43

- Ooto S, Hangai M, Takayama K, Ueda-Arakawa N, Tsujikawa A, et al. 2013. Comparison of cone pathologic changes in idiopathic macular telangiectasia types 1 and 2 using adaptive optics scanning laser ophthalmoscopy. *American Journal of Ophthalmology* 155: 1045-57
- Ooto S, Hangai M, Yoshimura N. 2011c. Photoreceptor restoration in unilateral acute idiopathic maculopathy on adaptive optics scanning laser ophthalmoscopy. *Archives of Ophthalmology* 129: 1633-35
- Pang CE, Suqin Y, Sherman J, Freund KB. 2015. New insights into stargardt disease with multimodal imaging. *Ophthalmic surgery, lasers & imaging retina* 46: 257-61
- Paques M, Miloudi C, Kulcsar C, Leseigneur A, Chaumette C, Koch E. 2015. High-resolution imaging of gunn's dots. *Retina* 35: 120-4
- Park SP, Hong IH, Tsang SH, Lee W, Horowitz J, et al. 2013. Disruption of the human cone photoreceptor mosaic from a defect in NR2E3 transcription factor function in young adults. *Graefes Arch.Clin.Exp.Ophthalmol.* 251: 2299-309
- Park SP, Lee W, Bae EJ, Greenstein V, Sin BH, et al. 2014. Early Structural Anomalies Observed by High-Resolution Imaging in Two Related Cases of Autosomal-Dominant Retinitis Pigmentosa. *Ophthalmic Surg.Lasers Imaging Retina*: 1-5
- Pinhas A, Razeen M, Dubow M, Gan A, Chui TY, et al. 2014. Assessment of perfused foveal microvascular density and identification of nonperfused capillaries in healthy and vasculopathic eyes. *Invest Ophthalmol Vis Sci* 55: 8056-66
- Pyo PS, Hwan HI, Tsang SH, Chang S. 2013. Cellular imaging demonstrates genetic mosaicism in heterozygous carriers of an X-linked ciliopathy gene. *Eur.J.Hum.Genet.* 21: 1240-48
- Querques G, Kamami-Levy C, Blanco-Garavito R, Georges A, Pedinielli A, et al. 2014. Appearance of medium-large drusen and reticular pseudodrusen on adaptive optics in age-related macular degeneration. *British Journal of Ophthalmology* 98: 1522-27
- Querques G, Massamba N, Guigui B, Lea Q, Lamory B, et al. 2012. In vivo evaluation of photoreceptor mosaic in early onset large colloid drusen using adaptive optics. *Acta Ophthalmol.* 90: e327-e28
- Ratnam K, Vastinsalo H, Roorda A, Sankila EM, Duncan JL. 2013. Cone structure in patients with usher syndrome type III and mutations in the Clarin 1 gene. *JAMA Ophthalmol.* 131: 67-74
- Rha J, Dubis AM, Wagner-Schuman M, Tait DM, Godara P, et al. 2010. Spectral domain optical coherence tomography and adaptive optics: imaging photoreceptor layer morphology to interpret preclinical phenotypes. *Adv.Exp.Med.Biol.* 664: 309-16
- Roorda A, Garcia CA, Martin JA, Poonja S, Queener H, et al. 2006. What can adaptive optics do for a scanning laser ophthalmoscope ? *Bull.Soc.Belge Ophthalmol.:* 231-44
- Rossi EA, Achtman RL, Guidon A, Williams DR, Roorda A, et al. 2013a. Visual function and cortical organization in carriers of blue cone monochromacy. *PLoS One* 8: e57956
- Rossi EA, Rangel-Fonseca P, Parkins K, Fischer W, Latchney LR, et al. 2013b. In vivo imaging of retinal pigment epithelium cells in age related macular degeneration. *Biomed.Opt.Express* 4: 2527-39
- Saleh M, Debellemanniere G, Meillat M, Tumahai P, Bidaut GM, et al. 2014. Quantification of cone loss after surgery for retinal detachment involving the macula using adaptive optics. *British Journal of Ophthalmology* 98: 1343-48
- Scoles D, Higgins BP, Cooper RF, Dubis AM, Summerfelt P, et al. 2014a. Microscopic inner retinal hyper-reflective phenotypes in retinal and neurologic disease. *Invest Ophthalmol.Vis.Sci.* 55: 4015-29
- Scoles D, Sulai YN, Langlo CS, Fishman GA, Curcio CA, et al. 2014b. In vivo imaging of human cone photoreceptor inner segments. *Invest Ophthalmol.Vis.Sci.* 55: 4244-51
- Song H, Latchney L, Williams D, Chung M. 2014. Fluorescence adaptive optics scanning laser ophthalmoscope for detection of reduced cones and hypoautofluorescent spots in fundus albipunctatus. *JAMA Ophthalmol.* 132: 1099-104

- Sredar N, Ivers KM, Queener HM, Zouridakis G, Porter J. 2013. 3D modeling to characterize lamina cribrosa surface and pore geometries using in vivo images from normal and glaucomatous eyes. *Biomed.Opt.Express* 4: 1153-65
- Stepien KE, Han DP, Schell J, Godara P, Rha J, Carroll J. 2009. Spectral-domain optical coherence tomography and adaptive optics may detect hydroxychloroquine retinal toxicity before symptomatic vision loss. *Trans.Am.Ophthalmol.Soc.* 107: 28-33
- Stepien KE, Martinez WM, Dubis AM, Cooper RF, Dubra A, Carroll J. 2012. Subclinical photoreceptor disruption in response to severe head trauma. *Archives of Ophthalmology* 130: 400-02
- Stepushina OA, Bol'shunov AV. 2011. [Combination of measurement of retinal vascular caliber, adaptive optics and fluorescent angiography in early diagnosis and monitoring of diabetic and hypertensive retinopathy]. *Vestn.Oftalmol.* 127: 29-31
- Sundaram V, Wilde C, Aboshiha J, Cowing J, Han C, et al. 2014. Retinal structure and function in achromatopsia: implications for gene therapy. *Ophthalmology* 121: 234-45
- Syed R, Sundquist SM, Ratnam K, Zayit-Soudry S, Zhang Y, et al. 2013. High-resolution images of retinal structure in patients with choroideremia. *Invest Ophthalmol.Vis.Sci.* 54: 950-61
- Takayama K, Ooto S, Hangai M, Arakawa N, Oshima S, et al. 2012. High-resolution imaging of the retinal nerve fiber layer in normal eyes using adaptive optics scanning laser ophthalmoscopy. *PLoS One* 7: e33158
- Tam J, Dhamdhere KP, Tiruveedhula P, Lujan BJ, Johnson RN, et al. 2012. Subclinical capillary changes in non-proliferative diabetic retinopathy. *Optometry and Vision Science* 89: E692-E703
- Tam J, Dhamdhere KP, Tiruveedhula P, Manzanera S, Barez S, et al. 2011. Disruption of the retinal parafoveal capillary network in type 2 diabetes before the onset of diabetic retinopathy. *Invest Ophthalmol Vis Sci* 52: 9257-66
- Telander DG, Choi SS, Zawadzki RJ, Berger N, Keltner JL, Werner JS. 2010. Microstructural Abnormalities Revealed by High Resolution Imaging Systems in Central Macular Arteriovenous Malformation. *Ophthalmic Surg.Lasers Imaging*: 1-4
- Tojo N, Nakamura T, Ozaki H, Oka M, Oiwake T, Hayashi A. 2013. Analysis of macular cone photoreceptors in a case of occult macular dystrophy. *Clin.Ophthalmol.* 7: 859-64
- Vincent A, Wright T, Garcia-Sanchez Y, Ksilak M, Campbell M, et al. 2013a. Phenotypic characteristics including in vivo cone photoreceptor mosaic in KCNV2-related "cone dystrophy with supernormal rod electroretinogram". *Invest Ophthalmol.Vis.Sci.* 54: 898-908
- Vincent AL, Carroll J, Fishman GA, Sauer A, Sharp D, et al. 2013b. F45L Allele Does Not Cause Autosomal Dominant Retinitis Pigmentosa in a Large Caucasian Family. *Transl.Vis.Sci.Technol.* 2: 4
- Wagner-Schuman M, Neitz J, Rha J, Williams DR, Neitz M, Carroll J. 2010. Color-deficient cone mosaics associated with Xq28 opsin mutations: a stop codon versus gene deletions. *Vision Research* 50: 2396-402
- Wang Q, Tuten WS, Lujan BJ, Holland J, Bernstein PS, et al. 2015. Adaptive Optics Microperimetry and OCT Images Show Preserved Function and Recovery of Cone Visibility in Macular Telangiectasia Type 2 Retinal Lesions. *Invest Ophthalmol Vis Sci* 56: 778-86
- Werner JS, Keltner JL, Zawadzki RJ, Choi SS. 2011. Outer retinal abnormalities associated with inner retinal pathology in nonglaucomatous and glaucomatous optic neuropathies. *Eye (Lond)* 25: 279-89
- Wilk MA, McAllister JT, Cooper RF, Dubis AM, Patitucci TN, et al. 2014. Relationship between foveal cone specialization and pit morphology in albinism. *Invest Ophthalmol.Vis.Sci.* 55: 4186-98
- Wolfing JI, Chung M, Carroll J, Roorda A, Williams DR. 2006. High-Resolution Retinal Imaging of Cone-Rod Dystrophy. *Ophthalmology* 113: 1014-19
- Xue B, Choi SS, Doble N, Werner JS. 2007. Photoreceptor counting and montaging of en-face retinal images from an adaptive optics fundus camera. *J.Opt.Soc.Am.A Opt.Image Sci.Vis.* 24: 1364-72

- Yokota S, Ooto S, Hangai M, Takayama K, Ueda-Arakawa N, et al. 2013. Objective assessment of foveal cone loss ratio in surgically closed macular holes using adaptive optics scanning laser ophthalmoscopy. *PLoS One* 8: e63786
- Yoon MK, Roorda A, Zhang Y, Nakanishi C, Wong LJ, et al. 2009. Adaptive optics scanning laser ophthalmoscopy images in a family with the mitochondrial DNA T8993C mutation. *Invest Ophthalmol.Vis.Sci.* 50: 1838-47
- Zayit-Soudry S, Duncan JL, Syed R, Menghini M, Roorda AJ. 2013. Cone structure imaged with adaptive optics scanning laser ophthalmoscopy in eyes with nonneovascular age-related macular degeneration. *Invest Ophthalmol.Vis.Sci.* 54: 7498-509
- Zhang Y, Wang X, Rivero EB, Clark ME, Witherspoon CD, et al. 2014. Photoreceptor perturbation around subretinal drusenoid deposits as revealed by adaptive optics scanning laser ophthalmoscopy. *American Journal of Ophthalmology* 158: 584-96