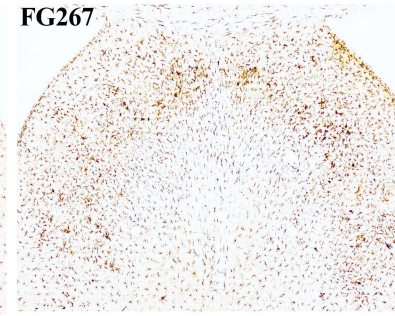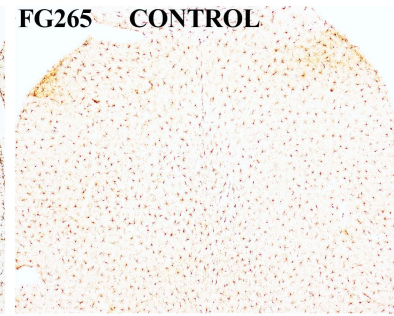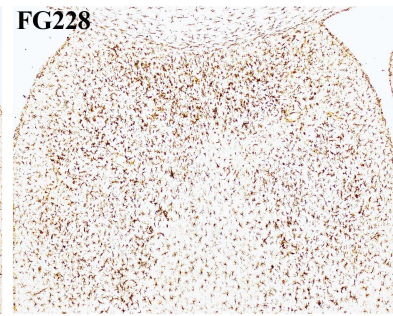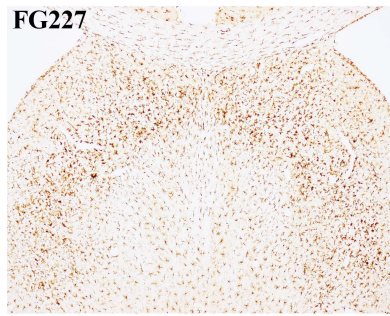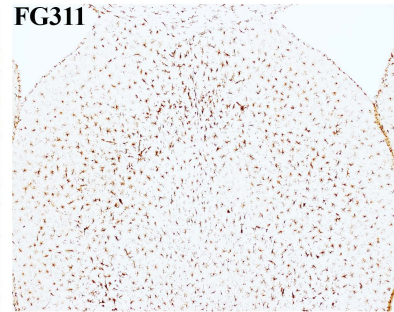
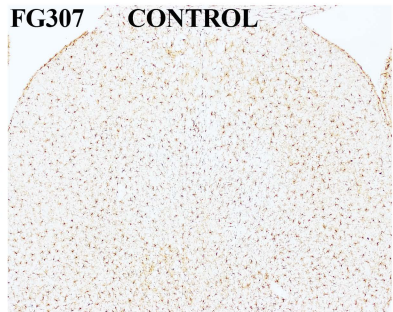
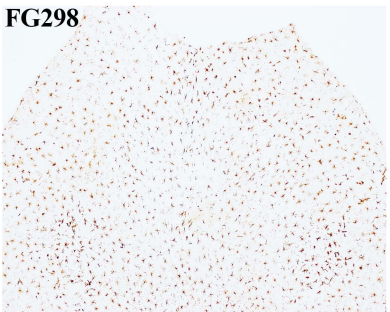
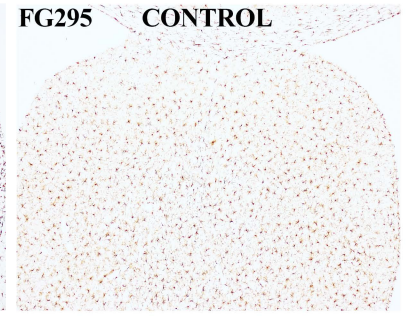
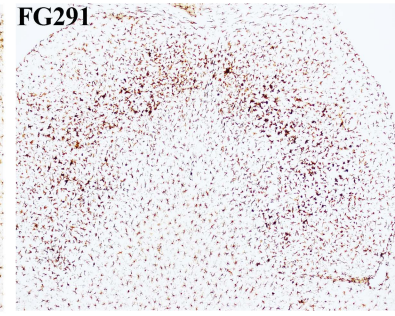
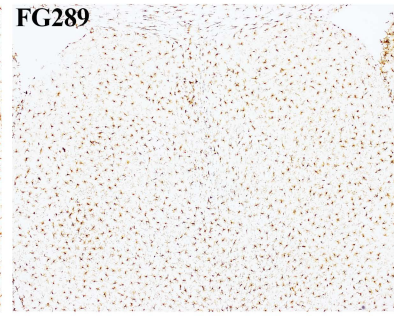
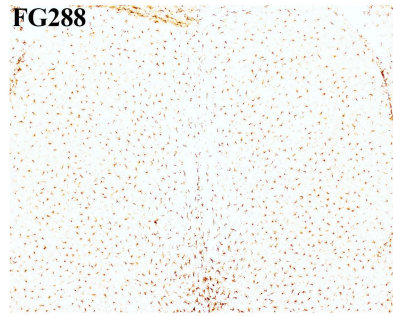

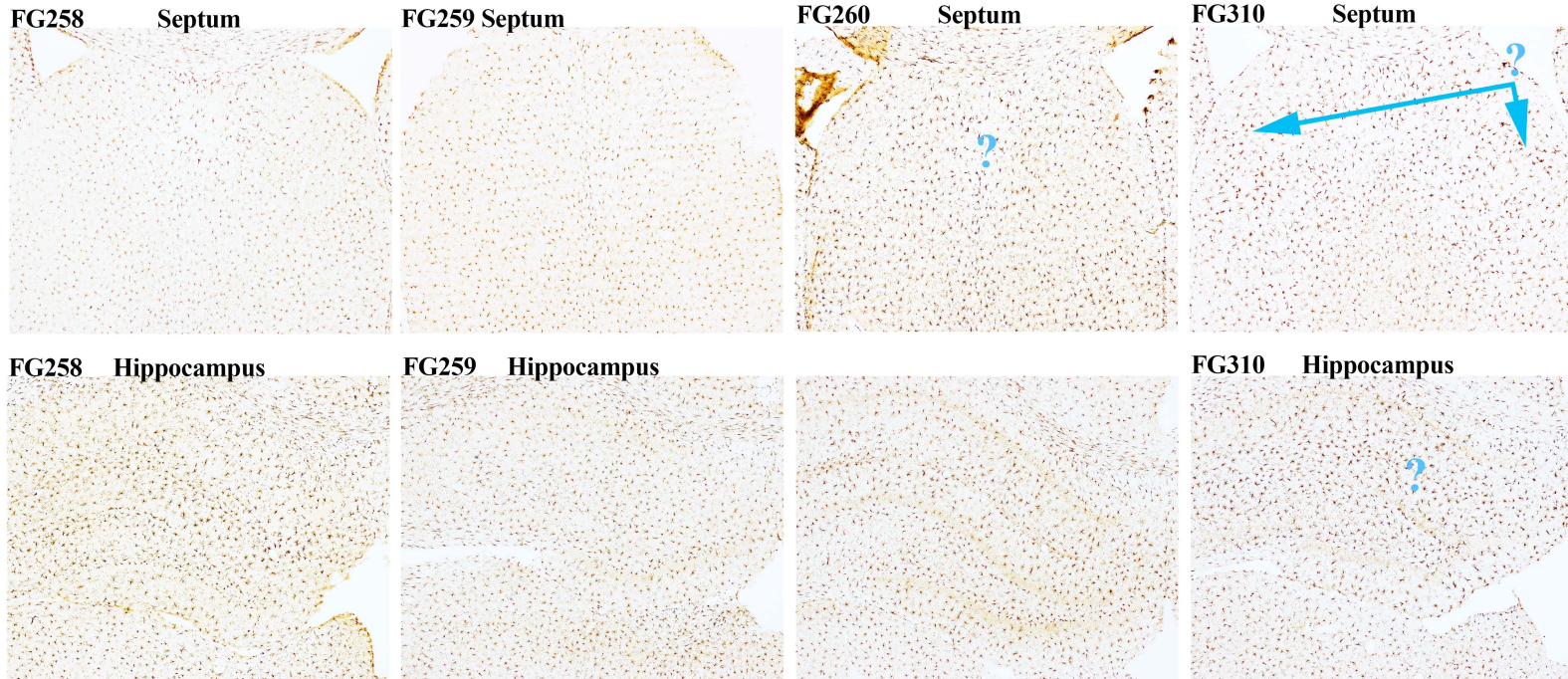


**FG268**





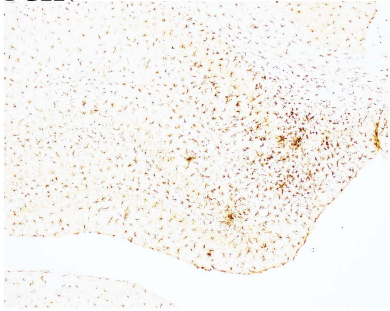


**Question marks in figure indicate that the overall size of the soma of the microglia may have increased. However, the shape/ morphology of the microglia are similar to control. The arrows in the septum of FG310 point to regions where the shape/ morphology of the microglia are more like those associated with vasculature in regions where vascular disruption likely occurred.**

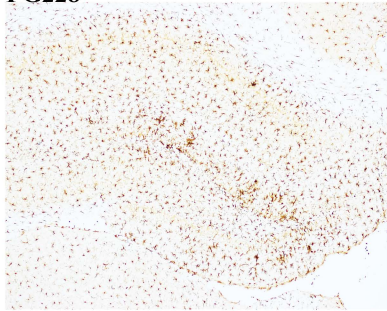


*Supplemental Figure 2A*

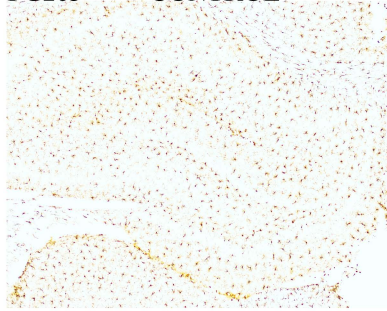
**FG227**



**FG228**

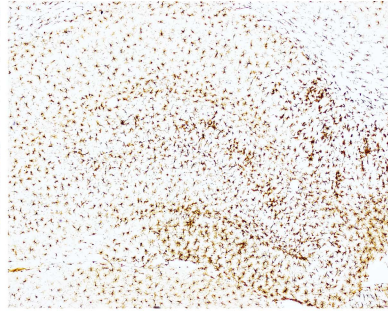


**FG265**

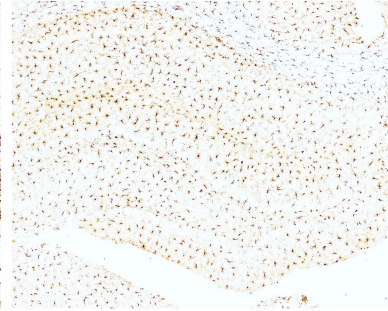


**CONTROL**

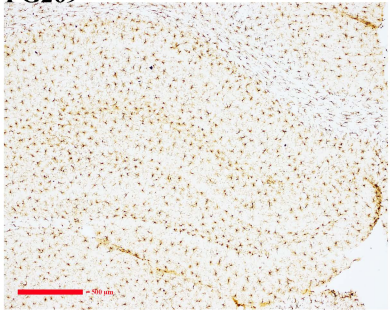
**FG267**



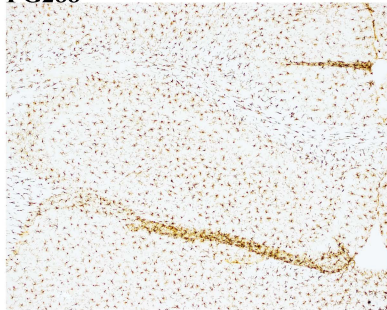
**FG268**



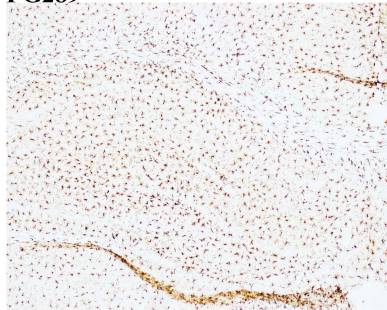
**FG269**



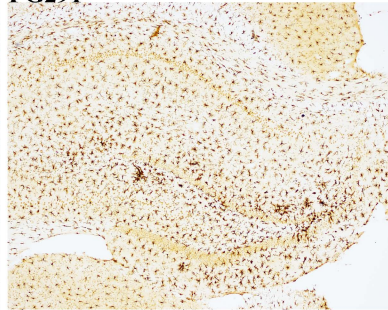
**FG288**



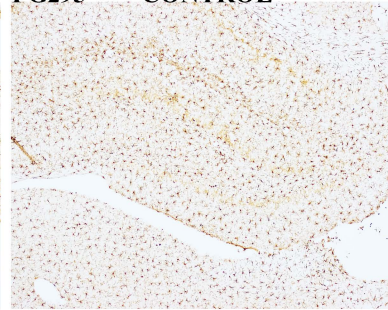
**FG289**



**FG291**

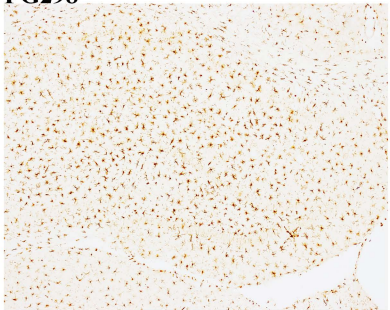


**FG295**

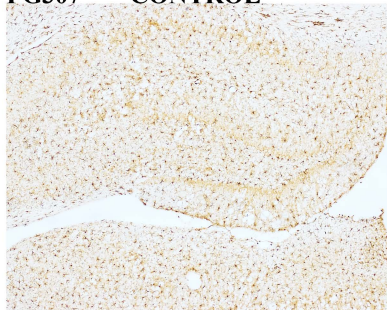


**CONTROL**

**FG298**

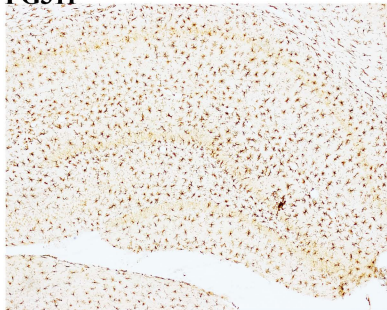


**FG307**



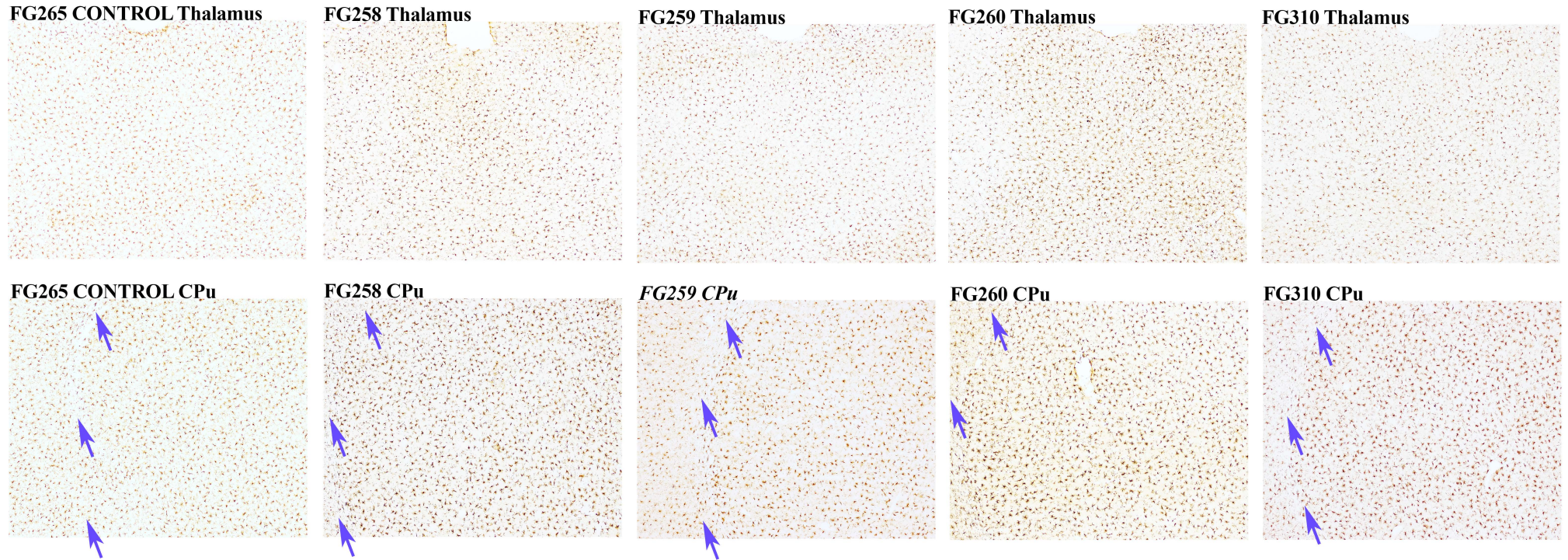
**CONTROL**

**FG311**



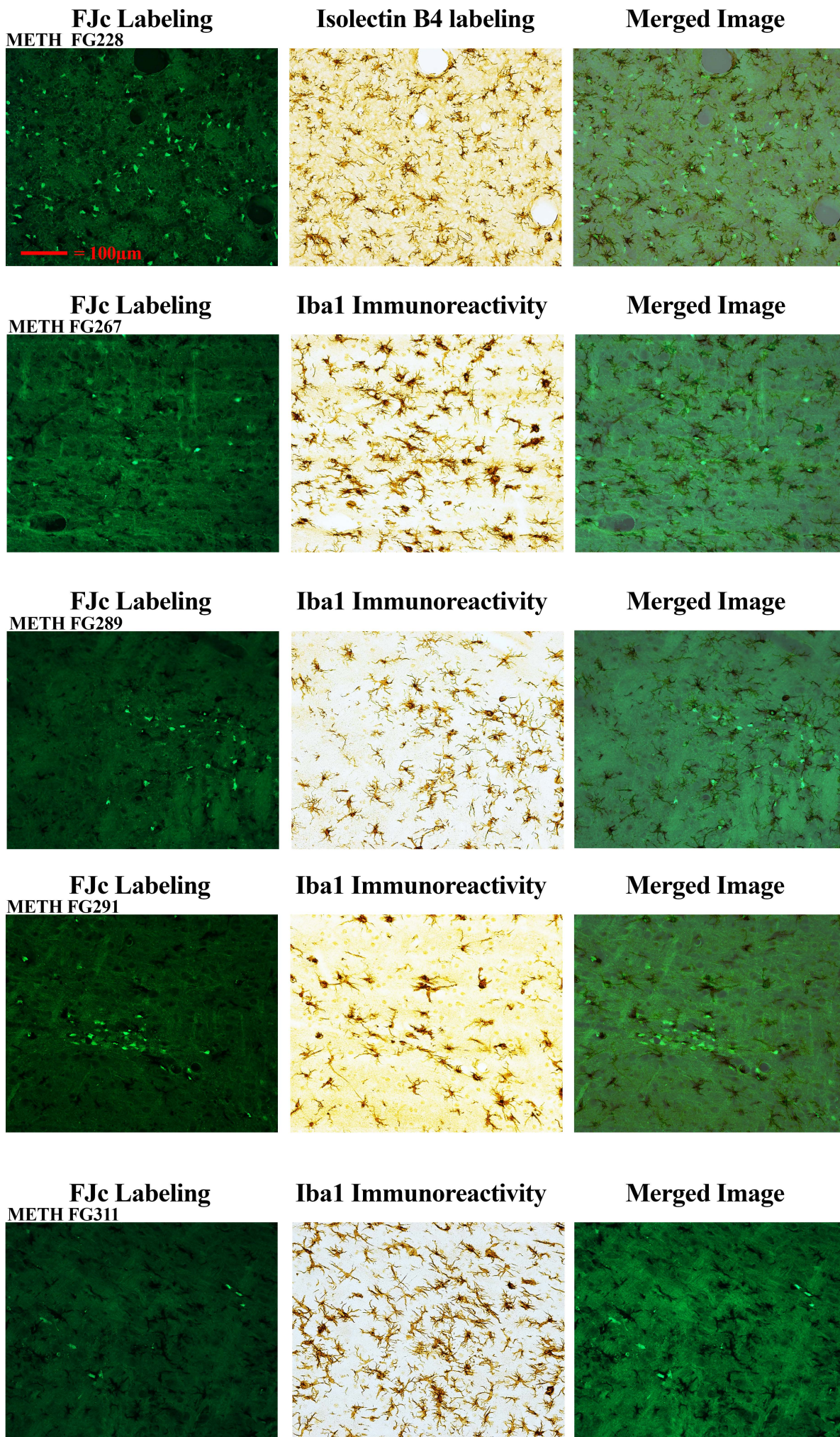


*Supplemental Figure 2B*



*Arrows indicate the position of the corpus callosum situated between the cortex and the lateral CPu. Note that in the METH treated rats that the microglia are larger in the CPu than the cortex, which is not the case in the control.*



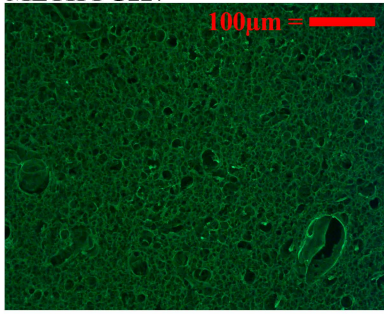


Neurodegeneration in the ventrolateral and or ventromedial thalamic nuclei was detected via FJc-labeling in the left-most column of panels while microglia activation is seen with DAB-Iba1 immunolabeling in the middle column of panels at 3 days after METH. The merger of the two images is shown in the right-most column of panels. Magnification is the same for all the panels shown. See magnification bar in top left panel.



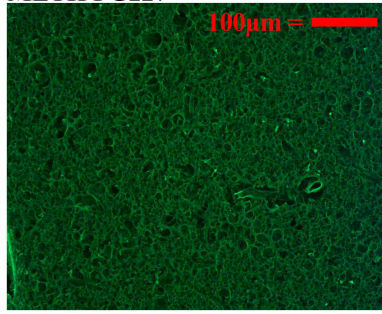
**Dorsolateral Septum**

METH FG227

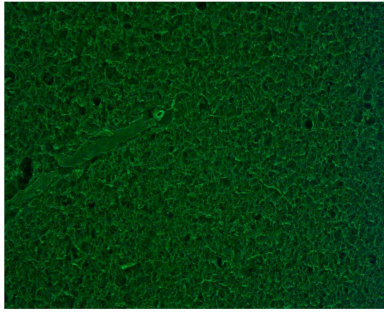


**Centrolateral Septum**

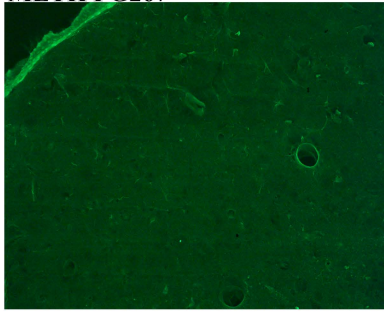
METH FG227



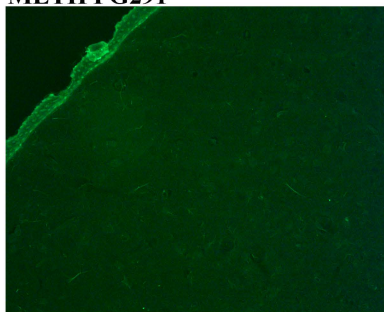
METH FG228



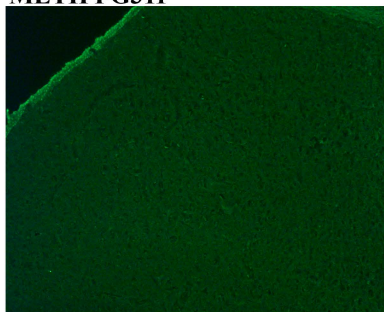
METH FG267



METH FG291

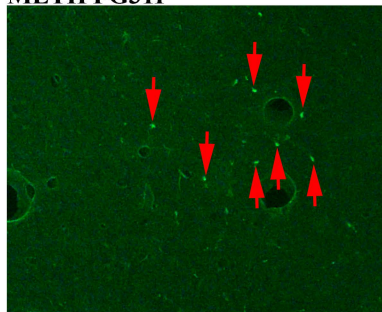


METH FG311



**Ventromedial Septum**

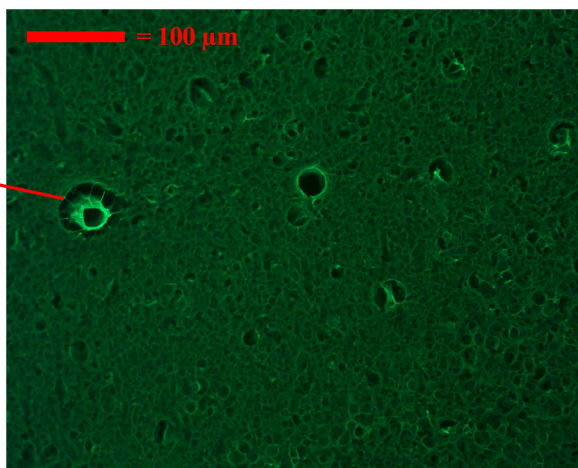
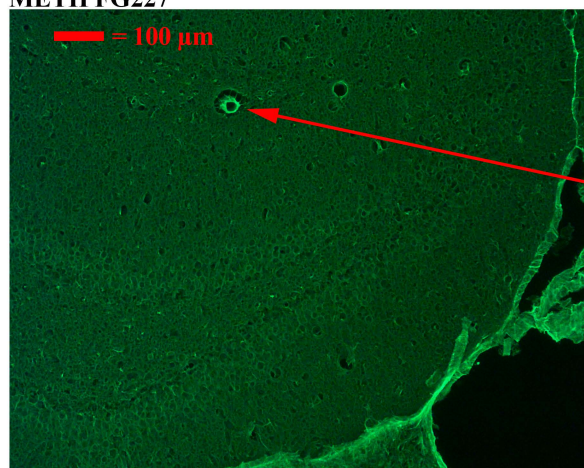
METH FG311




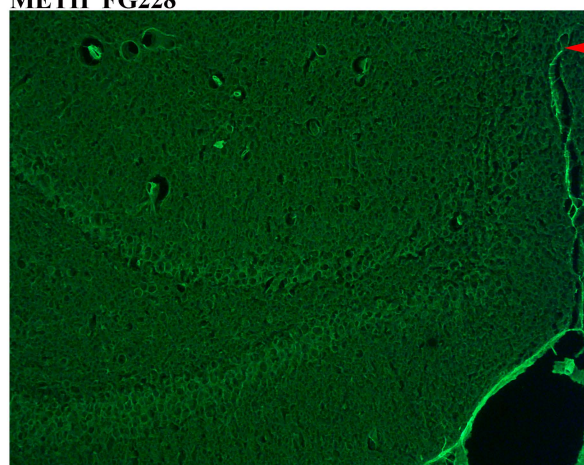
FJc images of the dorsolateral septum are shown in the left-most column at 3 d after METH. There is faint labeling in the FG227 rat that is most likely due to vasculature and not degenerated axons or dendrites the FJc labeling in the ventromedial septum of FG311 may be due to degenerating axons or dendrites. All panels are of the same magnifications (see upper-most panels).





METH FG227




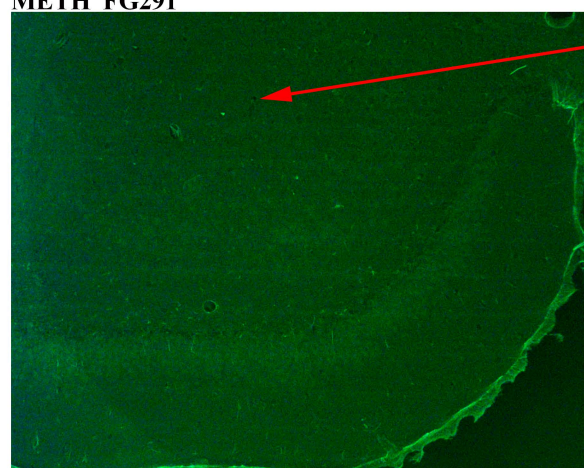
METH FG228



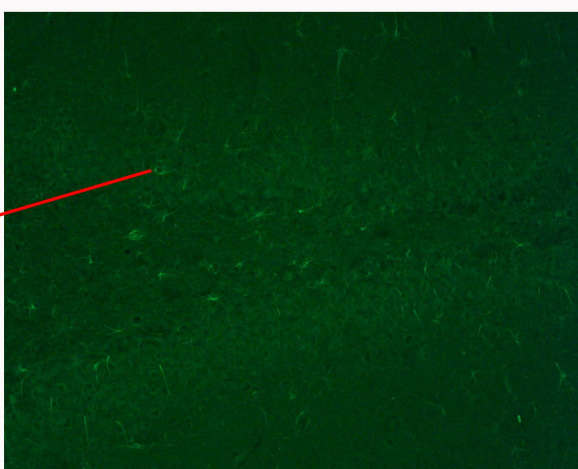
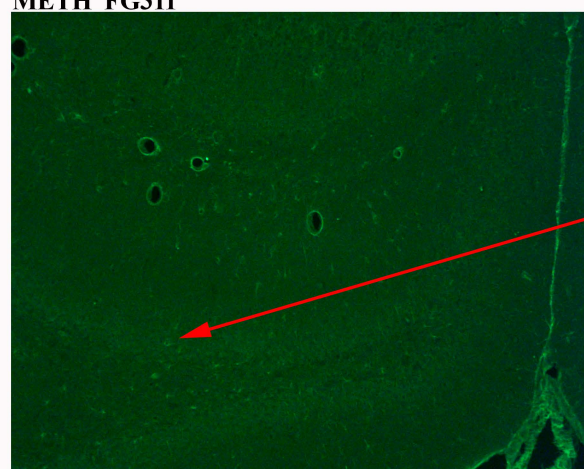
METH FG267



METH FG291



METH FG311




**FJc labeling in the anterior medial hippocampus at two different magnifications at 3 d after METH. The red arrows are for orientation of two magnifications of the same area. The blue arrows in FG291 appear to be related to vasculature. Note that in FG311 ghost like structures that are not neuroal in origin are seen. These may or may not be faint labeling of astrocytes. It is important to note that none of the FJc labeled structures would be visible/ labeled if the more stringent methods of of Schmued et al would have been used.**

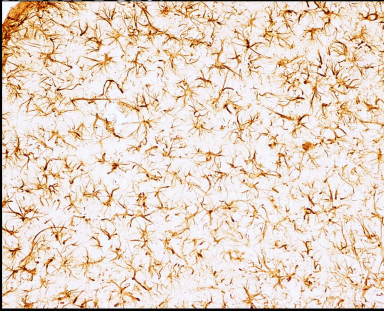


## Dorsal Septum

Control FG265

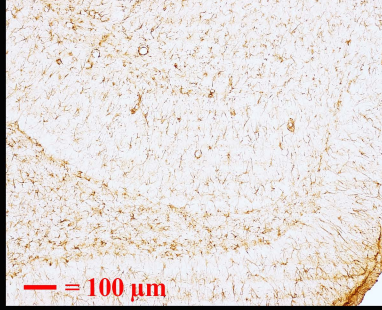


METH FG267

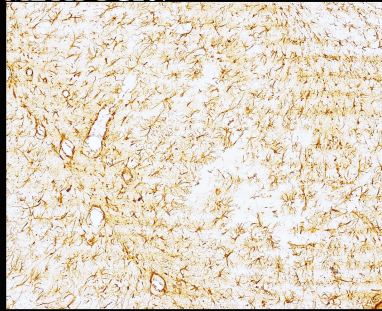


## Hippocampus

Control FG265

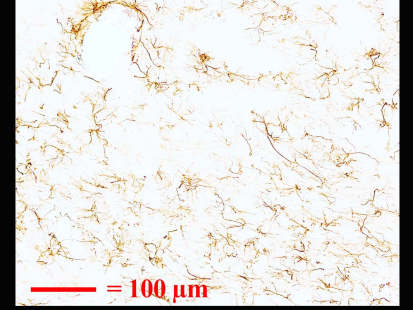


METH FG267



## VL/VM Thalamus

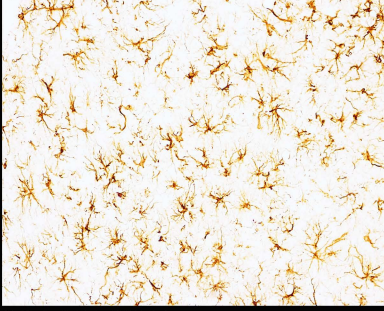
Control FG265



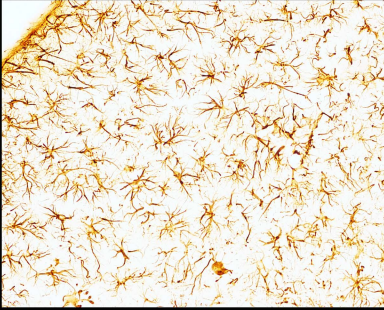METH FG267



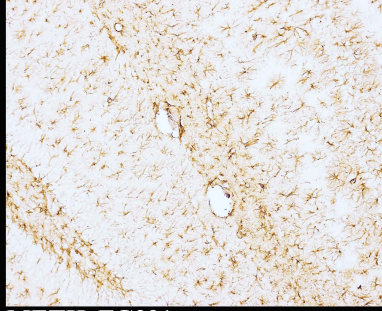
Control FG295



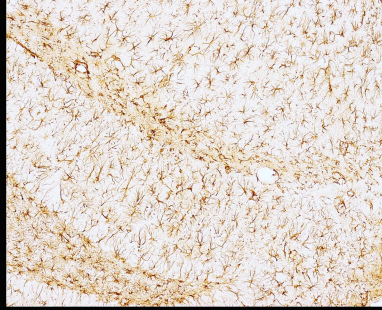
METH FG291



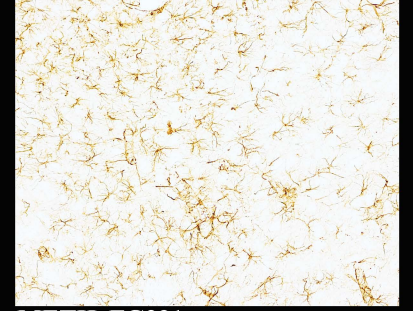Control FG295



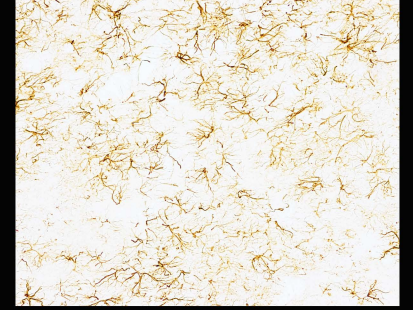
METH FG291



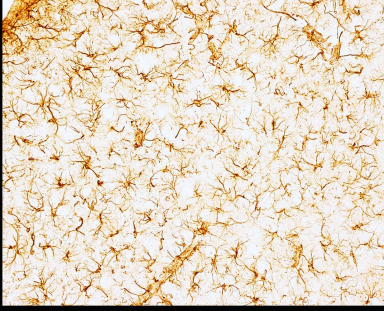
Control FG295



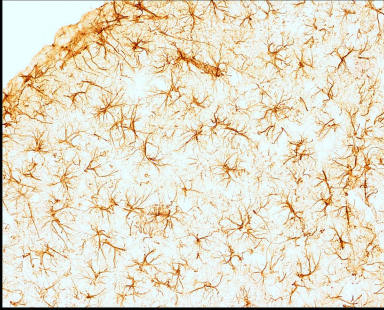
METH FG291



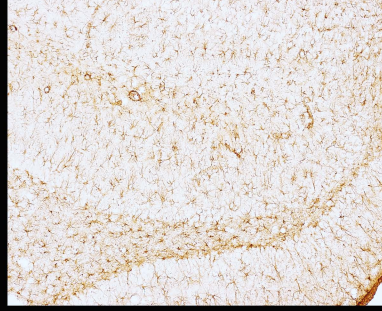
Control FG307



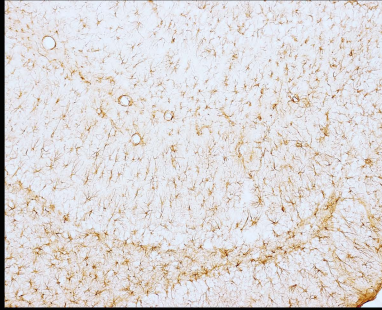
METH FG311



Control FG307



METH FG311



Control FG307



METH FG311



DAB-GFAP immunolabeling of astrocytes is seen in; the septum in left-most column of panels, the hippocampus in the center column of panels, and the ventrolateral thalamus in the right-most column of panels. Note that the magnification for the hippocampal sections is half of the septum and thalamus. This is because the types of astrocytes are so much more diverse in the hippocampus and not well represented at the higher magnification. Magnifications for each panel in the column are the