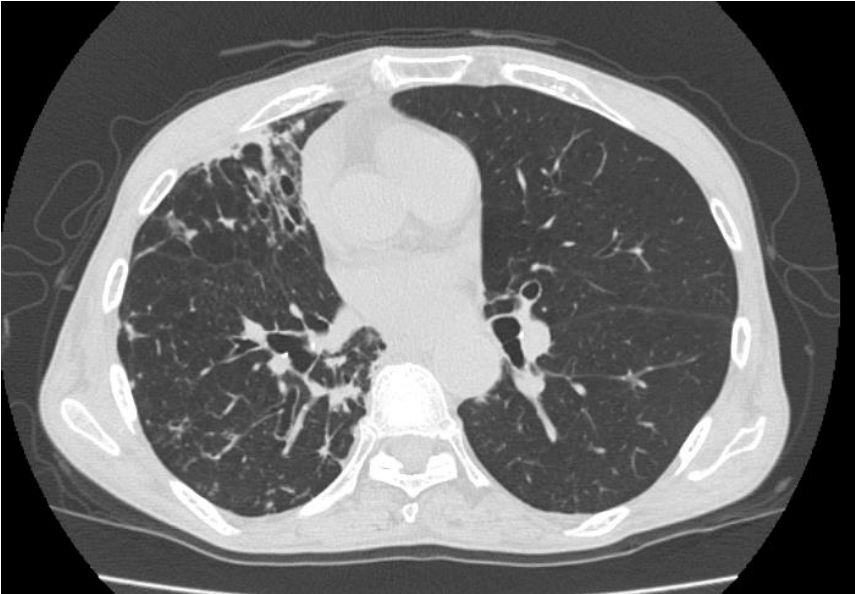


Additional file 1: Figure S1

Representative CT images of airway lesion dominant and IP dominant patterns.

A Airway lesion dominant



B Interstitial pneumonia dominant

