

THE ANGIOCARDIOGRAM IN FALLOT'S TETRALOGY

BY

JAMES B. LOWE

From the Institute of Cardiology, London

Received February 16, 1953

While the principal angiocardio-graphic features of the tetralogy of Fallot have been listed by many authors, the number of cases described in detail or illustrated is relatively small. Recently Dotter and Steinberg (1951) reviewing the subject emphasized the need for further observations with necropsy control in cyanotic congenital heart disease.

A final clinical diagnosis of Fallot's tetralogy was made in nearly one-third of the first 160 patients investigated by angiocardio-graphy at the National Heart Hospital and at the Brompton Hospital. The results in this group have been analysed, and the appearances correlated with such surgical and post-mortem findings as were available.

Technique. Although slightly modified, the technique employed was essentially that described by Robb and Steinberg (1939). Diodone was injected through a wide-bore plastic cannula introduced into the median cubital vein. Venous pooling of contrast material was reduced by advancing the cannula tip to the subclavian vein; and by injecting, immediately after the diodone, 10 to 15 ml. of saline previously layered above it in the syringe. Since 1948 when Dr. M. McGregor devised a perforated plastic disc for introduction between diodone and saline during the loading of the syringe, this method of preventing mixing before the injection has been routinely employed. The injection of one ml. of 70 per cent diodone per kg. body weight usually took less than two seconds.

The hand-operated multiple-cassette changer at the Brompton Hospital was constructed by McGregor (1949), and that used at the National Heart Hospital was a modified copy of this machine. The patient was recumbent, and with either apparatus it was possible to expose nine films in six seconds. Anode-film distance was 48 inches.

With few exceptions the investigation was performed under thiopentone anaesthesia.

MATERIAL AND METHOD

Fifty patients with Fallot's tetralogy were investigated. The diagnosis was supported in twenty-nine by the results of cardiac catheterization, and in thirty-one by the findings at operation, which included a direct attack on the site of stenosis in fifteen. In six cases necropsy confirmation was eventually obtained. At the time of this study there remained six cases where the diagnosis rested entirely on clinical and angiocardio-graphic evidence; but in none of these was there any reasonable doubt as to the nature of the malformation.

The following analysis refers, except where otherwise indicated, to the appearances in the antero-posterior view. Films in this projection were available in 47 cases, while oblique or lateral angiocardio-graphs were taken in 12 only.

The interpretations were subject to certain limitations. The relatively slow operating speed of the cassette changers introduced a possible error of approximately 0.7 sec. in the timing of events. No attempt was made to measure the size of the right ventricle or infundibulum, for the exact phase of the cardiac cycle at which a film had been exposed was not known. It was necessary to assess the size of the pulmonary arteries in an arbitrary fashion as large or normal or small, because normal standards for the calibre of these vessels have not been established under comparable conditions;

though measurements made from angiocardiograms taken at an anode-film distance of 72 inches have been published (Dotter and Steinberg, 1949).

THE APPEARANCES IN FALLOT'S TETRALOGY

While films that demonstrate both a right to left shunt and pulmonary stenosis are not necessarily diagnostic of Fallot's tetralogy, these are the basic angiocardiographic appearances of the malformation.

The Shunt. In most cases a right to left shunt was shown by early opacification of the proximal thoracic aorta. Occasionally premature aortic filling was not convincingly demonstrated and the only certain evidence of the small shunt was faint opacification of a subclavian artery (Fig. 1), a sign emphasized by Campbell and Hills (1950). In these circumstances filling of the systemic vessel

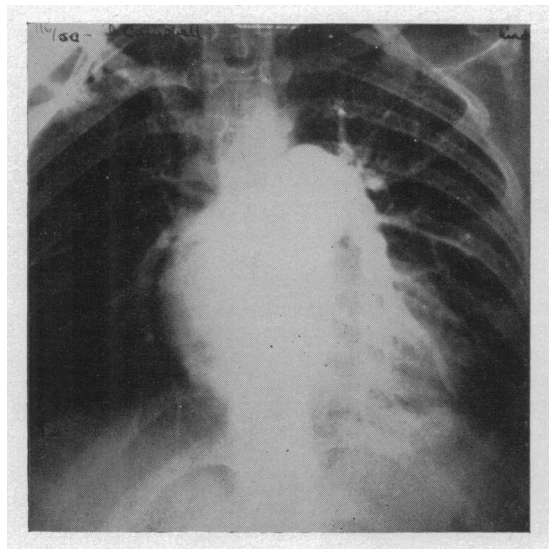


FIG. 1.—Fallot's tetralogy. Stenosis believed to be valvular at Blalock-Taussig operation. Angiocardiogram at 2 seconds showing pulmonary arterial enlargement. There is some opacification of the left subclavian artery.

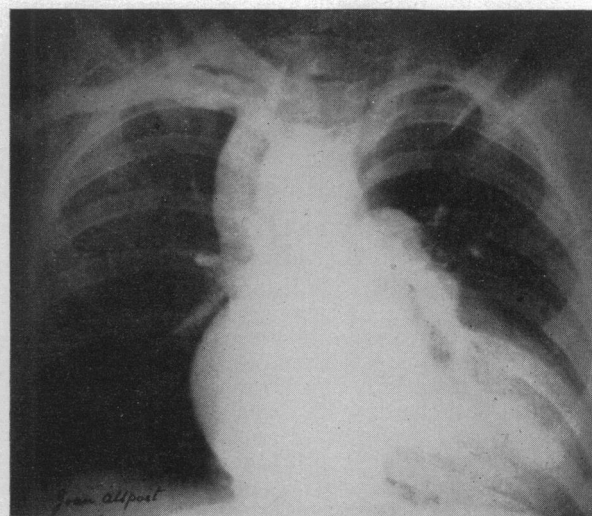


FIG. 2.—Fallot's tetralogy. Stenosis believed to be subvalvular at Blalock-Taussig operation. Angiocardiogram at 2 seconds. An infundibular chamber is shown. The aortic arch is right-sided.

might not be visible until the second film to show diodone in the pulmonary artery; but in all other cases both the aorta and the pulmonary artery were first visualized in the same film.

It is widely recognized that premature opacification of the left ventricle may occur in Fallot's tetralogy (Sussman and Grishman, 1947; Ulfsparré, 1949; Dotter and Steinberg, 1951); but this was seen in fewer than half the cases in the present series. When visible, early left ventricular opacification was usually faint, but it was of moderate density in four cases, one of which is illustrated in Fig. 3.

The Stenosis. The site of stenosis was seldom directly visualized, but the demonstration of an infundibular chamber (Fig. 2) sometimes provided conclusive though indirect evidence of stenosis. With the technique employed, however, it is unusual for the infundibulum to be well filled, not only in Fallot's tetralogy (Cooley *et al.*, 1949), but also in normal subjects (Dotter and Steinberg, 1949); and, as Thompson *et al.* (1949) emphasized, a single film may give a false impression of infundibular narrowing. On the other hand visualization of an apparently normal right ventricular outflow tract and pulmonary valve area does not exclude pulmonary stenosis (Dotter and Steinberg, 1951). Features that might indirectly indicate pulmonary stenosis were therefore sought. Attention was

directed to the size of the pulmonary arteries and to the time of onset and the density and duration of opacification of these vessels.

Reduction in calibre of the pulmonary arterial tree sometimes suggested the presence of stenosis (Fig. 3); but not infrequently the major arteries were normal in size or even enlarged (Fig. 1), and often no convincing abnormality of the lung vascular pattern could be detected. Campbell and Hills (1950) found that pulmonary stenosis did not delay filling of the pulmonary arteries, and this was confirmed; in no case was opacification of these vessels shown to occur later than that of the aorta. Moreover, in spite of the stenosis the pulmonary arteries were usually densely opacified. Delayed emptying of the pulmonary vessels has been noted in the presence of pulmonary stenosis (Ulfsparre, 1949; Campbell and Hills, 1950; Cooley, 1951). In the present series the duration of opacification of the major pulmonary arteries tended to be greater in both Fallot's tetralogy and pulmonary stenosis with intact ventricular septum than in control subjects (Fig. 4). The overlapping of the groups may be partly due to the younger ages of those with pulmonary stenosis, for the circulation of diodone is normally more rapid in children than in adults (Steinberg *et al.*, 1943). Undue persistence of diodone in the lung vessels may, however, also occur in mitral stenosis (Angelino and Actis Dato, 1952), in the Eisenmenger complex (Campbell and Hills, 1950; Cooley, 1951; Soulié *et al.*, 1951*b*), and in other conditions associated with a severe pulmonary hypertension (Fig. 4).

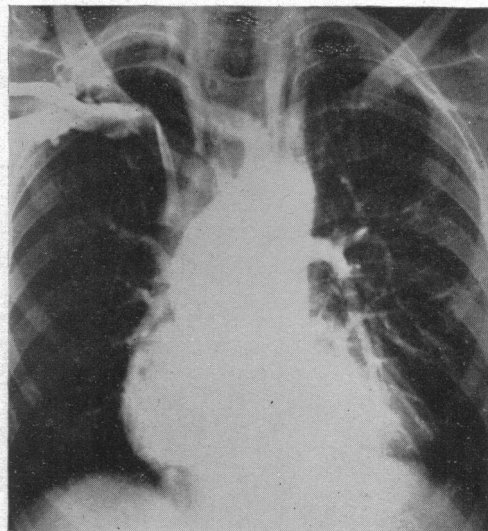


FIG. 3.—Fallot's tetralogy. Angiocardiogram at $2\frac{1}{2}$ seconds. The pulmonary arteries are small but well opacified. There is considerable early filling of the left ventricle.

OTHER FINDINGS OF ANATOMICAL OR PHYSIOLOGICAL SIGNIFICANCE

Right Ventricular Hypertrophy. Hypertrophy of the right ventricle was included by Carson *et al.* (1948) and by others who have listed the angiocardigraphic findings in Fallot's tetralogy. In the present series evidence for this in antero-posterior films was unconvincing. In such lateral or oblique angiocardigrams as were available the interventricular septum was sometimes convex to the left, a sign of right ventricular hypertrophy put forward by Sussman *et al.* (1942); but it was not always possible to distinguish this border from the posterior margin of the right atrium.

Dextroposition of the Aorta. Usually the position of the base of the aorta in antero-posterior films gave no real indication of the presence, let alone the degree, of anatomical aortic override. The density of early aortic opacification was not accepted as evidence of the anatomical relations of the aortic orifice; it merely reflected the size of the shunt under angiocardigraphic conditions.

Vascular Abnormalities. There was a right-sided aortic arch in six patients, but the other anomalies of the great vessels found in coincidental association with the tetralogy of Fallot will not be enumerated. Those involving the aorta and its branches caused no difficulty in interpretation. The significance of apparent malformations of the major pulmonary arteries was less readily determined. Cooley *et al.* (1949) pointed out that failure to demonstrate one of these by angiocardiology does not disprove its existence. In one case the films strongly suggested, and necropsy later confirmed, absence of the left pulmonary artery; the right pulmonary artery passed posteriorly before turning to cross the mid-line, and in the lateral view this was responsible for a shadow

suggesting a blind diverticulum at the site of origin of the left pulmonary artery (Fig. 5): bronchial arteries supplied the left lung but were not visible in the angiocardioqram.

Large bronchial arteries arising from the aorta were seen only in patients believed to have pulmonary atresia and therefore excluded from this discussion; but in some cases of Fallot's tetralogy the lung vascular pattern showed features indicative of an increased bronchial blood supply (Campbell and Gardner, 1950). Occasionally the internal mammary arteries were prominent, and in one case large tortuous intercostal arteries on the left side were associated with slight unilateral rib notching (Fig. 6). At the age of ten this thirty-year-old patient had had a respiratory infection in the course of which fluid was removed from the left pleural cavity; he maintained that during the succeeding months his cyanosis had lessened and his exercise tolerance had improved considerably.

The Site of the Stenosis. The development of intra-cardiac surgery (Brock, 1948; Brock and Campbell, 1950) as an alternative to the anastomotic operation (Blalock and Taussig, 1945) has

DIAGNOSIS	NO. CASES	AV AGE (RANGE)	DURATION OF PA. OPACIFICATION (SECS.)				
			<2	2-3	3-4	4-5	>5
NORMAL CONTROLS	12	32 (17-47)					
FALLOTS TETRALOGY	47	13 (3-32)					
PULMONARY STENOSIS	11	19 (4-38)					
EISENMENGER COMPLEX	5	18 (6-29)					
PULMONARY HYPERTENSION	10	26 (8-39)					

FIG. 4.—Duration of opacification of left or right pulmonary artery, whichever was the more readily visible, in (1) normal controls, (2) Fallot's tetralogy, (3) pulmonary stenosis with intact ventricular septum, (4) Eisenmenger's complex, and (5) severe pulmonary hypertension. In some cases of group (5) this was associated with patent ductus arteriosus through which flow was reversed; in others a ventricular septal defect was suspected but not proven. In both pulmonary stenosis and pulmonary hypertension, whether the ventricular septum was defective or intact, opacification of the pulmonary arteries tended to persist for longer than in normal subjects.

made the precise determination of the site of stenosis in Fallot's tetralogy a matter of some importance. Selective angiocardioqramy (Jönsson *et al.*, 1949; Soulié *et al.*, 1951*b*) would seem to be the most effective technique for revealing the detailed anatomy of the obstruction, but it was of interest to discover how much information could be obtained from intravenous angiocardioqrams. Of the 18 cases where the level of stenosis was determined at direct operation or at necropsy, it was valvular in 8 and subvalvular in 9: in the remaining one necropsy revealed a high infundibular obstruction, with a small infundibular chamber, and also a tight valvular stenosis.

In three cases with proven subvalvular stenosis there was clear evidence of the level of stenosis. In two (Fig. 5 and 7) an infundibular chamber was demonstrated, and in the third there was an

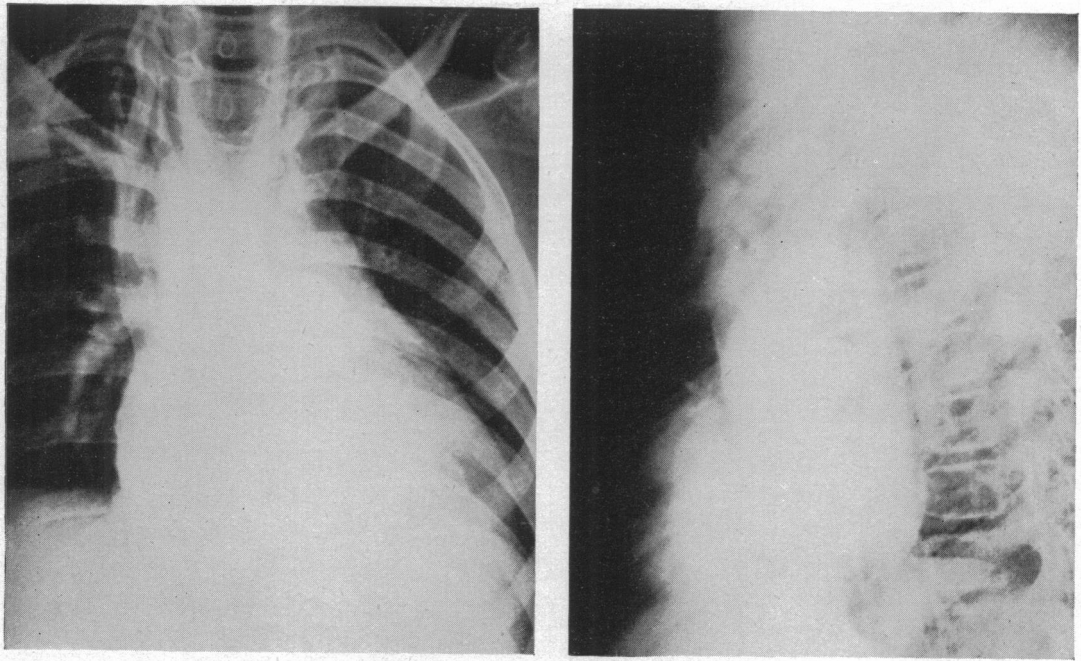


FIG. 5.—Fallot's tetralogy with subvalvular stenosis, an infundibular chamber, and absence of left pulmonary artery (necropsy). (A) Antero-posterior angiogram at 2 seconds, showing infundibular chamber and right-sided aortic arch. No left pulmonary artery is visible. (B) Left lateral angiogram at 3 seconds. The opacity at the expected site of origin of the left pulmonary artery is the right pulmonary artery.

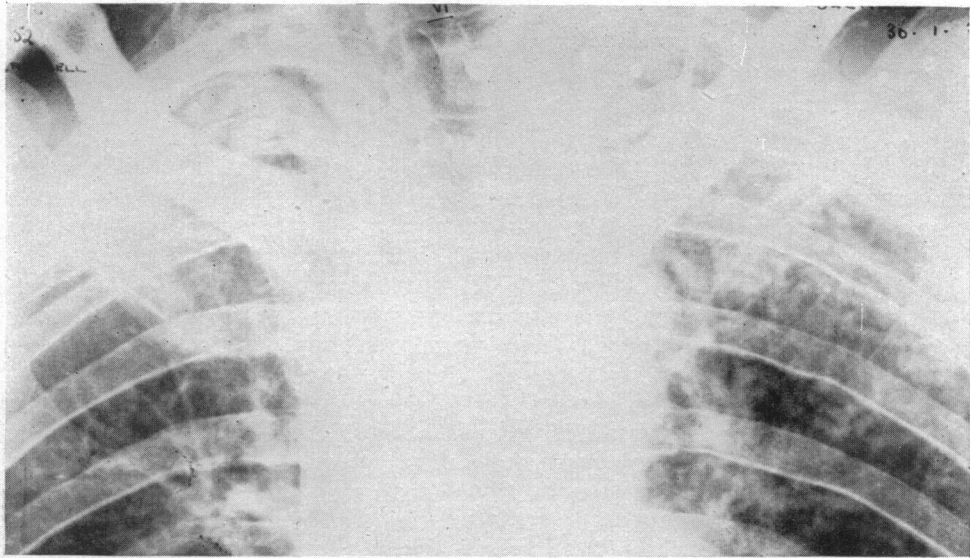

FIG. 6.—Fallot's tetralogy. Part of angiogram at 4 seconds, showing on the left side, enlarged intercostal arteries, and slight rib notching (see text).

abrupt narrowing of the right ventricular outflow tract. In all three these appearances persisted essentially unchanged in three or more consecutive films. When this tract was not well opacified, care was necessary to avoid mistaking the shadows cast by the descending branches of the left pulmonary artery for diiodone in the infundibulum; but in several cases of subvalvular stenosis a persistent though faintly outlined infundibular deformity was visible although the degree of narrowing could not be estimated. A similar appearance was noted in two patients with valvular stenosis, and Soulié *et al.* (1951, *a* and *b*) have emphasized that narrowing and irregularity of the infundibulum is usual in Fallot's tetralogy regardless of the site of maximal obstruction. However, in two

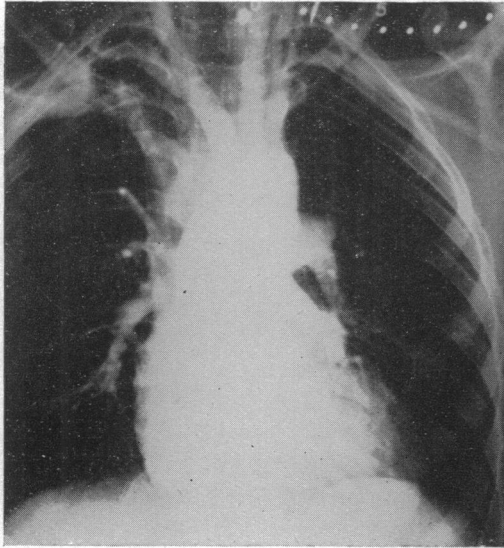


FIG. 7.—Fallot's tetralogy with valvular as well as infundibular stenosis (necropsy). Angiocardiogram at $2\frac{1}{2}$ seconds showing the infundibular chamber. The left pulmonary artery is relatively large and the appearances suggest fusiform dilatation of this vessel.

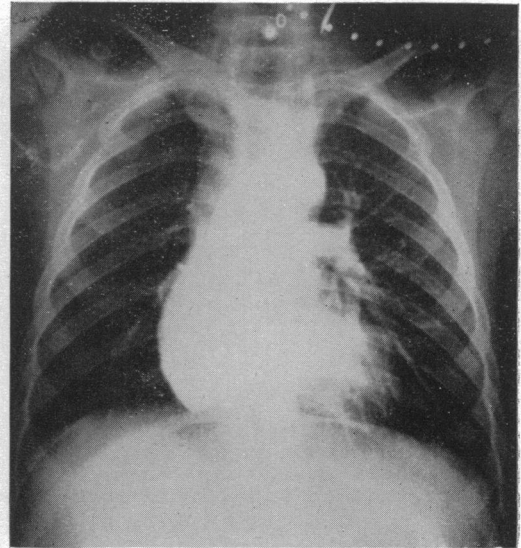


FIG. 8.—Fallot's tetralogy with valvular stenosis (necropsy). Angiocardiogram at 2 seconds. The right ventricular outflow tract is medially situated (compare Fig. 5 and 7).

patients with valvular stenosis the right ventricular outflow tract was well opacified and apparently undeformed, an appearance not seen in any proven case of infundibular stenosis.

In subvalvular stenosis, when the right ventricular outflow tract was visualized it was displaced to the left, and the infundibulum and pulmonary trunk were approximately parallel to the left heart border (Fig. 5 and 7). Brock and Campbell (1950) noted the almost horizontal course sometimes taken by the infundibulum in subvalvular stenosis. In valvular stenosis, on the other hand, the right ventricular outflow tract was usually more medially situated and almost vertical, commonly being superimposed on the left border of the spine or on the descending aorta (Fig. 8).

A persistent filling defect, with an upward convexity or peak at valve level, is sometimes found in pulmonary valvular stenosis with a closed ventricular septum (Fig. 9). This appearance was not seen in any patient with Fallot's tetralogy where the site of stenosis had been proven, though it was visible in two cases in the series.

In general the pulmonary trunk was larger in valvular than in subvalvular stenosis, but there were exceptions. Loss of parallelism of the walls of this vessel was more frequently observed and was usually greater in valvular than in subvalvular stenosis; but in two cases of valvular stenosis where the main pulmonary artery was clearly defined no fusiform dilatation could be detected.

The left pulmonary artery tended to be more prominent when the stenosis was valvular, but it was not always small in infundibular stenosis. It is possible that the shape of this vessel is of greater significance than its calibre. In some patients with valvular stenosis the antero-posterior angiogram suggested that fusiform dilatation of the pulmonary trunk was maximal not proximally but distally, and that it spread beyond the bifurcation to involve the first part of the left pulmonary artery. Certainly this may occur in valvular pulmonary stenosis with intact ventricular septum (Fig. 13); and fusiform dilatation of the left pulmonary artery sometimes makes a significant contribution to the prominence of the pulmonary arc characteristically shown by conventional radiology in these cases. Although in all other respects the angiogram of Fallot's tetralogy illustrated in Fig. 7 points to subvalvular obstruction, there appears to be fusiform dilatation of the left pulmonary artery, and possibly this should have suggested that valvular stenosis was also present.

Of the 18 angiocardiograms under discussion the site of stenosis was clearly demonstrated in three, and suggested by indirect evidence in eight. No real indication of the level of obstruction was given in the remaining seven but the quality of the films was below average in four of these. In ten other cases the probable site of stenosis was determined by direct examination of the heart as described by Brock (1948); but, because an anastomotic operation was performed, conclusive proof is lacking. Of these the level of stenosis was clearly shown by the angiogram in three cases and indirectly indicated in four; in one the surgeon concluded that the obstruction was valvular but the films suggested that it was infundibular; and in the remaining two the angiograms gave no evidence of the site of stenosis.

Physiological. Although in general the most dense early aortic opacification, the smallest pulmonary arteries, and the most lengthy persistence of diiodone in the lung vessels were seen in the most disabled patients, the quantitative angiocardiographic estimates of right to left shunting and of pulmonary blood flow added little to the clinical assessment. However, reopacification in late films of the left heart and aorta by contrast material that had passed through the pulmonary circulation sometimes gave confirmatory evidence of relatively good pulmonary flow. This appeared earliest and was most dense in those patients where the pulmonary flow was believed on clinical and other grounds to be least reduced.

DIFFERENTIAL DIAGNOSIS

The angiogram of itself was rarely diagnostic of Fallot's tetralogy, and usually the most that could be claimed was that the appearances were compatible with the clinical diagnosis. Nonetheless the investigation was of value in differentiating the tetralogy from other malformations; and, although an exhaustive account of angiocardiographic differential diagnosis is not justified by the study of so small a series, two conditions in which the angiogram may be similar to that of Fallot's tetralogy will be briefly considered.

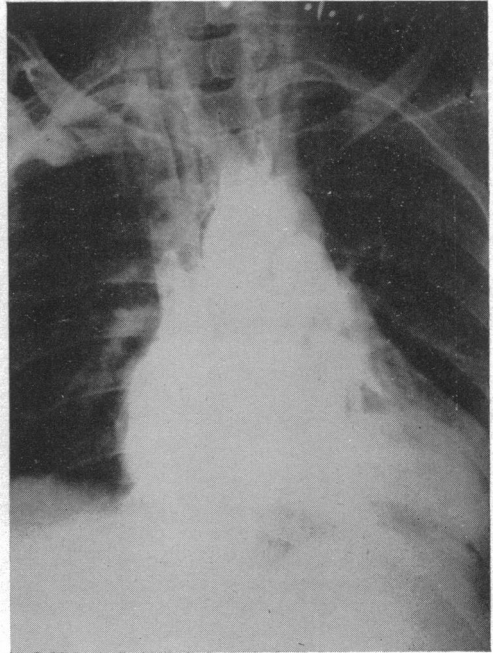


FIG. 9.—Pulmonary stenosis with intact ventricular septum and inter-atrial communication (necropsy). Angiocardiogram at $3\frac{1}{2}$ seconds. The ventricle and the aorta are well filled and the stenosed valve is outlined. Left atrial opacification was not visible now or earlier in this view.

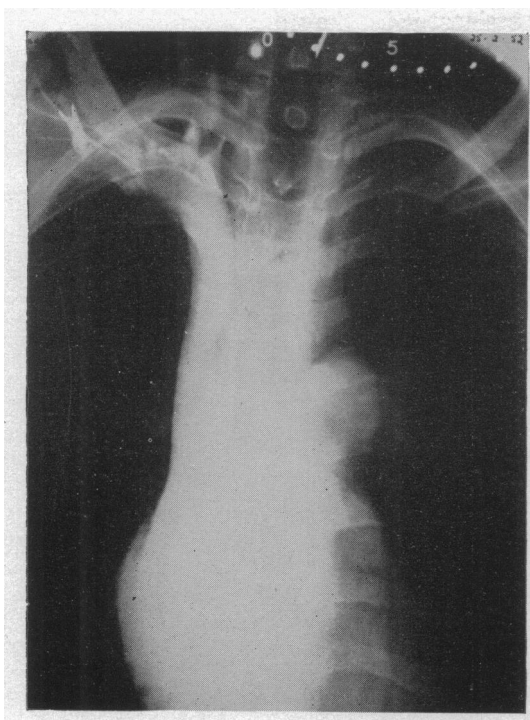


FIG. 10.—Pulmonary stenosis and inter-atrial communication; ventricular septum probably intact (valvotomy). Angiocardiogram at 2 seconds showing premature opacification of the left atrium.

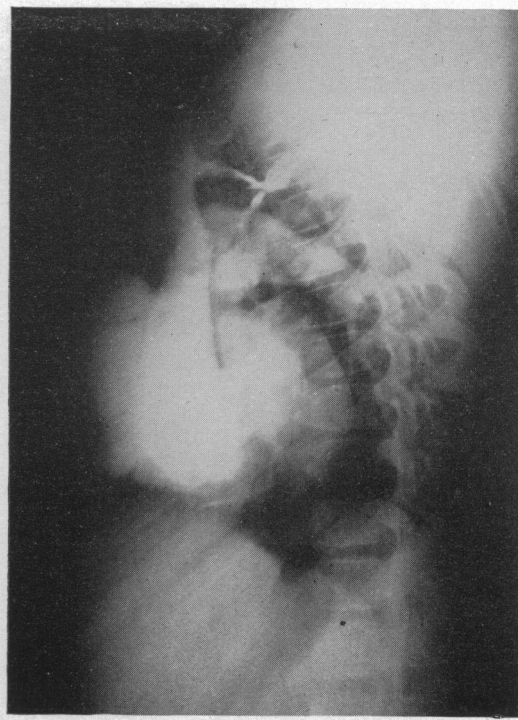


FIG. 11.—Pulmonary stenosis with intact ventricular septum and inter-atrial communication (valvotomy). Same patient as Fig. 13. Left lateral angiocardiogram at $1\frac{1}{2}$ seconds. Premature opacification of the left atrium is clearly shown.

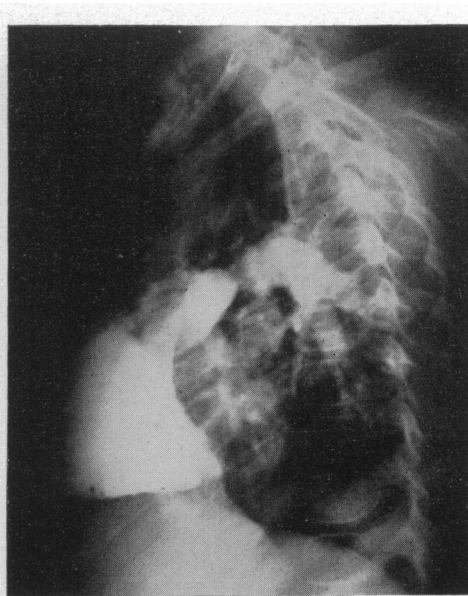
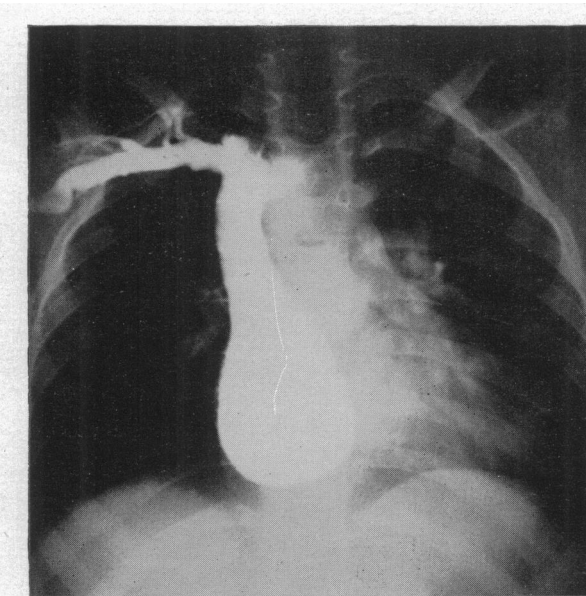


FIG. 12.—Fallot's tetralogy. (A) Antero-posterior angiocardiogram at $1\frac{1}{2}$ seconds. Opacification of a large and unusually medial right atrial appendage resembles premature filling of the left atrium. (B) Left lateral angiocardiogram at $1\frac{1}{2}$ seconds. The right heart is well opacified but diiodone has not passed to the left atrium.

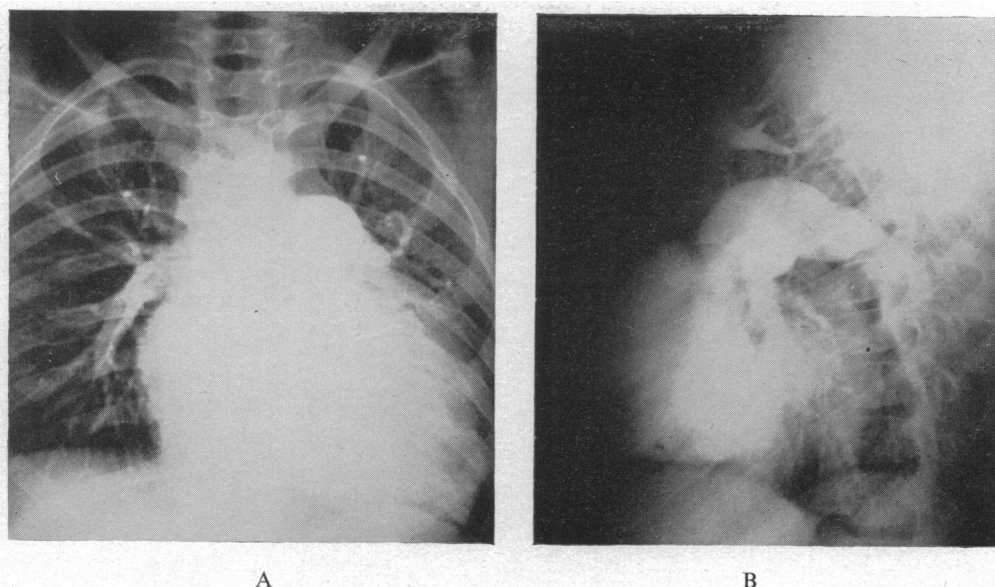


FIG. 13.—Pulmonary stenosis with intact ventricular septum and inter-atrial communication (valvotomy). (A) A-P angiogram at $4\frac{1}{2}$ seconds showing pulmonary arterial enlargement. (B) Left oblique angiogram at 3 seconds. The dilatation of the pulmonary trunk is maximal distally and extends into the left pulmonary artery.

The Eisenmenger Complex. Premature aortic opacification was visible in the angiograms of five cyanosed patients with pulmonary hypertension and ventricular septal defect, the appearances closely resembling those in Fallot's tetralogy where the area of stenosis was not visible. Even when an apparently normal infundibulum and pulmonary valve region were demonstrated pulmonary stenosis could not be excluded (Dotter and Steinberg, 1951).

In no case of the Eisenmenger complex were the major pulmonary arteries reduced in size; but in one only was there gross pulmonary arterial dilatation, and the slight or moderate enlargement present in the other four was no greater than that sometimes seen in Fallot's tetralogy (Fig. 1). Rounded opacities in the lung fields, representing enlarged pulmonary artery branches in cross-section, were visible in four angiograms of the Eisenmenger complex, but a not dissimilar appearance was occasionally noted in Fallot's tetralogy. De Groot (1951) claimed that contrast material reached the left atrium more quickly in the Eisenmenger complex than in Fallot's tetralogy, but no such difference was found in this series, diodone tending to be held up in the pulmonary arteries in both conditions (Fig. 4).

Miller (1950) stressed the difficulty of distinguishing between the Eisenmenger complex and Fallot's tetralogy by means of angiography, and although the films usually show features that favour one or the other malformation, it is agreed that this differential diagnosis can be made with greater assurance in other ways.

Pulmonary Stenosis with Intact Ventricular Septum. Angiograms of six patients with pulmonary stenosis and intact ventricular septum, where cyanosis was due to an inter-atrial shunt, were compared with those of Fallot's tetralogy. The diagnosis was eventually confirmed at necropsy in three; and in the other three, later subjected to valvotomy, the clinical impression was supported by the results of cardiac catheterization. These films resembled those of the tetralogy in so far as there was premature aortic opacification in all cases, and definite evidence of pulmonary stenosis in some. In pulmonary stenosis with intact ventricular septum, as in the tetralogy, filling of the aorta and of the pulmonary artery usually first appeared in the same film; moreover, the density of

aortic opacification in severely cyanosed patients (Fig. 9 and 14) was comparable to that seen in many cases of Fallot's tetralogy.

Early filling of the left atrium (Fig. 10) is the key to the angiocardigraphic differentiation between these malformations, but in the antero-posterior view this was occasionally simulated by opacification of the right atrial appendage (Fig. 12). Again, films in this projection sometimes failed to demonstrate premature filling of the left atrium, even though considerable central cyanosis indicated that the inter-atrial shunt was large (Fig. 9 and 14). In these it seemed that left atrial opacification was fleeting and that, because the ascending aorta was already filled in the first film to show contrast material beyond the right atrium, any residual traces of diodone remaining in the left atrium at this time were concealed by the aortic shadow.

When early left atrial filling was doubtful in the antero-posterior view left lateral films were decisive on this point (Fig. 11); but twice at least uncertainty as to the diagnosis remained. In these cases, although early left atrial opacification was shown in the lateral projection, it was faint and transient and seemed inadequate to account for the denser and more persistent filling of the aorta. In both patients this apparent discrepancy appeared to favour Fallot's tetralogy with patent foramen ovale, through which a small right to left shunt had occurred under angiocardigraphic conditions. Both died after valvotomy and in both necropsy revealed pulmonary stenosis with a large inter-atrial communication and without ventricular septal defect. When the angiocardigrams (Fig. 9 and 14) were reviewed it was noted that early left ventricular opacification was more complete and greater in density than was commonly seen in Fallot's tetralogy. While dense early left ventricular filling may occasionally occur in Fallot's tetralogy (Fig. 2), it is certainly exceptional when the injection is made intravenously, and should at least arouse suspicion of an alternative diagnosis (Donzelot *et al.*, 1949).

The duration of right heart opacification, fleeting in Fallot's tetralogy, but persistent in pulmonary stenosis with intact ventricular septum (Campbell and Hills, 1950), and the shape of the infundibulum, usually irregular in Fallot's tetralogy but smooth in pulmonary stenosis with intact ventricular septum (Soulié *et al.*, 1951*b*), are other features of value in differentiating these conditions. A right-sided aortic arch strongly favours the tetralogy.

SUMMARY

Intravenous angiocardigrams of fifty patients with Fallot's tetralogy are reviewed. In all cases a right to left shunt was demonstrated.

The area of pulmonary stenosis was seldom directly visualized. Reduction in the calibre of the pulmonary arterial tree gave indirect evidence of the stenosis in some cases, but in others no abnormality of the pulmonary arteries could be detected. Pulmonary stenosis did not cause delay in the filling of the pulmonary arteries and poor opacification of these vessels was exceptional. There was undue persistence of diodone in the pulmonary arteries but this was also observed in patients with severe pulmonary hypertension.

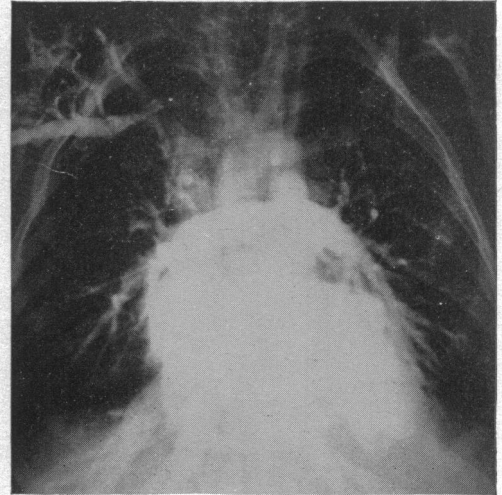


FIG. 14.—Pulmonary stenosis with intact ventricular septum and inter-atrial communication (necropsy). Angiocardigram at $1\frac{1}{2}$ seconds. The left ventricle and aorta are already visualized, but filling of the left atrium is doubtful. The dense shadow above the bifurcation of the pulmonary trunk is a blind sac formed by the ductus arteriosus which was closed only at its junction with the aorta.

In eighteen cases the angiocardigraphic appearances were correlated with the level of the stenosis which had been determined during intracardiac surgery or at necropsy. In this group the site of stenosis was clearly demonstrated by angiocardigraphy in only three, and in seven the films gave no indication of the level of the obstruction. In the remaining eight angiocardigrams the correct site of stenosis was suggested by indirect evidence.

The difficulties of angiocardigraphic differential diagnosis between the tetralogy of Fallot and the Eisenmenger complex or pulmonary stenosis with a closed ventricular septum and reversed interatrial shunt are emphasized. Dense, early, left ventricular opacification is believed to favour pulmonary stenosis with intact ventricular septum and inter-atrial communication rather than Fallot's tetralogy.

I wish to express my thanks to the many registrars, radiographers, and members of the nursing staff who participated in these investigations at both the National Heart Hospital and the Brompton Hospital; to Dr. M. McGregor who initially instructed me in this technique; to Dr. B. G. B. Lucas who administered most of the anaesthetics; and to Mrs. I. O. Terry who prepared the illustrations. I am grateful to Dr. Maurice Campbell for his interest and advice. I am greatly indebted to Dr. Paul Wood for constant encouragement and for much helpful advice in the preparation of this paper.

REFERENCES

- Angelino, P. F., and Actis-Dato, A. (1952). *Angiocardiopneumography in mitral stenosis*. Presented at First European Congress of Cardiology, London, September, 1952.
- Blalock, A., and Taussig, H. B. (1945). *J. Amer. med. Ass.*, **128**, 189.
- Brock, R. C. (1948). *Brit. med. J.*, **1**, 1121.
- and Campbell, M. (1950). *Brit. Heart J.*, **12**, 403.
- Campbell, M., and Gardner, F. (1950). *Brit. Heart J.*, **12**, 183.
- and Hills, T. H. (1950). *Brit. Heart J.*, **12**, 65.
- Carson, M. J., Burford, T. H., Scott, W. G., Goodfriend, J. (1948). *J. Pediat.*, **33**, 525.
- Cooley, R. N. (1951). *J. Fac. Radiol.*, **2**, 249.
- , Bahnson, H. T., and Hanlon, C. R. (1949). *Radiology*, **52**, 329.
- Donzelot, E., Emam-Zadé, A. M., Heim de Balsac, R., Escalle, J. E. and Anoine, M. (1949). *Sem. Hôp. Paris*, **25**, 2309.
- Dotter, C. T., and Steinberg, I. (1949). *Radiology*, **52**, 353.
- , — (1951). *Angiocardiography. Annals of Roentgenology*, vol. XX, Cassels and Co. Ltd., London.
- Groot, J. W. C. de (1951). *Angiocardiography as a diagnostic aid in Congenital Heart Disease*. Keesing, Amsterdam.
- Jönsson, G., Brodén, B., Karnell, J. (1949). *Acta Radiol.*, **32**, 486.
- MacGregor, M. (1949). *Brit. J. Radiol.*, **22**, 459.
- Miller, J. E. (1950). *Amer. J. Roentgenol.*, **64**, 214.
- Robb, G. P., and Steinberg, I. (1939). *Amer. J. Roentgenol.*, **41**, 1.
- Soulié, P., Chiche, P., and Voci, G. (1951a). *Sem. Hôp. Paris*, **27**, 699 and 715.
- , Piton, A., Touche, M. (1951b). *Arch. Mal. Coeur*, **44**, 1057.
- Sussman, M. L., and Grishman, A. (1947). *Advances in Internal Medicine*. Vol. ii. Edited by Dock and Snapper, Interscience Publishers Inc., New York.
- , Steinberg, M. F., Grishman, A. (1942). *Amer. J. Roentgenol.*, **47**, 368.
- Steinberg, M. F., Grishman, A., Sussman, M. L. (1943). *Amer. J. Roentgenol.*, **49**, 766.
- Thompson, W. H., Figley, M. M., Hodges, F. J. (1949). *Radiology*, **53**, 729.
- Ulfsparré, F. (1949). *Morbis Ceruleus*. Edited by Mannheimer, S. Karger, New York.