

# A RAPID CYTOLOGICAL METHOD FOR THE DIAGNOSIS OF MEASLES

BY

A. J. BEALE\* AND W. CAMPBELL

*From the Public Health Laboratory, Newcastle upon Tyne*

(RECEIVED FOR PUBLICATION APRIL 27, 1959)

The fact that the laboratory diagnosis of virus infections is a lengthy process is the constant complaint of our clinical colleagues. The purpose of this paper is to call attention to the method of exfoliative cytology as a rapid method for the diagnosis of measles. It has been established that the characteristic pathological feature of measles is the appearance of large multinucleated giant cells, particularly in areas of lymphoid tissue, as first described by Denton (1925). The work of Tompkins and Macaulay (1955) has demonstrated that similar syncytial giant cells are present in sputum and may be recovered by aspirating mucus from the back of the nose. It is striking that measles virus also produces syncytial giant cell masses when growing in tissue culture on epithelial type cells (Enders and Peebles, 1954). The particular value of this method of diagnosis is that the giant cells are present during the catarrhal stage, disappearing rapidly with the onset of the rash. It is easy to obtain material which can be rapidly stained and examined in the laboratory, enabling a diagnosis to be made in a few hours. This may be valuable with suspected measles, for example, in a children's ward. Similar giant cells do not seem to occur in other diseases, although somewhat similar cells are seen in nasal mucus of ferrets infected with canine distemper virus. Also Done (1958) has recently described a similar method for the diagnosis of inclusion body rhinitis of swine. He examined nasal secretions of pigs using Giemsa or methylene blue staining. The pathognomonic cells contain intranuclear inclusions. The giant cells seen in herpes simplex and varicella are quite different from those seen in measles, having fewer nuclei, which often overlap and contain less cytoplasm.

## Method

**Aspiration of Nasal Mucus.**—At first nasal mucus was collected by the method described by Tompkins and Macaulay (1955). This involved pushing a glass pipette along the floor of the nose and aspirating

mucus from the posterior turbinate region. Because of a natural fear of damaging the child insufficient mucus for examination was frequently obtained. Later a better method of obtaining sputum from children, which was described by Auger (1939), was used. In this method a polythene tube attached to a syringe (preferably at least of 20 ml. capacity) is inserted into the back of the nose and then suction is applied. In order to obtain a second suction stroke a small hole can be cut in the side of the tubing which enables air to be expelled without dislodging the mucus. During suction the hole is occluded.

**Staining.**—Papanicolaou's method was used following in general the technique described by the staff of the Vincent Memorial Hospital (1950), using smears fixed immediately in ether-alcohol mixture. (This technique was taught by the staff of the General Hospital, Newcastle upon Tyne, through the courtesy of Dr. B. E. Tomlinson.) Tompkins and Macaulay report that methylene blue staining of air-dried films is adequate, and working with Dr. Morley, of Ilesha, Nigeria, it has been found that very good results can be obtained using Giemsa staining of air-dried smears.

## Results

In a florid case in the catarrhal stage it is easy to obtain mucus which is full of the characteristic giant cell masses. A low-power view of the appearances seen is shown in Fig. 1. If material is taken from the front of the nose or later on in the disease when the rash has appeared large necrotic masses are often present in which it is impossible to decipher a giant cell. Material collected earlier (up to five days before the onset of the rash) during the catarrhal stage of the disease from the posterior turbinate region contains easily recognizable giant cells. Higher-power views of these cells are shown in Figs. 2 and 3. It seems probable that these cells are derived from fusion of ciliated mucosal cells that have become desquamated. Tompkins and Macaulay (1955) describe having seen cilia on the edge of the cells, but we have not observed this. Fig. 4, however, shows cells coming together and we think that these go on to form the giant cell masses by dissolution of the cell boundaries.

\*Present address: Glaxo Laboratories Ltd., Sefton Park, Stoke Poges, Buckinghamshire.

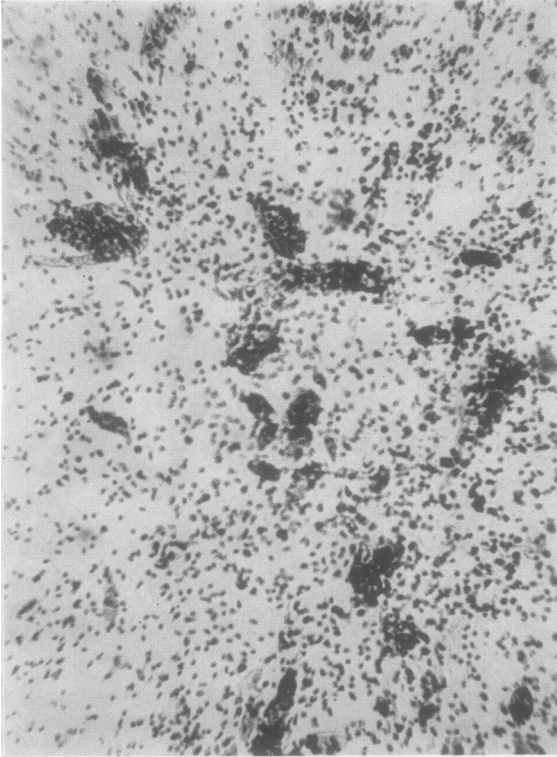


FIG. 1.—Low-power view of measles giant cells obtained on the day of onset of the rash (Papanicolaou  $\times 100$ ).

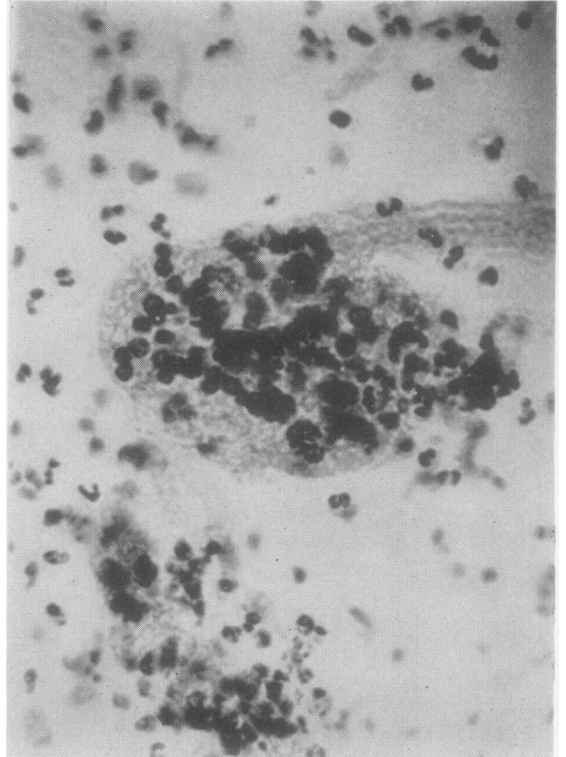


FIG. 2.—High-power view of a cell from Fig. 1 (Papanicolaou  $\times 500$ ).

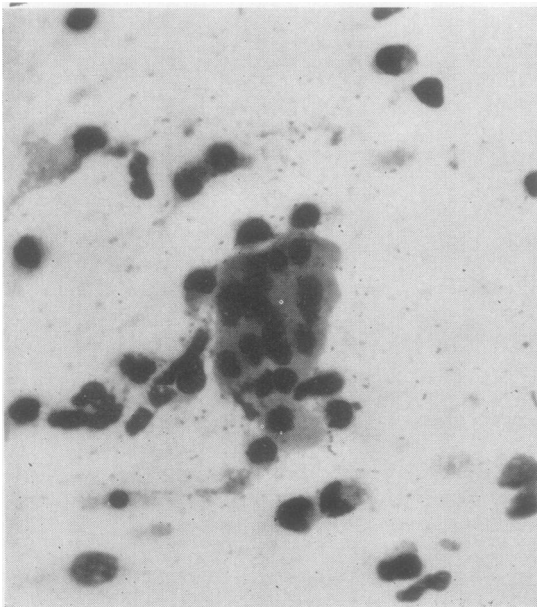


FIG. 3.—High-power view of measles giant cell (Giemsa  $\times 500$ ).

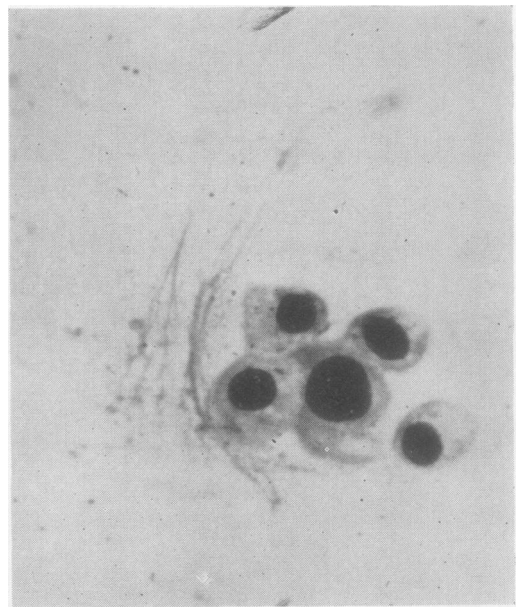

FIG. 4.—Isolated cells fusing to form giant cell (Giemsa  $\times 500$ ).

In the winter of 1956-57 there was an epidemic of measles in Newcastle upon Tyne, as elsewhere in England, and during the spring of 1957 this method of diagnosis was put to the test with the co-operation of the general practitioners in the city. In all 32 smears were examined. When the general practitioner visited a case of suspected measles in the prodromal stage he took material from the child's nose, fixed it in 50-50 ether alcohol and sent it to the laboratory. When the result was reported to the doctor he in turn reported whether a measles rash had developed. During this time mucus was collected with a glass pipette which did not prove very satisfactory, and this almost certainly accounts for the rather high proportion of false negatives. As shown in the Table, it will be seen that 13 patients who

TABLE  
EXAMINATION OF NASAL SMEARS FROM CHILDREN  
WITH CATARRHAL SYMPTOMS FOR MEASLES GIANT  
CELLS

Number of Patients	Giant Cells Present	Measles Rash
13	+	+
10*	-	+
9	-	-

\*In at least five of these the specimen was not adequate for examination.

developed measles showed giant cells, whereas 10 patients who had measles failed to show giant cells. On the other hand there were no false positives; all the nine patients who did not develop a rash did not show giant cells. Similar giant cells have not been seen in other children with catarrhal symptoms not due to measles. In many hundreds of sputum specimens examined for the diagnosis of carcinoma of the bronchus the appearances seen in measles have not been observed (Dr. B. E. Tomlinson, personal communication).

### Discussion

Giant cells are the characteristic pathological feature of measles virus infection both in the intact animal (man or monkey) and in tissue culture. Recently Sherman and Ruckle (1958) described and illustrated these changes. There are two sorts of giant cells seen in measles.

**1. Epithelial Giant Cell or Syncytium.**—This is most common in the respiratory tract, but sometimes occurs on other epithelial surfaces, for example, the bladder. It is these cells desquamated from the respiratory tract which enable a cytological diagnosis of measles to be made. They are not known in other conditions with the exception of Hecht's giant cell pneumonia which is probably in reality due to measles virus. Similar

giant cells have been seen in canine and mink distemper (Pinkerton *et al.*, 1945). These epithelial type giant cells also occur in tissue cultures infected with measles virus (Enders and Peebles, 1954) and contain eosinophilic intranuclear inclusions. It is generally acknowledged that these syncytial masses arise by fusion of cells.

**2. Reticulo-endothelial Type Giant or Warthin-Finkeldey Cell.**—These cells are occasionally encountered in the appendix removed from prodromal measles cases and may arise by fusion or by phagocytosis. Intranuclear inclusions are rarely seen in them in tissue sections, but Sherman and Ruckle (1958) reported that intranuclear and intracytoplasmic inclusions were present in cells cultured from measles-infected spleen or lymph nodes.

So far as is known the presence of these giant cells is specific for measles infection. Unfortunately in this study it did not prove possible to examine large numbers of control children in order to establish this definitely. However, giant cells were not seen in patients not suffering from measles. Similarly Tompkins and Macaulay (1955) report that giant cells were not seen in other upper respiratory infections or allergic rhinitis. Multinucleated giant cells are characteristic of some other virus infections, for example, herpes simplex and varicella. The giant cell seen in these diseases is different, having fewer nuclei and less cytoplasm, and can be obtained by scraping the floor of a chickenpox vesicle. If seen a distinction can be made between herpes simplex and varicella (showing giant cells) and smallpox and vaccinia (not showing giant cells), for example.

Although measles is not often a difficult diagnostic problem there are occasions, especially in children's hospitals, where it would be most valuable to be able to make a diagnosis in the catarrhal stage. It is our object to call attention to a simple and rapid method which may well enable this to be achieved.

Our thanks are due to general practitioners in Newcastle upon Tyne who co-operated in this study, and to Mr. S. A. Keeble for the photomicrographs.

### REFERENCES

- Auger, W. J. (1939). *J. Pediat.*, **15**, 640.  
 Denton, J. (1925). *Amer. J. med. Sci.*, **169**, 531.  
 Done, J. T. (1958). *Vet. Rec.*, **70**, 877.  
 Enders, J. F., and Peebles, T. C. (1954). *Proc. Soc. exp. Biol. (N.Y.)*, **86**, 277.  
 Pinkerton, H., Smiley, W. L., and Anderson, W. A. D. (1945). *Amer. J. Path.*, **21**, 1.  
 Sherman, F. E., and Ruckle, Gisela (1958). *A.M.A. Arch. Path.*, **65**, 587.  
 Tompkins, V., and Macaulay, J. C. (1955). *J. Amer. med. Ass.*, **157**, 711.  
 Vincent Memorial Hospital (1950). *The Cytologic Diagnosis of Cancer*. W. B. Saunders, Philadelphia.