

GENERALIZED CYTOMEGALIC INCLUSION-BODY DISEASE ASSOCIATED WITH PNEUMOCYSTIS PNEUMONIA IN ADULTS

A REPORT OF THREE CASES, WITH WEGENER'S GRANULOMATOSIS,
THROMBOTIC PURPURA, AND HODGKIN'S DISEASE AS PREDISPOSING
CONDITIONS

BY

W. ST. C. SYMMERS

From Charing Cross Hospital and Medical School, London

(RECEIVED FOR PUBLICATION JULY 4, 1959)

Three cases of generalized cytomegalic inclusion-body disease (salivary virus disease) in adults are reported, bringing the number of published cases up to 34. The infection is very rare in adults although well known in infants. As is often found in infants with this disease, pneumonia due to *Pneumocystis carinii* was also present in each case.

The first patient had Wegener's granulomatosis, which presented with acute otitis media: a review of histological material obtained at mastoidectomy eight weeks before death showed that inclusion-body cytomegaly was already present then. Various antibiotics and prednisolone were given, and the lesions in the respiratory organs and the arteritis healed to a considerable extent. Renal failure, however, was progressive and led to death.

The second patient had thrombotic purpura and died after a few weeks' illness, during which oxytetracycline and hydrocortisone were given. Congenital absence of the spleen was found at laparotomy, which was performed with the object of doing a splenectomy. Focal cryptococcal pneumonia was present *post mortem*: six years before death a solitary cryptococcal granuloma of one lung had been treated by lobectomy.

The third patient had had Hodgkin's disease for 18 years. During the first 12 years the disease had the characteristics of the so-called indolent form ("Hodgkin's paragranuloma") and it then passed into the typical form. Deep x-ray therapy and cytotoxic drugs were used during the course of the disease at various times, and streptomycin and tuberculostatic drugs were given because of intercurrent tuberculous meningitis which developed three months before death.

In all three cases it seems likely that the underlying disease, or the drugs used in its treatment, predisposed to cytomegalic inclusion-body disease and concomitant pneumocystis pneumonia by lowering the patients' resistance. Just as some unusual types of fungal and bacterial infections have become less rare since the introduction of certain drugs, including antibiotics and steroids, it is possible that cytomegalic inclusion-body disease and pneumocystis infection may also be met with oftener in adults, perhaps particularly as a complication of the use of these drugs in the treatment of diseases which are specially liable to interfere with the body's defences.

The adult type of cytomegalic inclusion-body disease occurs usually, if not in fact always, as a complication of some other disease or its treatment, and in a considerable proportion of the cases the lesions have been widespread and serious. These features distinguish the adult type from the infantile type of the disease, which is

often no more than an incidental post-mortem finding without clinical significance.

The current editions of most textbooks of medicine and virology say little or nothing about this infection: it is possible to give only a short account of selected aspects here, but further information, particularly about the disease in

infancy, is to be found in the admirable monographs of Seifert and Oehme (1957) and of Nelson and Wyatt (1959), and in articles by Wyatt, Saxton, Lee, and Pinkerton (1950) and France (1951) among others.

The Viral Nature of the Infection

VonGlahn and Pappenheimer (1925) studied a case of generalized cytomegalic inclusion-body disease in an adult, and on cytological grounds put forward the theory that the disease was caused by a virus. A year later Cole and Kuttner (1926) successfully propagated the disease through several generations of guinea-pigs by intracerebral inoculation of cell-free filtrates originally obtained from salivary tissue of naturally infected animals. Work on other animals has shown that each virus is specific to the species from which it is isolated. The presence of a virus in tissue from human cases has been demonstrated only recently: Smith (1956) isolated a virus which causes the development of similar intranuclear inclusion bodies in tissue cultures of human fibroblasts, and is neutralized by the serum of infants with the disease and by that of their mothers. Parallel observations confirming these results were made by Rowe, Hartley, Waterman, Turner, and Huebner (1956). Studies by Minder (1953) suggested that the virus itself can be shown by electron microscopy as aggregates of spherules in the optically clear zone between the intranuclear inclusion body and the nuclear membrane.

The Inclusion Bodies

Two sorts of inclusion are found in the affected cells, intranuclear and intracytoplasmic (Fig. 1). Every infected cell contains an intranuclear inclusion body: in contrast, the intracytoplasmic inclusions seem to have been found only in epithelial cells, particularly those of the ducts of secretory glands. At different stages of maturation and ageing the intranuclear inclusion bodies differ considerably in appearance and in the relative proportions of their chemical constituents. The variation in chemical composition explains some of the apparently conflicting results of different observers when recording the staining reactions and histochemistry of the inclusions. At its most typical, when fully mature, the intranuclear inclusion body is separated by a clear zone from the nuclear membrane and the nucleus has a characteristic "owl's eye" appearance (Fig. 2). Although the whole affected cell is anything from twice to four or more times its normal size the cytoplasm increases in amount approximately in

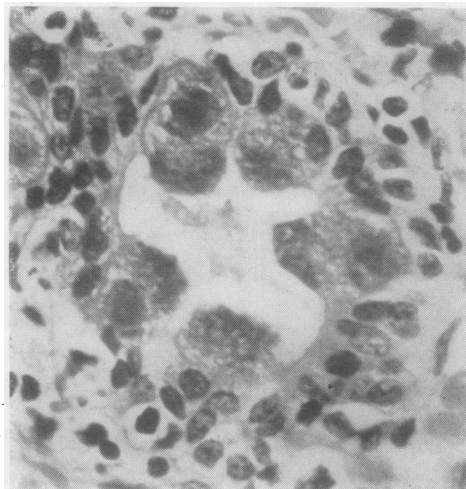


FIG. 1.—Inclusion-body cytomegaly affecting five cells of a parotid ductule (Symmers, 1960). The nucleus is seen in only three of the cells, and is much enlarged, consisting almost wholly of inclusion body without any of the clear zone of nucleoplasm which is characteristic at another stage in development of the infection (see Figs. 2 and 25). The nucleus is basally placed: the opposite pole of the cell protrudes into the lumen of the ductule, and intracytoplasmic inclusions are responsible for the darker appearance of this part. Haematoxylin-eosin. $\times 700$.

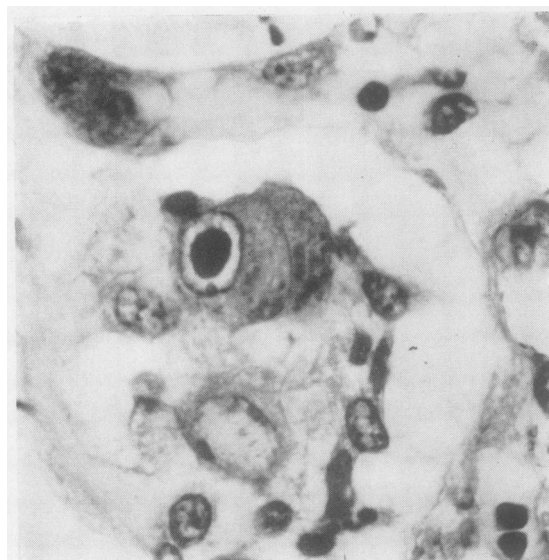


FIG. 2.—Case 1: Inclusion-body cytomegaly in a bronchial gland. "Owl's eye" appearance of the affected nucleus, with large central inclusion body separated by a clear zone from the nuclear membrane. A "polar body" on the nuclear membrane projects into the clear nucleoplasm at the lower pole of the nucleus; such polar bodies are often seen in the affected cells. Intracytoplasmic inclusions are seen as dark particles below and to the right, adjacent to the lumen of the acinus, which in this tangential section is just visible below the affected cell. Haematoxylin-eosin. $\times 850$.

proportion to the enlargement of the nucleus and the nucleocytoplasmic ratio remains about normal. The mature intranuclear inclusion bodies consist mainly of deoxyribonucleic acid, with some ribonucleic acid (Seifert, 1956; Symmers and Humberstone, 1959): they are probably formed mainly of virus particles.

The intracytoplasmic inclusions in the cells of salivary duct epithelium accumulate as rather coarsely granular masses between the nucleus and the free margin of the cell, causing the cell to bulge into the lumen. They consist largely of neutral mucopolysaccharides and are probably secretory substances which have accumulated because of interference with nuclear function. Traces of deoxyribonucleic acid and ribonucleic acid are usually present also, and larger amounts may appear when the ageing intranuclear inclusion body begins to lose its concentration of these substances, during the period before the degenerating cell is shed into the lumen (Seifert, 1956; Symmers and Humberstone, 1959).

Extent of the Infection in the Body

(a) Localized Cytomegalic Inclusion-body Disease in Infancy.—In the great majority of cases the disease in infants is apparently confined to the salivary glands, particularly the serous glands. The epithelium of the ductules is affected almost exclusively, inclusion bodies being rarely found in acinar cells.

(b) Localized Cytomegalic Inclusion-body Disease in the Adult.—It is usually said that the salivary glands are not affected in adults, and in fact their involvement has only once been recorded (Symmers, 1960). It is debatable whether any localized form of cytomegalic inclusion-body disease occurs in adults which is at all comparable with the symptomless and clinically unimportant localized infection in infants. While cases have been recorded in which the infection was observed only in one part of the body, the circumstances have always been very different from those in infancy; the cytomegaly has usually been in the vicinity of a definite lesion, such as ulceration of part of the alimentary tract (five cases), or it has been confined to the lungs (six cases), when it is usually associated with pneumocystis infection or some other form of pneumonia complicating Hodgkin's disease or another serious illness.

(c) Generalized Cytomegalic Inclusion-body Disease in Infancy.—The organs involved in generalized infections in infancy are, in order of frequency, salivary glands, kidneys, and lungs,

then liver and pancreas, and then thyroid, adrenals, gastrointestinal tract, and brain. Other organs and tissues are rarely affected.

(d) Generalized Cytomegalic Inclusion-body Disease in the Adult.—In adults the relative liability of the various organs to the infection differs somewhat from that in infancy; those most heavily involved have been the lungs, adrenals, spleen, intestine, and kidneys, approximately in that order.

The virus is not exclusively epitheliotropic, and in generalized infections vascular endothelium, mesothelium, fibroblasts, and macrophages, and occasionally muscle cells, may be infected: this seems particularly likely to be the case in adults.

Other Changes in Infected Organs.—Heavily affected organs show focal interstitial inflammation, with a predominantly lymphocytic and plasma-cell infiltrate. Focal necrosis is common in the adrenals and liver when they are heavily involved.

Incidence

The average incidence of cytomegalic inclusion-body disease in infants and children, as shown by regular histological examination of salivary glands, was between 10 and 15% of some 1,700 necropsies in various parts of the world (China, Czechoslovakia, East Indies, Germany, Hungary, United States of America, and Venezuela) between 1932 and 1956 (Seifert and Oehme, 1957). Generalized infection is considerably less frequent: the studies which Seifert and Oehme (1957) reviewed indicated an incidence of between 1 and 3% of necropsies in childhood. My impression from discussions with colleagues who see considerably more material from infants and young children than I do is that both localized and generalized infections are less frequent in Britain than in the countries where the figures noted above were obtained.

The adult type of the disease, which is met with in older children as well as in adults, is undoubtedly very rare. Details of the published cases have been tabulated by Seifert and Oehme (1957), Geiler (1957),* and Fisher and Davis (1958). To the 25 cases collected in these three reviews may be added a case reported by Takos (1956), the case of Sakamoto and Oota (1957), three cases reported by Peace (1958) and the three cases in this paper, as well as a case of involvement of a parotid gland (Symmers, 1960). Nineteen of

*Geiler's (1957) case of a 7-year-old boy with the adult type of cytomegalic inclusion-body disease was also included by Seifert and Oehme (1957) as case 83 of their series.

these 34 cases were examples of inclusion-body cytomegaly localized to one organ, and 15 were examples of generalized infection; in some of the cases in which only one organ was found to be involved the specimen was obtained surgically and the true extent of the infection in the body is therefore unknown.

Association with Pneumocystis Pneumonia

Both in infants and in adults cytomegalic inclusion-body disease has been associated notably often with another unusual infection, pneumonia caused by *Pneumocystis carinii*. This organism is usually described as a protozoon but its nature is in fact uncertain, and it is thought by some workers to be a fungus; it has not yet been cultivated. Pneumocystis infection has been made familiar to us by Baar (1955) and Hamperl (1957); it is rarer in this country than in continental Europe. The alveoli of affected parts of the lungs are filled by the characteristic colonies of the organism. The pneumonic reaction is practically confined to the interstitial tissue (Fig. 3), and plasma cells are so conspicuous that the name interstitial plasma-cell pneumonia is peculiarly apt, although not every case of pneumonia for which this name would be appropriate is due to pneumocystis infection; other causes are said to include cytomegalic inclusion-body disease itself.

Pneumocystis pneumonia was present in 35 of the 78 cases of cytomegalic inclusion-body disease in children under 1 year of age studied personally by Seifert and Oehme (1957). Sixteen of their 78 cases were cases of generalized cytomegalic inclusion-body disease, and no less than 10 of these 16 showed pneumocystis infection. Similarly, pneumocystis infection, which ordinarily is very rare indeed in adults, was recognized with certainty in six of the 15 recorded cases of the adult type of generalized cytomegalic inclusion-body disease, including all three of the cases reported in this paper; it was probably present in at least four more of the published cases.

The coexistence of these two unusual infections is too frequent to be due to chance. Possibly there is some biological synergism between *Pneumocystis carinii* and the virus of cytomegalic inclusion-body disease. On the other hand, it is possible that some independent circumstance or combination of circumstances predisposes to both infections; resistance to them may be low in infants because of prematurity and in adults because of some other illness or of an effect of the drugs with which it has been treated.

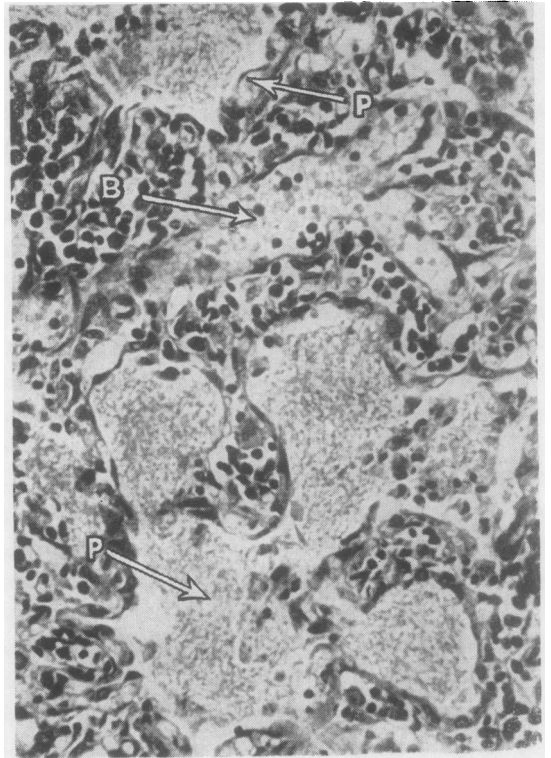


FIG. 3.—Case 1: Typical picture of plasma-cell interstitial pneumonia with intra-alveolar pneumocystosis. The appearances are indistinguishable from those seen in pneumocystis pneumonia in infancy. P—colonies of *Pneumocystis carinii* filling alveoli. B—blood vessel. Haematoxylin-eosin. $\times 350$.

Predisposing Conditions

It is debatable whether prematurity predisposes to the infantile type of cytomegalic inclusion-body disease or is caused by it. Haemolytic disease of the newborn has also been said to predispose to this infection, but again the evidence seems to be more in favour of the infection being one of the rarer causes of that syndrome (Cappell and McFarlane, 1947). In contrast, there is no doubt that predisposing diseases play an important part in the aetiology of the adult type of cytomegalic inclusion-body disease, particularly the generalized form. An apparent predisposing cause was present in 12 of the 15 cases of the generalized infection in adults and in six of the 20 other adult cases on record. The associated condition was a primary malignant disease of the lymphoreticular system (Hodgkin's disease or lymphosarcoma) or leukaemia in 10 cases and aplastic anaemia in two cases; paraplegia, hypertensive nephrosclerosis, glomerulonephritis, ulcerative colitis, Wegener's granulomatosis, and thrombotic purpura accounted

for the other six cases. The last two of these cases and one of the cases of Hodgkin's disease are reported in this paper.

Case 1: Generalized Cytomegalic Inclusion-body Disease, Pneumocystis Pneumonia, and Wegener's Granulomatosis

A 34-year-old American schoolmistress was troubled slightly by deafness in the right ear in May and again in November, 1956. In May, 1957, she was given an unidentified antibiotic by mouth because of throbbing tinnitus in the left ear. Her general health had always been good. While on her way from America to Britain she had coryzal symptoms followed by a persistent blood-streaked discharge from the nose during an outbreak of influenza in the ship, and on the day of arrival here (July 8, 1957) her left ear became painful and deaf. Two days later she called at a hospital: acute suppurative otitis media was found, and she was given an injection of penicillin. She did not attend for the rest of the prescribed course of injections because she was anxious not to interrupt a study tour. On July 15 she again went to a hospital: she attended for four daily injections of penicillin, and on alternate days chloramphenicol was insufflated into the ear, from which pus discharged freely. After this she decided to continue her journey.

On July 23 she arrived in London and was obliged by severe pain to go straight into hospital with acute mastoiditis. Temperature 102.2° F. (39° C.). Leucocyte count 12,000 per c.mm.; haemoglobin 11.5 g. per 100 ml. Urine showed a trace of protein, and there were a few erythrocytes in the centrifugate.

Simple mastoidectomy was performed on July 24: the mastoid air cells were acutely inflamed and contained sterile mucopus; the granulation tissue removed from the mastoid was sent for histological examination (see below). The lateral sinus was not involved, and needling showed that it contained normal blood.

Her general condition did not improve after the operation: although the aural symptoms were promptly relieved she continued to feel and look very ill. During the following week her temperature ranged between 100 and 103° F. (37.8 and 39.4° C.), with proportionate tachycardia. Her respirations rose to 42 a minute. She coughed a great deal, producing purulent sputum, cultures of which yielded heavy growths of *Escherichia coli* but nothing else of note. In spite of treatment with antibiotics (see Table) and probenecid ("benemid") there was no sustained improvement. Radiographs showed increasingly widespread, patchy consolidation in both lungs, and by August 7 some of these lesions were beginning to show cavitation. The likeliest diagnosis at this time was thought to be multiple lung abscesses due to embolism, secondary to septic thrombosis of the lateral sinus as a complication of the mastoid infection, although by then the mastoid wound had healed and the ear itself was dry. Repeated blood

B*

TABLE I
ANTIBIOTIC AND STEROID THERAPY IN CASE 1

Drug	Length of Course	Administration	Total Dosage
Oxytetracycline (tetracycline)	i, July 23-26	0.25 g. by mouth 6-hourly (11 doses)	2.75 g.
	ii, July 30-31	0.5 g. by mouth 6-hourly (4 doses)	2.0 g.
Streptomycin ..	i, July 26-29	1.0 g. intramuscularly twice daily (8 doses)	8.0 g.
	ii, July 30-Aug. 3	Ditto (9 doses)	9.0 g.
Benzylpenicillin*	iii, Aug. 9-13	2,500,000 units intramuscularly 4-hourly (14 doses)	35,000,000 units
	i, July 27-29	2,000,000 units intramuscularly thrice daily (12 doses)	24,000,000 units
Erythromycin	July 31-Aug. 7	0.5 g. by mouth thrice daily (20 doses)	10.0 g.
Tetracycline (achromycin)	Sept. 5-10	0.5 g. by mouth 6-hourly (20 doses)	10.0 g.
Prednisolone ..	Aug. 26-Sept. 16	10 mg. by mouth 6-hourly (84 doses)	840 mg.

* The patient had also had an injection of penicillin daily from July 15 to 18 inclusive. The dose and preparation are not known. (The left ear was insufflated with chloramphenicol twice during the same period; chloramphenicol was not administered internally.)

cultures were sterile. The urine contained many erythrocytes and occasional granular casts; protein + +. Neutrophil leucocytosis persisted, and the haemoglobin fell to 9.2 g. per 100 ml. Blood transfusions were given, and during one of these (August 3) she developed acute, severe, generalized urticaria, which responded promptly to the intramuscular injection of 50 mg. of promethazine hydrochloride ("phenegan"). After this episode promethazine was given by mouth for several days, with supplementary parenteral administration during and after blood transfusions: no further urticaria developed.

The right kidney was explored surgically on August 10 because of tenderness and fullness in the lumbar region, first noticed a week earlier. The tissues round the kidney were healthy, but the kidney itself was swollen and there was bloody fluid beneath its capsule, which was therefore stripped. There was a febrile reaction (101.2° F. [38.4° C.]; pulse 130) during a blood transfusion after this operation: intense generalized flushing accompanied the reaction but there was no shock, pain, or rigor; the transfusion was completed at a reduced rate and nothing further happened until some hours later, when the urine was found to be heavily blood-stained.

Haematuria persisted, punctate erythema developed and became confluent, and there were epistaxes. Bedsores formed rapidly where the rash had been heaviest over the buttocks. The blood urea level began to rise; acidosis, sodium deficiency, and increasing fluid retention developed, and attempts to maintain fluid and electrolyte balance were only partly successful. Oedema, congestive heart failure, and progressive uraemia were accompanied by persistent

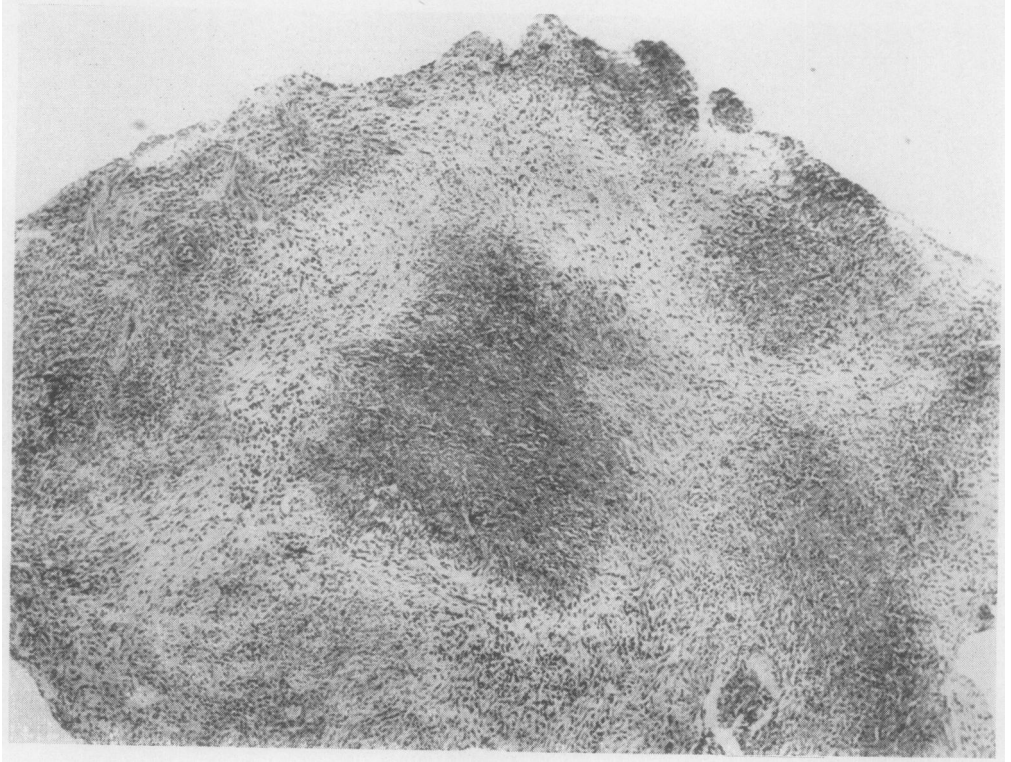


FIG. 4

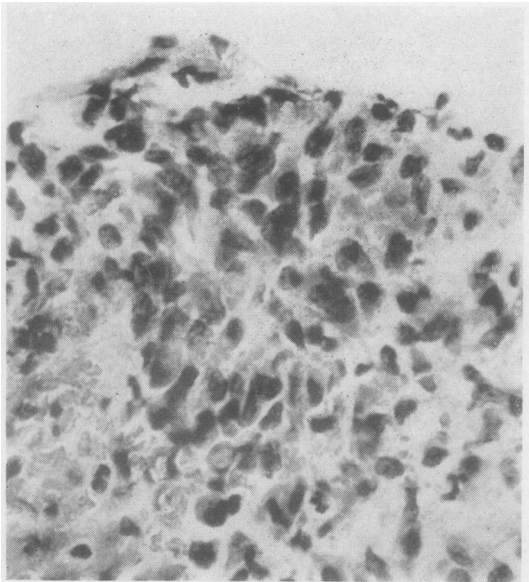


FIG. 5

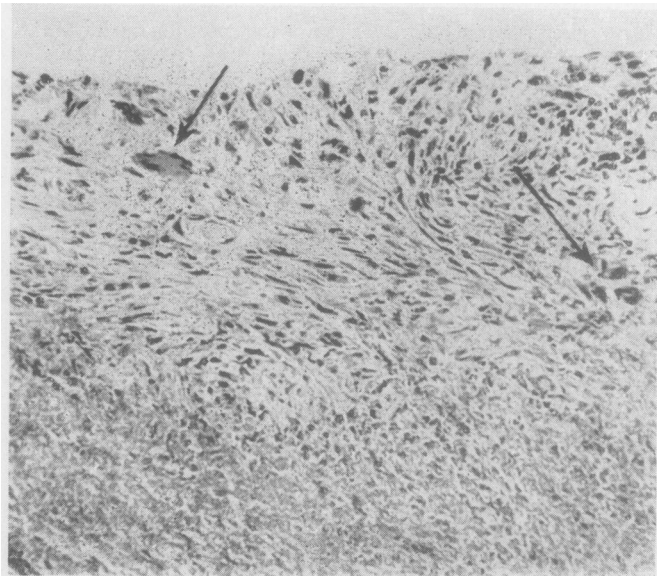


FIG. 6

FIG. 4.—Case 1: Mastoidectomy specimen. Low-power view showing extensive foci of necrosis (darker areas) and intervening fibrosis. Haematoxylin-eosin. $\times 45$.

FIG. 5.—Case 1. Mastoidectomy specimen. "Radiärknötchen," focal collection of more or less radially orientated cells. Haematoxylin-eosin. $\times 600$.

FIG. 6.—Case 1: Mastoidectomy specimen. Multinucleated giant cells (arrowed) in organizing granulation tissue adjoining a necrotic focus (below). Haematoxylin-eosin. $\times 90$.

FIG. 7.—Case 1: Lung. Typical multinucleated giant cells of Wegener's granulomatosis, with hyperchromatic, compact nuclei. Haematoxylin-eosin. $\times 300$.

FIG. 8.—Case 1: Mastoidectomy specimen. Inclusion-body cytomegaly. Haematoxylin-eosin. $\times 700$.

FIG. 9.—Case 1: Lung. Pulmonary arteritis, showing palisading of cells around necrotic media, and thrombosis. Haematoxylin-eosin. $\times 220$.

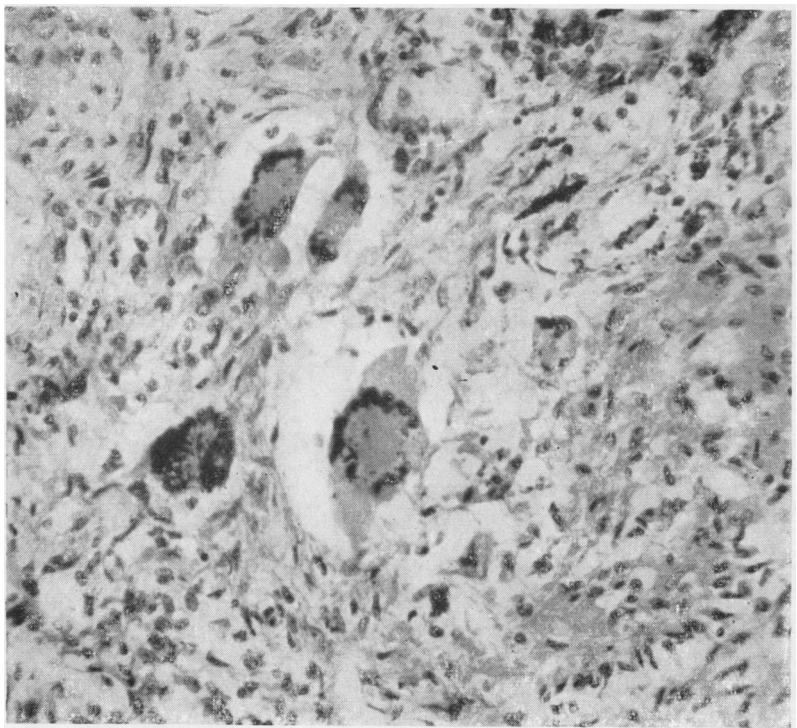


FIG. 7

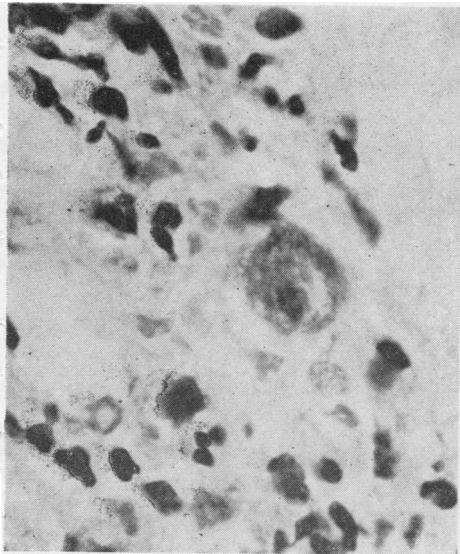


FIG. 8

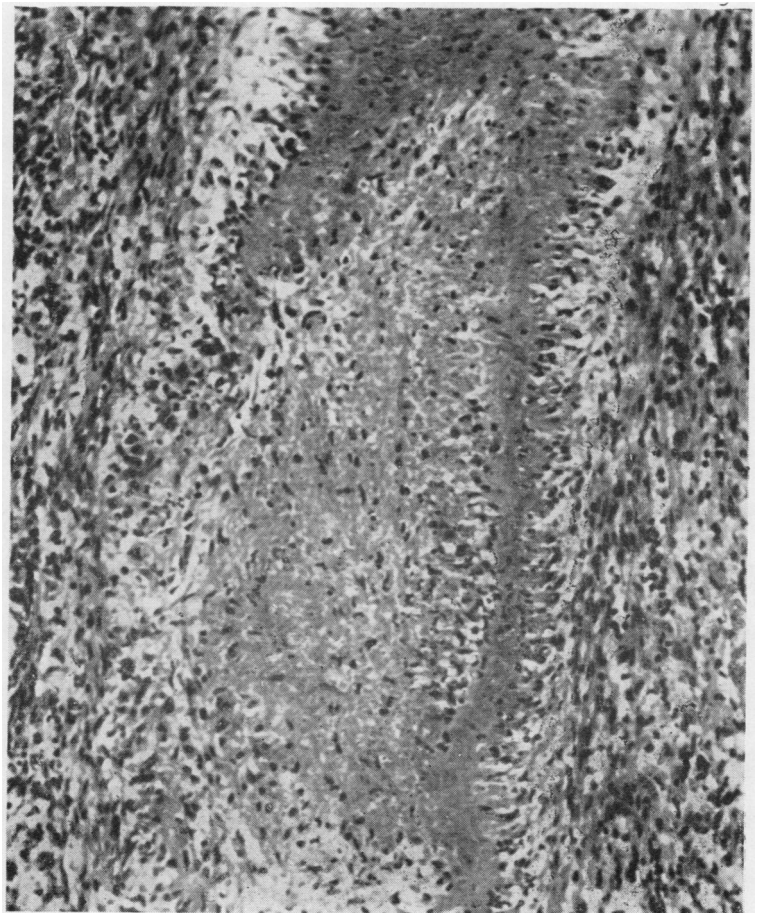


FIG 9

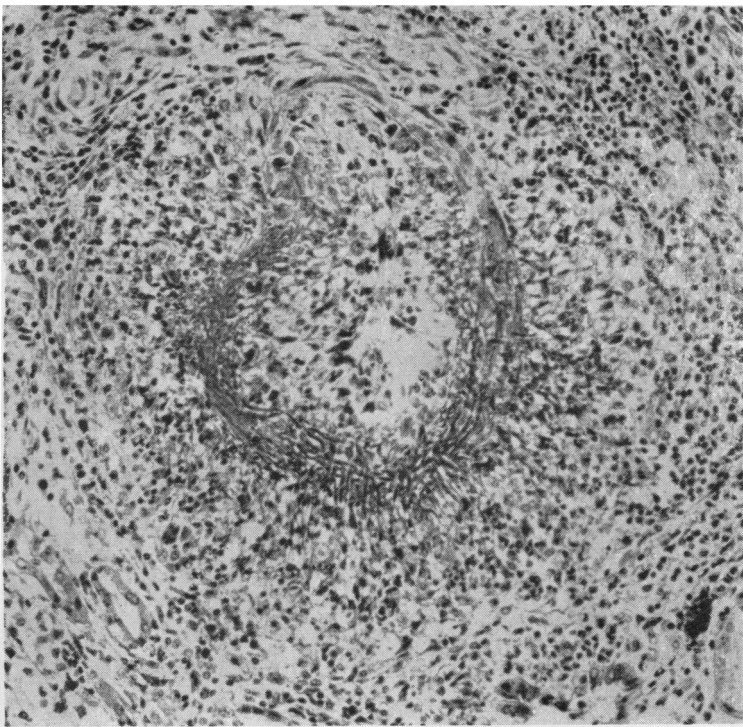


FIG. 10

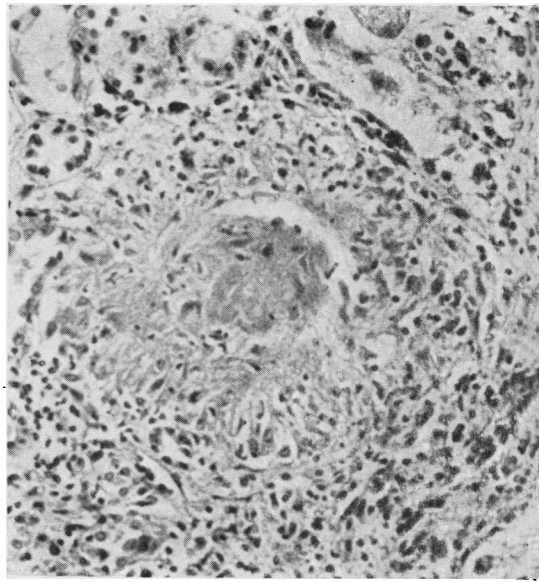


FIG. 12

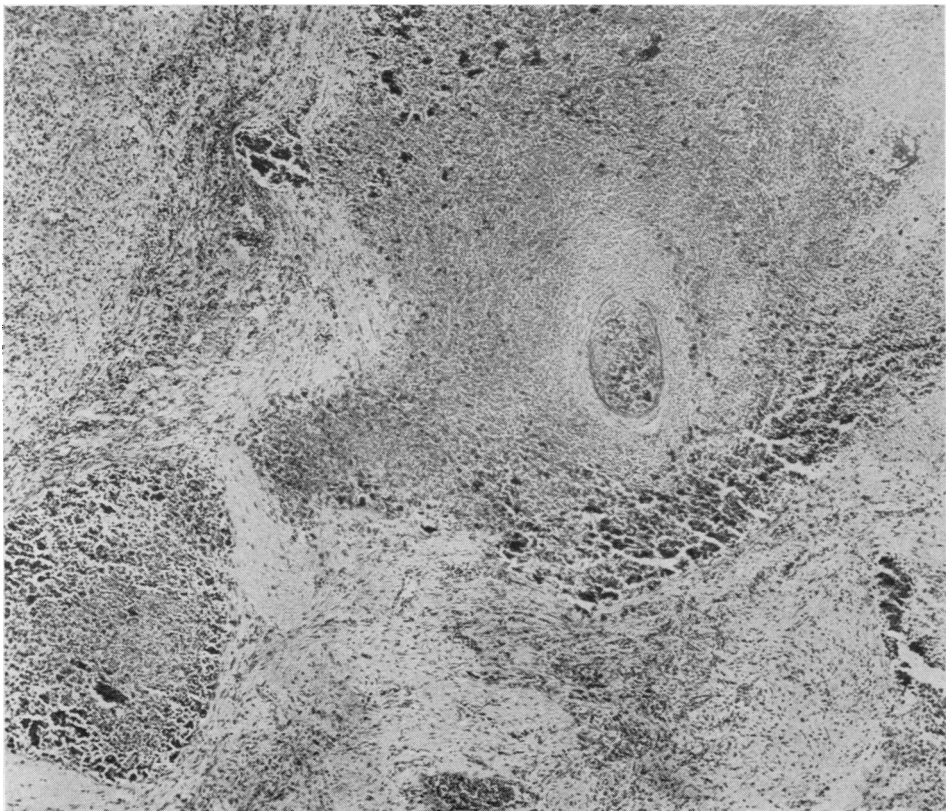


FIG. 11

FIG. 10.—Case 1: Kidney. Acute segmental arteritis. Haematoxylin-eosin. $\times 200$.

FIG. 11.—Case 1: Spleen. "Fleckmilz," infarction due to arteritis; the extensive dark stippling of the dead tissue is due to calcification. Haematoxylin-eosin. $\times 40$.

FIG. 12.—Case 1: Kidney. Granulomatous nephritis of Wegener's disease. Necrosis of the glomerulus with radiating circumglomerular granuloma. Haematoxylin-eosin. $\times 220$.

FIG. 13.—Case 1: Fibrinoid necrosis of part of a glomerulus. Haematoxylin-eosin. $\times 600$.

FIG. 14.—Case 1: Lung. Interstitial fibrosis with preservation of alveolar pattern, conspicuous alveolar cell lining, and intra-alveolar collections of desquamated cells. The picture is that seen in certain cases of the Hamman-Rich syndrome. High magnification showed no evidence of inclusion-body cytomegaly in such fields as this, in contrast to areas such as that shown in Fig. 15. Haematoxylin-eosin. $\times 100$.

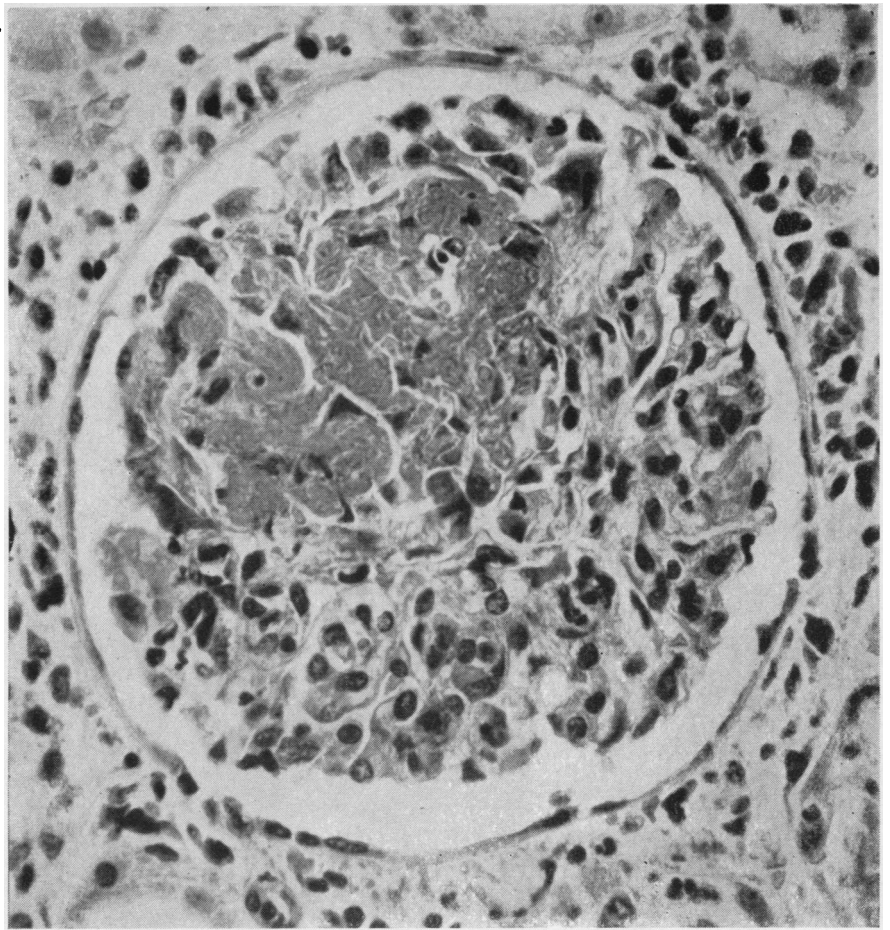


FIG. 13

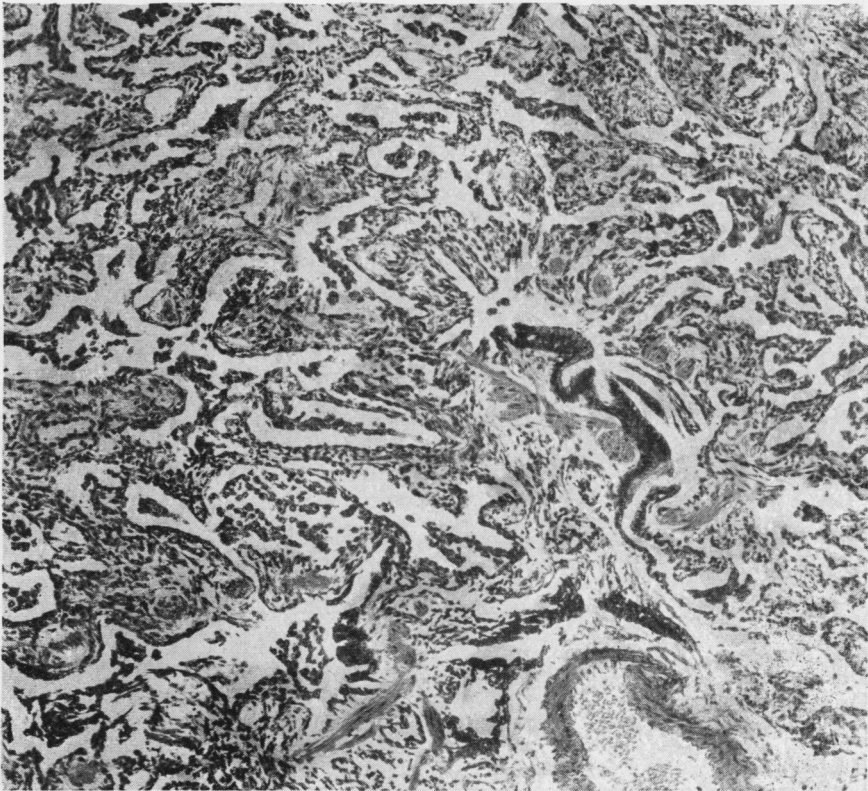

FIG. 14

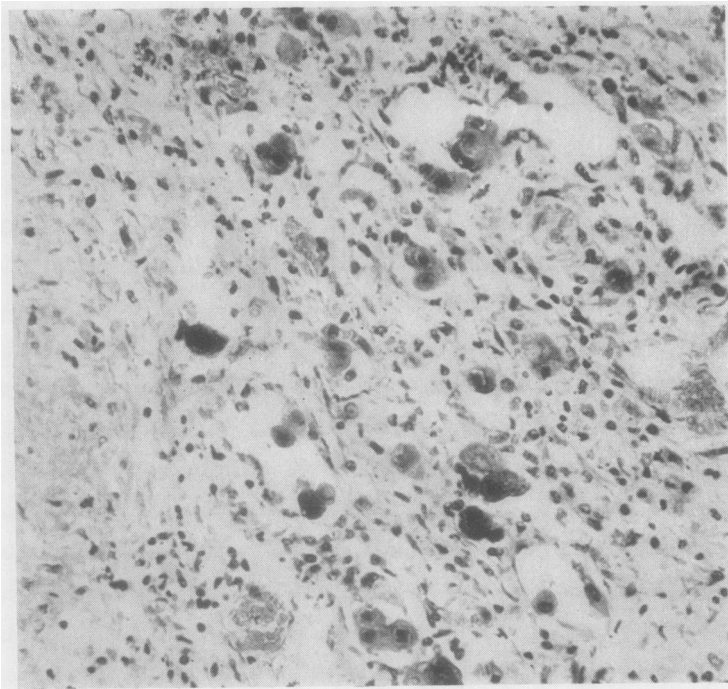


FIG. 15

FIG. 15.—Case 1: Lung. An area of interstitial fibrosis with inclusion-body cytomegaly in the alveoli. The adjacent tissue includes a necrotic focus of Wegener's granulomatosis, with a characteristic multinucleated giant cell. Haematoxylin-eosin. $\times 220$.

FIG. 16.—Case 1: Colonic ulcer: inclusion-body cytomegaly. Extensive infiltration of muscle coat and subserosa by collections of affected cells. At C endothelium of a blood vessel is heavily involved. (A, Auerbach's plexus [normal].) Haematoxylin-eosin. $\times 55$.

FIG. 17.—Case 1: Higher magnification of part of field shown in Fig. 16. $\times 220$.

FIG. 18.—Case 1: Inclusion-body cytomegaly of adrenal cortex. Haematoxylin-eosin. $\times 200$.

FIG. 19.—Case 1: Pneumocystis infection. The lace-like appearance is typical of a colony of *Pneumocystis carinii*. The field is from a focus of terminal suppurative bronchopneumonia quite unrelated to the presence of pneumocystosis. Silver preparation for reticulin; haematoxylin counterstain. $\times 300$.

FIG. 20.—Case 1: Field corresponding to that in Fig. 19, showing colonial appearance more clearly in a periodic-acid-Schiff preparation (Mayer's haemalum counterstain). $\times 300$.

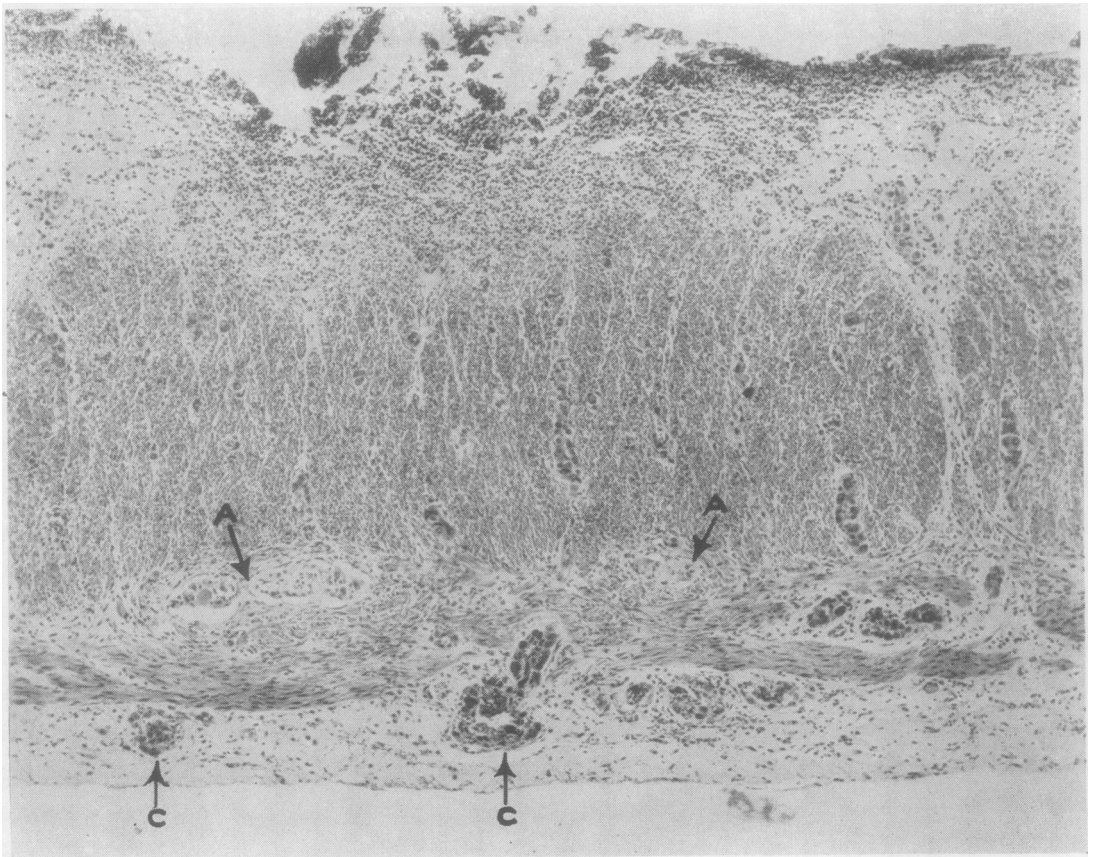


FIG. 16

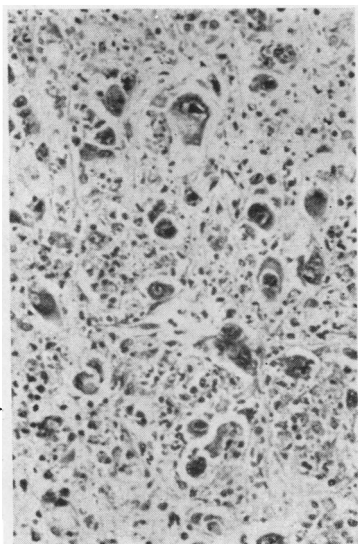


FIG. 18

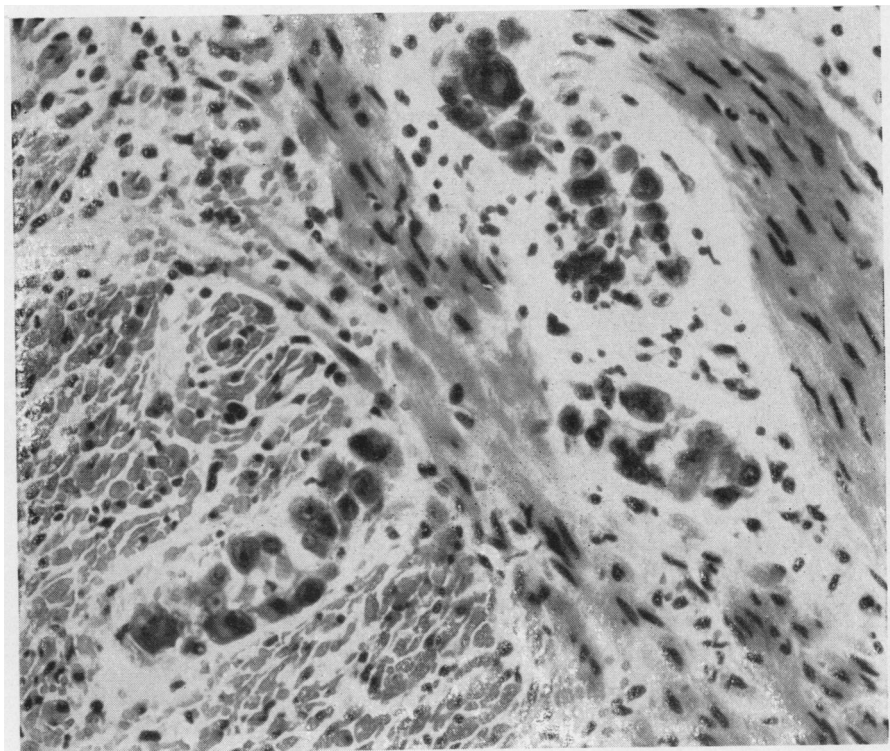


FIG. 17

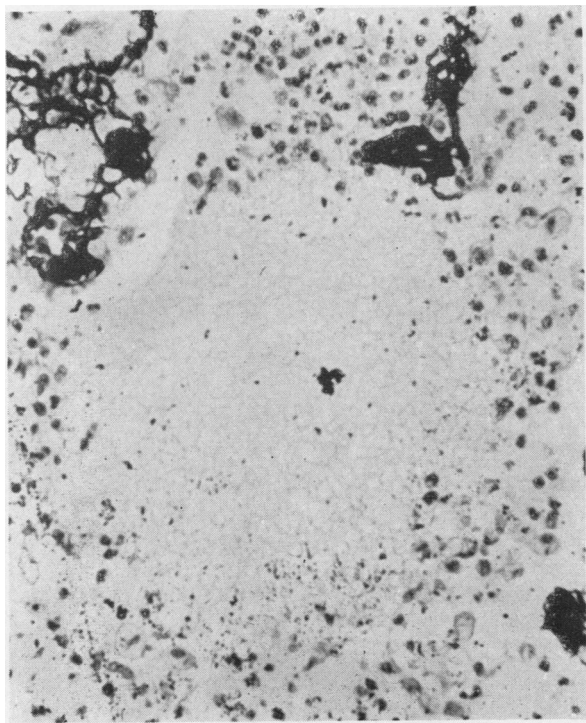


FIG. 19

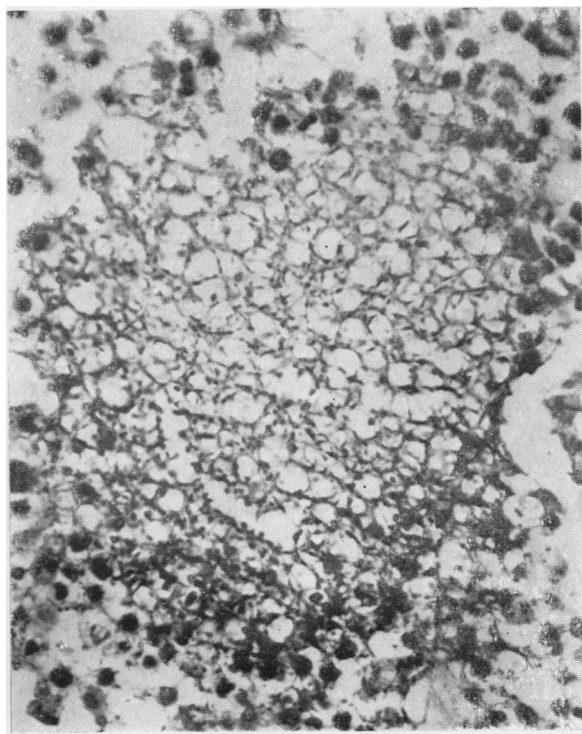


FIG. 20

haemorrhagic manifestations and progressive anaemia in spite of transfusions. Crops of purpura began to appear, without thrombocytopenia.

L.E. cells were looked for on one occasion only: none was found.

It was now (August 26) considered that Wegener's granulomatosis was the diagnosis likeliest to account for the complex clinical picture. Treatment with prednisolone was started (see Table), and continued until the patient's death in uraemic coma on September 16. There was some passing improvement in the first week of this course, the fever and tachycardia disappearing, but the biochemical disturbances became severer and could not be controlled. Her blood pressure was normal until the last week of the illness, when it ranged about 170/100 mm. of mercury. The chest lesions had begun to resolve shortly before the course of prednisolone was begun, and this improvement continued until the week of her death. Purpura recurred three days before her death, but only on the limbs. On September 13 haemoglobin was 7.7 g. per 100 ml.; erythrocytes 2,330,000 per c.mm.; leucocytes 17,000 (98% neutrophils); platelets 38,000 per c.mm.

Necropsy Findings.—The necropsy was performed 22 hours after death. There was considerable purpura on the limbs.

Respiratory System.—The mastoidectomy site had healed. The nasal passages, nasopharynx, larynx, and trachea were healthy. There was suppurative bronchopneumonia in both lungs and some patchy hyperaemia and carnification. Several ill-defined, abscess-like lesions, none more than 2 cm. in diameter, were present in both lungs, accounting for the confluent shadows in the radiographs. Filmy pleural adhesions were present but no active pleurisy.

Cardiovascular System.—Generalized fibrinous pericarditis was present. The myocardium was soft but the heart was otherwise healthy. No thrombosis was found in the heart or elsewhere.

Central Nervous System.—The dural venous sinuses, meninges, and brain were healthy.

Alimentary System.—The only abnormalities were in the liver and colon. The liver (2,365 g.) was pale and appeared to be somewhat fatty; two encapsulated, whitish, ovoid structures (3 by 1 cm., and 2 by 1 cm.) were present within the left lobe, apparently in continuity with portal tracts. The colon near the splenic flexure was intensely hyperaemic throughout an annular zone which contained a few shallow ulcers, the largest of which measured 0.75 by 0.25 cm.; the larger dimension of the ulcers was in the long axis of the bowel.

Lymphoreticular System.—The spleen (225 g.) showed almost complete infarct-like necrosis, only a narrow subcapsular and circumvascular zone appearing to have survived. The splenic artery and vein were healthy. There was no lymphadenopathy.

Urinary System.—The kidneys (left 280 g., right 240 g.) were swollen: the cortex was pale and

contained several anaemic infarcts, none of which was more than 0.25 cm. in its longest dimension. The urinary passages and bladder were normal.

Endocrine System.—The adrenals were pale and soft; the other glands appeared normal. The reproductive organs were healthy.

Histological Studies*

Mastoidectomy Specimen.—The tissue removed during the mastoidectomy eight weeks before death was examined histologically at that time and reported upon as "simple granulation tissue, partly necrotic." It is unfortunate that more attention was not given to the interpretation of this specimen, from which the diagnosis of both Wegener's granulomatosis and cytomegalic inclusion-body disease should have been made. It was originally overlooked that the tissue showed considerably more organization and fibrosis than was consistent with the comparatively short duration (16 days) of acute otitis before the operation. Moreover, there were many necrotic foci which together occupied a considerable proportion of the tissue (Fig. 4): the abundance of nuclear debris in these foci, the unusually sharp demarcation of much of the necrotic matter from the surrounding fibrotic tissue, and the suggestion in places of peripheral histiocytic palisading should have indicated that the appearances were not consistent with a banal suppurative process. In addition, in the more actively inflamed parts there were occasional radiate nodules (Fig. 5), like the *Radiärknötchen* described by Miescher (1942) in erythema nodosum (Reich, 1952). Although these nodules are not specific, recognition of their presence is helpful because they indicate the possibility of an allergic or other unusual reaction. Eosinophils were present but very scanty.

The most important diagnostic feature of this biopsy was the presence of multinucleated giant cells of the type which are so characteristic of Wegener's granulomatosis that when found in necrotic tissue in any part of the respiratory tract they are virtually pathognomonic (Figs. 6 and 7). These cells appear at first sight to be similar to the typical Langhans giant cell of tuberculosis: their nuclei, however, are smaller and more compact than those of the Langhans cell, and are hyperchromatic, even pyknotic, in appearance or, alternatively, show the curious muddy, greyish-lilac colour in haematoxylin-eosin preparations which commonly indicates depolymerization of deoxyribonucleic acid. The nuclei are usually

*All the tissues studied in these three cases were fixed in formal-saline (4% formaldehyde in normal saline).

densely clustered, sometimes in radial formation, at one or both poles of the cell, or form a group at its centre. The cytoplasm of the Wegener cell is more eosinophil and more hyaline than that of the giant cell of tuberculosis.

When cytomegalic inclusion-body disease was recognized in the post-mortem material, the 20 available serial sections of the biopsy specimen were reviewed: two vascular endothelial cells were found which showed the characteristic nuclear changes (Fig. 8).

Post-mortem Material.—Histological examination confirmed the clinical diagnosis of Wegener's granulomatosis and also showed the presence of generalized cytomegalic inclusion-body disease and of pneumocystis pneumonia. The findings relevant to these conditions may most conveniently be dealt with under separate headings, with additional notes on some observations which do not clearly fall into these categories.

Wegener's Granulomatosis.—The pathological criteria for the diagnosis of Wegener's granulomatosis are (1) necrotizing giant-cell granulomatosis of the respiratory tract, with involvement both of the upper air passages (or their adnexa) and of the lungs, (2) necrotizing angitis, and (3) glomerulonephritis. These criteria were amply fulfilled in this case.

(1) The mastoid lesion represented the characteristic upper respiratory tract involvement. In the lungs necrotizing pneumonia typical of Wegener's disease accounted for the macroscopical abscess-like lesions. Fibrosis of some of the pulmonary lesions had converted considerable parts of the affected tissues into scars, still heavily infiltrated by inflammatory cells, with fresh necrotic foci sparsely scattered through the tissue. Tubercle-like formations were seen but were infrequent. Occasionally, a striking focal proliferation of smooth-muscle cells was found in the Wegener lesions, and characteristic Wegener giant cells in these foci sometimes appeared to have developed in such intimate association with muscle cells that their origin from muscle cells seemed possible. Implication of smooth muscle was seen in another form in the necrosis of the media of pulmonary arteries (Fig. 9); marginal histiocytic palisading was also a feature of the arteritic changes. Some of these arteries were filled by completely organized and partly recanalized granulation tissue, presumably following thrombotic occlusion, and their walls were sometimes breached by segmental fibrous scars. The arterial lesions were confined to the foci of diffuse pulmonary fibrosis, and it is

therefore possible that some of these were organized infarcts.

(2) Angitis was found in skeletal muscle, kidneys, pancreas, lungs, and spleen: small arteries and arterioles were predominantly involved, but occasionally also small veins. Some of the lesions were healed or healing; rarely, others, particularly in the kidneys, were in an acute phase (Fig. 10) and indistinguishable from the lesions of acute polyarteritis. Eosinophils were present, but very sparse, in the exudate in the acute lesions. The appearances in the spleen were those of polyarteritis, with infarction, trabeculitis, and folliculitis; parts of the necrotic tissue were heavily calcified (Fig. 11). The two encapsulated lesions in the liver were thrombosed and organizing polyarteritic aneurysms.

(3) Glomerulitis was conspicuous, most of the glomeruli being involved. The lesions were of different ages; some were healing and others were fresh, either with necrosis or with conspicuous granuloma formation involving the glomerulus and the immediately surrounding tissue (Fig. 12).

Findings Reminiscent of Systemic Lupus Erythematosus.—Some glomeruli showed changes which were more typical of systemic lupus erythematosus than of Wegener's disease. These ranged from segmental thrombosis and segmental fibrinoid necrosis (Fig. 13) to the typical "wire-loop" change in the capillary basement membrane. Further, in some of the necrotic foci, for example, in the spleen and in the Wegener lesions in the lungs, haematoxyphil bodies like those of systemic lupus erythematosus were readily found. Protracted search of such areas showed occasional unmistakable instances of phagocytosis of altered nuclei by neutrophil polymorphonuclear leucocytes, an observation which is possibly the histological equivalent of the L.E. phenomenon (Symmers, 1958).

Interstitial Pulmonary Fibrosis (Hamman-Rich Type).—In parts of the lungs there were foci of purely interstitial fibrosis, and the alveolar pattern was preserved: the alveoli in these foci contained aggregates of large mononuclear cells (Fig. 14). The picture was indistinguishable from that which may be seen in advanced stages of progressive interstitial pulmonary fibrosis in the Hamman-Rich syndrome (Hamman and Rich, 1944; Peabody, Buechner, and Anderson, 1953). These foci could not be clearly related either to the lesions of Wegener's granulomatosis or to the interstitial pneumonia associated with infection by *Pneumocystis carinii* (see below), but the latter would be a likelier origin in view of the destructive

nature of the Wegener lesions. In infancy both cytomegalic inclusion-body disease and pneumocystis infection may cause interstitial pneumonia and eventually interstitial pulmonary fibrosis; in the present case the cytomegalic infection was very much more widespread than the interstitial fibrosis, and although it was more prominent in areas of fibrosis than elsewhere in the lungs (Fig. 15) there were fibrotic foci which were free from cytomegaly (Fig. 14).

Cytomegalic Inclusion-body Disease.—Inclusion-body cytomegaly was present in every tissue examined. The heaviest involvement was in the colonic ulcers, lungs, spleen, adrenals, and skin. The colonic ulcers, in the absence of any other apparent local cause, such as arteritis, may have been due to the viral infection; there were many conspicuous accumulations of affected cells, probably histiocytes, in the mucosa and submucosa forming the edges and floor of the ulcers, and aggregates of these cells were present in the muscle coats, following the lymphatic pathways, and in the subserosa. The appearances at low magnification were remarkably like those of carcinomatous infiltration (Fig. 16), but higher magnification immediately showed their real nature (Fig. 17). Vascular endothelial cells were conspicuously involved in the vicinity of the colonic lesions (Fig. 16), and mesothelial cells were occasionally affected. Throughout the affected tissues in all parts of the body, however, involvement of free-lying cells in the interstitial tissues, presumably histiocytes, predominated.

Epithelium was relatively seldom affected, except in the adrenals; occasional cells of the kidney (mainly proximal convoluted tubules), pancreas (ducts and islet cells), and bronchial glands (Fig. 2) were involved. In the adrenals there were many foci of heavy involvement of the cortical cells (Fig. 18), and there was extensive central necrosis in the larger lesions: the shadow cells in these necrotic foci still showed clear traces of cytomegalic changes, and any possibility that the infection was secondary to the death of the tissue seemed to be excluded.

In the lungs inclusion-body cytomegaly was found mainly in two situations, in ulcers of the bronchi and in the alveoli (Fig. 15). There was nothing to suggest that the bronchial ulcers had occurred as part of the Wegener's disease; their appearances were comparable with the cytomegalic ulcers in the colon.

In the spleen it was the cells lining the sinusoids and occasional free pulp cells which were involved. In the infarcted parts of the spleen inclusion-body

cytomegaly was still recognizable among the shadow cells, and in the calcified parts all stages of calcification of the infected cells could be seen.

In the skin involvement was heaviest in purpuric areas, and capillary endothelium was predominantly infected. There were no other lesions in the skin.

The findings strongly suggested that the colonic and bronchial ulceration, the cutaneous purpura, and much of the focal adrenal cortical necrosis were due directly to cytomegalic inclusion-body disease.

Adrenal Cortical Necrosis.—As well as the necrosis of cytomegalic foci there were many smaller foci of necrosis in which no evidence of infection was to be seen: these foci were of the cytolytic type such as is seen after treatment with cortisone and its analogues.

Parenchymatous Cytocalcinosis.—Calcification of parenchymatous cells, sometimes in foci of necrosis and sometimes without other apparent alteration in the affected field, was present in small areas of myocardium, kidneys (tubular epithelium), liver, adrenal cortex, anterior lobe of the pituitary, and thyroid. It seems probable that this, and doubtless also the widespread calcification of the necrotic splenic tissue, resulted from the disturbances in acid-base balance which were so troublesome clinically.

Pulmonary Infection by Pneumocystis carinii.—When it was found that cytomegalic inclusion-body disease was present the available sections of lung were searched for evidence of pneumocystis infection, in view of the known association of the two infections. At first nothing to suggest pneumocystis was found in the haematoxylin-eosin preparations of the eight blocks of lung tissue available. However, when examining the reticulin pattern in some silvered preparations in which a light haematoxylin nuclear stain had been used a single, clear, rounded area was noticed in a bronchopneumonic area (Fig. 19); at first this was thought to be an artefact due to the nuclear stain failing to take, and no particular attention was paid to it. Later, while looking at a periodic-acid-Schiff preparation of an adjacent section from the same block it was seen that the corresponding field was in fact occupied by a network of Schiff-positive material enclosing minute rounded spaces (Fig. 20). This so closely resembled a colony of pneumocystis that further blocks of lung tissue were prepared: two of these contained small areas of typical plasma-cell interstitial pneumonia with alveolar pneumocystosis (Fig. 3).

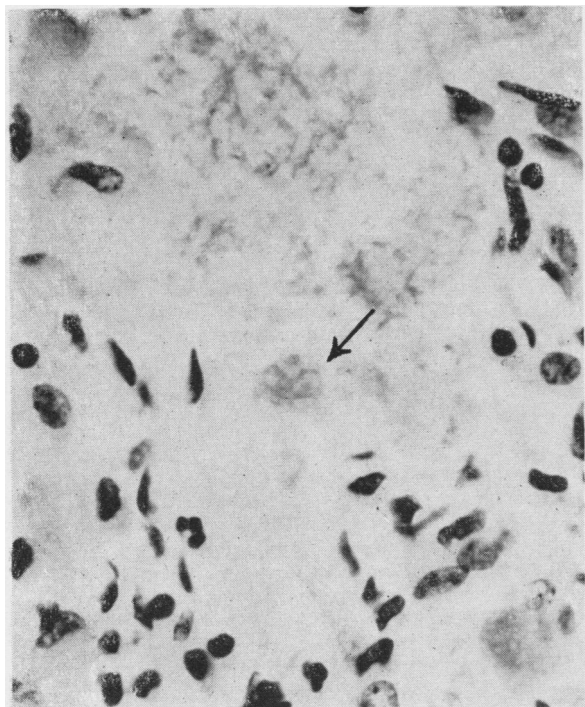


FIG. 21.—Case 2: *Pneumocystis* infection. An alveolus filled with the organisms, of which only the arrowed cluster and occasional single parasites have shown at all well in spite of the periodic-acid-Schiff reaction (Mayer's haemalum counterstain). $\times 600$.

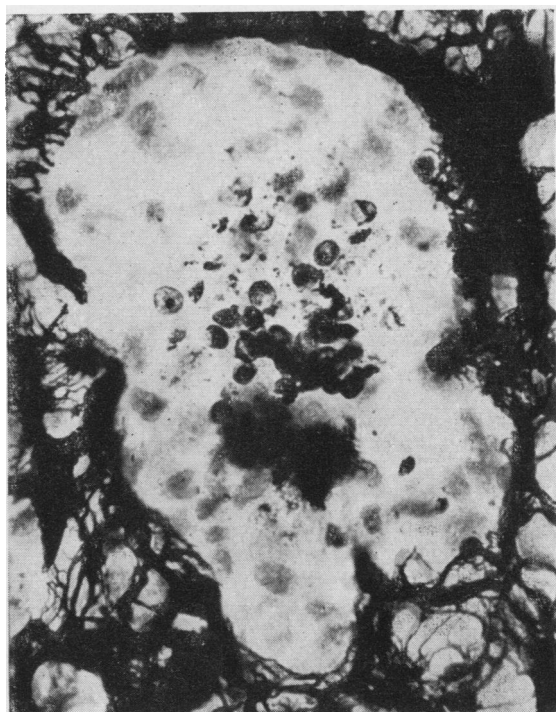


FIG. 22.—Case 2: Field corresponding to that in Fig. 21, showing individual organisms clearly (and some of their internal structure). Silver preparation by Mr. F. D. Humberstone (1958). $\times 600$.

Although the appearance of the colonies of *Pneumocystis carinii* is distinctive and practically unmistakable in haematoxylin-eosin and periodic-acid-Schiff preparations (Fig. 3) the individual organisms are not readily demonstrable by these methods (Fig. 21); they can be beautifully shown by silver methods as used by Le Tan (1954), and particularly in a modification developed by F. D. Humberstone (1958) in my laboratory for use on paraffin sections of formol-fixed material (Fig. 22). The Gomori methenamine (hexamine) silver-nitrate method as modified by Grocott (1955) also gives a very clear and delicate picture of these organisms.

Commentary on Case 1

Steroids have been temporarily helpful in some cases of Wegener's granulomatosis, and sometimes have induced remissions of considerable duration (Fahey, Leonard, Churg, and Godman, 1954). Plummer, Angel, Shaw, and Hinson (1957a) stressed the desirability of beginning to give steroids before the onset of renal failure. Steroid therapy was begun late in the course of the case reported here,

which illustrated the characteristically unremitting progress of the renal involvement in spite of considerable healing of the pulmonary and arteritic lesions and complete healing of the disease in the mastoid. How far treatment contributed to healing is debatable, and it is not clear why the renal changes did not react correspondingly well: at least it may be said that the histological findings are an encouragement to continue to try the effect of steroids in future cases of Wegener's disease, in spite of the attendant risks.

Wegener's granulomatosis is not to be confused with the so-called lethal midline granuloma of the face ("granuloma grangerescens") (see Resnick and Skerrett, 1959). Its kinship to polyarteritis, and, more remotely, to systemic lupus erythematosus, places it within the heterogeneous group of diseases primarily affecting the connective tissues (the so-called "collagen diseases"). The finding in the case under discussion of histological features usually associated with systemic lupus erythematosus (haematoxyphil bodies; phagocytosis of altered nuclei; glomerular changes) reflects the overlap of the pathogenic

manifestations of the two entities, but is not evidence of any particularly close relationship between them.

This case, like others which have been reported, illustrated the proneness of patients with Wegener's granulomatosis to show unusual sensitivity reactions, in this case urticarial and febrile reactions during blood transfusions. The erythematous skin rash was also, for a time, thought to be due to sensitivity (to penicillin), but in fact it may have been related to the developing purpura, which in turn was probably due, at least in part, to cytomegaly affecting the small blood vessels. (Thrombocytopenia was not present until the patient was moribund.) Quite apart from sensitization being considered as a symptom of Wegener's disease, sensitivity to drugs or to micro-organisms has been suggested as a factor in its causation. It is therefore pertinent to mention that some authors (Plummer *et al.*, 1957a) have suggested the need for special care in the use of chemotherapy and antibiotics in cases of this disease because they might prove more dangerous than useful.

There is no reason to believe that either cytomegalic inclusion-body disease or the concomitant pneumocystis infection caused or contributed to the development of Wegener's disease in this case: indeed, there are more cogent reasons for accepting the converse view, that the latter predisposed to the infections. Whether the antibiotics and prednisolone influenced the course of the infections is unanswerable. It is worth noting that steroids have been used as treatment for cytomegalic inclusion-body disease in infancy, being given because of their anticipated effect on the thrombocytopenia, haemolytic anaemia, and hepatitis which are associated with the severest form of the generalized congenital infection: success has been claimed for this treatment in three such cases (Margileth, 1955; Birdsong, Smith, Mitchell, and Corey, 1956; van Gelderen, 1959). While the cause of the anaemia and thrombocytopenia in the case reported here was obscure there may well have been, as in the severe congenital infections, more than just a chance association with the inclusion-body cytomegaly.

Case 2: Generalized Cytomegalic Inclusion-body Disease, Pneumocystis Pneumonia, Recurrent Cryptococcal Pneumonia, and Thrombotic Purpura

A 47-year-old man was admitted to a nursing-home because of acute haemolytic anaemia. His health had previously been good, apart from a lobectomy six years earlier following the chance radiological finding

of a peripheral lung shadow: histological study had shown this to be a localized cryptococcal granuloma, and no sign of infection elsewhere was found. Eight weeks before his admission to the home with haemolytic anaemia he had an attack of acute pharyngitis (temperature 104° F. [40° C.]) during an outbreak of streptococcal infection. He was given oxytetracycline (total dose 5 g. in five days): the infection quickly subsided, but he was left feeling unexpectedly tired and weak. Examination of the blood on admission showed 2,000,000 erythrocytes per c.mm.; haemoglobin 6.0 g. per 100 ml.; leucocytes 6,900 per c.mm. (normal differential count); spherocytes and normocytes were conspicuous in the films. Coombs tests (direct and indirect) were negative. A series of blood transfusions had no significant effect on the haematological findings. Eight days after admission purpura began to appear; platelet count 34,000 per c.mm. He became drowsy and confused, with muscle twitching and transient episodes of choreiform movements. Blood urea 36 mg. per 100 ml.; serum bilirubin 4.8 mg. per 100 ml. Urine analysis showed protein +; urobilinogen +++; many erythrocytes in deposit. His temperature since admission had ranged between 99 and 101.8° F. (37.2–38.8° C.), and oxytetracycline was given throughout the first 14 days in the home (0.25 g. by mouth six-hourly, total dose 14 g.). On the eighth day it was realized that he had thrombotic purpura: steroid therapy was started (hydrocortisone 50 mg. by mouth thrice daily, total dose 2,100 mg. in 14 days), and it was decided to perform splenectomy without delay. At laparotomy no trace of the spleen was found; there were no splenunculi or haemolymph nodes, and no serosal or retroperitoneal splenosis. The opportunity to take tissue for histological confirmation of the diagnosis was missed. With the administration of hydrocortisone his condition began to improve. His temperature became normal, purpura faded, and the neurological and mental disturbances disappeared. Six blood transfusions, each of half a litre, were given during the eight days following the laparotomy: the erythrocyte count rose from 2,000,000 per c.mm. to 3,900,000 a fortnight later, and evidence of haemolysis disappeared. The platelet count also rose steadily, but more slowly, and did not pass 120,000 per c.mm. On the fourteenth day after the operation (11 weeks after the initial pharyngitis) he died suddenly.

Necropsy Findings.—The necropsy was limited by request to examination of the thoracic and abdominal viscera, with removal of no more material for histological examination than was essential for diagnosis. A coiled embolic thrombus, clearly a cast of the main veins of one leg, was impacted at the bifurcation of the main pulmonary artery. The lungs were hyperaemic, and there was a sparse, patchy consolidation in both; the consolidated foci were greyish red, dry, and mostly about 1 cm. in diameter, and they had no predilection for any particular part of the lungs.

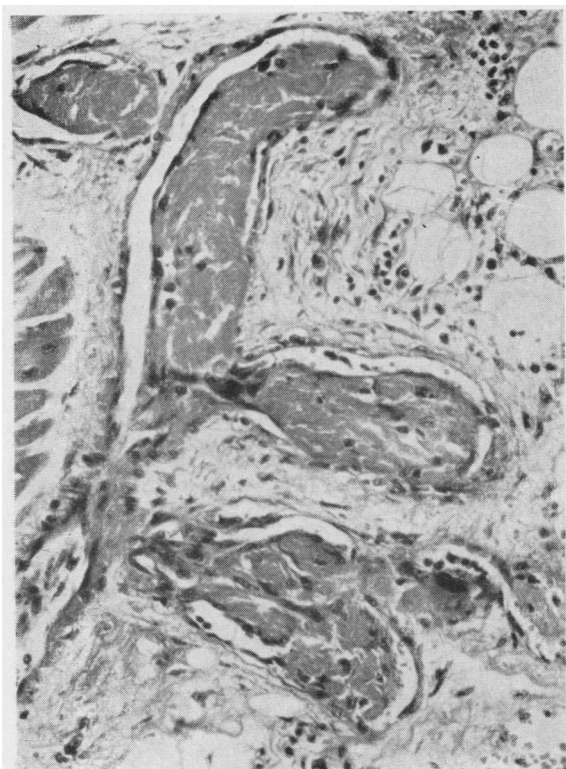


FIG. 23

Histological Findings.—Thrombotic microangiopathy (Fig. 23), typical of thrombotic purpura, was found in all the organs sectioned (heart, lungs, adrenal, and kidney). Inclusion-body cytomegaly was widespread in the lungs and adrenal, with bronchial ulceration and extensive adrenal cortical necrosis, as in Case 1; occasional affected cells were found in renal glomeruli; the section of heart (wall of left ventricle) was free from involvement. The consolidated foci in the lungs were typical of pneumocystis infection, with plasma-cell interstitial pneumonia and alveolar pneumocystosis (Figs. 21 and 22); pneumocystis was also occasionally found in the interstitial tissue itself, as described by Hamperl (1957). A single small focus of active torulosis was found in one of the four blocks of lung tissue which were sectioned (Fig. 24); it is not known from what part of the lungs this block came. No other lesions containing cryptococci were found.

It was impossible to obtain sections of the pulmonary lobectomy specimen for review.

Commentary on Case 2

All the criteria for the clinical diagnosis of thrombotic purpura were present in this case, and

FIG. 23.—Case 2: Myocardium. Typical thrombotic microangiopathy of thrombotic purpura. Haematoxylin-eosin. $\times 220$.

FIG. 24.—Case 2: Lung. Cryptococcal pneumonia. Periodic-acid-Schiff; Mayer's haemalum. $\times 200$.

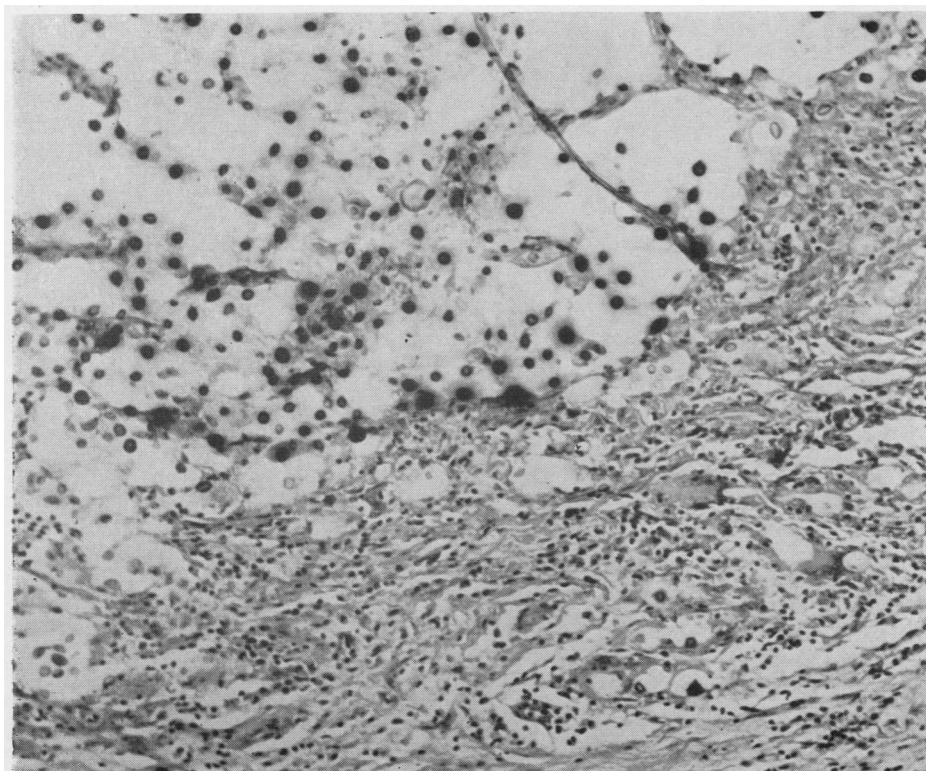


FIG. 24

this was confirmed by the typical histological findings *post mortem*. Although the number of acceptable published cases of thrombotic purpura is now over 150, the clinicopathological picture defined in the earlier studies has not been much amplified. The diagnosis is now made during life in a higher proportion of cases, and, although treatment is unavailing in the great majority of cases, large doses of steroids (with or without splenectomy) have been followed by long-lasting remissions in a few cases (Burke and Hartmann, 1959), and there is therefore some hope that the hitherto uniformly mortal outcome may at least occasionally be avoided. This might have been so in the case described here, in view of the remarkable remission, which, however, was cut short by the pulmonary embolism.

It is likely that the steroid therapy, and perhaps the antibiotics as well, acted in association with thrombotic purpura in this case, as with Wegener's disease in Case 1, to predispose to the generalized cytomegalic inclusion-body disease. The same factors may have been responsible for the reactivation of the cryptococcal infection, which, in view of the rarity of torulosis, is likelier to have been dormant in the lung since the lobectomy six years earlier than to have been a fresh infection.

The association of torulosis with pneumocystis infection has been recorded only once before (Winslow and Hathaway, 1959). The case was one of chronic lymphatic leukaemia, and the patient had been treated with *x* rays, prednisone, chemotherapy (nature not specified), and the instillation of radioactive gold into the body cavities. Necropsy showed leukaemia, disseminated torulosis, and pulmonary pneumocystosis. (I am indebted to Lieutenant-Colonel Winslow for the information that a histoplasmic granuloma was also found in this case when further sections of the lungs were examined.)

Thrombotic purpura, like Wegener's disease, has features which relate it to the group of collagen diseases, and this adds to the interest of the apparent role of these two diseases in predisposing to the infections described.

Agnesis of the spleen is very rare (Putschar and Manion, 1956); it is not likely to have been of aetiological significance in the development of thrombotic purpura, or of any of the associated infections. It is worth mentioning that in another case of thrombotic purpura (Symmers, 1956, Case 1) the spleen had been removed surgically because of traumatic rupture some years before the onset of this disease.

Case 3: Generalized Cytomegalic Inclusion-body Disease, Pneumocystis Pneumonia, Tuberculosis, and Hodgkin's Disease

The patient, aged 37, had had Hodgkin's disease for 18 years. This presented with unilateral cervical lymph-node enlargement, first noticed during medical examination for military service, and treated then by block dissection and deep *x*-ray therapy. The histological findings at that time could not be reviewed, but sections were available from a biopsy performed when cervical lymphadenopathy recurred six years later: this biopsy was originally described as "typical of Hodgkin's disease," but the picture was that which now is often known as the indolent (or so-called "benign") form of Hodgkin's disease ("Hodgkin's paragranuloma"). Deep *x*-ray therapy was followed by regression. A further six years later there was fresh lymph-node enlargement, this time involving cervical, axillary, and mediastinal nodes. A cervical node showed the typical histological picture of the ordinary form of Hodgkin's disease. Over the next five years the disease was with some difficulty kept under control by treatment with deep *x* rays interspersed with courses of cytotoxic drugs. The drugs used were mustine (nitrogen mustard), tretamine (triethylene melamine), chlorambucil ("leukeran"), and the folic-acid antagonist teropterin: each in turn produced a striking but short-lasting remission, each recurrence proving to be resistant to further administration of the drug last used. During the last year of his illness the patient's general condition became progressively poorer, and although he tolerated treatment less well courses of deep *x*-ray treatment and mustine were continued. Leucoerythroblastic anaemia developed, and repeated blood transfusions were needed. Three months before his death symptoms of subacute meningitis appeared. It was thought that this might prove to be due to torulosis, in view of the recognized liability of Hodgkin's disease to be complicated by this infection; however, repeated direct and cultural examinations of the cerebrospinal fluid showed tubercle bacilli and no cryptococci. No sign of tuberculosis was found clinically elsewhere; there was nothing to suggest tuberculosis in the chest radiographs, and no tubercle bacilli were found in the sputum. The meningitic symptoms subsided on treatment with streptoducin (0.5 g. intramuscularly twice daily for five weeks, and then daily for three weeks, total dose 44 g.), isoniazid (25 mg. intrathecally daily for seven days, total dose 175 mg.), and sodium aminosalicylate (3 g. by mouth four-hourly for eight weeks, total dose 1,000 g.). His general condition continued to deteriorate in spite of the response of the meningeal infection; he died in a state of cachexia.

Necropsy Findings. — There was widespread involvement of the lymph nodes, spleen, liver, and bone marrow by Hodgkin's disease, with a few deposits in the kidneys, testes, and lungs. A small focus of partly excavated but fibrotic tuberculosis was

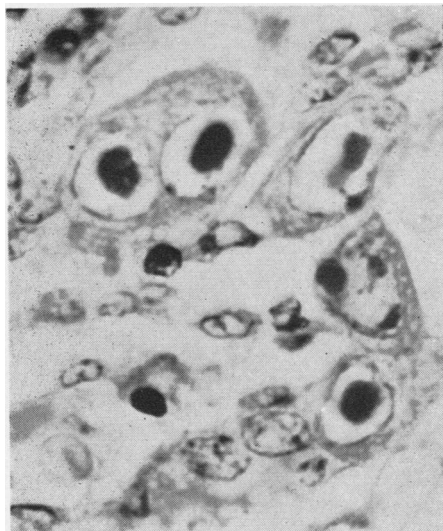


FIG. 25.—Case 3; Lung. Inclusion-body cytomegaly affecting several alveolar cells: typical "owl's eyes" appearance. Haematoxylin-eosin. $\times 1,000$.

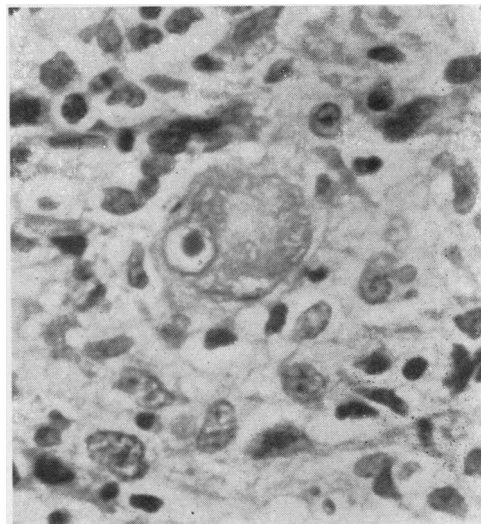


FIG. 26.—"Owl's eye" nucleus in a multinucleated giant cell in a lesion of Hodgkin's disease: such nuclei may be met with in Hodgkin's lesions in the absence of salivary-virus inclusion-body cytomegaly. Haematoxylin-eosin. $\times 600$.

present in the apical part of one lung; an attempt to isolate tubercle bacilli from this lesion was not successful. There was widespread suppurative bronchopneumonia. No other macroscopical abnormalities were recorded. Permission to examine the brain and spinal cord was not obtained.

Histological Findings.—The biopsy findings have been summarized in the case history. The sections of the post-mortem material confirmed the naked-eye findings; the lesions of Hodgkin's disease were largely fibrotic, but the fibrous tissue enclosed many islands of typical, active Hodgkin's disease. Alveolar pneumocystosis was found in two of the six pieces of lung examined: plasma-cell and lymphocytic infiltrate was present in the septa in these foci, but was less abundant than in Cases 1 and 2. Inclusion-body cytomegaly was widespread, with particularly heavy involvement of the lungs (Fig. 25) and adrenals, as in the other two cases; bronchial ulceration and necrosis of the affected areas of adrenal cortex were particularly marked. Endothelial and interstitial cells in the spleen, lymph nodes, and bone marrow were commonly affected by this infection: in spite of the superficial resemblance between the nuclei of the atypical reticulum cells of the Hodgkin lesions and those affected by inclusion-body disease, there was no real difficulty in distinguishing the two.

Commentary on Case 3

Little need be said about this case, as most of the points which it illustrates have been covered in the commentaries on the preceding cases. The main difference from the other cases was that the

patient was not given steroid therapy. On the other hand, in addition to streptomycin and repeated blood transfusions he had been heavily treated with cytotoxic drugs, which are known to lessen resistance to some forms of infection, and he had also had sodium aminosalicylate and isoniazid shortly before his death. Hodgkin's disease, in common with other malignant diseases arising in the lymphoreticular system, has been recorded before in cases of cytomegalic inclusion-body disease, of which it is presumably one of the predisposing causes, as it is of torulosis (see Symmers, 1957). The finding of tuberculosis and not torulosis as the cause of the meningitis should not have been unexpected, for the liability to tuberculosis of patients with Hodgkin's disease was well known long before the comparable liability to torulosis and other fungal infections was recognized.

Discussion

The importance of these three cases of cytomegalic inclusion-body disease is not the rarity of this infection in adults but its severity and the circumstances of its occurrence. Although its effect on the course of the underlying disease cannot be defined, it should be looked upon as a grave complication. This is suggested, for instance, by the extent of the adrenal changes (which in Cases 1 and 2 were possibly complicated

by adrenocortical necrobiosis associated with steroid therapy), and in Case 1 by the severe melaena from the colonic ulcers and by the purpura. The extent to which the underlying disease and the treatment with antibiotics, steroids, or chemotherapy predisposed to the infection cannot be assessed; it is likely that the effect of each was enhanced by the other, although it is not known by what mechanism resistance can be so altered that an infection which seems ordinarily to occur only in babies, and then usually as a trivial infection confined to salivary glands, can become established as a dangerous generalized disease in adults. The diseases which have been recorded as predisposing to cytomegalic inclusion-body disease and its concomitant pneumocystis pneumonia include leukaemias and refractory anaemias, as well as Hodgkin's disease (and some other diseases of the lymphoreticular system): it is not surprising to find that diseases like Wegener's granulomatosis and thrombotic purpura, belonging to the group of disorders of the connective tissues, may also be liable to these infective complications. The diseases which predispose to these two infections are known also to predispose to some other unusual infections (torulosis, mucormycosis, toxoplasmosis, *Pasteurella septica* infection), and also to unusual disseminated forms of infection (tuberculosis, leprosy, moniliasis, aspergillosis, histoplasmosis) which in their usual manifestations are more or less commonplace in the communities to which the patients belong. It is relevant that certain therapeutic agents, including antibiotics, steroids, and some other drugs, e.g., sex hormones and cytotoxic drugs, and also radiotherapy, may likewise predispose to these unusual or atypical forms of infection. There is also experimental evidence, for instance, that steroid administration predisposes to pneumocystis pneumonia (Weller, 1955; Ricken, 1958).

As well as considering the possible interaction of two predisposing factors (the underlying disease and the treatment given) it is necessary to consider a third fundamental aetiological factor, the portal of entry of the infection. It is possible that the salivary virus is already present in dormant state in the tissues: it is likely that in man, as in animals, part of the population carries the virus, and that most of its hosts have enough immunity not to become ill. By analogy with other infections, an alteration in the host's immunological state might permit the virus to multiply, and the characteristic cell changes would then appear.

It is commonly stated that the salivary glands are not affected in adults with inclusion-body cytomegaly, in contrast with the sialotropism of the infection in babies. In most of the published cases in adults there is no mention of histological study of salivary glands, and in the cases reported in this paper no salivary glands were sectioned. Regular sectioning of tissue from the sub-mandibular gland or, preferably, the parotid, in cases of this infection in adults is needed before a factual assessment of their supposed freedom from involvement can be made.

It has been suggested that the virus of inclusion-body cytomegaly may have been transmitted by blood transfusion in some of the published cases of this disease in adults, particularly as seven of these patients had blood diseases necessitating repeated transfusions. The histological findings in the mastoidectomy specimen in Case 1 showed that the infection was already present before the patient had any transfusions. For various reasons this route of infection, while possible, seems to be an unlikely one. If the infection is exogenous, and not the result of reactivation of a dormant virus in the patient's tissues, the likeliest route would presumably be droplet infection of the respiratory tract.

In all three of the cases reported here there was considerable ulceration of the bronchi, and in Case 1 there were also colonic ulcers; all of these ulcers were heavily affected by inclusion-body cytomegaly. There was no evidence that the ulceration was due to any of the associated diseases, and it is possible, although unproved, that they resulted directly from the viral infection. If this were the case they represent a possible portal of entry for the infection.

With regard to the recognition of cytomegalic inclusion-body disease, the only diagnostic difficulty arises in interpreting the nature of the alteration in those cells in which intracytoplasmic inclusions do not form, particularly histiocytes or other interstitial cells in the connective tissues. Occasionally, as in the intestinal muscle coats in the vicinity of the colonic ulcers in Case 1, the histological appearances may somewhat resemble carcinomatous infiltration until studied under high magnifications. It is also worth a mention that the cell affected by inclusion-body cytomegaly has a superficial likeness to the atypical reticulum cells of reticulosarcomas and of Hodgkin's disease, with their large nucleus, distinct nuclear membrane, clear nucleoplasm, and unusually conspicuous nucleolus (Figs. 25 and 26).

The failure to recognize the cytomegaly in the mastoid tissue in Case 1 until the biopsy sections were reviewed, after the diagnosis had been made *post mortem*, indicates the need for the histologist to be on the look-out for this disease in biopsy material. It will be interesting to learn whether generalized cytomegalic inclusion-body disease is met with oftener as the present emphasis on treatment with antibiotics, chemotherapeutic drugs, and steroids continues. The infection is likelier to have its main practical importance in cases of diseases like sarcoidosis than in those which in any case are likely to prove mortal. In sarcoidosis, when appropriately treated, the prospect of recovery should be good: but sarcoidosis, like Hodgkin's disease, affects the lymphoreticular system predominantly, and therefore can seriously interfere with the body's defences against infection. By analogy with Hodgkin's disease, and with its own liability to predispose to torulosis and some of the other infections noted above (Plummer *et al.*, 1957b), sarcoidosis may prove to be one of the diseases which predispose to generalized cytomegalic inclusion-body disease, particularly if the defences have been further weakened by the effects of drugs.

It is a pleasure to express my thanks to my colleagues, Dr. H. S. Baar, Dr. M. Bodian, Dr. W. E. D. Evans, Dr. N. E. France, Professor H. Hamperl, Dr. N. S. Plummer, Dr. G. A. C. Summers, and Mr. Lionel Taylor, for allowing me access to their records and material in the preparation of this paper, for comparative material from other cases, and for permission to publish the case histories and necropsy reports. My thanks are also due to Mr. F. D. Humberstone, Mr. K. R. James, and Mr. K. W. Iles for their technical and photographic collaboration.

REFERENCES

- Baar, H. S. (1955). *J. clin. Path.*, **8**, 19.
 Birdsong, McL., Smith, D. E., Mitchell, F. N., and Corey, J. H., Jr. (1956). *J. Amer. med. Ass.*, **162**, 1305.
 Burke, H. A., Jr., and Hartmann, R. C. (1959). *Arch. intern. Med.*, **103**, 105.
 Cappell, D. F., and McFarlane, M. N. (1947). *J. Path. Bact.*, **59**, 385.
 Cole, R., and Kuttner, A. G. (1926). *J. exp. Med.*, **44**, 855.
 Fahey, J. L., Leonard, E., Churg, J., and Godman, G. (1954). *Amer. J. Med.*, **17**, 168.
 Fisher, E. R., and Davis, E. (1958). *New Engl. J. Med.*, **258**, 1036.
 France, N. E. (1951). *Arch. Dis. Childh.*, **26**, 588.
 Geiler, G. (1957). *Frankfurt. Z. Path.*, **68**, 507.
 Gelderen, H. H. van (1959). *Acta paediat. (Uppsala)*, **48**, 169.
 Grocott, R. G. (1955). *Amer. J. clin. Path.*, **25**, 975.
 Hamman, L., and Rich, A. R. (1944). *Bull. Johns Hopk. Hosp.*, **74**, 177.
 Hamperl, H. (1957). *J. Path. Bact.*, **74**, 353.
 Humberstone, F. D. (1958). Unpublished work.
 Le Tan, V. (1954). *Arch. franç. Pédiat.*, **11**, 1035.
 Margileth, A. M. (1955). *Pediatrics*, **15**, 270.
 Miescher, G. (1942). *Dermatologica (Basel)*, **86**, 64.
 Minder, W. H. (1953). *Schweiz. med. Wschr.*, **83**, 1180.
 Nelson, J. S., and Wyatt, J. P. (1959). *Medicine (Baltimore)*, **38**, 223.
 Peabody, J. W., Jr., Buechner, H. A., and Anderson, A. E. (1953). *Arch. intern. Med.*, **92**, 806.
 Peace, R. J. (1958). *Amer. J. Med.*, **24**, 48.
 Plummer, N. S., Angel, J. H., Shaw, D. B., and Hinson, K. F. W. (1957a). *Thorax*, **12**, 57.
 — Symmers, W. St. C., and Winner, H. I. (1957b). *Brit. med. J.*, **2**, 599.
 Putschar, W. G. J., and Manion, W. C. (1956). *Amer. J. clin. Path.*, **26**, 429.
 Reich, H. (1952). *Hautarzt*, **3**, 503.
 Resnick, N., and Skerrett, P. V. (1959). *Arch. intern. Med.*, **103**, 116.
 Ricken, D. (1958). *Virchows Arch. path. Anat.*, **331**, 713.
 Rowe, W. P., Hartley, J. W., Waterman, S., Turner, H. C., and Huebner, R. J. (1956). *Proc. Soc. exp. Biol. (N.Y.)*, **92**, 418.
 Sakamoto, S., and Oota, K. (1957). *Acta path. jap.*, **7**, 167.
 Seifert, G. (1956). *Verh. dtsh. Ges. Path.*, **40**, 123.
 — and Oehme, J. (1957). *Pathologie und Klinik der Cytomegalie*. Thieme, Leipzig.
 Smith, M. G. (1956). *Proc. Soc. exp. Biol. (N.Y.)*, **92**, 424.
 Symmers, W. St. C. (1956). *Lancet*, **1**, 592.
 — (1957). *Brit. med. J.*, **1**, 459.
 — (1958). In *Eight Colloquia on Clinical Pathology*, ed. Welsch, M., Dustin, P., and Dagnelie, J., Ch. 29, p. 749. Presses Académiques Européennes, Brussels.
 — (1960). *J. Path. Bact.* In press.
 — and Humberstone, F. D. (1959). Unpublished work.
 Takos, M. J. (1956). *Docum. Med. geogr. trop. (Amst.)*, **8**, 346.
 VonGiahn, W. C., and Pappenheimer, A. M. (1925). *Amer. J. Path.*, **1**, 445.
 Weller, R. (1955). *Z. Kinderheilk.*, **76**, 366.
 Winslow, D. J., and Hathaway, B. M. (1959). *Amer. J. clin. Path.*, **31**, 337.
 Wyatt, J. P., Saxton, J., Lee, R. S., and Pinkerton, H. (1950). *J. Pediat.*, **38**, 271.