

Haematoxylin bodies in Hodgkin's disease

N. CANDREVIOTIS

From the Department of Pathology, Evangelismos Hospital, Athens, Greece

SYNOPSIS A case is described in which haematoxylin bodies were found in a lymph node altered by Hodgkin's disease. They can no longer therefore be regarded as entirely specific for lupus erythematosus.

Haematoxylin bodies were first described by Gross in 1940, and are considered by Klemperer, Pollack, and Baehr (1941) to be specific histological features of disseminated lupus erythematosus. Worken and Pearson (1953) found these bodies in several organs in a case of allergic angiitis without lupus erythematosus but they could not be considered as incompatible, since both allergic angiitis and lupus erythematosus are of a similar pathogenetic nature, representing hypersensitive conditions of the connective tissue. However, the presence of haematoxylin bodies in a pathological condition having no apparent connexion with lupus erythematosus would be of interest for their diagnostic significance.

In a previous paper (Candreviotis, 1959) we described the presence of haematoxylin bodies in a lymph node involved by Hodgkin's disease, and we have recently found haematoxylin bodies in another case of Hodgkin's disease.

CASE REPORT

A 48-year-old woman was admitted on 14 February 1962 because of general lymph node enlargement associated with high fever. She was operated on in February 1961 for a femoral hernia on the right side. Afterwards enlargement of the inguinal lymph nodes was noted, and a little later the cervical lymph nodes also became enlarged. In April 1961 the patient's temperature rose to 39° C., associated with malaise and a further increase in the lymph node enlargement. This condition lasted for several months, and treatment with cortisone was started in October 1961. The patient's general condition improved but the enlarged lymph nodes did not decrease in size. The fever and malaise appeared again as soon as the cortisone treatment was interrupted and the patient was re-admitted.

On examination the inguinal and cervical lymph nodes were found to be greatly enlarged. A blood examination showed an increased erythrocyte sedimentation rate up to 52 mm. in the first hour. Red cells numbered 4,400,000 per cm., Hb was 13.9 g. per ml., and there were 8,800

white blood cells per c.mm. (polymorphs 76%, lymphocytes 14%, monocytes 8%, and transitional cells 2%). No lupus erythematosus cells were found. On 14 February 1962 an enlarged inguinal lymph node was excised for histological examination.

PATHOLOGICAL FINDINGS

The excised lymph node measured 2.5 × 2 × 1.5 cm. and was dense in consistency, homogeneous in appearance, and gray white in colour.

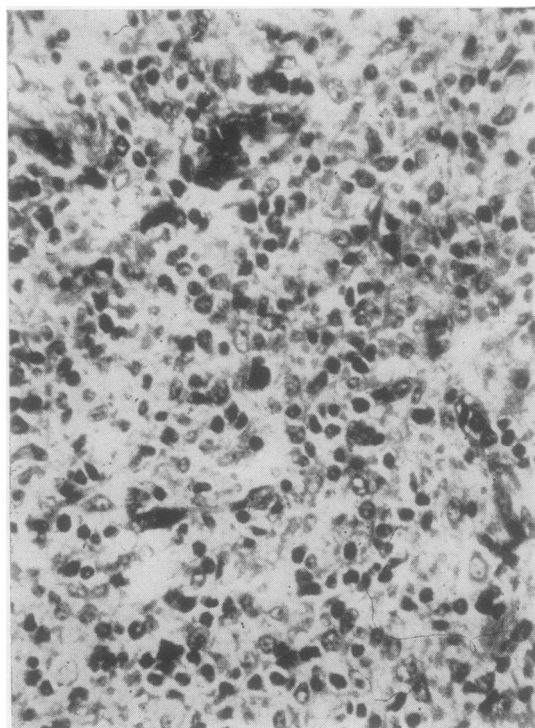


FIG. 1. *An ovoid haematoxylin body in the centre of the cellular tissue.*

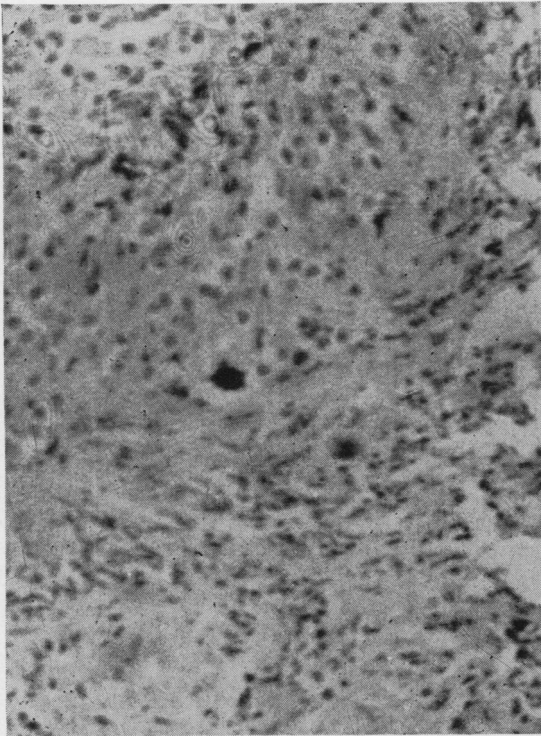


FIG. 2. The same form as in Fig. 1 in a positive Feulgen reaction.

Histologically, the typical picture of Hodgkin's disease was seen. The normal lymph node architecture was completely destroyed and replaced by a cellular, newly formed granulomatous tissue consisting

of lymphocytes and numerous atypical reticulum cells with large vesicular nuclei containing a well-marked nucleolus. Most of the cells had more than one nucleus of various sizes, shapes, and staining intensity. Reed-Sternberg giant cells were abundant. In some areas sclerotic fibrosis was present and in others a few ovoid or irregularly shaped forms were found giving a deep purple colour with haematoxylin and a positive Feulgen reaction (Figs. 1 and 2). These were predominant in the sclerotic areas.

COMMENT

On the basis of the clinical and histological findings it is apparent that the case is one of Hodgkin's disease with haematoxylin bodies in an altered lymph node. Lupus cells or other signs of disseminated lupus erythematosus were not present. Since haematoxylin bodies have been found in other conditions they cannot be regarded as specific for lupus erythematosus but it does not follow that they have lost at all their diagnostic significance. It only means that haematoxylin bodies cannot any longer be considered as pathognomonic for this disease. As to the origin of the haematoxylin bodies in this case, according to Gross they are of nuclear origin. This belief is supported by the fact that they were found mainly in the sclerotic areas.

REFERENCES

- Candreviotis, N. (1959). *Zbl. allg. Path. path. Anat.*, **99**, 191.
 Gross, L. (1940). *Amer. J. Path.*, **16**, 375.
 Klemperer, P., Pollack, A. D., and Baehr, G. (1941). *Arch. Path.*, **32**, 569.
 Worken, B., and Pearson, R. D. (1953). *Ibid.*, **56**, 293.