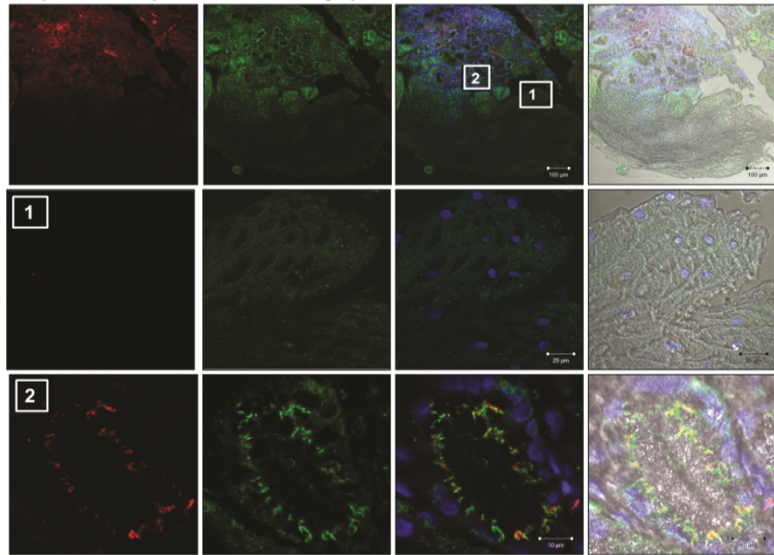
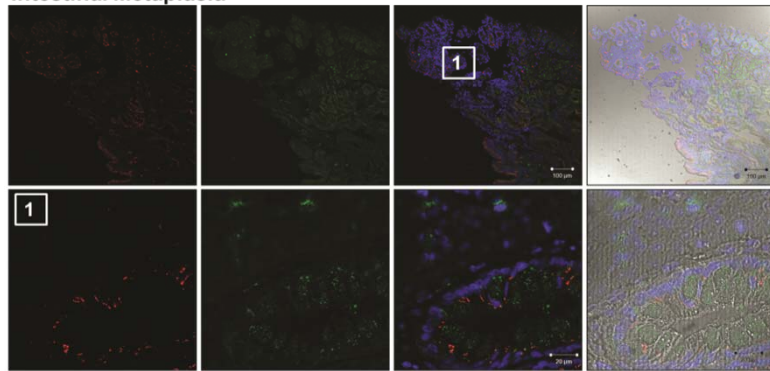


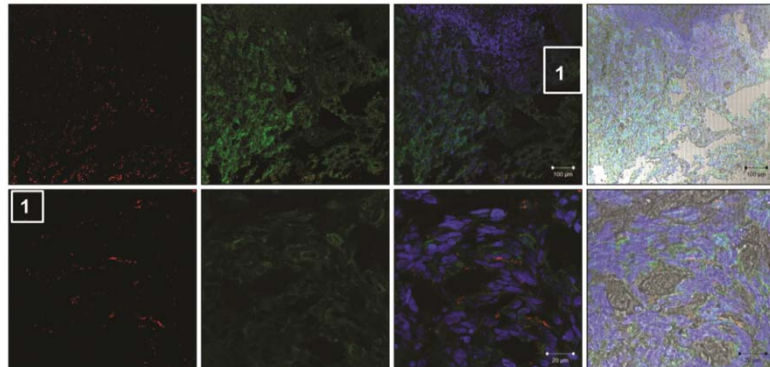
Squamous Epithelium /Non-dysplastic



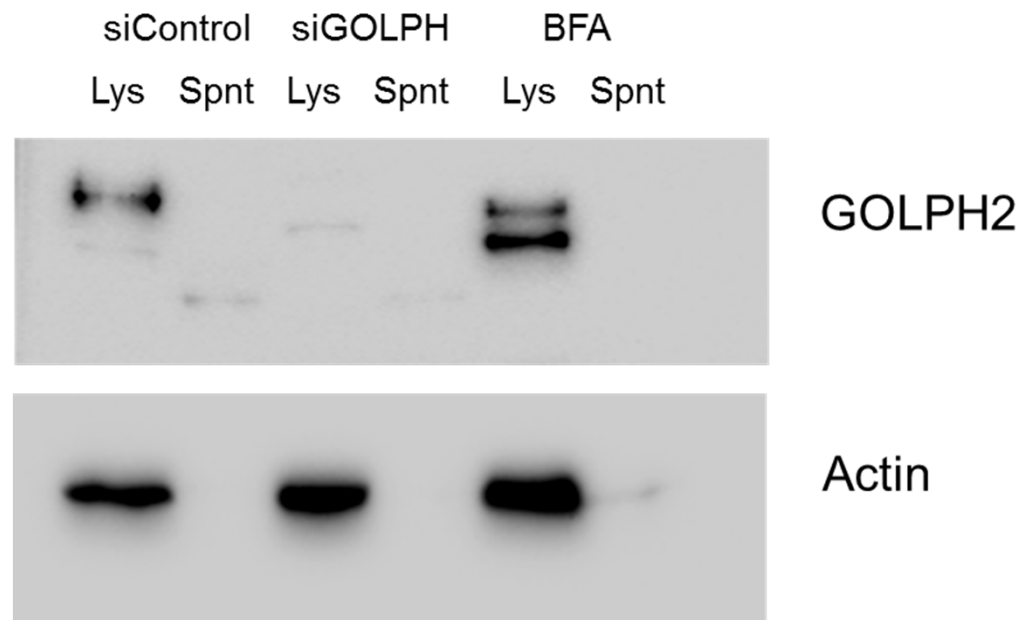
Intestinal Metaplasia



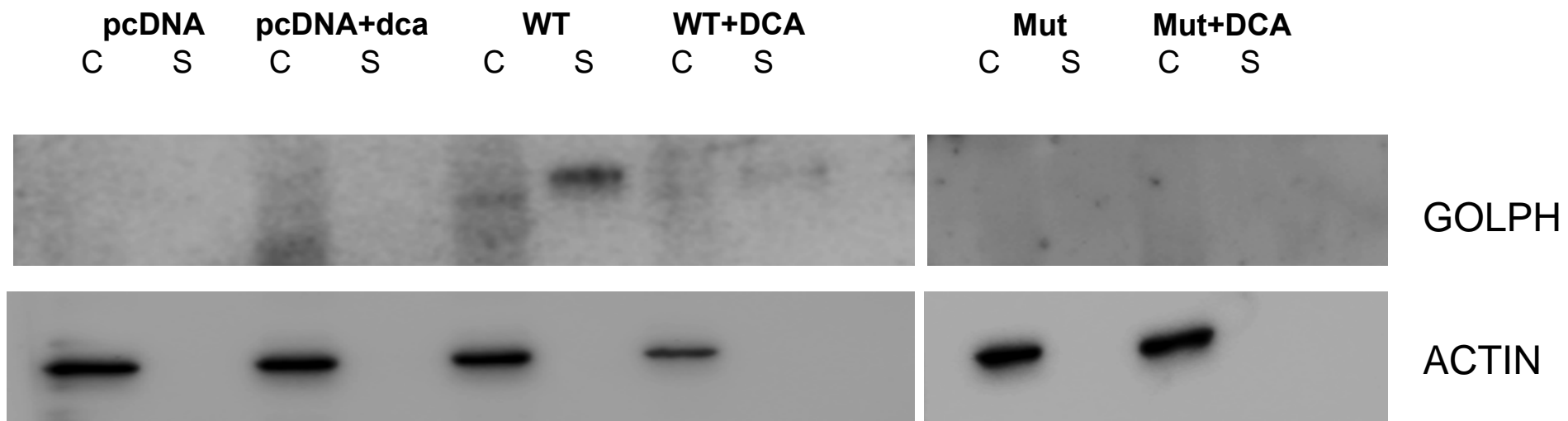
Adenocarcinoma



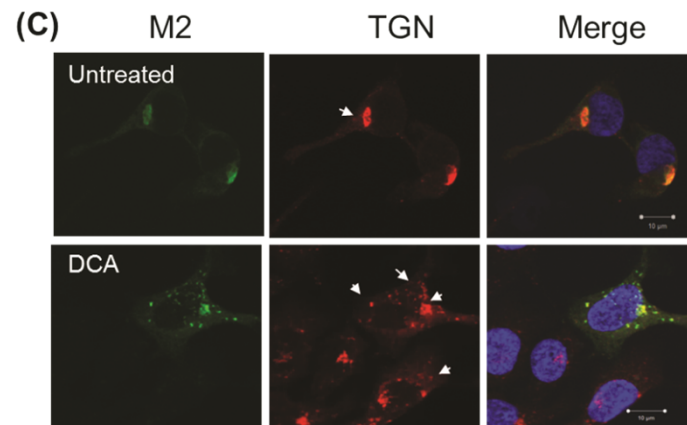
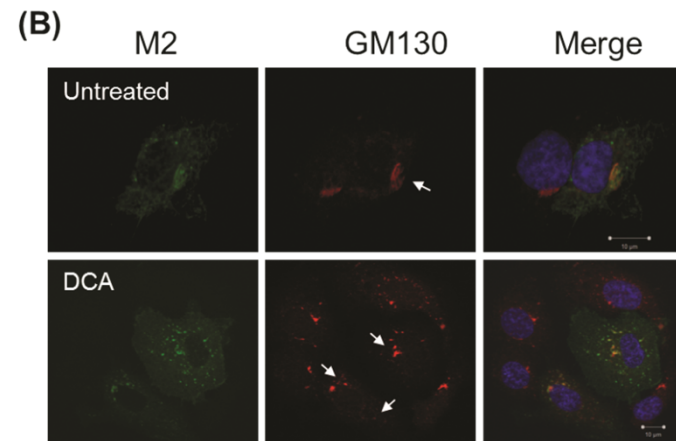
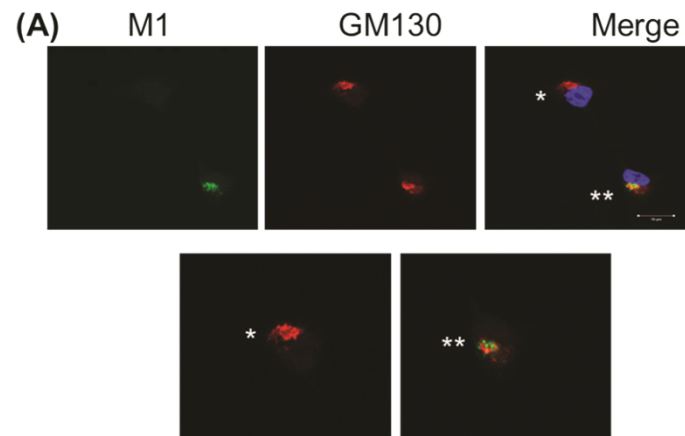
Supplementary Figure 1



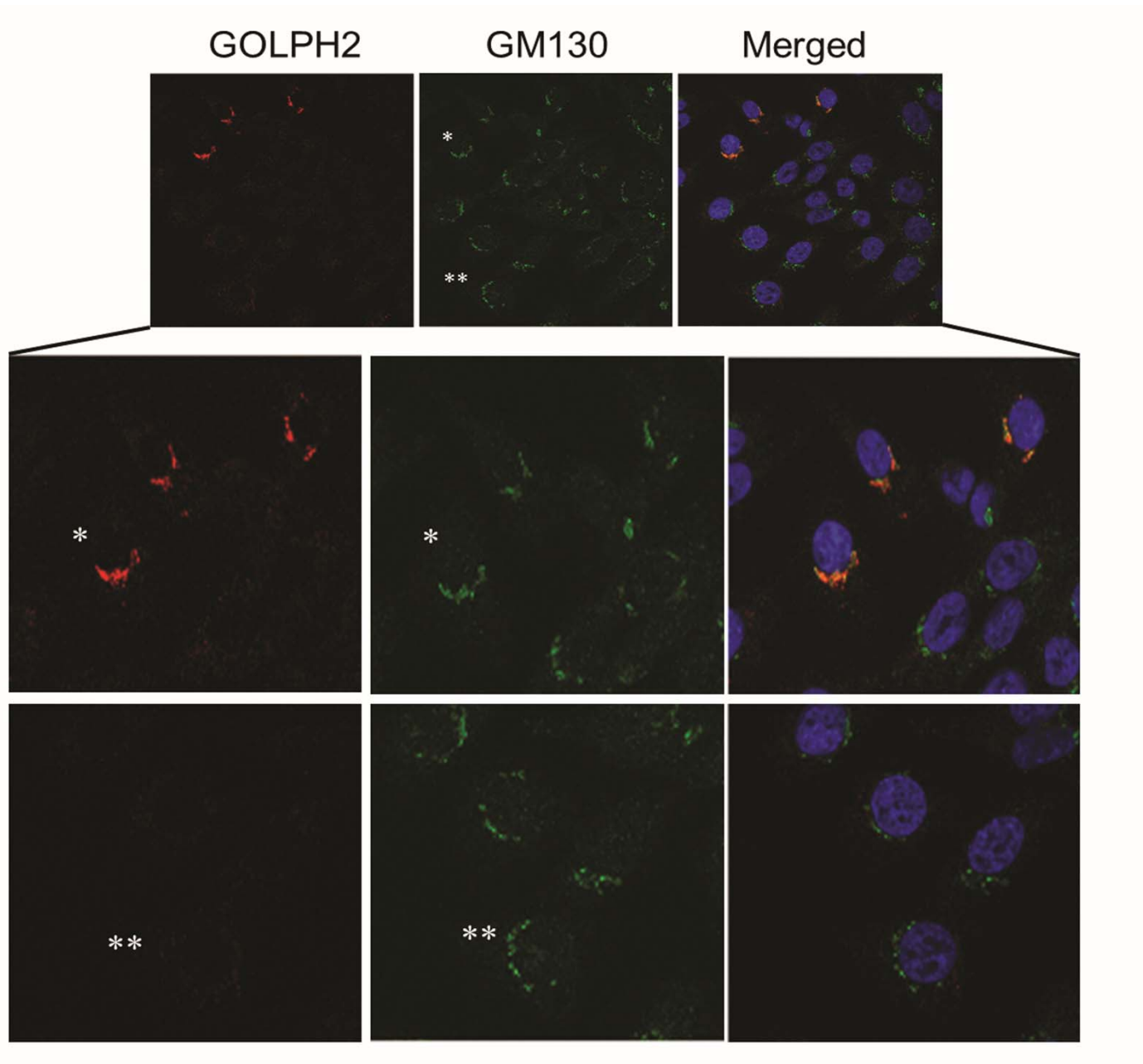
Supplementary Figure 2



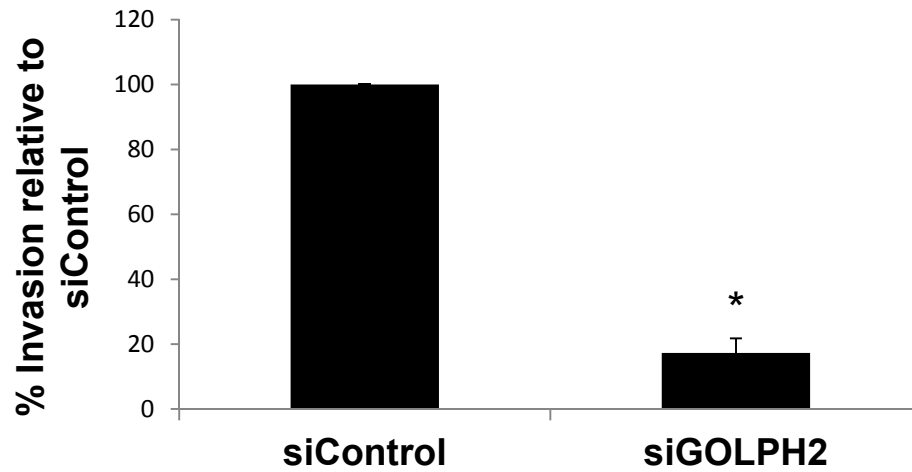
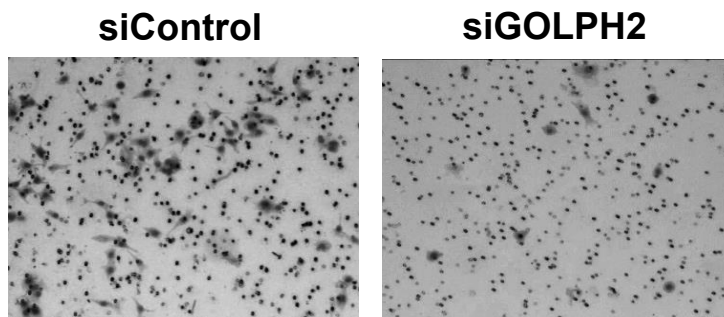
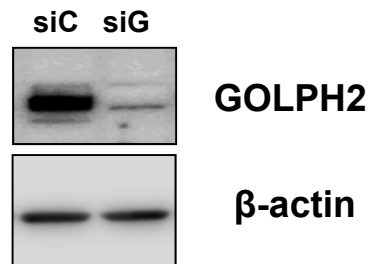
Supplementary Figure 3



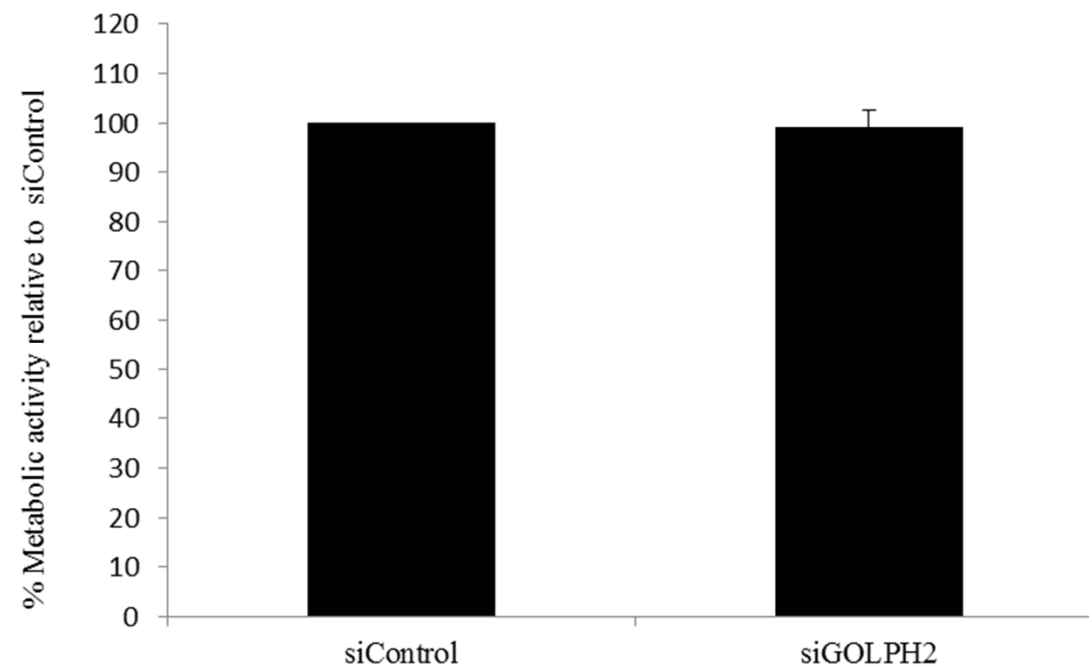
Supplementary Figure 4



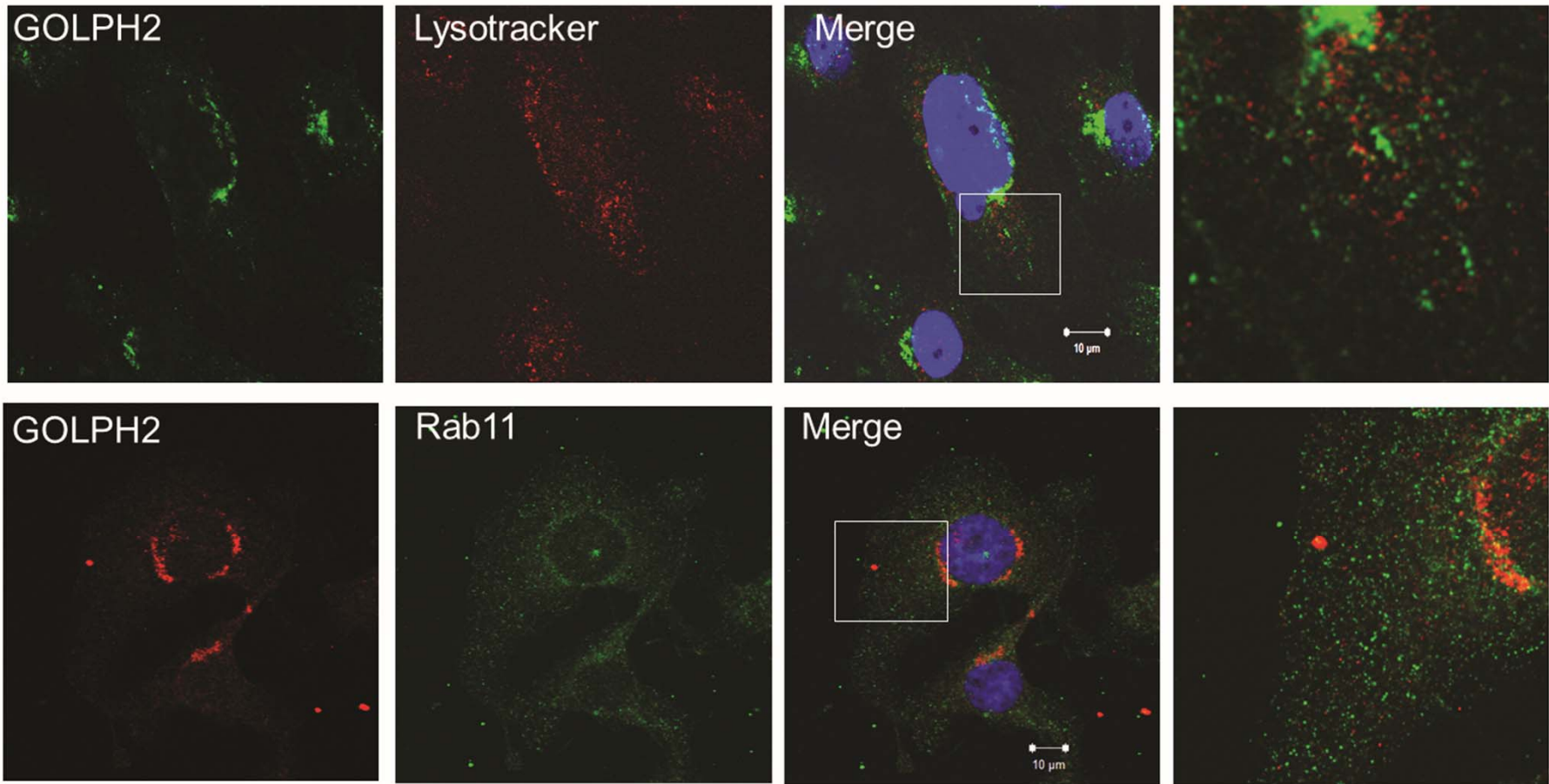
Supplementary Figure 5



Supplementary Figure 6



Supplementary Figure 7



Supplementary Figure 8