

Conditions for effective Nd-YAG laser angioplasty

HERBERT J GESCHWIND, GEORGES BOUSSIGNAC, BERNARD TEISSEIRE,
NICOLE BENHAIEM, RENÉE BITTOUN, DANIEL LAURENT

From the Departments of Clinical Investigation and Histopathology, University Hospital Henri-Mondor, Créteil, France

SUMMARY To establish the optimal conditions for recanalisation of obstructed arteries without damage to vessel walls, a Nd-YAG laser coupled to a 0.2 mm diameter optic fibre was used on obstructed human cadaver coronary and peripheral arteries and on popliteal arteries in amputated limbs. Vaporisation of atheromatous plaques was consistently obtained with an energy of 360–600 J and a diluted blood perfusate (3 g/100 ml haemoglobin) at a rate of 20 ml/min. The arterial wall was protected from thermal injury by inserting the optic fibre into an inflated balloon catheter and by cooling the system with the perfusate. Since recanalisation of occluded arteries was consistently obtained without damage to the arterial wall or debris and thin and flexible optic fibres were easy to guide in the arteries, percutaneous transluminal Nd-YAG laser angioplasty was used in obstructed femoral and popliteal arteries in three patients.

The first European trials in man showed the method to be feasible, effective, and harmless, although further studies are required to improve penetration of the obstruction and increase the diameter of tunnel.

Lasers have been widely used in the treatment of diseases in several areas of medical practice. This technique has not, however, yet been applied in diseases of the heart and blood vessels. Experimental studies have recently been undertaken to assess the efficacy of laser radiation for removing obstructions in test tubes,¹ in human cadaver arteries,² or in animal arteries.³ The obstructions were either thrombi or atheromatous plaques. The sources of laser that have been used comprised carbon dioxide, Nd-YAG (neodymium yttrium, aluminium, garnet), and mainly argon.⁴ These studies concluded that atheromatous plaques and thrombi may be recanalised, but damage to the arterial wall often occurred.

Since the optimum conditions for successfully perforating obstructed arteries and avoiding injury to the arterial wall have not yet been determined, we carried out experimental studies with a Nd-YAG laser coupled to a fiberoptic system to establish the main suitable conditions required to relieve obstructions in arteries without perforating the arterial wall.⁵

Requests for reprints to Dr Herbert J Geschwind, CHU Henri Mondor, 51 avenue du Maréchal de Lattre de Tassigny, 94010 Créteil, France.

Accepted for publication 2 August 1984

Material and methods

Experimental studies were performed on various material including: (a) 10 thrombi prepared from blood samples from normal human volunteers; the blood was permitted to clot and dry in test tubes of 5 mm in diameter, and the thrombi were cut to fixed lengths of 5 mm; (b) 10 atheromatous plaques removed from obstructed fresh human cadaver arteries and inserted into test tubes; (c) 20 totally occluded fresh human cadaver coronary arteries cut to lengths of 5 mm; and (d) 10 totally occluded popliteal and tibial arteries located in freshly amputated limbs.

A Nd-YAG laser with a wavelength of 1064 nm (Robert et Carrière Biomédical) was coupled to a fiberoptic system consisting of a 0.2 mm diameter silica fibre 3 mm long. One end was aligned with the focused laser beam as it exited from the laser, and the free end was used for laser emission. The power reading on the laser meter was 20–25 W and the actual power at the fibretip 12 W. The main laser beam was used with continuous emission, and duration of exposure varied between 2 and 50 s. Peak emission was also used and the duration adjusted by an electronic system to 0.2, 0.3, 0.5, and 0.7 s with automatic firing in bursts at a rate of one emission every 5 s. The

divergence at the tip of the optic fibre was 10°. In order accurately to locate the impact area from the main beam a low power red beam (having no effect on tissues) was emitted when desired by an He-Ne laser, thus showing the beam trajectory.

The optic fibre was inserted into a balloon catheter and both were advanced against the atherosclerotic plaque or the thrombus. The balloon was inflated in order to maintain the coaxial position of the optic fibre. For laser treatment of coronary arteries, the device commonly used in coronary angioplasty procedures was used. Both the optic fibre and the balloon catheter were inserted into a guiding catheter so that the tip of the optic fibre was placed 3 mm beyond the tip of the balloon catheter. When test tubes were used the laser beam was directed through the open end.

During the procedure fluid was circulated in both the guiding and balloon catheters using a Transomega T4 pump. Experiments were achieved using: (a) blood (haemoglobin 15 g/dl); (b) saline; and (c) a mixture of blood and saline so that the haemoglobin concentration was 3 g/dl. The rate of perfusion was adjusted to 10, 20, and 50 ml/min. Blood was filtered from the artery effluent through 8 and 3 µm micro-pore filters.

The effects of laser emission were evaluated by gross inspection and microscopically; those in obstructed amputated limb arteries were assessed by repeat angiography. In intact occluded coronary artery segments the treatment was considered to be successful if the plaque was penetrated and a new lumen established. The diameter of holes was measured using a stereoscopic microscope (Wild Heerbrugg M8). Perforation was defined as a rupture through the entire thickness of the arterial wall.

After exposure to the laser, all tissue samples were fixed in 10% formaldehyde, dehydrated, and embedded in paraffin. Tissue blocks were cut in sections of 3 µm thickness. Sections from each tissue were stained with haematoxylin and eosin, Masson's trichrome, and orcein. Each section was evaluated by light microscopy.

The total energy delivered in joules was calculated as the product of the amount of power (watts) and the duration of exposure (s).

Results

EFFECTS ON THROMBI

Retraction of thrombi occurred in all cases, and a reduction in size by 50–70% was obtained with 200 J. Totally obstructive thrombi were detached from the walls of test tubes and arterial walls, and holes and perforations were created.

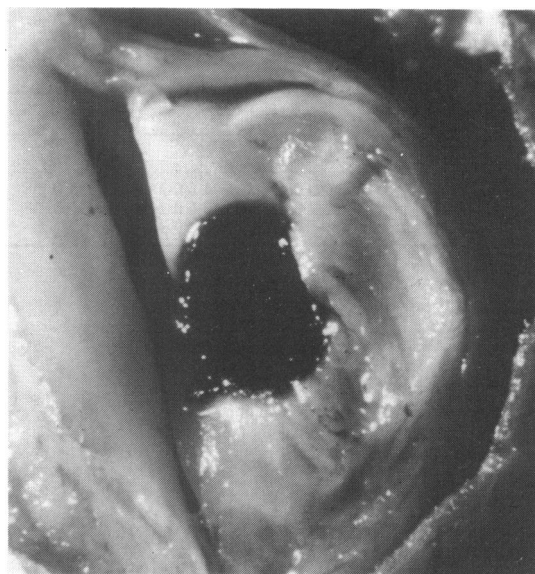

Fig. 1 Hole obtained with Nd-YAG laser emission in an obstructed fresh human cadaver carotid artery viewed through a stereoscopic microscope.

EFFECT ON ATHEROMATOUS PLAQUES

The effects were dependent on the colour, thickness, density of tissue,⁶ power intensity, and duration of exposure to the laser as well as the composition and rate of the perfusion. With saline, no significant effects were observed. With blood, thermal injury occurred at the entry of the plaque but no perforation resulted. By contrast, with diluted blood (3 g/100 ml haemoglobin concentration) perfusion, perforation of the atheromatous plaque occurred (Fig. 1). The most efficient perfusion rate was 20 ml/min with a perfusate temperature of 22°C (Tables 1 and 2). Under these

Table 1 Results of laser treatment on atheromatous plaques according to the perforate used. Values are mean (SD) (n=8)

Perfusate	Size of perforation		
	Length (mm)	Entry diameter (mm)	Exit diameter (mm)
Saline (0.9 g/100 ml)	0.7(0.5)***	0.4(0.3)***	0***
Diluted blood:			
Haemoglobin concentration 3 g/100 ml	4.8(0.2)	2.1(0.2)	1.2(0.3)
Haemoglobin concentration 10 g/100 ml	3.8(0.4)***	2.1(0.3)	0.3(0.4)***
Blood:			
Haemoglobin concentration 15 g/100 ml	2.2(0.5)***	2.9(0.5)	0.3(0.3)***

***p<0.001.

Table 2 Results of laser treatment on atheromatous plaques according to temperature of perfusate. Values are mean (SD) (n=8)

Size of perforation	Temperature		
	4°C	22°C	37°C
Length (mm)	4.6(0.4)	4.8(0.2)	4.8(0.2)
Entry diameter (mm)	1.9(0.4)	2.1(0.2)	2.0(0.3)
Exit diameter (mm)	1.0(0.4)	1.2(0.3)	1.2(0.2)

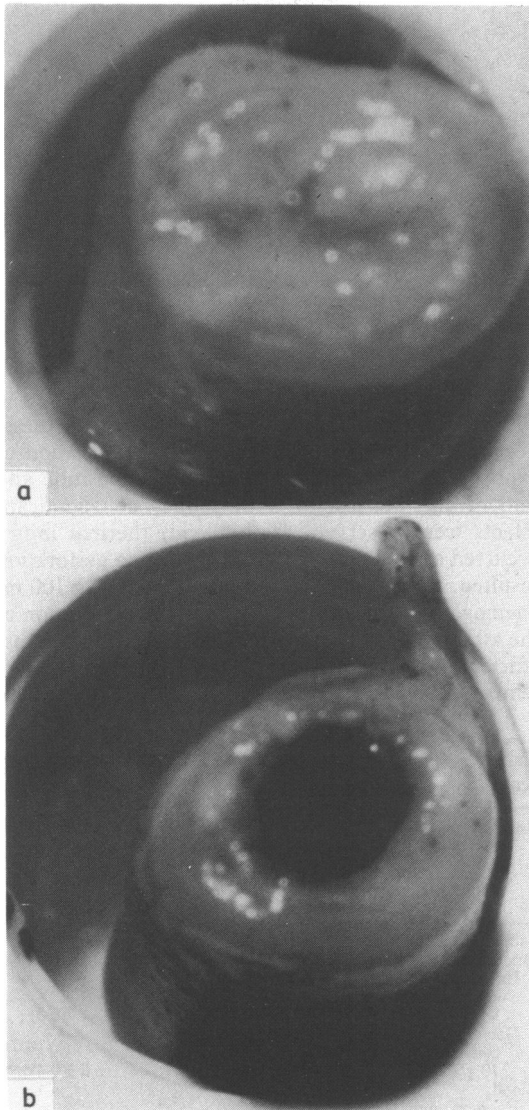


Fig. 2 An obstructed fresh human cadaver coronary artery (a) before laser treatment and (b) after penetration with a laser beam (energy 360 J; energy density 36 000 J/cm²).

experimental conditions the energy required to penetrate a 5 mm long plaque was 12 W at the tip of the optic fibre and the exposure duration 30 s, the energy density being 36 000 J/cm² (Fig. 2). Three firings of 480 J each were necessary totally to penetrate plaques 20 mm long. The diameter of the hole at the entry of the tunnel was 2 mm and 1 mm at the other end. No effect could be obtained when laser emission was used in bursts. Five centimetres of occluded amputated limb arteries were cleared with nine successive firings of 600 J each.

EFFECT ON THE ARTERIAL WALL

Only three perforations of the arterial wall occurred. In these cases the optic fibre had been inserted into the arterial lumen without maintaining coaxial position with the inflated balloon catheter. When the coaxial position was maintained no damage to the arterial wall occurred, and no leak of contrast medium was seen at repeat angiography during recanalisation of the amputated limb arteries (Fig. 3).

Neither clots nor debris appeared to be retained on the micropore filter from the perfusion effluent after laser exposure.

HISTOLOGICAL FINDINGS

No matter which haemoglobin concentration was used, histological examination showed thermal injury, fissures, retraction, and dissection of the atherosclerotic plaques. With a saline perfusion, the fracture of the lesion was insufficient to create a viable pathway. Using the 15 g/dl haemoglobin concentration the vascular wall thickness suffered thermal injury, but no perforation occurred. No perforation of the vascular wall occurred with saline and the 3 g/dl haemoglobin perfusate but only slight thermal injury to the wall.

Discussion

Laser energy carried by optic fibres appears to be an efficient method of improving perfusion through obstructed arteries. This was shown by perforations consistently obtained on atherosclerotic plaques or thrombi.

The diameter of the holes at the entry of the tunnel and at the other end were large enough appreciably to improve arterial perfusion. This was demonstrated by control angiograms, which showed satisfactory penetration of obstructed popliteal and tibial arteries from amputated limbs.

Maximum efficacy was observed when lasing was used with a diluted blood perfusion of 3 g/dl haemoglobin concentration. This may be due to the fact that with saline the laser beam was not absorbed by the white and yellow coloured plaque. With blood, the absorption of the laser beam was likely to be too high

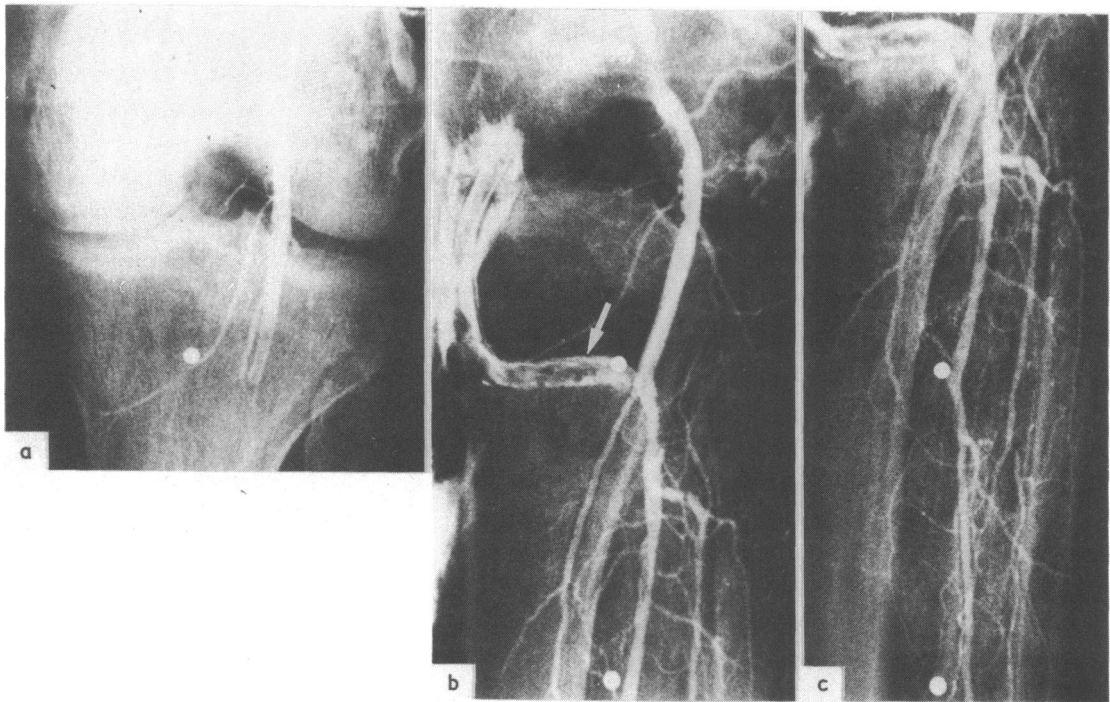


Fig. 3 Angiograms of (a) an obstructed popliteal artery in a freshly amputated limb; (b) recanalisation of popliteal and tibial arteries after laser treatment; note retrograde opacification of a previous obstructed bypass (arrow); (c) repermeation of distal vessels in the same limb.

at the entry of the plaque, thus preventing the beam from penetrating into the atheroma. With diluted blood, the absorption of the laser beam was sufficient to allow perforation to occur and the plaque to be entirely penetrated, since more residual energy was available.

The rate of perfusion also played a role in the efficacy of vaporising the atheroma, since a high rate of perfusion prevented thermal injury. By contrast, a low rate of perfusion permitted blood to absorb the laser radiation to too great an extent. Consequently, insufficient laser energy was available and thermal injury to the plaque did not occur.

An adequate rate of perfusion was required to prevent the arterial wall from being injured by the laser beam since the circulating fluid acts by cooling the artery. The arterial wall was protected by the coaxial position of the tip of the optic fibre in the centre of the arterial lumen since the inflated balloon kept the fibre tip at a distance from the arterial wall.

Laser treatment was effective only with continuous emission when the duration was long enough to create thermal injury to the obstruction. By contrast, when bursts were used cooling occurred during the emission intervals leading to an ineffective response.

The safety of the procedure was shown by the fact that no debris was retained on the micropore filters; thus no distal embolisation is likely to occur. This agrees with the findings of Choy *et al* who observed total vaporisation without debris then thrombi were subjected to laser emission.³

Finally, since the optic fibre that was used in our experiments was very thin and flexible it could be inserted into all available balloon catheters including those commonly used for peripheral artery angioplasty and specifically those used for coronary angioplasty. The feasibility of guiding these devices in man was evident both in the femoral and iliac arteries as well as in the coronary arteries.

CLINICAL STUDY

Since these experimental studies consistently showed effective recanalisation of totally occluded arteries without perforation of the arterial wall the method was recently applied in three patients. The protocol was approved by the human research committee of this hospital and informed consent was obtained from all patients. The first patient had a totally occluded femoral artery, the second a totally occluded popliteal artery, and the third a femoral artery stenosis 5 mm

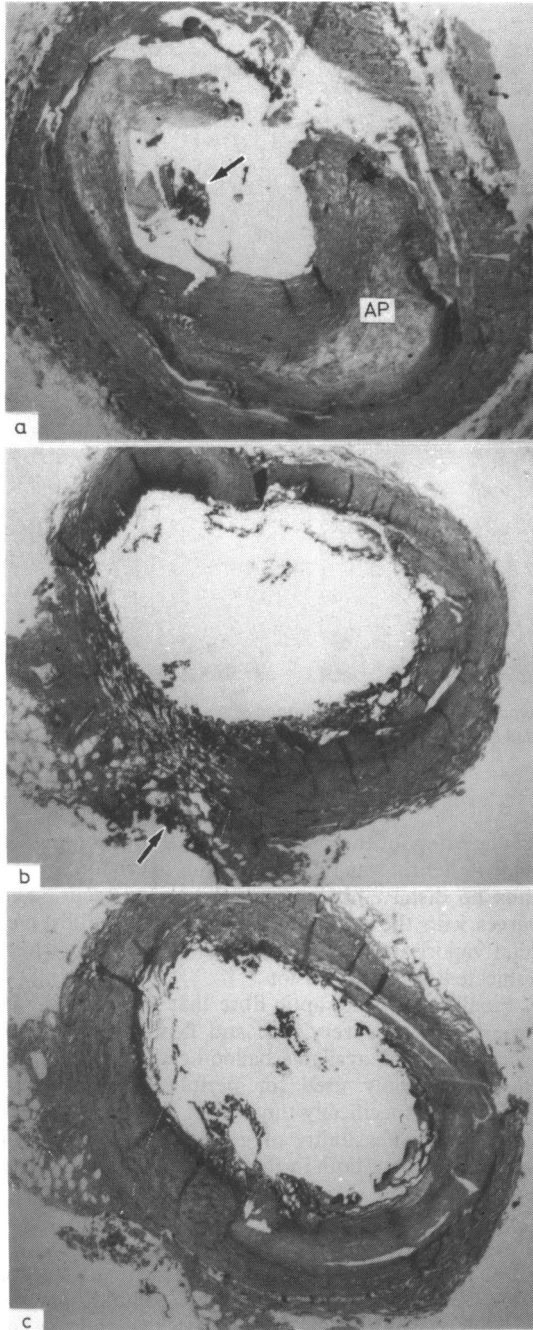


Fig. 4 Histological specimens showing the effects of laser treatment. (a) In an atheromatous vascular wall treated using a saline perfusate the atherosclerotic plaque (AP) is lightly penetrated. Note the thermal injury (arrow). Masson's trichrome stain $\times 32$. (b) Treatment with the 15 g/100 ml haemoglobin perfusate produced thermal necrotic debris in the adventitia (arrow). Mainly necrotic intimal and medial cells can be seen. Masson's trichrome stain $\times 32$. (c) Treatment with 3 g/100 ml haemoglobin perfusate produced efficient recanalisation of the occluded arterial lumen without major injury to the wall. Masson's trichrome stain $\times 32$.

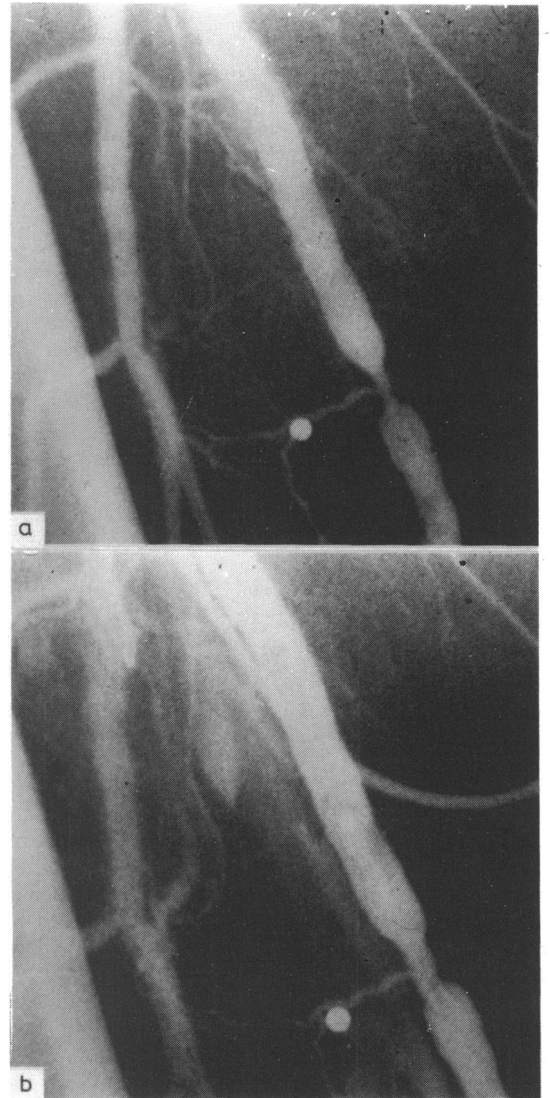


Fig. 5 Angiograms of femoral artery stenosis in man (a) before and (b) after enlargement of the stenosis by the laser.

long and 1 mm in diameter. The balloon catheter and the optical fibre were inserted percutaneously into the femoral artery. Three firings of 600 J each were necessary to recanalise the occluded femoral and popliteal arteries. Three firings of 360 J each were required to enlarge the femoral artery stenosis from 1 to 4 mm (Fig. 5). No perforation of the arterial wall occurred. The only side effect was a burning sensation in the limb during laser emission.

These clinical trials of laser recanalisation in obstructed peripheral arteries are to our knowledge the first in Europe to be carried out in man. To date, the method appears to be limited as the stenosis was not entirely relieved; only a narrow tunnel could be obtained in the totally occluded arteries and follow up was not possible. Although further studies are required to improve penetration of the obstruction and increase the diameter of the tunnels, these cases show that percutaneous transluminal laser angioplasty is feasible, effective, and harmless in man.

We thank B Gaujour, O Legoff, and P Mayiolini for their technical assistance.

The research was supported by grants from the

Institut de la Santé et de la Recherche Médicale (INSERM), Research Unit U138, and the French Ministry of Research and Industry.

References

- 1 Lee G, Ikeda RM, Stobbe D, *et al.* Effects of laser irradiation on human thrombus: demonstration of a linear dissolution-dose relation between clot length and energy density. *Am J Cardiol* 1983; 52: 876-7.
- 2 Choy DSJ, Stertz SH, Rotterdam HZ, Bruno MS. Laser coronary angioplasty: experience with 9 cadaver hearts. *Am J Cardiol* 1982; 50: 1209-11.
- 3 Choy DSJ, Stertz S, Rotterdam HZ, Sharrock N, Kaminow IP. Transluminal laser catheter angioplasty. *Am J Cardiol* 1982; 50: 1206-8.
- 4 Abela GS, Normann S, Cohen D, Feldman RL, Geiser EA, Conti CR. Effects of carbon dioxide, Nd-YAG, and Argon laser radiation on coronary atheromatous plaques. *Am J Cardiol* 1982; 50: 1199-205.
- 5 Geschwind H, Boussignac G, Teisseire B, *et al.* Laser angioplasty: effects on coronary artery stenosis [Letter]. *Lancet* 1983; ii: 1134.
- 6 Lee G, Ikeda R, Herman I, *et al.* The qualitative effects of laser irradiation on human arteriosclerotic disease. *Am Heart J* 1983; 105: 885-9.