

Functional and anatomical correlates in atrial septal defect

An echocardiographic analysis

J COLIN FORFAR,* MICHAEL J GODMAN

From the Department of Cardiology, Royal Hospital for Sick Children, Edinburgh

SUMMARY The results of cross sectional echocardiography, intracardiac contrast echocardiography, and balloon sizing techniques and conventional haemodynamic assessment were correlated in 40 consecutive patients evaluated for an isolated left to right shunt at atrial level. Echo free areas along the septum were identified in 23 of 25 patients with a secundum defect, but not in two with a fenestrated defect, and in the upper atrial septum in three of four patients with a sinus venosus defect. No false positive results occurred in 11 patients with a probe patent foramen ovale. Saline contrast injection into the left atrium showed significant left to right shunting in all patients with atrial septal defect; inferior vena caval injection produced right to left shunting in 15 of 29 patients and a negative contrast effect in eight of 29 patients with an atrial septal defect, although neither correlated quantitatively with defect diameter or magnitude of the left to right shunt.

Echocardiographic assessment of defect size as small, moderate, or large showed a highly significant correlation with balloon measurement of defect diameter, although some overlap between the groups was evident. In contrast, the correlation between defect diameter and pulmonary to systemic blood flow ratio was poor, mainly because of highly variable shunting in patients with an anatomically large defect.

Cross sectional echocardiography has high sensitivity and specificity in the diagnosis of the non-fenestrated atrial septal defect and provides quantitative information about defect diameter. Contrast studies do not add to the diagnostic value of imaging from the subcostal position. The poor correlation between defect size and the measured shunt suggests that the latter may not be the best criterion for surgical management and that size could be an important factor likely to influence both the long term prognosis and the decision for closure.

The decision to close defects of the interatrial septum in younger patients conventionally rests on the extent of intracardiac shunting assessed by oximetry. Although there is little debate about the management of patients with a high pulmonary blood flow and right ventricular enlargement, the relation between flow and defect size with a small or modest overall

shunt without specific chamber enlargement is less well understood and the decision for closure is less clear cut.¹

The diagnostic value of cross sectional echocardiography in identifying atrial septal defects has been recognised,²⁻⁵ although the place of contrast echocardiography as a diagnostic aid remains uncertain.⁶⁻⁸

The purpose of this study was to assess the sensitivity and specificity of cross sectional echocardiography in the diagnosis and quantitative evaluation of atrial septal defects and to examine the relation between defect size and the extent of interatrial shunting, the latter measured conventionally by oximetry and directly by intracardiac contrast echocardiography.

Requests for reprints to Dr M J Godman, Cardiology Department, Royal Hospital for Sick Children, Sciennes Road, Edinburgh EH9 1LF.

*Present address: Cardiac Department, John Radcliffe Hospital, Headington, Oxford.

Accepted for publication 22 March 1985

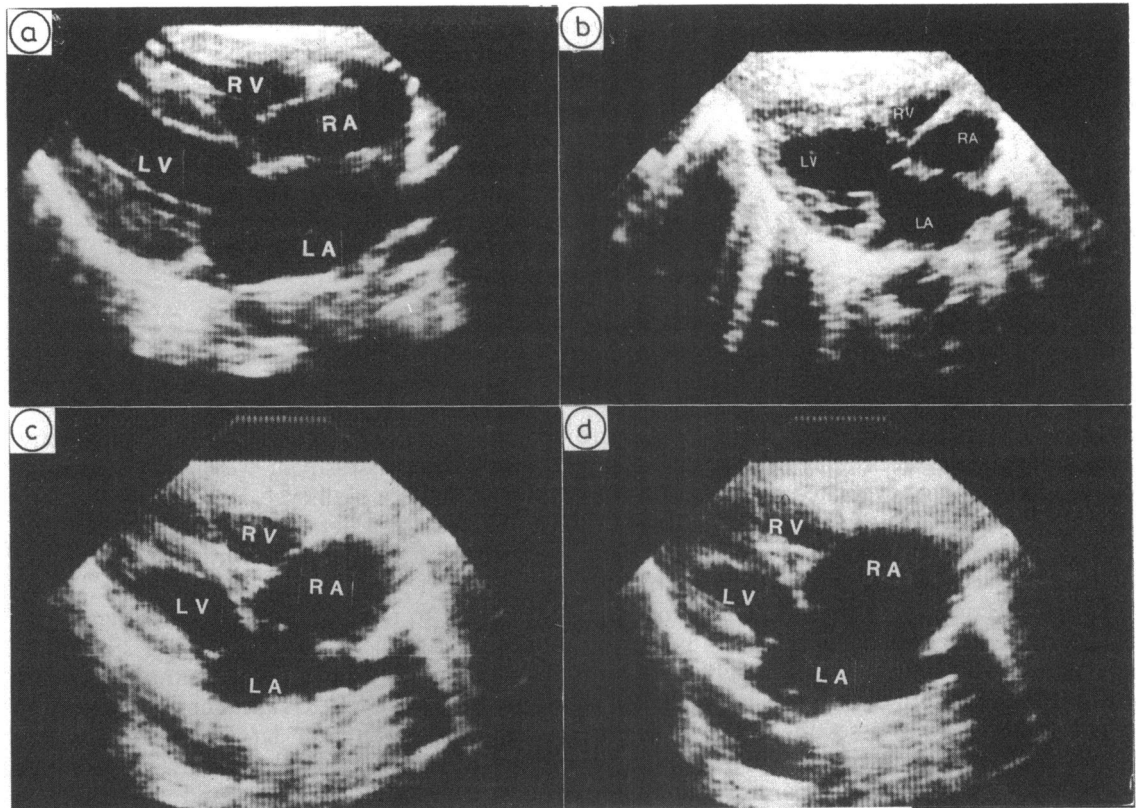


Fig. 1 Echocardiographic grading of the atrial septum from the subcostal position as intact (a), or showing a small (b), moderate (c), or large (d) defect.

Patients and methods

Forty consecutive patients (19 boys, 21 girls; aged 1–16 years) were studied over a 21 month period at the time of cardiac catheterisation for evaluation of a possible isolated left to right shunt at atrial level. Patients in whom an ostium primum defect was suspected, those with additional cardiac malformations, or those with a calculated pulmonary vascularity resistance in excess of 4 units were excluded from the analysis. After all of the investigative procedures, 25 patients were categorised as having a secundum defect, four a sinus venosus defect, and 11 a probe patent foramen ovale without evidence of intracardiac shunting.

ECHOCARDIOGRAPHY

After clinical evaluation, including echocardiography and chest radiography, each patient underwent an echocardiographic examination before cardiac catheterisation. Cross sectional studies of the interatrial septum were performed from the subcostal and

the apical four chamber view using an ATL Advanced 850 mechanical sector scanner with 3 or 5 MHz transducers or Kontron Irex Mark III phased array scanner. The septum was classified as intact (0) or showing a small (+), moderate (++), or large (+++) defect where 30%, 30–60%, or >60% of total septal length respectively appeared to be free of echoes (Fig. 1).

Contrast echocardiographic studies were performed from the left atrium and inferior vena cava at the time of diagnostic catheterisation. Saline injections (2–4 ml) were repeated if necessary until dense opacification of the chamber was achieved. Injection into the left atrium allowed classification of the left to right shunt as small (+), moderate (++), or large (+++) according to whether opacification within the atrium and ventricle was minimal, less than, or equal to opacification of the left sided chambers. Injection into the inferior vena cava established the presence or absence of right to left shunting at atrial level (Fig. 2a) or a negative contrast effect where filling of the right atrium by non-opacified blood from the left

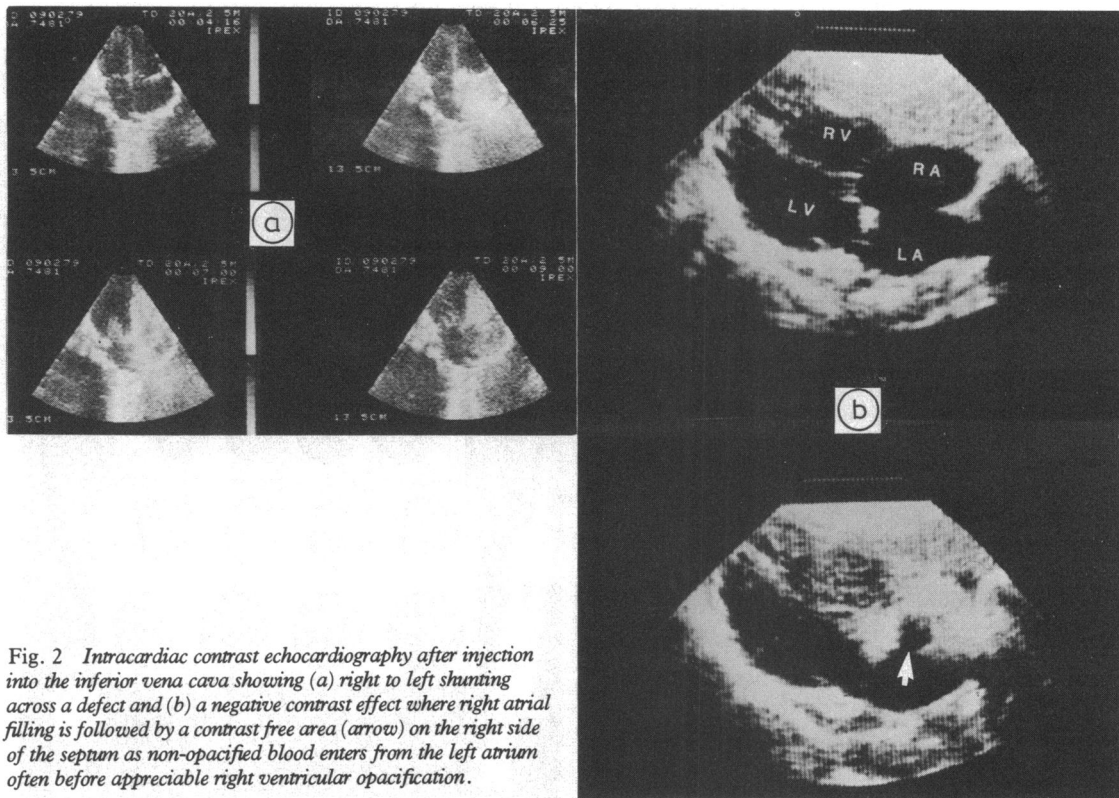


Fig. 2 Intracardiac contrast echocardiography after injection into the inferior vena cava showing (a) right to left shunting across a defect and (b) a negative contrast effect where right atrial filling is followed by a contrast free area (arrow) on the right side of the septum as non-opacified blood enters from the left atrium often before appreciable right ventricular opacification.

atrium resulted in a contrast free area on the right side of the septum at the level of the defect, often before significant right ventricular opacification occurred (Fig. 2b).

HAEMODYNAMIC MEASUREMENTS

Routine cardiac catheterisation was performed from the saphenous vein under light ketamine anaesthesia. The atrial septum was crossed in all patients except one with a high sinus venosus defect. Arterial oxygen saturation was equated with a sample from the left ventricle or femoral artery and mixed venous saturation derived from superior (SVC) and high inferior (IVC) vena cava saturation according to the formula⁹: mixed venous saturation (%) = (3SVC + HIVC)/4 saturation (%). The pulmonary systemic blood flow ratio was derived from standard options.

BALLOON SIZING TECHNIQUE

Measurement of defect diameter was achieved using a balloon catheter according to the method of King *et al.*¹⁰ A Fogarty 8–8F, 8–10F, or 8–14F embolectomy catheter (Edwards Laboratories, Santa Ana, California) was advanced into the left atrium and drawn

across the defect into the right atrium with increasing volumes of dilute contrast until resistance was felt and the balloon remained in the left atrium (Fig. 3a). The maximum volume in the balloon that allowed the defect to be crossed was noted. The defect diameter was derived by inflation of the balloon to exactly the same volume and directly measured using a series of calibrated aluminium templates (Fig. 3b). Reproducibility studies by the same observer showed a maximum variability in defect diameter in eight patients (measured twice during catheterisation) of 2 mm. Technically satisfactory sizing of a secundum defect was achieved in all except one patient, in whom the 8–14F catheter proved too large for the saphenous vein; maximum balloon diameter with 8–10F catheter was 24 mm. Sizing was possible in only two of four patients with a sinus venosus defect. As preliminary studies, in agreement with King *et al.*,¹⁰ had found a large margin of safety between the manufacturer's recommended maximum liquid capacity for the balloon and the volume at which the balloon rupture occurred (with a minimum rupture volume three times the recommended maximum inflation volume) the maximal liquid capacity was exceeded by up to

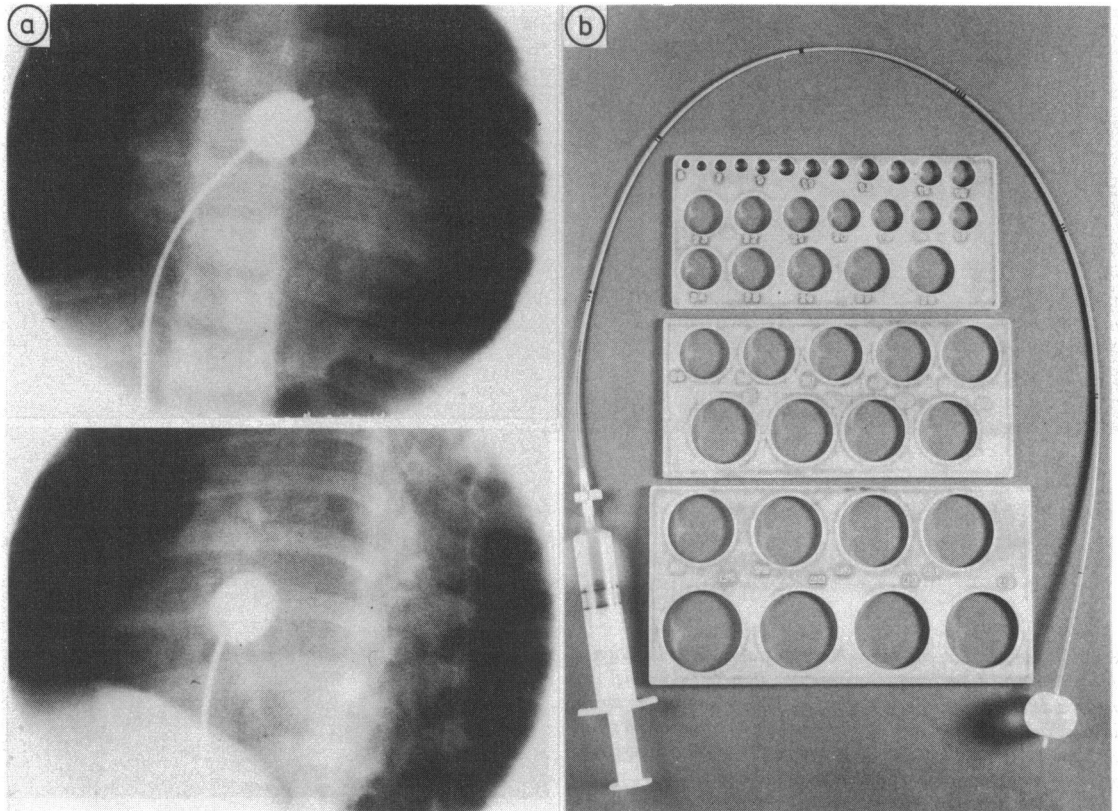


Fig. 3 (a) Angiograms showing balloon sizing of defect diameter from anteroposterior (top) and left oblique projection (below). The contrast filled balloon lies across a secundum defect and the maximum volume needed to cross the defect is noted and the diameter at that volume derived using a series of calibrated templates (b).

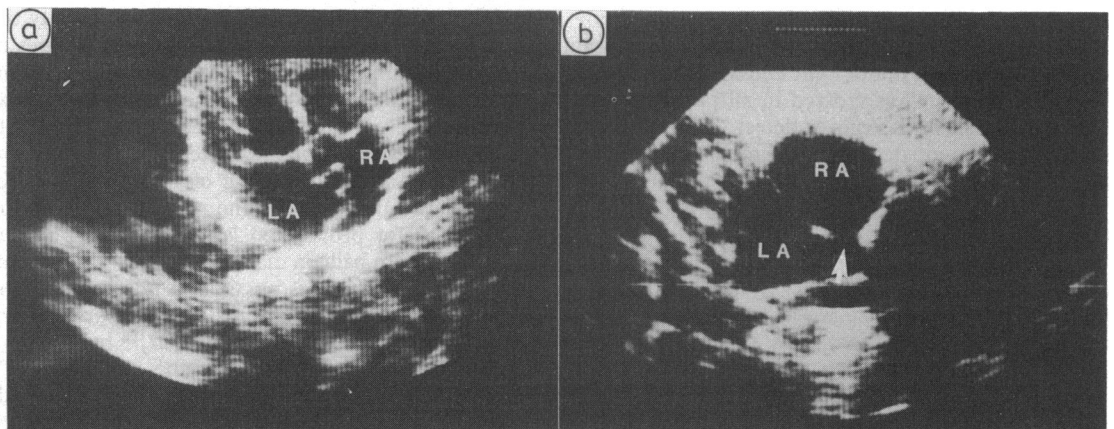


Fig. 4 Echocardiograms showing (a) an aneurysm of the intra-atrial septum protruding into the right atrium. The aneurysm was associated with a large fenestrated septal defect, although no echo free areas are seen. (b) A sinus venosus defect produced an echo free area (arrow) in the upper atrial septum.

Table Contrast echocardiographic assessment of atrial shunting and negative contrast effect in patients with atrial septal defect and patent foramen ovale

	No of patients	No with left-right shunt	No with right-left shunt	No with negative contrast
Atrial septal defect:				
Secundum	25	25	14	8
Sinus venosus	4	3*	1	0
Patent foramen ovale	11	5	0	0

*Defect not crossed in one patient.

50% before a change was made to a catheter with a larger balloon. No complications of the procedure were noted. The inflated balloon floated into and wedged in the main pulmonary artery in two patients but was rapidly deflated without any apparent adverse haemodynamic effect or arrhythmia.

SURGICAL ASSESSMENT

Further assessment of defect diameter at the time of closure on cardiopulmonary bypass was available in 22 patients. For the purposes of comparison with the balloon sizing technique, the shape of the defect was noted and its area carefully measured. In those patients with non-circular defects, a diameter giving an area equivalent to that measured at the time of operation was used for comparison with the balloon sizing technique.

STATISTICAL ANALYSIS

The relation between echocardiographic assessment of defect size and balloon size or pulmonary blood flow was analysed by analysis of variance. Balloon and surgical assessment of defect size was correlated with balloon size and pulmonary blood flow using a linear regression coefficient with least squares method of analysis.

Results

DIRECT ECHOCARDIOGRAPHY

Echo free areas were seen along the atrial septum in 23 of 25 (92%) patients with a secundum defect, but not in two patients, both of whom had a fenestrated defect (one of which occurred in association with a septal aneurysm) (Fig. 4a). Echocardiography also identi-

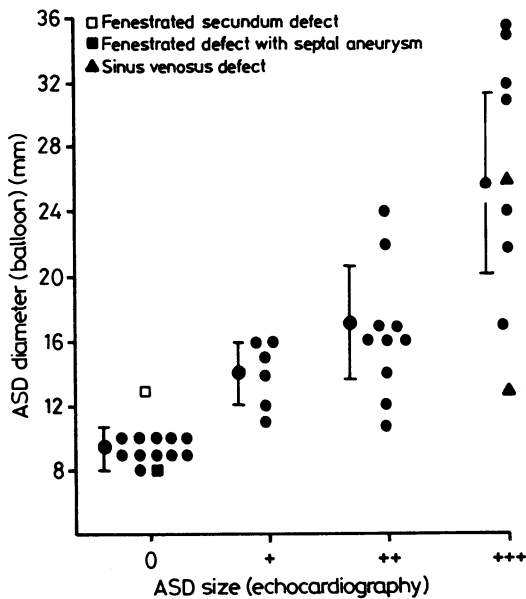


Fig. 5 Diameter of atrial septal defect (ASD) by echocardiography and balloon sizing techniques (n=38). Mean (SD) values are shown. 0, intact; +, small; ++, moderate; +++, large.

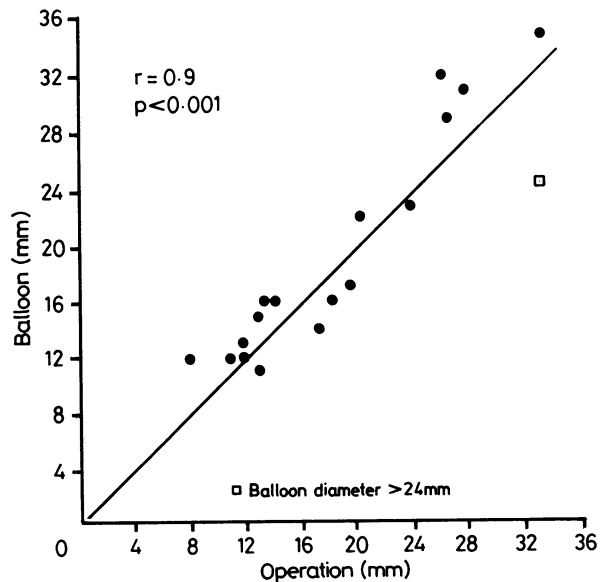


Fig. 6 Comparison of atrial septal defect diameter measured directly at operation and indirectly by balloon sizing techniques (n=18).

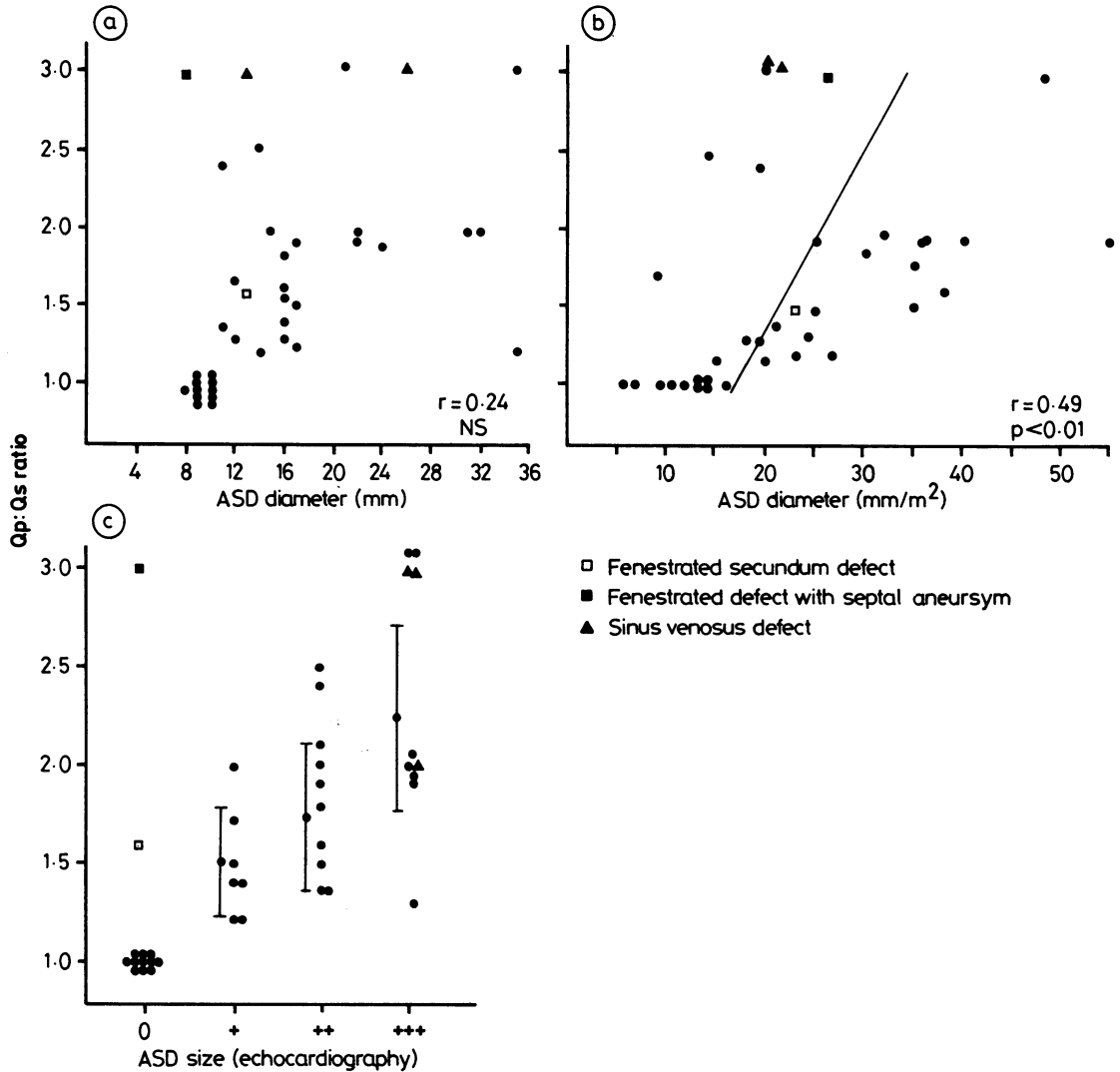


Fig. 7 Relation of pulmonary to systemic blood flow ratio ($Q_p:Q_s$) to size of atrial septal defect estimated by (a) balloon diameter ($n=38$), (b) balloon diameter indexed to body surface area ($n=38$), and (c) echocardiography ($n=40$). 0, no shunt; +, small; ++, medium; +++, large.

fied echo free areas in the upper atrial septum in three of four patients with a sinus venosus defect (Fig. 4b), but the defect was not visualised in the fourth patient. Although thinning of the septum at the level of the fossa ovalis was observed in most of the 11 patients with a foramen ovale, echo free areas along the septum were not seen.

CONTRAST ECHOCARDIOGRAPHY

Contrast injection into the left atrium showed variable left to right shunting in all of the 28 patients with an atrial septal defect in whom the defect was crossed

(one sinus venosus defect not crossed). A small amount of left to right shunting, probably catheter related, was also present in five of the 11 patients with a foramen ovale. Right to left shunting at atrial level was detected in 15 of 29 patients and a negative contrast effect in eight of 29 patients with an atrial septal defect, but neither was seen in patients with a foramen ovale. The Table summarises these results.

SIZING TECHNIQUES

The echocardiographic grading of defect size as small, moderate, or large showed a fairly close and highly

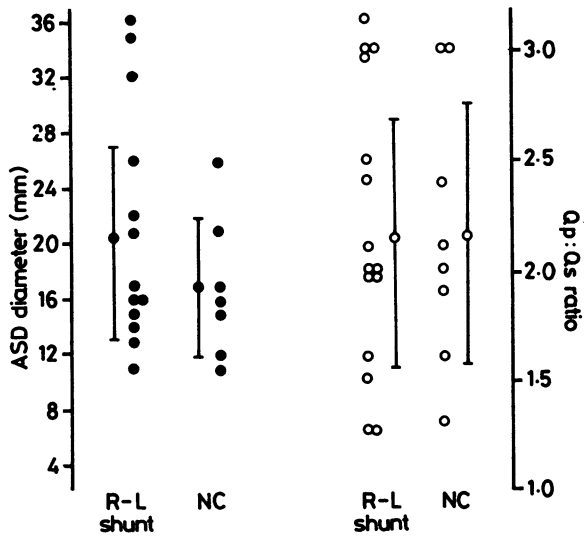


Fig. 8 Balloon assessment of atrial septal defect (ASD) diameter (●) and pulmonary to systemic blood flow ratio ($Q_p:Q_s$) (○) in patients in whom a right to left (R-L) shunt or negative contrast (NC) effect was seen.

significant ($p < 0.005$) relation to the diameter measured by the balloon, although some overlap between the groups was evident (Fig. 5). The balloon technique did not distinguish between defects of < 10 mm in diameter and a foramen ovale, but this has little practical significance as all the defects correctly identified by echocardiography had a diameter of ≥ 11 mm. In both patients with a fenestrated secundum defect, the balloon substantially underestimated overall defect size.

Of the 18 patients in this series who had undergone operative closure of a simple non-fenestrated secundum defect, comparison of defect diameter measured at operation with that at catheterisation showed a close correlation with no tendency for either measurement to vary systematically with respect to the other (Fig. 6).

RELATION BETWEEN DEFECT SIZE AND SHUNT

In contrast, the relation between defect size and pulmonary to systemic blood flow ratio at the time of catheterisation was poor (Fig. 7a). No correlation was evident unless defect diameter was indexed to body surface area, when the correlation did achieve statistical significance (Fig. 7b). In patients with large defects (> 25 mm in diameter) the ratio of pulmonary to systemic blood flow varied from 1.3 to 3:1. A similar variability in defect diameter was present in patients with a large left to right shunt, although for anatomical reasons, either because of fenestration or position high in the septum, the accuracy of balloon

sizing was limited in some of these patients. Variability in the measured shunt was particularly pronounced in patients with a large (+++) defect on echocardiography (Fig. 7c). The mean left to right shunt in seven patients with a small (+) defect was 1.5:1 and the maximum shunt 2.0:1.

The presence of a right to left shunt or negative contrast effect did not allow prediction of either the size or the magnitude of the intracardiac shunt in patients with an atrial septal defect (Fig. 8), both measurements showing considerable variability in the patients with these contrast phenomena.

Discussion

This study has validated cross sectional echocardiography in children as a sensitive and specific investigation for the diagnosis and quantitative evaluation of isolated defects of the atrial septum with two exceptions. Firstly, fenestrated secundum defects (present in 2 of 25 (7%) patients with atrial septal defect in this series) may be missed on echocardiography, and, secondly, the sensitivity of diagnosis of defects of the upper atrial septum remains in some doubt for in this series a sinus venosus defect was not visualised in one out of four patients in whom it was present. It is not surprising considering the anatomy of fenestrated defects that they can be missed by cross sectional echocardiography, but the recognition of an atrial aneurysm or an increased right ventricular dimension with paradoxical septal motion on M mode recording should prompt consideration of this diagnosis. M mode echocardiographic findings compatible with right ventricular volume overloading in the presence of an intact fossa ovalis by cross sectional echocardiography should also alert the examiner to examine the upper atrial septum and pulmonary venous drainage with care, particularly if the clinical findings have suggested an atrial septal defect.

Although minute degrees of right to left shunting have been detected in children with uncomplicated ostium secundum defects,¹¹ we found that despite dense right atrial opacification from central injection of contrast medium right to left shunting was present in no more than 50% of children. Furthermore, the range of defect size and pulmonary to systemic blood flow ratios in patients with echocardiographically demonstrated right to left shunting was considerable (Fig. 8) and too large to allow classification of the defect likely to be associated with this type of shunt. This observation does not accord with that of Fraker *et al.*, who noted right to left shunting in all of 11 adult patients with an atrial septal defect, seven of whom had no right to left shunt detectable by oximetry.⁶ Technical factors or changes in right atrial or right

ventricular compliance with age may explain this difference.

A negative contrast effect was present in 28% (8/29) of patients in our series, a figure considerably lower than that reported by Weyman *et al* in a study of 12 patients with atrial septal defect and a mean age of 31 years⁷ but somewhat similar to that reported by Koilpillai *et al* in 50 consecutive patients.¹² Although demonstration of right to left shunting or negative contrast effect may have a place in the differentiation of the smaller defect from thinning of the septum in the region of the fossa ovalis, we do not believe that in children contrast studies contribute significantly to the diagnostic value of imaging from the subcostal position.

The ability of balloon sizing techniques to predict accurately the diameter of defects has been established in this study for the uncomplicated secundum defect by comparison with measurements obtained during defect closure on cardiopulmonary bypass. For technical reasons the procedure cannot reliably determine the size of a sinus venosus or fenestrated secundum defect. Balloon sizing has, however, provided an anatomical measurement that can be conveniently used as a reference for validation of echocardiographic techniques and has confirmed that the extent of echo free areas defined on echocardiography from the subcostal position does indeed correspond to the margins of the septal defect itself. Echocardiography may thus have particular value in longitudinal studies of the natural history of the smaller defect that is not closed surgically¹³ and may provide information about which type of defects can undergo a spontaneous reduction in size.¹⁴⁻¹⁶

The poor correlation between defect diameter and pulmonary to systemic blood flow ratio (Fig. 7a and b) raises doubts about the use of the latter measurement as the principal basis for surgical closure. In particular, in one patient with an anatomically large defect (34 mm in diameter) the measured left to right shunt was only 1.3:1. Measurement of interatrial shunting by oximetry in the artificial environment of the catheterisation laboratory provides only a crude index of the overall shunt. Changes in ventricular compliance and vascular resistance, for example on exercise, may substantially influence interatrial blood flow.

On the other hand, echocardiographic assessment of defect size is independent of such influences and may provide important information that should influence the long term prognosis and hence the decision for closure. With typical clinical, radiographic, electrocardiographic, and echocardiographic features, routine cardiac catheterisation for the uncomplicated

moderate or large secundum atrial septal defect is unnecessary.

References

- 1 Cohn LH, Morrow AG, Braunwald E. Operative treatment of atrial septal defect: clinical and haemodynamic assessments in 175 patients. *Br Heart J* 1976; 29: 725-34.
- 2 Dillon JC, Weyman AE, Feigenbaum H, Eggleton RC, Johnston K. Cross-sectional echocardiographic examination of the interatrial septum. *Circulation* 1977; 55: 115-20.
- 3 Liew N, Scallion R, Dehar VS, Kisslo JA. Two dimensional echocardiographic findings in atrial septal defect. *Circulation* 1977; 56: 447-56.
- 4 Silverman NH, Schiller NB. Apex echocardiography: a two-dimensional technique for evaluating congenital heart disease. *Circulation* 1978; 57: 503-11.
- 5 Bierman FZ, Williams RG. Subxiphoid two-dimensional imaging of the interatrial septum in infants and neonates with congenital heart disease. *Circulation* 1979; 60: 80-90.
- 6 Fraker TD Jr, Harris PJ, Behar VS, Kisslo JA. Detection and exclusion of interatrial shunts by two-dimensional echocardiography and peripheral venous injection. *Circulation* 1979; 59: 379-84.
- 7 Weyman AE, Wann LS, Caldwell RL, Hurwitz RA, Dillon JC, Feigenbaum H. Negative contrast echocardiography: a new method for detecting left-to-right shunts. *Circulation* 1979; 59: 498-505.
- 8 Bourdillon PDV, Foale RA, Rickards AF. Identification of atrial septal defects by cross-sectional contrast echocardiography. *Br Heart J* 1980; 44: 401-5.
- 9 Miller HC, Brown DJ, Miller GAH. Comparison of formulae used to estimate oxygen saturation of mixed venous blood from caval samples. *Br Heart J* 1974; 36: 446-51.
- 10 King TD, Thompson SL, Mills NL. Measurement of atrial septal defect during cardiac catheterization: experimental and clinical results. *Am J Cardiol* 1978; 41: 537-42.
- 11 Levin AR, Spach MS, Boineau JP, Canent RV Jr, Capp MP, Jewett PH. Atrial pressure-flow dynamics in atrial septal defects (secundum type). *Circulation* 1968; 37: 476-88.
- 12 Koilpillai C, Gilbert BW, Phaneuf DC, Drobac M, Howard RJ, Rakowski H. Can two-dimensional echocardiography diagnose secundum atrial septal defect and predict the need for surgery? [Abstract]. *Circulation* 1982; 66 (suppl II): 161.
- 13 Anderson M, Lyngborg K, Møller I, Wennevold A. The natural history of small atrial septal defects: long term follow-up with serial heart catheterizations. *Am Heart J* 1976; 92: 302-7.
- 14 Cumming GR. Functional closure of atrial septal defects. *Am J Cardiol* 1968; 22: 888-92.
- 15 Hoffman JIE, Rudolph AM, Danilowicz D. Left to right atrial shunts in infants. *Am J Cardiol* 1972; 30: 868-75.
- 16 Mody MR. Serial hemodynamic observations in secundum atrial septal defect with special reference to spontaneous closure. *Am J Cardiol* 1973; 32: 978-81.