

Nomenclature and classification of congenital heart disease

MICHAEL J. TYNAN¹, ANTON E. BECKER², FERGUS J. MACARTNEY³,
MANUEL QUERO JIMÉNEZ⁴, ELLIOT A. SHINEBOURNE⁵, AND
ROBERT H. ANDERSON^{6,7}

SUMMARY At present there is no universally accepted nomenclature for congenital cardiac malformations. Much of the controversy results from failure to distinguish the structural connections of the heart from the morphology and spatial relations of its components. The confusion is compounded by an abundance of individual definitions, many of them speculative.

The present article proposes a totally descriptive nomenclature. It describes in turn the connections of the cardiac segments, their morphology, their relations, and additional anomalies in any segment. Each step in the segmental approach is discrete. The overall effect is to force a succinct and comprehensive description of any cardiac malformation, no matter how complex.

To be of value, a nomenclature must allow all congenital heart defects to be described unambiguously, accurately, and succinctly. It must assist the clinical cardiologist to diagnose and describe all these anomalies during life. It must be compatible with the morphological findings so that it is as valid for examinations at operation or necropsy as it is during diagnostic investigations. A classification and nomenclature should not be difficult to learn or to remember. Clarity, not erudition, is the touchstone of success.

It is our contention that classifications at present in use do not satisfy these criteria. They lack flexibility and are frequently derived from morphogenetic concepts which are more or less speculative. In the less flexible systems, where a Procrustean approach is necessary, attempts to make them comprehensive result in sub-classifications with alphabetical and numerical designations (Edwards and Burchell, 1949) which have no descriptive value. In those based in part upon deductions from

normal embryology, changes in nomenclature are frequent and depend upon the authority whose theories are considered to be most valid at that time or in that place (de la Cruz and Nadal-Ginard, 1972; Van Praagh, 1972).

There is little doubt that a segmental approach (Van Praagh *et al.*, 1964; de la Cruz and Nadal-Ginard, 1972; Van Praagh, 1972; Kirklin *et al.*, 1973; de la Cruz *et al.*, 1976) to description is logical, but there is no consensus on how to employ this analytical method (Shinebourne *et al.*, 1976; Brandt and Calder, 1977). For example, a recent article (Stanger *et al.*, 1977) was accompanied by an editorial and glossary (Van Praagh, 1977) to facilitate its comprehension. Since the glossary contained such cryptic terms as 'isolated atrial non-inversion' and 'isolated ventricular discordance' its success was limited!

In any segmental approach, the prime requirement is the identification of the components of each cardiac segment. Then, since the route of the circulation is fundamental to the physiology and treatment of congenital heart disease, nomenclature should be based on the connections of the segments. Consideration of the connections must not exclude attention to and description of the relations of the segments nor obscure awareness that variations in chamber morphology can exist with the same connections.

The most productive way of using the sequential approach is to employ a synthesis of connections,

¹Guy's Hospital, London.

²Wilhelmina Gasthuis, Amsterdam.

³Hospital for Sick Children, London.

⁴Hospital Ramon y Cajal, Madrid.

⁵Brompton Hospital, London.

⁶Cardiothoracic Institute, Brompton Hospital, London.

⁷RHA is supported by the Joseph Levy Foundation together with the British Heart Foundation.

Table 1

(A)	Define atrial situs
(B)	Describe atrioventricular junction <ol style="list-style-type: none"> (i) Connections (ii) Mode of connection (iii) Ventricular morphology (if not specified by (i)) (iv) Relation of chambers in ventricular mass
(C)	Describe ventriculoarterial junction <ol style="list-style-type: none"> (i) Connections (ii) Relation of arterial valves and great arteries (iii) Morphology of outflow tracts
(D)	Define additional anomalies

morphology, and relations at each junction of the cardiac segments. Thus connections, morphology, and relations must be described both at the junction of the atria with the ventricles and between the chambers in the ventricular mass and the great arteries.

The segmental approach proposed by some of us (Shinebourne *et al.*, 1976) has proved to have deficiencies and does not provide this synthesis. It has been modified to provide a comprehensive and easily assimilable nomenclature.

(A) Steps employed in descriptive analysis (Table 1)

The initial step is to identify the atrial situs. The analysis of the atrioventricular junction is then performed. The type and mode of atrioventricular connection are determined. In most instances, this process will include identification of ventricular morphology. If not identified, this must be established. Then the relations of chambers in the ventricular mass are described. This same process is then repeated at the level of the junction of the great arteries with the ventricular mass, identifying connections, relations, and the morphology of the outflow tracts. Finally, knowing the route of circulation and the anatomy and relations of the cardiac chambers, additional cardiac anomalies are described.

(B) Definitions

There is little controversy concerning definition and terminology of atrial chambers (Van Praagh *et al.*, 1964; de la Cruz *et al.*, 1976; Shinebourne *et al.*, 1976). However, less agreement exists with regard to the nomenclature and anatomy of chambers within the ventricular mass (Lev, 1954; Van Praagh *et al.*, 1964; Lev *et al.*, 1969; de la Cruz *et al.*, 1976; Shinebourne *et al.*, 1976). For example, the term 'single ventricle' is used to describe hearts which possess 2 chambers within their ventricular mass (Van Praagh *et al.*, 1964; Lev *et al.*, 1969). It is

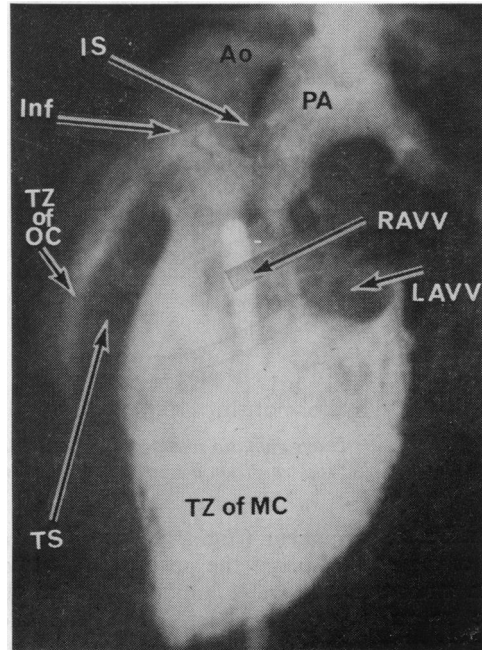


Fig. 1 Angiogram taken so as to show the septum between the chambers in profile in an example of 'single ventricle with outlet chamber' (univentricular heart of left ventricular type). The anterior chamber has both an outlet component (OC) and a trabecular component. It is not merely an infundibular chamber, but is a rudimentary chamber of right ventricular type separated from the main chamber (MC) by the trabecular septum (TS). Ao = aorta; PA = pulmonary artery; Inf = infundibulum; TZ = trabecular zone; IS = infundibular septum; RAVV, LAVV = right, left atrioventricular valve. See also Fig. 8. Angiogram provided by courtesy of Dr B. Soto, University of Alabama in Birmingham, Birmingham, Alabama, USA.

implicit in this usage that one of these chambers is not a ventricle. This is a problem which cannot be ignored, nor dismissed on the basis that one chamber is merely the infundibular or conus portion of the right ventricle (Van Praagh *et al.*, 1964). Such chambers contain, in addition to an infundibulum, a discrete trabecular zone separated from the main chamber by a trabecular septum (Fig. 1). To clarify this situation, it is necessary to define the minimal requirements for a chamber to be considered a ventricle. The initial step in this process is to be clear concerning the components of a normal ventricle. Goor and Lillehei (1975) have suggested that normal ventricles possess 3 components, and our observations endorse this opinion. In descriptive terms these components are the inlet component, the trabecular component, and the outlet or

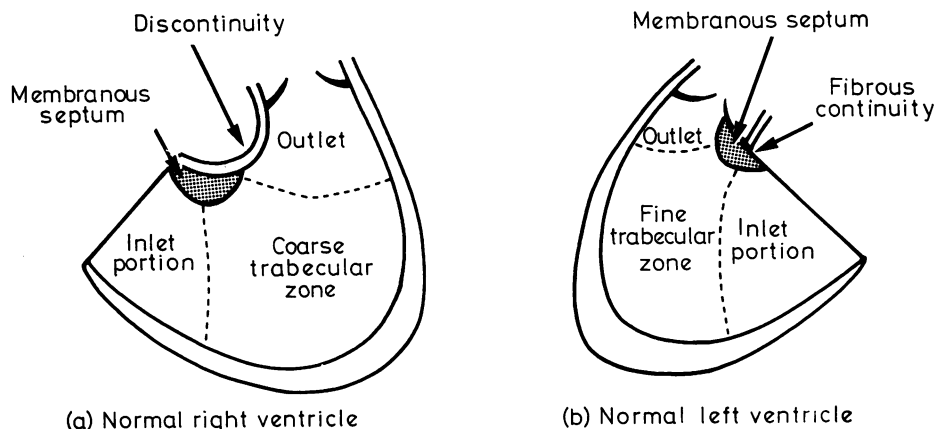


Fig. 2 Diagrammatic representation of the components of normal ventricles. In such normal ventricles, the transition between the components is indistinct.

infundibular component (Fig. 2). The *ventricular inlet component* comprises the portion downstream of an atrioventricular valve annulus whether that valve be patent or imperforate. The anatomical presence of an inlet component is unrelated to the patency of its valve. The *ventricular trabecular*

component comprises the body of the ventricle distal to the insertion of the papillary muscles. The trabecular pattern is distinctive and is independent of both inlet and outlet. Thus a distinction can be made between a trabecular portion of morphologically right ventricular type and one of morphologi-

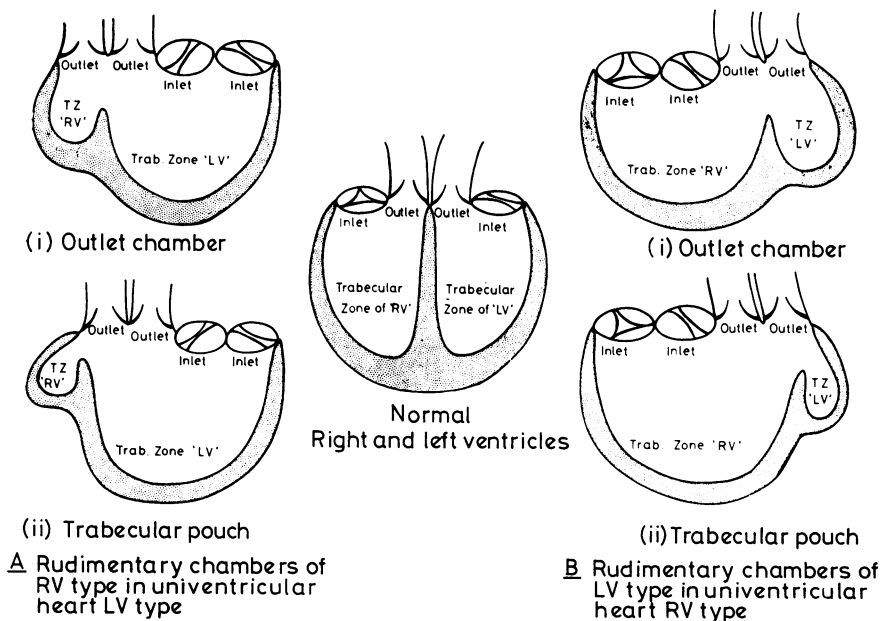


Fig. 3 Diagrammatic representation of the possible types of rudimentary chamber compared with normal right and left ventricles. Rudimentary chambers of right ventricular (RV) type coexist with main chambers of left ventricular (LV) type giving univentricular hearts of left ventricular type. Rudimentary chambers of left ventricular type are found in univentricular hearts of right ventricular type, the main chamber having the trabecular zone of the right ventricle. Rudimentary chambers can exist with double outlet, but are not illustrated.

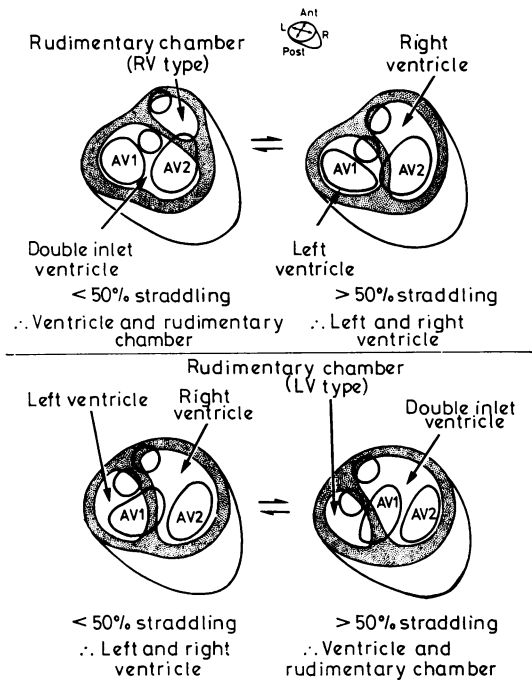


Fig. 4 Diagram illustrating the spectrum which exists when the right (upper diagrams) or left (lower diagrams) atrioventricular valve straddles the ventricular septum. The degree of straddle refers to the amount by which the valve is committed to the chamber with right ventricular characteristics. It is suggested that 50 per cent straddling be the 'cut-off' point for assigning an atrioventricular valve to a chamber in the ventricular mass. These illustrations do not depict every situation in which straddling occurs, but wherever a valve straddles a septum the principles remain the same.

cally left ventricular type. The ventricular outlet component supports the arterial valve of the ventricle. It may be a complete muscular structure, or may be attenuated to permit continuity between the atrioventricular and arterial valves.

A normal ventricle has all 3 components. However, the left ventricle in double outlet right ventricle is generally accepted to be a ventricle though it has no outlet component. In accordance with common usage, therefore, the outlet component is not essential for a chamber to be considered a ventricle. We suggest that the minimal requirements for a chamber to be considered a ventricle are that it possesses an inlet portion and a trabecular portion as defined above. Chambers which do not possess an inlet portion are not ventricles and are described as rudimentary chambers. They may be of left or right ventricular type depending upon the nature of their trabecular portion (Fig. 3). They may be of two

varieties—outlet chambers which possess both trabecular and outlet portions or trabecular pouches having only a trabecular part (Fig. 3). Each of these varieties may be of left or right ventricular type.

In the normal heart, the inlet and outlet portions of each ventricle are unequivocally committed to their respective trabecular zones. However, in malformed hearts it is known that either or both inlet and outlet components can straddle or override the septum separating the trabecular portions (Liberthson *et al.*, 1971; Quero Jiménez *et al.*, 1973). Between the situations in which inlet or outlet components are entirely committed to one ventricle or the other, there is a continuum of variation that cannot be glossed over. Any classification must cater for this contingency. In the case of overriding arterial valves, Kirklin *et al.* (1973) suggested that they be assigned to the ventricle supporting more than half the valve circumference. We suggest that this concept be extended to straddling or overriding inlet components and that such components also be assigned to the chamber connecting to more than half their atrioventricular annulus. A chamber in the ventricular mass is judged to possess an inlet component, and hence be a ventricle, when its connection is to more than half an atrioventricular valve annulus (Fig. 4). When this condition is not fulfilled, it is a rudimentary chamber. A rudimentary chamber is defined as an outlet chamber when it supports more than half an arterial valve annulus. It is a trabecular pouch when the trabecular portion in question is connected to less than half the circumference of both an atrioventricular and an arterial valve (Fig. 5).

In the presence of a common atrioventricular valve connecting both atria to both chambers in the ventricular mass, where this can, by inspection of the attachment of valve leaflets to the ventricular mass, be divided into mitral and tricuspid components, these should be treated as described for separate mitral and tricuspid valves. Where the common valve cannot be so divided both these chambers are defined as ventricles if they each receive more than 25 per cent of the orifice of the common valve. If one receives less than 25 per cent it is considered not to have an inlet portion and therefore to be a rudimentary chamber.

This approach to straddling or overriding valves aims at providing a means of making decisions when the atrioventricular or arterial connections are in doubt. Since such decisions involve arbitrary subdivisions of a continuous spectrum of anomalies, and are made using methods where precise quantification is difficult, the estimated degree of overriding or straddling should be included in the description of the heart.

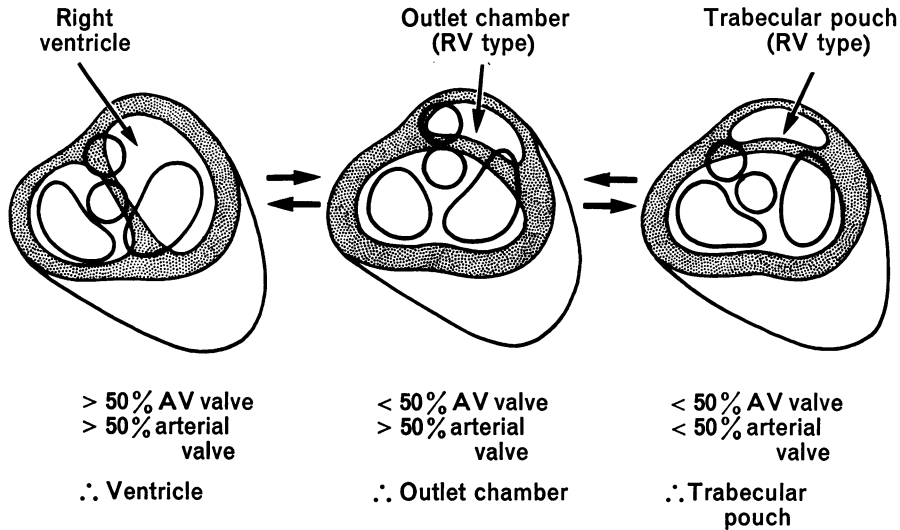
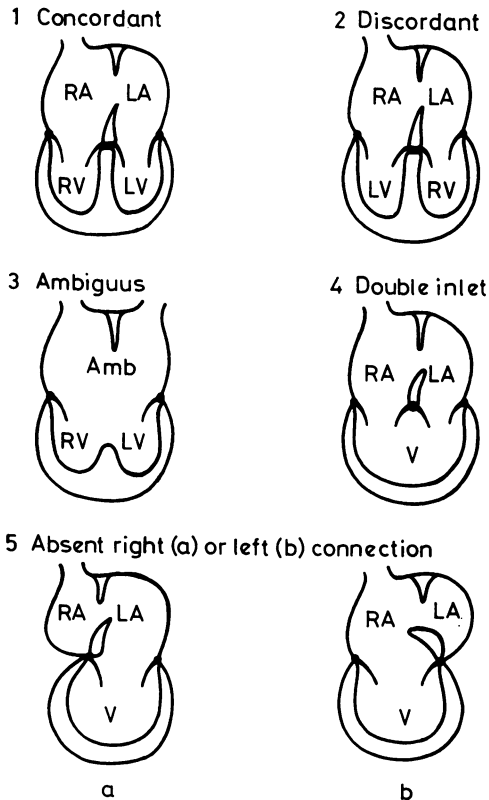


Fig. 5 Diagram illustrating the spectrum from a ventricle through an outlet chamber to a trabeculated pouch. The spectrum illustrated is of rudimentary chamber of right ventricular type. A similar spectrum exists for rudimentary chambers of left ventricular type. For simplicity, the question of concordance or discordance and the possibilities of double outlet rudimentary chamber or single outlet heart have been omitted.

Atrioventricular connections



(C) Determination of atrial situs

There are 3 varieties of atrial situs. These are situs solitus, situs inversus, and situs ambiguus (Van Mierop *et al.*, 1970). In the presence of situs solitus or inversus of the viscera, it is exceedingly rare for atrial situs not to reflect this visceral situs. Therefore, atrial situs can usually be established from visceral situs. In doubtful situations, particularly in the presence of situs ambiguus, bronchial anatomy is more reliable than the situs of the abdominal viscera as a guide to atrial situs. Partridge *et al.* (1975) showed that bronchial situs could be reliably identified radiologically because the morphologically left main bronchus is significantly longer than the morphologically right main bronchus. If both bronchi are approximately the same length, then bronchial isomerism exists and situs ambiguus of the atria is likely. Though bronchial anatomy is the best clinical guide to atrial situs, it is known that in rare cases atrial morphology does not correspond with bronchial anatomy (Brandt and Calder, 1977; Macartney *et al.*, 1978). Where such a situation is

Fig. 6 Diagrammatic representation of the possible types of atrioventricular connection. Where lateralisation is present, the diagrams illustrate situs solitus. The same possibilities exist and the same terms are used for situs inversus. Abbreviations: RA, right atrium; LA, left atrium; Amb, ambiguous atria; RV, right ventricle; LV, left ventricle; V, ventricle in the ventricular mass.

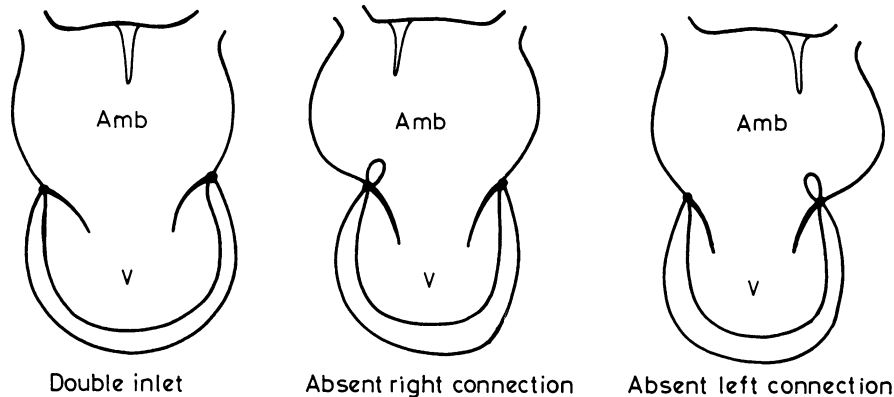


Fig. 7 Diagram illustrating how double inlet or absence of right or left atrioventricular connection can exist with ambiguous atria.

suspected, the question can only be resolved by demonstration of atrial morphology, either by angiocardiographically injecting contrast medium into the atrial appendages or by direct inspection.

(D) Description of atrioventricular junction

(i) ATRIOVENTRICULAR CONNECTIONS

There is little problem in defining atrioventricular connections when 2 atria connect with 2 ventricles. In these circumstances the possible types of connection are atrioventricular concordance, atrioventricular discordance, or ambiguous atrioventricular connection (Fig. 6). A concordant connection exists when the morphologically right atrium connects to the morphologically right ventricle and the morphologically left atrium to the morphologically left ventricle (Fig. 6.1). Discordance describes the converse connections (Fig. 6.2). In situ ambiguus, when the atria cannot be differentiated one from the other, the connection with 2 ventricles is necessarily ambiguous (Fig. 6.3).

Potential for confusion in defining atrioventricular connections exists when both atria do not connect directly with separate chambers in the ventricular mass, for instance when both atria connect to the same chamber or alternatively when one atrium is not directly connected to any chamber by either a perforate or an imperforate atrioventricular valve. These examples are separate and distinct connections, namely double inlet ventricle (Fig. 6.4) and absence of one atrioventricular connection (Fig. 6.5). Both can exist with solitus, inversus, or ambiguous atrial chambers (Fig. 7). These two connections make up the category of the univentricular heart.

(ii) MODE OF CONNECTION

The mode of atrioventricular connection describes the anatomy of the valve annuli at the atrioventricular junction. In the presence of definitive right and left ventricles without straddling of either atrioventricular valve, then the valves can be described as 'tricuspid', 'mitral', or common. In the univentricular heart, it may be impossible even at necropsy to identify definite 'mitral' or 'tricuspid' valve morphology. The non-specific terms 'right' and 'left' atrioventricular valve according to position (Anderson *et al.*, 1977) are therefore preferred in order to minimise confusion. When 2 atria are found to connect with the ventricular mass, the mode of connection may be via 2 perforate valves, one of which may straddle, a common atrioventricular valve which may straddle, or by one perforate and one imperforate valve. In order to diagnose an imperforate valve, rudiments of that valve must be unequivocally demonstrated. Though these rudiments are most frequently identified at necropsy, they can be shown in life angiographically (Macartney *et al.*, 1976) or echocardiographically (Mortera *et al.*, 1977). When rudiments of an imperforate valve are not seen, the terms absent right or left atrioventricular connection are used. In this context these terms characterise both type and mode of connection (Fig. 6.5). However, with an absent connection, the valve present can still straddle, in which case this must be specified together with the degree of straddling.

(iii) VENTRICULAR MORPHOLOGY

When both right and left ventricles are unequivocally present, there is little difficulty in differentia-

ting one from the other. However, when rudimentary chambers are present, as in the univentricular heart, guidelines are needed for their identification as right or left ventricular type. The 2 features that are of value in this respect are the characteristics of the trabecular zones of the chambers and the orientation of the septum within the ventricular mass. The quality of morphological rightness or leftness of a chamber is conferred upon it by the structure of the trabecular zone and is independent of its connections. Thus a chamber, be it a ventricle or rudimentary, is of right ventricular type when its trabeculations, particularly those on the septum, are coarse while a chamber of left ventricular type has finer trabeculations and a smooth septal surface. Unlike the septum separating 2 ventricles, that separating a rudimentary chamber from a main chamber may not necessarily be directed to the crux of the heart. In the case of rudimentary chambers of right ventricular type, the septum is anteriorly placed and is orientated towards the acute margin of the heart. In contrast, when a rudimentary chamber of left ventricular type is present, the septum is orientated posteriorly to the crux of the heart.

The description of a rudimentary chamber as being of right or left ventricular type implies that the trabecular zone of the main chamber is of the converse type. Thus the description of double inlet ventricle with rudimentary chamber of right ventricular type automatically implies that the trabecular zone of the main chamber is of left ventricular type. This is important when considering the diagnosis in life since a ventriculogram of sufficient quality for morphological definition may be more easily obtained when injecting into a small volume rudimentary chamber than into a large volume ventricle. Ventricular morphology in the univentricular heart may be indeterminate when only one chamber is present in the ventricular mass. It may be exceedingly difficult to distinguish this type of morphology from that of a right ventricular univentricular heart with a tiny rudimentary chamber of left ventricular type. However, success in making the distinction is more likely when the observer is aware of the possibilities.

(iv) RELATION OF VENTRICULAR CHAMBERS

Having determined the morphology of chambers in the ventricular mass, it is then necessary to identify their relations. Right ventricles are described relative to left ventricles, and may be to right or left, anterior or posterior, and superior or inferior. Rudimentary chambers are described in similar terms relative to the main chamber of a univentricular heart.

Table 2 *Connections of the chambers and great arteries*

<i>Atrioventricular connections</i>	
(i)	Concordant
(ii)	Discordant
(iii)	Ambiguous
(iv)	Double inlet
(v)	Absence of one atrioventricular connection
<i>Arterial connections</i>	
(i)	Concordant
(ii)	Discordant
(iii)	Double outlet ventricle or outlet chamber
(iv)	Single outlet heart

(E) Description of arterial junction with ventricular mass

There have been problems with the description of the ventriculoarterial junction because the connections of the arteries to the chambers in the ventricular mass have been confused with the relations of the great arteries one to another and with the morphology of the outflow tracts. All 3 attributes are necessary for full categorisation of the junction.

(i) ARTERIAL CONNECTIONS

There are 4 varieties of arterial connection (Table 2). Concordant connections exist when the aorta arises from the morphologically left ventricle or an outlet chamber of left ventricular type and the pulmonary artery from the morphologically right ventricle or an outlet chamber of right ventricular type. Discordant connections exist when the converse is true. Double outlet ventricle or double outlet chamber exist when more than half of both the aorta and the pulmonary artery arise from that chamber. Finally, single outlet heart is present when only one great artery is connected to the ventricular mass. There are 3 types: firstly, single outlet heart via the aorta when the pulmonary artery is not directly connected by a perforate or imperforate valve to the chambers in the ventricular mass; secondly, single outlet heart via the pulmonary artery when the aorta is not directly connected by a perforate or imperforate valve to the chambers in the ventricular mass; and, finally, single outlet heart via a persistent truncus arteriosus when a persistent truncus is connected to the chambers in the ventricular mass. The single great artery may arise from a ventricle or an outlet chamber. In all 3 varieties of single outlet heart the artery is assigned to the chamber which supports more than half its arterial valve.

Because potential connections of atria or great arteries to the ventricular mass are difficult to discern in life, absence of right or left atrioventricular connections and single outlet heart are the desig-

nations most likely to be changed by necropsy examination.

(ii) ARTERIAL RELATIONS

When describing the relations of the great arteries, the position of the arterial valves is described one relative to the other in both anteroposterior and lateral planes.

(iii) MORPHOLOGY OF OUTFLOW TRACTS

The morphology of the outflow tracts is independent of both connections and relations. Either or both arterial valves may have a complete infundibulum or may be in fibrous continuity with an atrioventricular valve. It is entirely logical that the situation of double outlet right ventricle may coexist with the morphological entity of tetralogy of Fallot.

(F) Additional cardiovascular abnormalities

These are catalogued in as much detail as the investigations permit and include anomalies of venous return, either pulmonary or systemic, septal defects, and ventricular outlet obstructions. In the majority of cases these 'additional' abnormalities will in fact be the only ones present. Thus, except in those cases with abnormal connections of the cardiac segments, there is little change in the terminology of most congenital cardiac malformations.

Comment

In the introduction we stated why a revision of the classification of congenital cardiac malformations was necessary. In the body of the paper we have presented our solutions to these problems. They differ in several ways from previous classifications. The present nomenclature describes connections, relations, and morphology as interdependent features, all being necessary for full description of the heart. Other approaches have used relations to predict connections (de la Cruz *et al.*, 1976) or else have used relations as interchangeable with connections, as for example in the term 'normally related great arteries' (Van Praagh, 1977).

Just as connections cannot be described in terms of relations, the anatomy of the atrioventricular junction cannot be described by merely indicating the presumed direction of looping of the embryonic heart tube (Van Praagh, 1972). Instead, it is necessary to describe this region in detail. We have chosen to use 4 steps, firstly the overall route of connection (type of connection), secondly the anatomy of the valves at the atrioventricular junction (mode of connection), thirdly the morphology of the ventricular mass, and finally the relation of chambers

within it. Kirklin *et al.* (1973) have previously used the terms 'concordant' and 'discordant' introduced by Van Praagh *et al.* (1964) to describe connections at both atrioventricular and ventriculoarterial levels, and we have followed this precedent. However, at the atrioventricular level connections exist which cannot be described accurately using either this terminology or the loop convention. We have used the terms ambiguous connection, double inlet ventricle, and absence of one atrioventricular connection to describe these situations. Using our terminology, together with separate description of chambers within the ventricular mass of the heart, it has proved possible to provide a description of complex anomalies such as the univentricular heart in all its variations, based solely upon the anatomy as it is observed. Using only anatomical features, we have distinguished chambers within the ventricular mass of univentricular hearts as ventricles and rudimentary chambers. This is necessary because 'single ventricle' and 'common ventricle' are in common usage to describe hearts which possess 2 chambers within their ventricular mass (Van Praagh *et al.*, 1964; Lev *et al.*, 1969; Stanger *et al.*, 1977).

The strict distinction between ventricles and rudimentary chambers also permits rationalisation of the problem of hearts with absence of one atrioventricular connection (Anderson *et al.*, 1977). Such hearts, for example in the majority of cases of tricuspid atresia, are at present excluded from the category of the univentricular heart on arbitrary grounds (Van Praagh *et al.*, 1964). Yet comparison of the anterior chambers in hearts with 'single ventricle' and in hearts with 'tricuspid atresia' shows that from an anatomical and descriptive standpoint they are the same (Fig. 8). Our definitions are aimed at eliminating this paradox, yet accentuating the differences within the univentricular group, namely variations in atrioventricular connection and ventricular morphology. Description of both these features are necessary to categorise fully these hearts.

Our proposed descriptive nomenclature takes the classification of congenital heart disease out of the arena of morphogenetic interpretation, since a nomenclature and classification cannot be part of this process and still fulfil the functions outlined in the introduction.

It is abnormal connections and associated abnormalities which may require surgical treatment. An abnormal relation or morphology alone does not need correction. The importance of the relations and morphology of the cardiac segments is in the planning and execution of surgical treatment. We have purposely avoided the use of terms such as

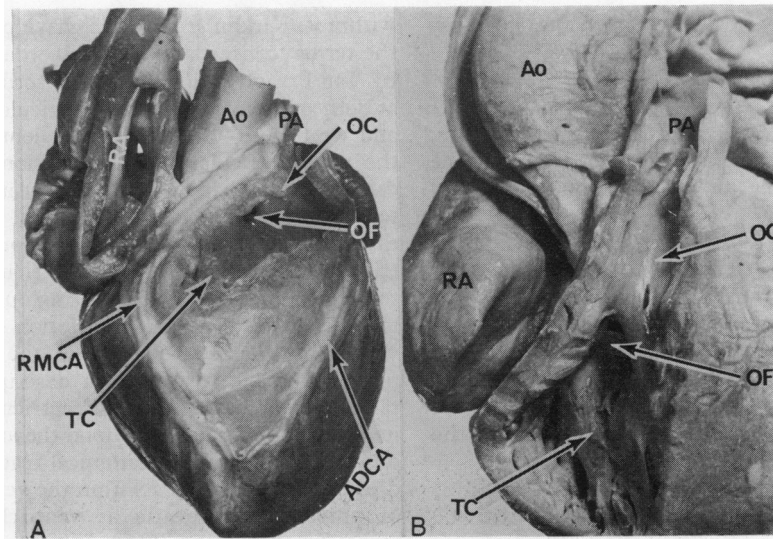


Fig. 8 Photographs of the anterior chambers in two hearts with arterial concordance and 'normally related' great arteries. Fig. 8A shows a heart with typical 'tricuspid atresia'. The right atrial appendage has been removed, showing the absence of the right atrioventricular connection. The right atrium (RA) is not related to the anterior chamber, which has outlet (OC) and trabecular (TC) components. The anterior chamber communicates with the atrial inlet only via the outlet foramen (OF) and the main chamber. Note that the chamber position is delimited by the marginal branch of the right coronary artery (RMCA) and the anterior descending branch (ADCA) of the left. Fig. 8B shows a heart with double inlet ventricle. The anterior chamber is virtually identical in morphology to the chamber illustrated in Fig. 8A. Both are rudimentary chambers of right ventricular type. (Note coarse trabeculations of trabecular zone in Fig. 8B; Ao, aorta; PA, pulmonary artery.)

'transposition', 'malposition', 'tricuspid atresia', 'mitral atresia', etc. because they mean different things to different people. We do not suggest that the terms be discarded. Providing that the basic scheme of connections, relations, and morphology is used then confusion cannot ensue.

We thank the members of the Study Group on Congenital Heart Disease in England and Wales, Dr L. H. S. Van Mierop of Gainesville, USA, Dr T. G. Losekoot of Amsterdam, The Netherlands, and our other colleagues and friends in Europe and America who helped during the formulation of the nomenclature. We are particularly grateful to Dr Benigno Soto for permitting us to use one of his profiled angiograms to illustrate a point.

References

- Anderson, R. H., Wilkinson, J. L., Gerlis, L. M., Smith, A., and Becker, A. E. (1977). Atresia of the right atrioventricular orifice. *British Heart Journal*, **39**, 414-428.
- Brandt, P. W., and Calder, A. L. (1977). Cardiac connexions: the segmental approach to radiologic diagnosis in congenital heart disease. *Current Problems in Diagnostic Radiology*, **7**, 1-35.
- de la Cruz, M. V., Berrazueta, J. R., Arteaga, M., Attie, F., and Soni, J. (1976). Rules for diagnosis of arterioventricular discordances and spatial identification of ventricles. *British Heart Journal*, **38**, 341-354.
- de la Cruz, M. V., and Nadal-Ginard, B. (1972). Rules for the diagnosis of visceral situs, truncocoanal morphologies and ventricular inversions. *American Heart Journal*, **84**, 19-32.
- Edwards, J. E., and Burchell, H. B. (1949). Congenital tricuspid atresia: a classification. *Medical Clinics of North America*, **33**, 1177-1196.
- Goor, D. A., and Lillehei, C. W. (1975). *Congenital Malformations of the Heart*, pp. 11-13. Grune and Stratton, New York.
- Kirklin, J. W., Pacifico, A. D., Barger, L. M., jun, and Soto, B. (1973). Cardiac repair in anatomically corrected malposition of the great arteries. *Circulation*, **48**, 153-159.
- Lev, M. (1954). Pathologic diagnosis of positional variations in cardiac chambers in congenital heart disease. *Laboratory Investigation*, **3**, 71-82.
- Lev, M., Liberthson, R. R., Kirkpatrick, J. R., Eckner, F. A. O., and Arcilla, R. A. (1969). Single (primitive) ventricle. *Circulation*, **39**, 577-591.
- Liberthson, R. R., Paul, M. H., Muster, A. J., Arcilla, R. A., Eckner, F. A. O., and Lev, M. (1971). Straddling and displaced atrioventricular orifices and valves with primitive ventricles. *Circulation*, **43**, 213-226.
- Macartney, F. J., Partridge, J. B., Scott, O., and Deverall, P. B. (1976). Common or single ventricle: an angiographic and hemodynamic study of 42 patients. *Circulation*, **53**, 543-554.

- Macartney, F. J., Partridge, J. B., Shinebourne, E. A., Tynan, M. J., and Anderson, R. H. (1978). Identification of atrial situs. In *Paediatric Cardiology*, 1977, pp. 16-26, ed R. H. Anderson, and E. A. Shinebourne. Churchill Livingstone, Edinburgh.
- Morera, C., Hunter, S., Terry, G., and Tynan, M. J. (1977). The echocardiography of primitive ventricle. *British Heart Journal*, **39**, 847-855.
- Partridge, J. B., Scott, O., Deverall, P. B., and Macartney, F. J. (1975). Visualization and measurement of the main bronchi by tomography as an objective indicator of thoracic situs in congenital heart disease. *Circulation*, **51**, 188-196.
- Quero Jiménez, M., Pérez Trevino, V. M., Maitre Azcárate, M. J., Merino Batres, G., and Mereno Granados, F. (1973). Exaggerated displacement of the atrioventricular canal towards the bulbus cordis (rightwards displacement of the mitral valve). *British Heart Journal*, **35**, 65-74.
- Shinebourne, E. A., Macartney, F., and Anderson, R. H. (1976). Sequential chamber localization—logical approach to diagnosis in congenital heart disease. *British Heart Journal*, **38**, 327-340.
- Stanger, P., Rudolph, A. M., and Edwards, J. E. (1977). Cardiac malpositions: an overview based on study of sixty-five necropsy specimens. *Circulation*, **56**, 159-172.
- Van Mierop, L. H. S., Eisen, S., and Schiebler, G. L. (1970). The radiographic appearance of the tracheobronchial tree as an indicator of visceral situs. *American Journal of Cardiology*, **26**, 432-435.
- Van Praagh, R., Ongley, P. A., and Swan, H. J. C. (1964). Anatomic types of single or common ventricle in man: morphologic and geometric aspects of 60 necropsied cases. *American Journal of Cardiology*, **13**, 367-386.
- Van Praagh, R. (1972). The segmental approach to diagnosis in congenital heart disease. *Birth Defects: Original Article Series*, **8**, No. 5, p. 4. Williams and Wilkins, Baltimore.
- Van Praagh, R. (1977). Terminology of congenital heart disease: glossary and commentary. *Circulation*, **56**, 139-143.

Requests for reprints to Dr M. J. Tynan, Evelina Children's Department, Guy's Hospital, London SE1 9RT.