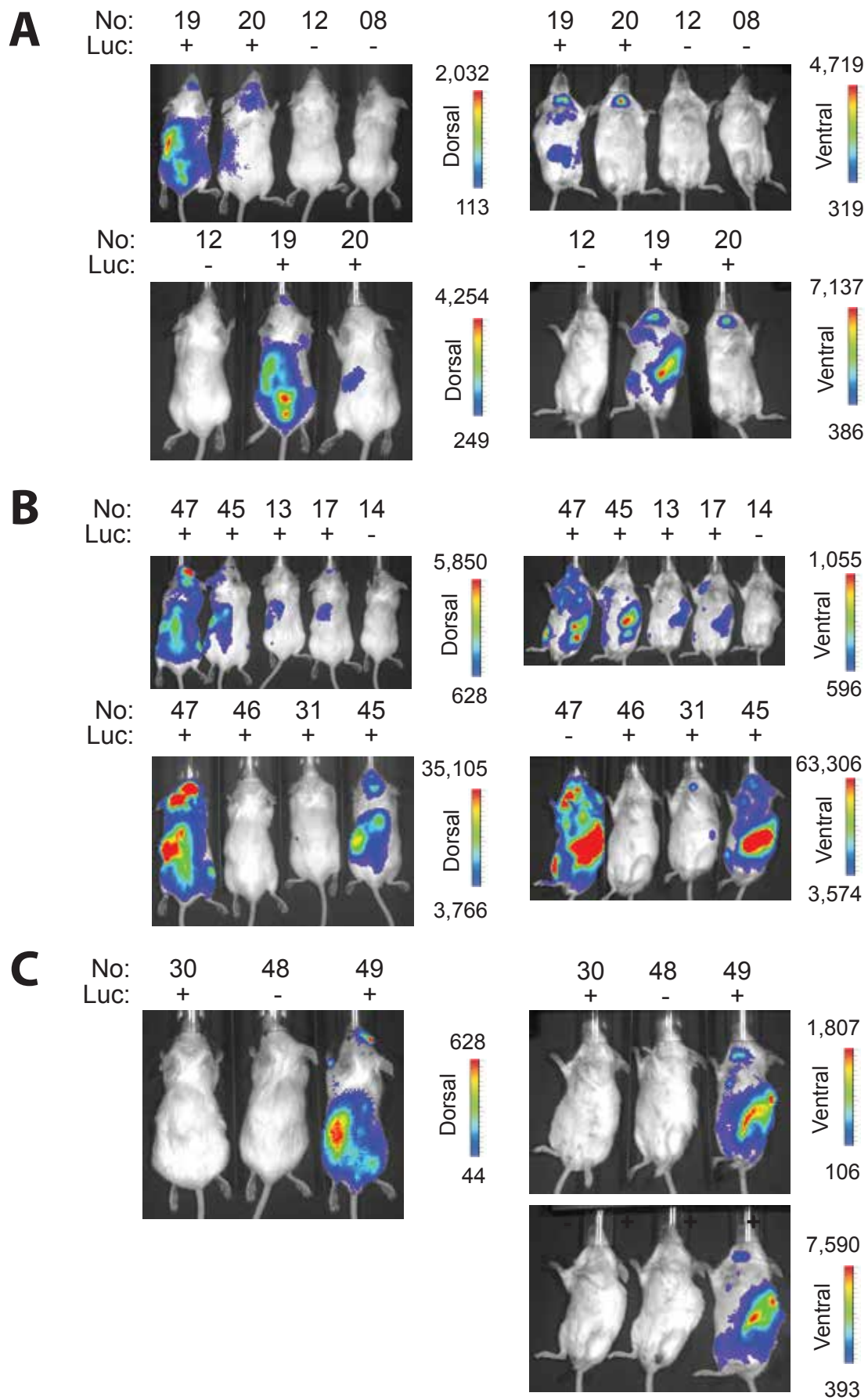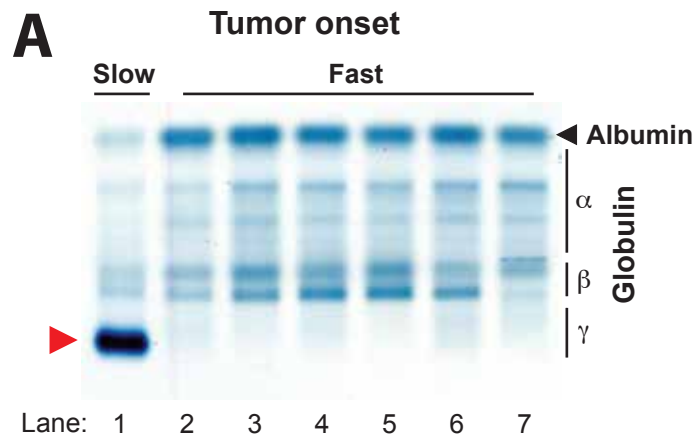
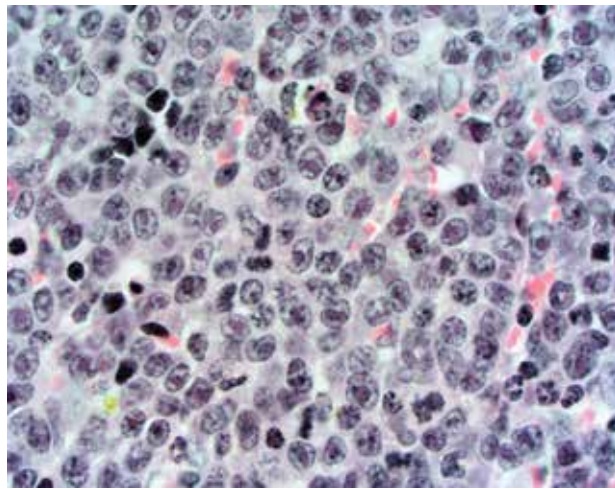


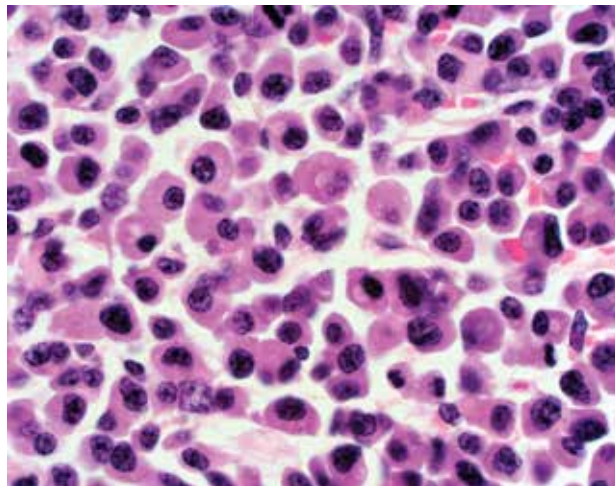
Supplemental Figure 1: Tompkins *et al.*



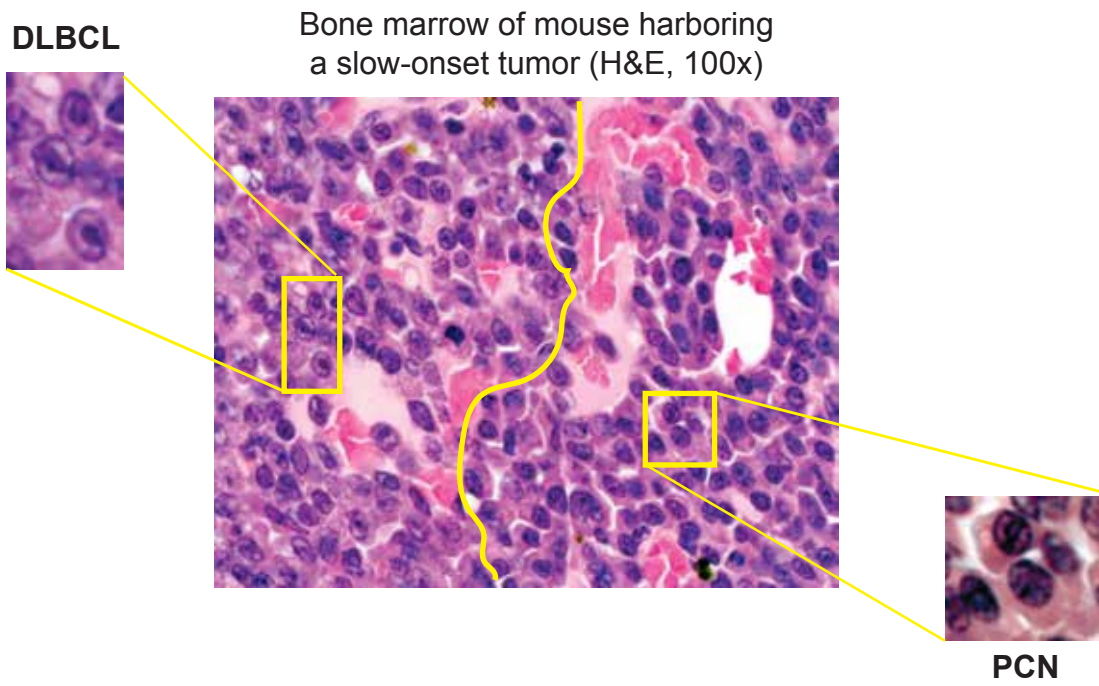
B Bone marrow (H&E, 100x)



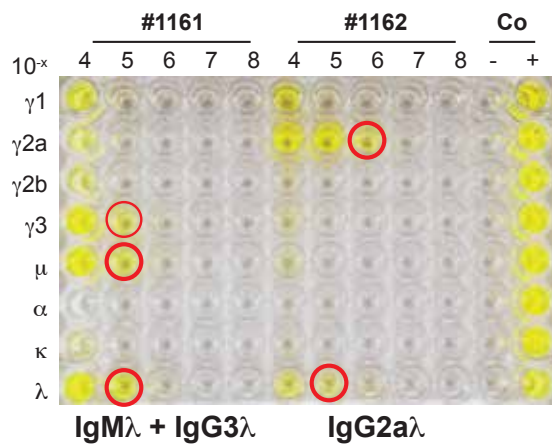
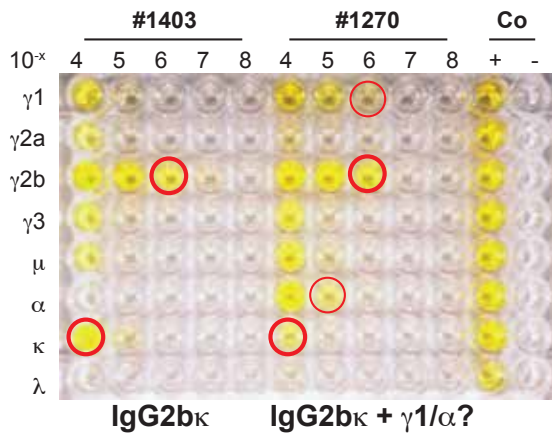

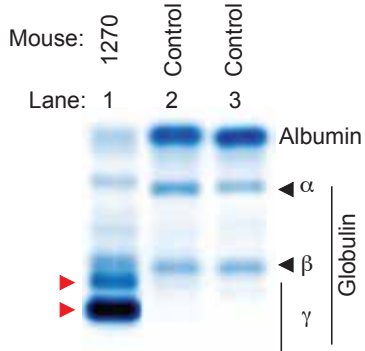
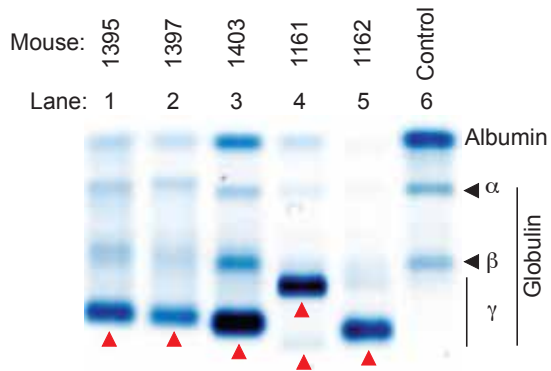
Fast-onset DLBCL



Slow-onset PCN

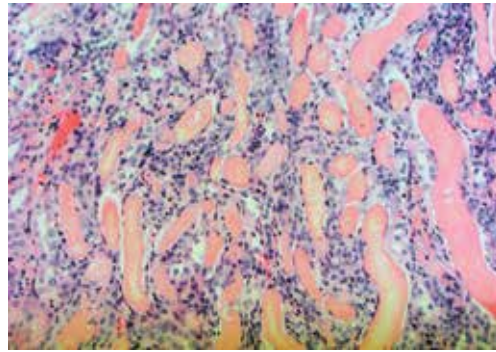


Supplemental Figure 3: Tompkins *et al.*

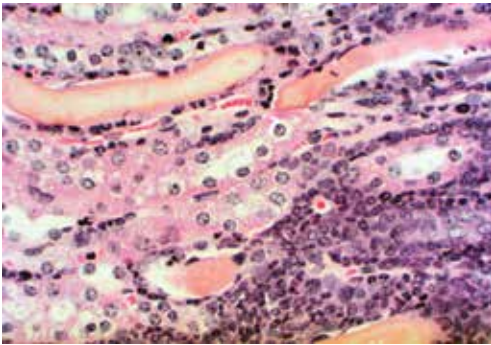


Supplemental Figure 4: Tompkins *et al.*

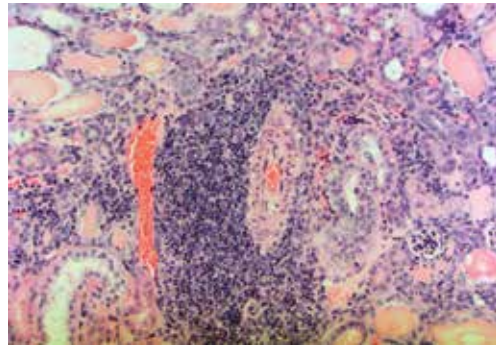
Cast nephropathy



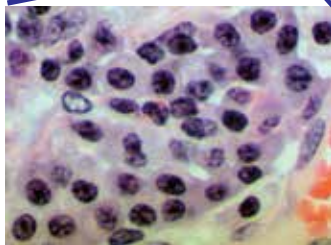
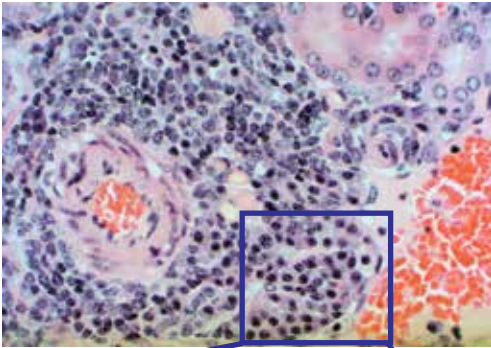
Acute inflammation



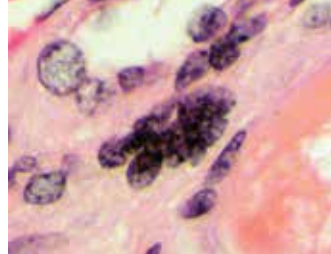
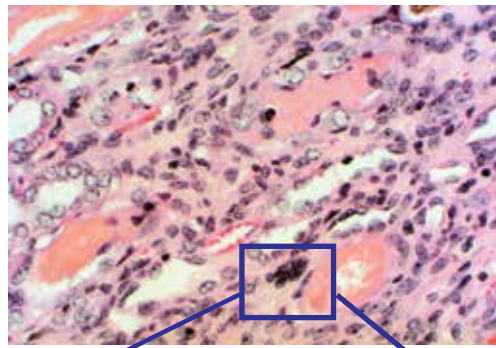
Chronic inflammation

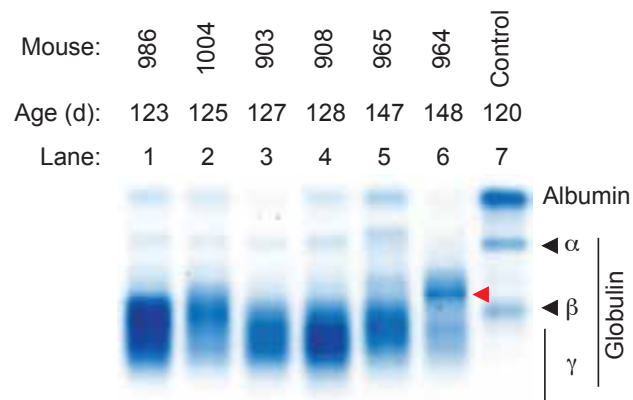
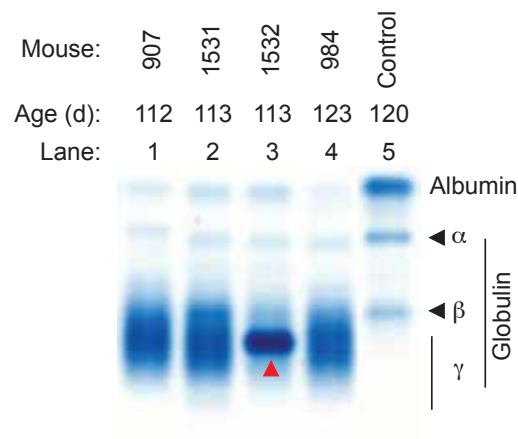
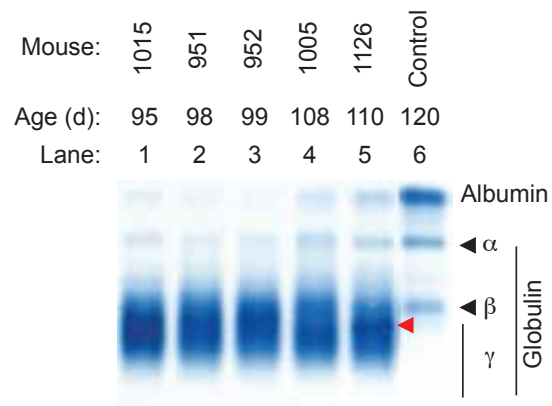


Neoplastic plasma cells

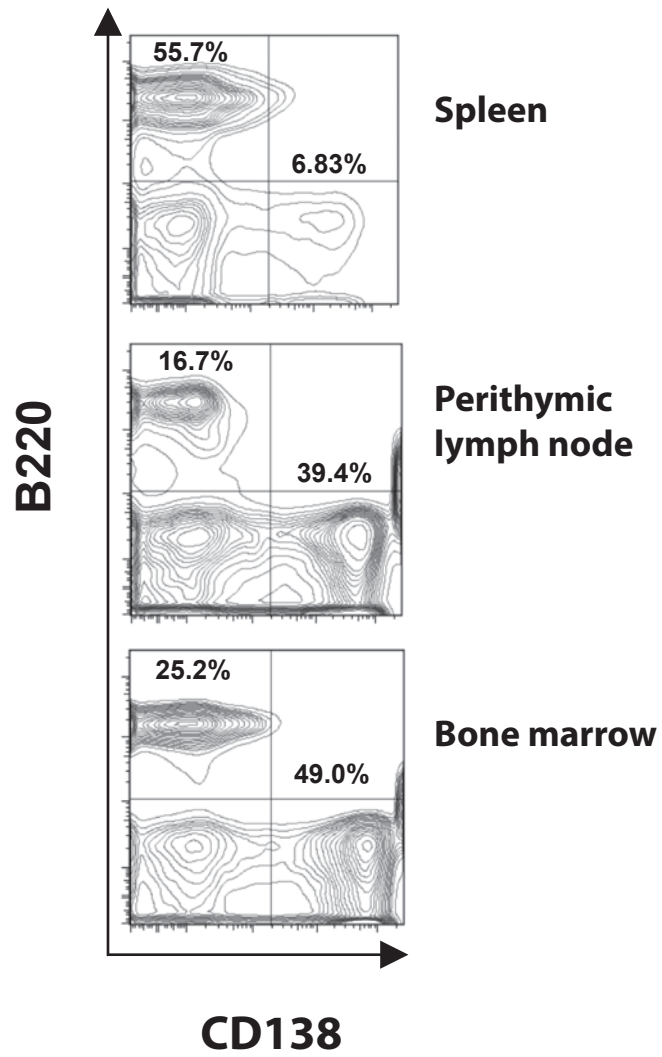


Giant cell

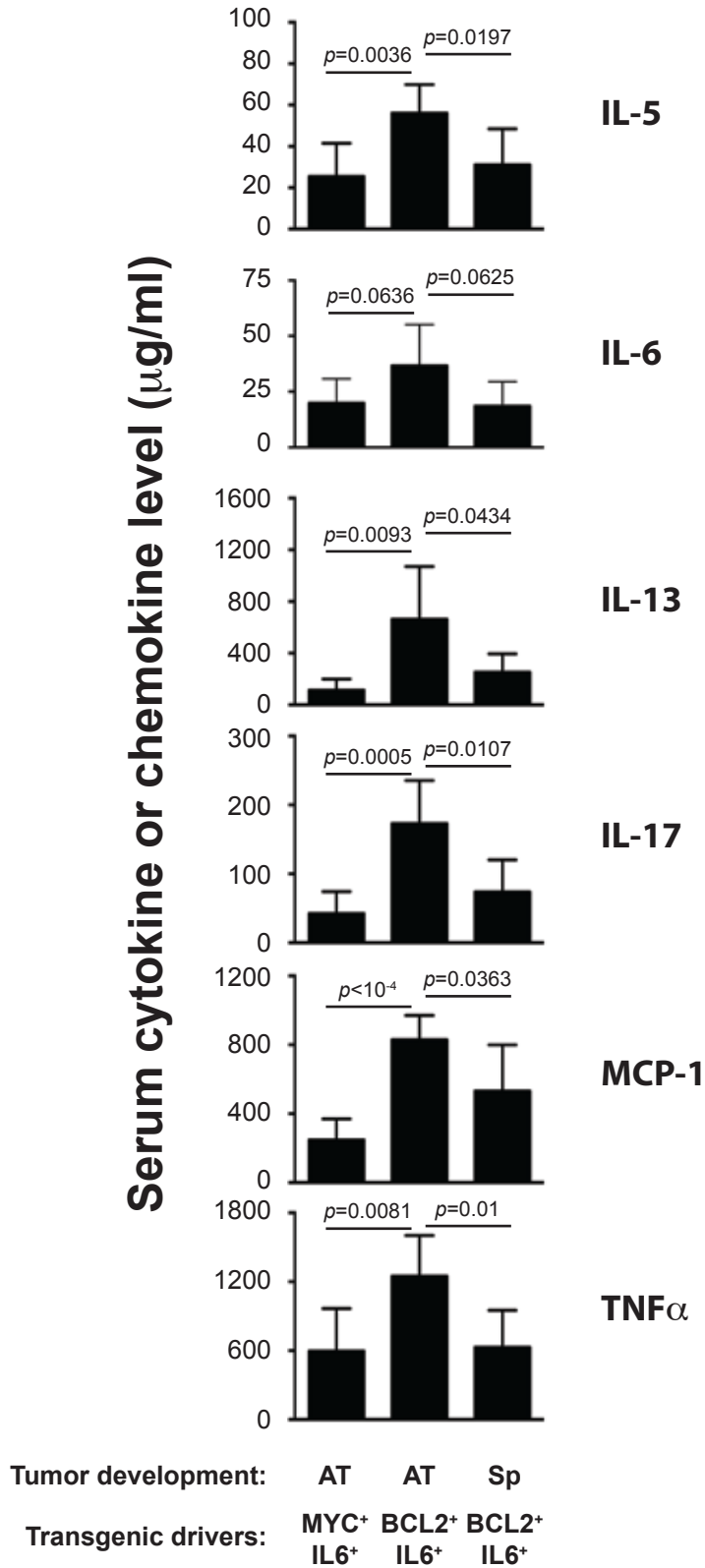




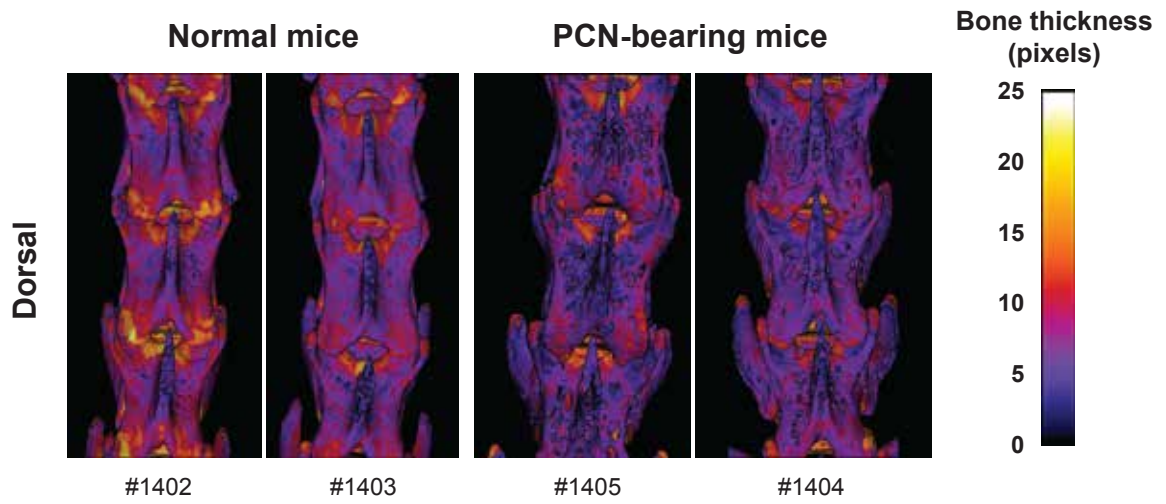
Supplemental Figure 6: Tompkins *et al.*



Supplemental Figure 7: Tompkins *et al.*



Supplemental Figure 8: Tompkins *et al.*



Supplemental Figure 9: Tompkins *et al.*