

Two-dimensional echocardiographic diagnosis of aorticopulmonary window

GENGI SATOMI, KENJI NAKAMURA, YASU HARU IMAI, ATSUYOSHI TAKAO

From the Department of Paediatric Cardiology, Cardiology, and Cardiac Surgery, The Heart Institute Japan, Tokyo Women's Medical College, Tokyo, Japan

SUMMARY Two-dimensional echocardiography was performed in two cases of distal type aorticopulmonary window. The defect of the aorticopulmonary septum could be visualised in both cases in transverse section of the great arteries using our method. We make it a rule to study three different levels of section: plane 1, where the echo of the semilunar valve of the posterior great artery is well seen; plane 2, where the echo of the semilunar valve of the anterior great artery is clearly observed; and plane 3, where neither semilunar valve is seen. The aorticopulmonary septal defects were recognised at the level of plane 2 to plane 3 in our two cases. Two-dimensional contrast echocardiography was performed in one of the cases. The contrast entered the ascending aorta from the main pulmonary artery through the aorticopulmonary septal defect in early systole. Postoperatively, no defects were detected in the aorticopulmonary septum in either case using the same approach, and no passage of contrast into the ascending aorta from the pulmonary artery was noted in the case where contrast was injected. Accurate diagnosis of this anomaly can be made by visualisation of the defect utilising two-dimensional echocardiography. Typing of this anomaly, proximal, distal, or combined may be possible with our new approach.

Aorticopulmonary window is a relatively rare congenital anomaly involving the great arteries.¹⁻³ In patients with this defect, pulmonary resistance tends to increase during early infancy. Therefore, prompt and accurate diagnosis becomes mandatory. Aorticopulmonary window is now classified into three types, as documented previously.⁴ The purpose of this paper is to report our new non-invasive approach to diagnosis of this defect using two-dimensional echocardiography.

Materials and methods

Instruments used for two-dimensional echocardiographic studies included a Toshiba Medical model SSH-10A phased-array ultrasonic sector scanner, an Hitachi Medico model EUB-10 phased-array sector scanner, and an Aloka model 110-S mechanical sector scanner.

Our routine approach when investigating spatial relation between the great arteries is as follows.⁵ The probe is placed over either the third or fourth intercostal space. The semilunar valve of the posterior great artery is identified by M-mode

echocardiography using a two-dimensional probe which is set as a single beam. The mode is then changed to real time while maintaining the axis of the probe; then a plane of the beam is rotated until a circular image of the great artery is obtained. This plane is designated plane 1, in which the echo of the semilunar valve of the posterior great artery is clearly seen. The echo plane is thereafter gradually directed cephalad, so that the echo of the semilunar valve of the anterior great artery is clearly obtained. This is designated plane 2. A slightly more cephalad plane, in which the echo of neither semilunar valve is shown, is designated plane 3. Pictures of normal great artery echoes in plane 1, plane 2, and plane 3 appear in Fig. 1. We studied two cases of aorticopulmonary window in which the diagnoses were confirmed at open surgical repair.

Case reports

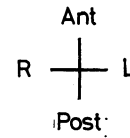
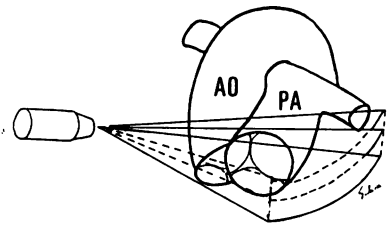
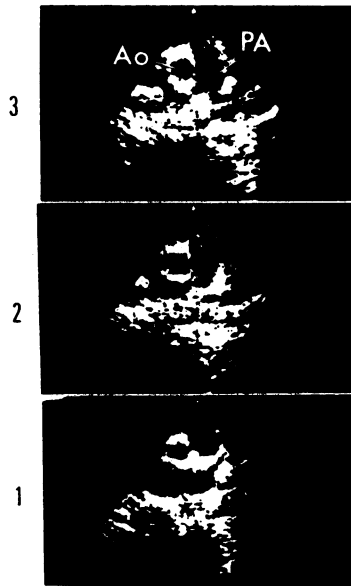
CASE 1

A 3-year-old boy was admitted with a history of poor weight gain in infancy. Findings of combined ventricular hypertrophy on the electrocardiogram,

pulmonary plethora with mild cardiomegaly, and bounding pulses indicated the presence of aorticopulmonary communication. The angiocardigram is shown in Fig. 2. Contrast medium injected in the ascending aorta entered the right pulmonary artery predominantly. Two-dimensional echocardiographic findings are illustrated in Fig. 3. After cardiac catheterisation and confirmation of the lesion,

repair was accomplished under direct vision. Pre-operatively, the aorticopulmonary septum at the levels of plane 2 and plane 3 was shown to be deficient during the whole cardiac cycle by two-dimensional echocardiography. The aorticopulmonary window, measuring about 2 cm in diameter, was closed transaortically using a Teflon patch. After operation, the aorticopulmonary septum was

Fig. 1 Two-dimensional echocardiographic findings of normal (spiral) relation between the great arteries. Posterior wall echo of the left anterior great artery is extended posteriorly from plane 1 to plane 3 (see text). Left-sided structures are to the right and right-sided structures are to the left of the observer. Ao, aorta; PA, pulmonary artery.



Spiral

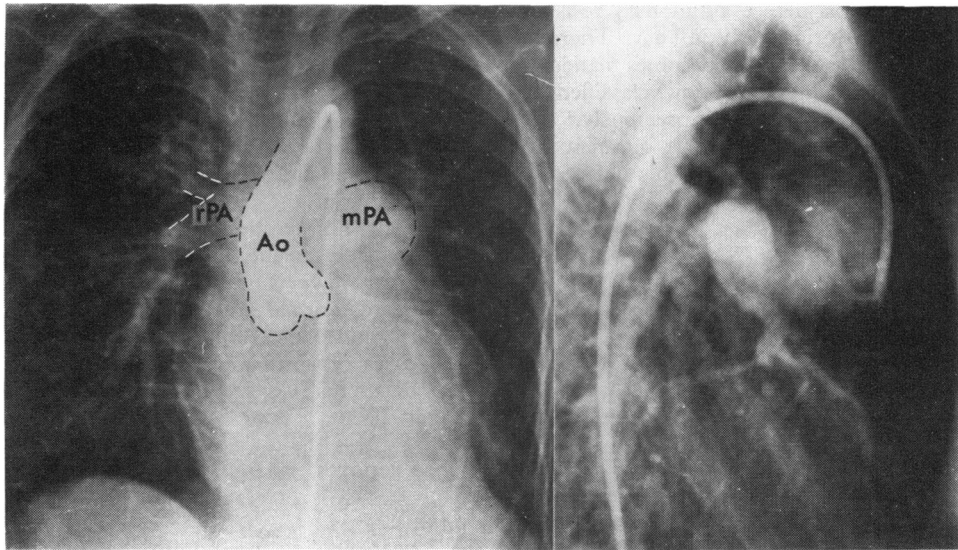


Fig. 2 Angiocardigram in case 1. Ao, aorta; mPa, main pulmonary artery; r-PA, right pulmonary artery.

T.N.

clearly seen even in plane 2 to plane 3 by two-dimensional echocardiography (Fig. 4).

CASE 2

A 3-year-old boy was referred to us with a diagnosis of left-to-right shunt and pulmonary hypertension. The electrocardiogram showed combined ventricular hypertrophy and a chest x-ray film showed mild cardiomegaly with pulmonary hypervascularity. Cardiac catheterisation showed pulmonary arterial pressure equivalent to systemic pressure. The angiogram, with right ventricular outflow tract and aortic root injections, is shown in Fig. 5 and 6. Contrast medium injected at the aortic root shows preferential opacification of the right pulmonary artery indicating a distal type of aorticopulmonary window.⁴ Contrast medium injected in the right ventricular outflow tract opacifies the main pulmonary artery, both pulmonary arteries, and the descending aorta. The data from

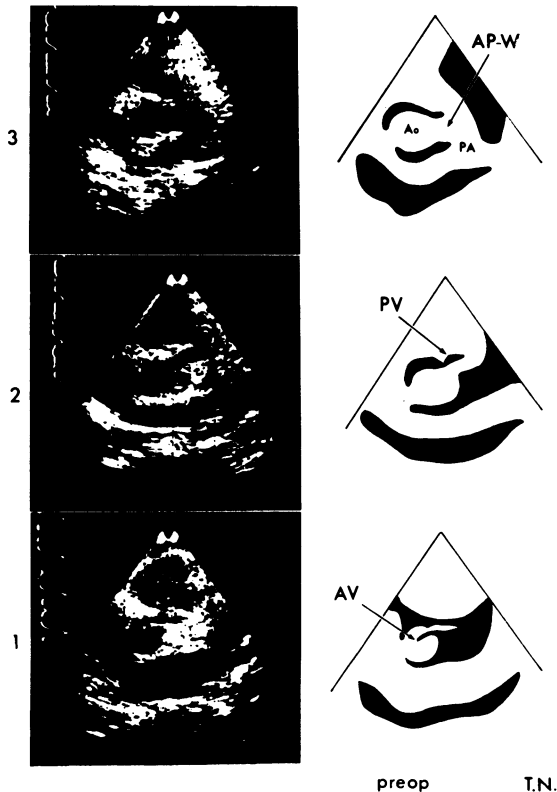


Fig. 3 Preoperative two-dimensional echocardiogram in case 1. AV, aortic valve; PV, pulmonary valve; Ao, aorta; PA, pulmonary artery; AP-W, aorticopulmonary window.

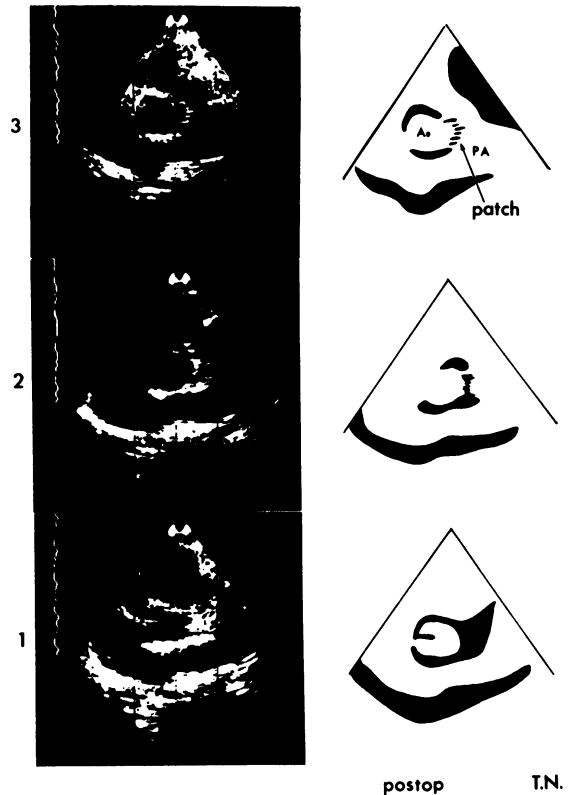


Fig. 4 Postoperative two-dimensional echocardiogram in case 1. Ao, aorta; PA, pulmonary artery; patch, patch echo.

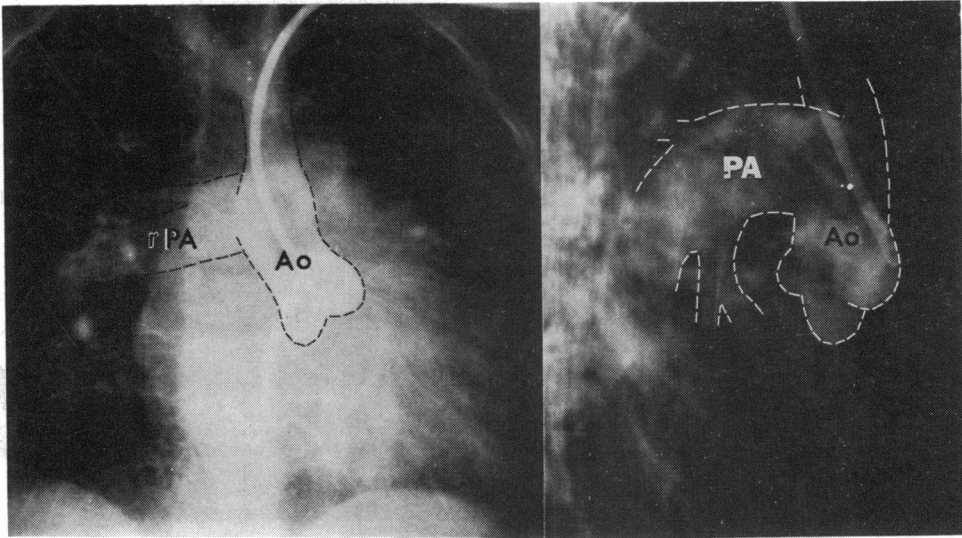
catheterisation and the angiograms, shown in Fig. 5 and 6, indicate a distal type of aorticopulmonary window with interruption of the aorta (type A). M-mode echocardiography showed no specific findings. Two-dimensional echocardiographic findings are shown in Fig. 7. The echo of the aorticopulmonary septum was absent at the levels of plane 2 and plane 3 preoperatively. During this examination, contrast echocardiography was performed. Glucose (1 ml of 5 per cent) was injected into the right antecubital vein while viewing plane 3 by two-dimensional echocardiography. The contrast medium entered the main pulmonary artery through the right ventricular outflow tract and entered the aorta via the aorticopulmonary septal defect in early systolic phase (Fig. 8). However, at the level of plane 1, no contrast was seen flowing from the right ventricular outflow tract to the ascending aorta. A patch closure of the aorticopulmonary window (measuring 1.5 cm in diameter) was carried

out successfully by transaortic approach; anastomosis of the aortic arch to the descending aorta was accomplished using an artificial graft. Postoperatively, two-dimensional echocardiography was performed again. No defect of the aorticopulmonary septum was seen at any level (Fig. 9). Two-dimensional echocardiography with contrast was also performed by peripheral vein injection. No

contrast echo was detected moving from the main pulmonary artery to the ascending aorta.

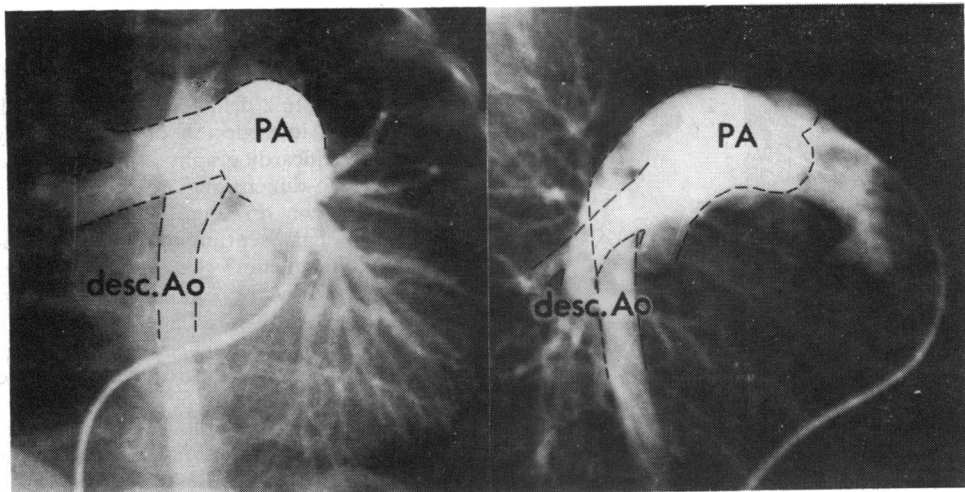
Discussion

A two-dimensional echocardiographic diagnostic approach using three differential planes is very useful for identifying the pulmonary artery and the



S.S.

Fig. 5 Angiocardiogram in case 2 with aortic root injection. Ao, aorta; r-PA, right pulmonary artery.



S.S.

Fig. 6 Angiocardiogram in case 2 with right ventricular outflow injection. PA, pulmonary artery; Ao, descending aorta.

aorta, and for recognising spatial relations between them.^{5 6} Aorticopulmonary septal defect was visualised by two-dimensional echocardiography at the level of plane 2 to plane 3 in both cases with distal type aorticopulmonary window.

A portion of the circular aortic echo which is

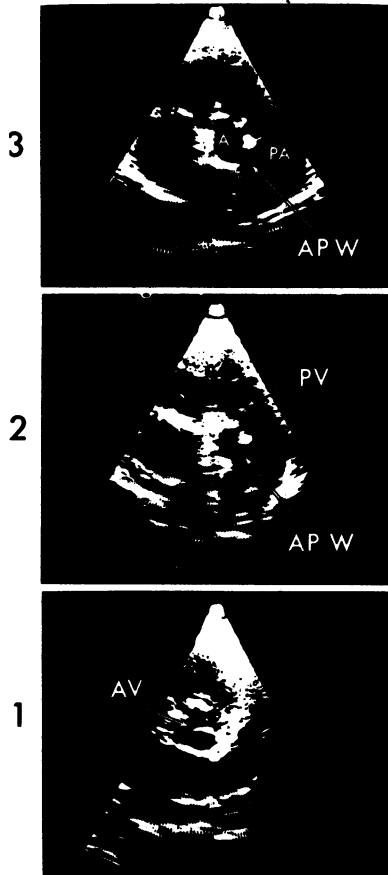


Fig. 7 Preoperative two-dimensional echocardiographic findings in case 2. AV, aortic valve; PV, pulmonary valve; AP-W, aorticopulmonary window.

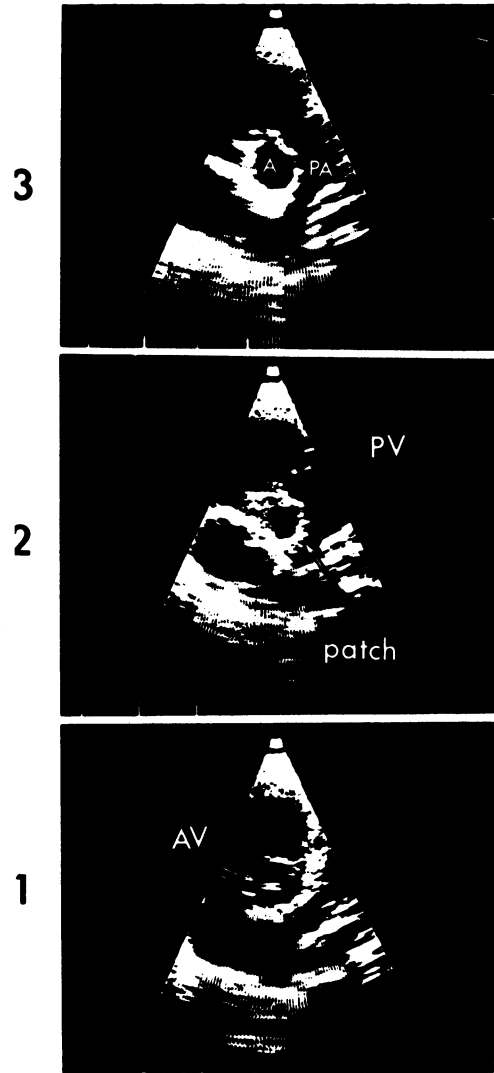


Fig. 9 Postoperative two-dimensional echocardiographic findings in case 2. AV, aortic valve; PV, pulmonary valve; Ao, aorta; PA, pulmonary artery; patch, patch echo.




Fig. 8 Preoperative contrast two-dimensional echocardiographic record in case 2 showing the contrast entering the aorta from the main pulmonary artery. Cont. echo, contrast echo; AP-W, aorticopulmonary window.

parallel to ultrasonic beams may appear as drop-out effect, even in normal subjects, especially on stop-action frames. However, use of real-time images alleviates these problems according to the human capability for integration,⁷ and no drop-out was observed in the normal subjects in plane 2 to plane 3 and real-time two-dimensional echocardiography. In the two cases reported here, relatively large echo defects of a portion of the aorticopulmonary septum were observed during the whole cardiac cycle even on real-time two-dimensional echocardiography. Other evidence of the defect is the passage of the contrast echo from the pulmonary artery to the ascending aorta. Two-dimensional contrast echocardiography was performed in one case. Contrast was noted passing through the aorticopulmonary septal defect at the level of plane 3; this phenomenon was missed at the level of plane 1. An aorticopulmonary window was found at the level of plane 2 to plane 3, and not at the level of plane 1. Accordingly, in a case with the proximal type of aorticopulmonary window, we expect to find the defect only at the level of plane 1 or slightly cephalad to it. When the defect is as described in the two cases reported here, it may be seen at the level of plane 2 to plane 3, and, in the combined proximal and distal type, two-dimensional echocardiographic study will probably show the defect in all planes. We hope to substantiate this speculation by further experience with such cases.

The operative approach, transpulmonary or trans-aortic, should be chosen according to the type of aorticopulmonary window.⁴ Therefore, accurate diagnosis and typing of this anomaly must be made

before operation. Two-dimensional echocardiography can be a very useful non-invasive diagnostic tool in aorticopulmonary window.

References

- ¹Collett RW, Edwards JE. Persistent truncus arteriosus: Classification according to anatomic types. *Surg Clin North Am* 1949; **29**: 1245-70.
- ²Baronofsky ID, Gordon AJ, Grishman A, Steinfeld L, KreeI I. Aorticopulmonary septal defect: diagnosis and report of case successfully treated. *Am J Cardiol* 1960; **5**: 273-6.
- ³Keith JD, Rowe RD, Vlad P. *Heart disease in infancy and childhood*. New York: Macmillan, 1967.
- ⁴Mori K, Ando M, Takao A, Ishikawa S, Imai Y. Distal type of aorticopulmonary window: report of four cases. *Br Heart J* 1978; **40**: 681-9.
- ⁵Satomi G, Shimizu K, Komatsu Y, Takao A. Echocardiographic identification of aorta and main pulmonary artery in complete transposition. *Br Heart J* 1979; **41**: 356.
- ⁶Satomi G, Shimizu K, Komatsu Y, Takao A. Two-dimensional echocardiographic diagnosis of congenital heart disease (segmental approach): part 1; spatial interrelationship between the great arteries (in Japanese with English summary). *J Cardiogr* 1978; **8**: 557-66.
- ⁷Roelandt J, van Dorp WG, Bom N. Pitfalls in echocardiography. In: Lundström NR, ed. *Echocardiography in congenital heart disease*. Amsterdam: Elsevier/North-Holland Biomedical Press, 1978: 67-82.

Requests for reprints to Dr Gengi Satomi, Department of Paediatric Cardiology, The Heart Institute Japan, 10 Kawada-cho, Shinjuku-ku, Tokyo 162, Japan.