

Primary myxomatous degeneration of cardiac valves

*Clinical, pathological, haemodynamic, and echocardiographic profile**

JAMES RIPPE, MICHAEL C FISHBEIN, BLASE CARABELLO,
GERALD ANGOFF, LAURENCE SLOSS, JOHN J COLLINS JR,
JOSEPH S ALPERT

*From the Cardiovascular Division, Pathology Department, Division of Thoracic and Cardiac Surgery,
Peter Bent Brigham Hospital, Boston, MA 02115, USA*

SUMMARY Four hundred and ninety-nine surgically excised valves were examined for pathological evidence of myxomatous degeneration. Thirty-six valves (7%) had myxomatous degeneration as a major pathological finding. Fourteen valves (3%) had significant myxomatous degeneration of the *pars fibrosa*, a finding which we define as "primary myxomatous degeneration". Echocardiographic findings and catheterisation results were correlated with the clinical course, surgical results, and follow-up in these 14 patients. Echocardiograms in 10 of the 11 patients who had them (91%) showed abnormalities suggesting the presence of primary myxomatous degeneration. Echocardiography was more helpful than angiography in diagnosis. The histological pattern of primary mitral myxomatous degeneration appears to be identical to that seen in patients with mitral valve prolapse and five of six patients with mitral lesions had echocardiographic evidence of prolapse. None of the patients with primary myxomatous degeneration of the aortic valve had syphilis or Marfan's syndrome. While the aetiology of primary myxomatous degeneration of cardiac valves is not known, a link to a more generalised disorder is suggested.

Myxomatous degeneration of cardiac valves has aroused considerable interest.¹⁻¹³ Evidence has accumulated to suggest that this is the predominant pathology in patients with mitral valve prolapse.¹⁴⁻¹⁹ Myxomatous degeneration has been found in patients with isolated mitral regurgitation,^{3 4 6} aortic regurgitation,¹ and combined mitral and aortic regurgitant lesions.^{1 2}

Much confusion surrounds the concept of myxomatous degeneration of cardiac valves. Some investigators maintain that it is the result of one specific disease process.⁴ Others characterise it as a non-specific tissue response to a variety of factors.¹ Myxomatous degeneration has been considered a normal ageing change, an associated finding in congenital heart disease,¹ a response to syphilitic aortitis, and the result of rheumatic heart disease.^{1 12 20}

Depending on the criteria used to define the entity and the population studied, the percentage of subjects with myxomatous degeneration of cardiac valves varies widely. If one accepts the view that this is the pathology causing mitral valve prolapse,^{14 16-19} as many as 6 per cent of healthy adults and 9 to 16 per cent of patients undergoing valve replacement in the United States may have it.^{1 2 5 12}

The clinical significance of myxomatous degeneration has been widely debated. Mitral valve prolapse has been linked to an increased incidence of arrhythmias,²¹⁻²⁴ a higher risk of subacute bacterial endocarditis,²⁵ and a greater chance of sudden death.^{26 27} Patients whose regurgitant lesions are the result of myxomatous degeneration have been retrospectively found to have endocardial friction lesions,²⁸ ruptured chordae tendineae,^{2 15 28} a higher incidence of bacterial endocarditis,² and an increased risk of intraoperative complications.^{2 3} The current study was undertaken to examine the clinical consequences of this pathological process.

*Presented in part at the 45th Annual Scientific Assembly of the American College of Chest Physicians, Houston, Texas, November 1979.

Received for publication 6 May 1980

Subjects and methods

(a) PATIENTS

Pathological data were reviewed from all patients who underwent replacement of one or more cardiac valves at the Peter Bent Brigham Hospital between 1 January 1974 and 1 June 1977. Of the 499 patients in this category, 36 had myxomatous degeneration of their cardiac valves as a major pathological finding (8%).

(b) PATHOLOGY

Histological sections and macroscopic appearances of the cardiac valves from these 36 patients were reviewed in detail by one of us (MCF) who had no knowledge of the clinical findings. In this study, primary myxomatous degeneration was defined as degeneration of collagen of the *pars fibrosa* of the valve with basophilic staining in this region caused by the deposition of acid mucopolysaccharides (proven by special histochemical techniques), in the absence of severe calcification or fibrosis, and no macroscopic evidence of rheumatic valvular disease (shortening, fusion, and thickening of the chordae tendineae of atrioventricular valves or commissural fusion of semilunar valves) (Fig. 1).

It is important to emphasize that the key pathological feature, the entity which we define as *primary* myxomatous degeneration, involves significant disruption of the *pars fibrosa*. While the amount of myxomatous material found in the *pars spongiosa* was also increased in our patients, this latter feature is a common pathological finding and may represent a non-specific response to ageing,¹² or to a diverse

number of underlying pathological conditions ranging from rheumatic valvular disease to Marfan's syndrome.¹⁰

Fourteen patients were found to have primary myxomatous valvular degeneration by the criteria outlined above. Seven of these had undergone mitral valve replacement, six aortic valve replacement, and one replacement of both mitral and aortic valves. Of the remaining 22 patients with myxomatous degeneration of their cardiac valves as a prominent finding, but without *primary* myxomatous degeneration, 11 had degeneration secondary to rheumatic heart disease, three had "presumed" papillary muscle dysfunction, two showed congenital malformations, one had calcific aortic stenosis, one had infective endocarditis, one had syphilitic aortitis, one had plasmacytic aortitis, and two were of uncertain cause.

(c) ECHOCARDIOGRAPHY

Echocardiograms were available on 11 of the 14 patients with primary myxomatous degeneration. These studies were recorded on Irex or Smith-Kilne ultrasound equipment interfaced with Irex strip chart recorders and 2.25 megaHertz transducers. Echocardiograms were obtained using standard techniques, with the mitral valve, tricuspid valve and aortic root imaged in the usual fashion.²⁹ Echocardiograms in these patients with severe mitral regurgitation were examined independently by three experienced echocardiographers who were unaware of both clinical information regarding the patients and the echocardiographic interpretations of their colleagues.

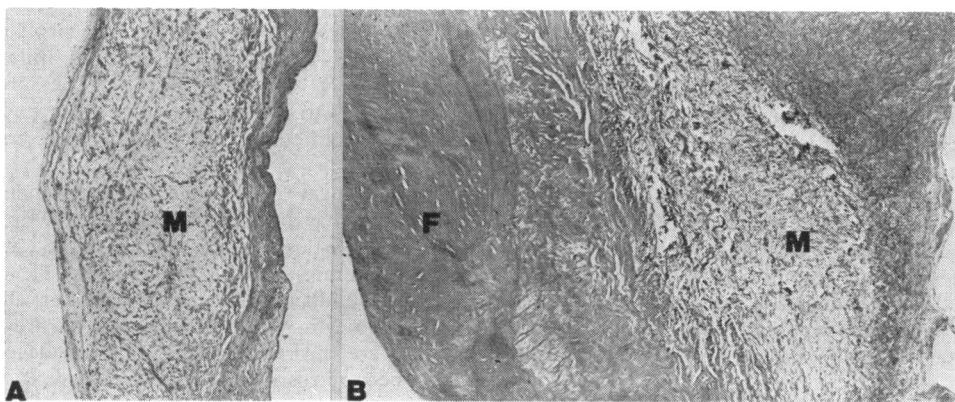


Fig. 1 (A) Primary myxomatous degeneration. The valve is thin with a distinct increase in myxomatous (M) tissue (H. and E. $\times 48$). (B) Secondary myxomatous degeneration from a patient with rheumatic mitral valvular disease. There is pronounced thickening of the valve leaflet caused mainly by an increase in fibrous (F) tissue. There is only a focal area of myxomatous (M) degeneration (H. and E. $\times 48$).

(d) CATHETERISATION

Cardiac catheterisation had been performed in 12 patients. Angiograms were available for nine patients, with both a left ventricular angiogram and an aortogram in six cases, a left ventricular angiogram alone in two cases, and an aortogram alone in one case. Haemodynamic data were analysed in these patients, and a scoring system was designed to characterise haemodynamic status as a function of left ventricular end-diastolic pressure, cardiac index, and estimated left ventricular wall motion. Ejection fraction could not be calculated in most instances because left ventricular images were too large to fit in their entirety on a cineangiogram frame. Mitral and aortic regurgitation were graded from the left ventricular angiograms and aortograms in nine patients and from written reports in three patients. Grading was from 0 to 4+ using standard angiographic criteria.³⁰

To study the angiographic presence of mitral valve prolapse in five patients with mitral regurgitation in whom angiograms were available, the end-systolic left ventricular angiographic frame from the right anterior oblique projection was traced onto paper, with special attention paid to the outline of the mitral valve. These tracings, together with similar tracings of nine normal subjects, were graded as to the degree of mitral valve prolapse by three experienced angiographers in ignorance of the clinical data. Tracings were used instead of the actual angiograms to eliminate possible bias introduced by the presence of mitral regurgitation.

Results

CLINICAL DATA

Clinical data for the 14 patients are summarised in Table 1. The sex incidence was equal. Ages ranged from 29 to 73 years. All had had congestive cardiac failure for periods ranging from six months to six years. Ten of the 14 patients had experienced either a sudden onset or a distinct exacerbation of symptoms within the 10 months before surgery. All patients had significant murmurs of mitral and/or aortic regurgitation. Systolic clicks, confirmed by phonocardiography, were noted in three instances. No patient had a Marfan habitus, ectopia lentis, or arachnodactyly. There was one probable case of infective endocarditis, though no organisms could be cultured from this patient's valve.

ECHOCARDIOGRAPHIC DATA

Echocardiographic data are summarised in Table 2. Echocardiograms were performed in six of the seven patients with mitral regurgitation, four of the six patients with aortic regurgitation, and in the patient with disease of both valves. Left ventricular volume overload patterns compatible with mitral regurgitation were noted in all six patients with the mitral valve lesion. Late systolic prolapse of the mitral valve, or bulging of the entire mitral valve apparatus toward the left atrium throughout systole was seen in five of these. Five, too (83%) also showed echoes diagnostic of ruptured chordae tendineae.³¹ Two of the six, reported elsewhere,³² had dilatation of the

Table 1 Clinical data: primary myxomatous degeneration

Case no.	Sex	Historical data			Physical examination			Laboratory data	Follow-up	
		Age (y)	Congestive heart failure	Chest pain	Palpitation	Subacute bacterial endocarditis	Clicks	Murmurs		Electrocardiogram
<i>Mitral valve disease</i>										
1	F	64	+	+	—	—	—	MR	1° AV block	Doing well 30 mth postop
2	M	62	+	—	+	—	+	MR	AF, AMI	Died 48 h postop
3	M	46	+	—	+	—	—	MR	LVH, RVH	Doing well 35 mth postop
4	F	70	+	+	+	—	+	MR	1° AV block	Doing well 36 mth postop
5	M	52	+	+	+	—	—	MR	AF, LVH	Doing well 30 mth postop
6	M	55	+	+	—	—	—	MR, AR	A fl, LVH, RVH	Died 24 h postop
7	M	57	+	+	—	—	—	MR	AF, LVH	Doing well 26 mth postop
<i>Aortic valve disease</i>										
8	F	29	+	—	—	+	—	SEM, AR	LAE, LVH	Doing well 36 mth postop
9	F	73	+	—	—	—	—	AR, MR	Non-specific ST and T wave changes	Died 72 h postop
10	F	59	+	+	—	—	—	SEM, AR	LVH	Doing well 26 mth postop
11	M	35	+	—	—	—	—	SEM, AR	LVH	Doing well 36 mth postop
12	F	65	+	—	—	—	—	SEM, AR	LVH	Doing well 34 mth postop
13	F	55	+	+	+	—	+	SEM, AR	LVH	Doing well 24 mth postop
<i>Aortic and mitral valve disease</i>										
14	M	50	+	—	—	—	—	AR, MR	LAE, LVH	Doing well 36 mth postop

Abbreviations: AF, atrial fibrillation; AMI, anterior myocardial infarction; AR, aortic regurgitation; LAE, left atrial enlargement; LVH, left ventricular hypertrophy; MR, mitral regurgitation; A fl, atrial flutter; RVH, right ventricular hypertrophy; SEM, systolic ejection murmur.

aortic root and tricuspid valve prolapse in addition to mitral valve prolapse (Fig. 2). Three of the four patients with aortic valve myxomatous degeneration who had echocardiograms showed significant dilatation of the aortic root. In these three the aortic valve itself appeared normal though excursion was small in relation to the aortic root (Fig. 3). Additional abnormal aortic echoes were present in two of these patients, possibly representing leaflet redundancy, but though mitral valve prolapse was not documented in any of them, tricuspid valve prolapse was seen in one patient. Echocardiography in the patient with disease of both valves showed only left ventricular volume overload and mitral valve fluttering secondary to aortic regurgitation.

about individual tracings (Fig. 4). In the five patients with aortic valve disease who had angiograms, dilated aortic root was shown in one patient, a dilated ascending aorta in another, and a type III dissecting aneurysm in a third.

SURGICAL RESULTS

Surgical findings and complications are summarised in Table 3. Mitral valve replacement was performed in all seven patients with mitral valve disease. Ruptured chordae tendineae were confirmed in five instances, and a dilated mitral valve annulus was found in five patients. A "floppy" appearance of the mitral valve was noted in three patients.

In four of the six patients with aortic valve disease,

Table 2 *Echocardiographic data: primary myxomatous degeneration*

Case no.	Aortic root (cm/m ²) [nl < 2.2 cm]	Aortic valve excursion (cm)	Left atrium (cm/m ²) [nl < 2.1 cm/m ²]	Right ventricular diameter (cm/m ²) [nl < 1.1 cm/m ²]	Mitral valve excursion (mm) [nl = 20-35 mm]	Interventricular septum thickness (mm) [nl = 9-11 mm]	Left ventricular post wall thickness (mm) [nl = 9-11 mm]	Left ventricle D _a (cm) ²	Left ventricle D _s (cm) ²	Tricuspid valve excursion
<i>Mitral valve disease</i>										
1	2.1		3.1		25	13	13	4.7	2.2	
2	1.8	1.9	3.6	2.2	35	10	12	6.8	4.6	Prolapse
4	1.8	1.7	4.0		38	9	10	7.0	4.8	Normal
5	1.9	2.0	3.7	1.3	28	9	9	7.1	6.0	Normal
6	2.3	1.8	3.2	0.9	30	10	11	8.5	5.9	Normal
7	2.1	2.3	2.9	1.5	33	12	11	5.9	3.0	Prolapse
<i>Aortic valve disease</i>										
8	1.9	2.1	2.2	0.9	12	9	11	5.5	3.4	Normal
11	2.5		2.6	6.0	24	10	12	8.2	6.2	Normal
12	2.5	1.3	2.0	7.0	12	12	11	6.8	4.2	Normal
13	2.7	1.6	2.4	1.0	22	10	8	6.5	4.5	Normal
<i>Aortic and mitral valve disease</i>										
14		3.6					10	6.8	3.9	

Abbreviations: D_a, diastolic diameter, D_s, systolic diameter.
Note: No echocardiogram was done in cases 3, 9, and 10.

CATHETERISATION DATA

Cardiac catheterisation was performed in six of the seven patients with primary myxomatous degeneration of the mitral valve and in five of the six patients with degeneration of the aortic valve. Significant angiographic valvular regurgitation was shown in all of these patients. Left ventricular function varied considerably, with no discernible pattern; in two patients it was good, in five modestly depressed, and in four severely compromised. Angiograms from five of the six patients with mitral valve disease were available for study of mitral valve prolapse by our three observers using tracings of the valve. Prolapse was judged to be present in only five of 15 possible observations (33%), but in no instance was there unanimous agreement among the observers

valve replacement alone was performed, while in two patients repair of an aortic aneurysm was also carried out. Several types of macroscopic valvular pathology were noted. Three patients had thin aortic leaflets and one patient had evidence of cusp destruction consistent with infective endocarditis.

Serious operative complications occurred in three patients: two experienced hypotension unresponsive to pressors and balloon counterpulsation (both dying within 48 hours of surgery), a third suffered a cerebrovascular accident of the right hemisphere, and haemostasis could not be achieved in a fourth who died 72 hours after operation.

PATHOLOGICAL FINDINGS

All excised valves fulfilled the criteria for primary

myxomatous degeneration described above. On macroscopic examination, no valve showed commissural fusion. One mitral valve had focal chordal fusion, but the diffuse chordal abnormalities characteristic of rheumatic valvular disease³³ were not present. Superimposed infective endocarditis was seen in one aortic valve. On microscopical examination, all valves showed prominent and uniform myxomatous degeneration of the *pars fibrosa* (Fig. 1). Some degree of fibrosis without calcification was present in all valves.

FOLLOW-UP

Patients surviving operation have done well post-operatively (see Table 1). Follow-up periods have

valvular architecture accompanied by an increase in ground substance with no appreciable inflammatory reaction⁷. Biochemical studies have shown that the abnormally increased ground substance in myxomatous degeneration is an acid mucopolysaccharide.^{7 34}

Numerous conditions including ageing,¹⁰ rheumatic heart disease,¹ and Marfan's syndrome,³⁵ have been associated with some degree of valvular myxomatous degeneration. As reported in the present study, primary myxomatous degeneration can be distinguished from these entities by histological criteria. The reported histological findings in the few valves excised from patients with mitral valve prolapse^{14 18 19} appear to be identical to those of our patients with primary myxomatous degeneration.

Early investigations of myxomatous degeneration of the aortic valve linked this pathological entity to more generalised connective tissue disorders and suggested that it might be an arrested form of Marfan's syndrome.⁴ Several subsequent studies failed to corroborate this^{1 2} and none of our patients had features of Marfan's syndrome. The condition is said to be commoner in men, but five of our six patients were women.

The other underlying conditions in secondary as well as in primary myxomatous degeneration which are possible causes of myxomatous degeneration were not found in our study.¹⁰ Our data support the observations of Pomerance¹⁰ and Roberts and Virmani³³ that primary myxomatous degeneration can be distinguished from that secondary to rheumatic heart disease. No patient had positive serology for syphilis, and none had congenital abnormalities. The average age of our patients was relatively low (55 years). Nevertheless, while no specific underlying aetiology was found, the presence of tricuspid and aortic valve prolapse in addition to mitral valve prolapse in two of our patients (14%) and the presence of aortic aneurysms or aortic annular dilatation in three patients (21%) raise the possibility of a more generalised disorder.

ranged from 24 to 36 months (mean=31.7) with all patients free from major complications or symptoms of congestive cardiac failure.

Discussion

PATHOLOGY OF MYXOMATOUS DEGENERATION

Considerable confusion surrounds the concept of myxomatous degeneration of cardiac valves and its relation to various disease states, in part arising from failure adequately to define myxomatous degeneration. General agreement exists on the histological pattern described by Sherman *et al.*⁶ that "Myxomatous transformation is pathologically characterised by disruption and loss of normal

INCIDENCE AND CLINICAL RELEVANCE OF PRIMARY MYXOMATOUS DEGENERATION

Previous studies have offered very different estimates of the incidence of myxomatous degeneration of cardiac valves.^{1 2 30} These differences may be in part the result of the problems of definition already mentioned. A small degree of myxomatous degeneration is probably present in most cardiac valves, and may represent a non-specific change on ageing²⁰ or a response to normal haemodynamic stress.¹² If the criteria outlined above for the diagnosis of primary myxomatous degeneration are

Comments

Typical ruptured chordae tendineae
 Typical ruptured chordae tendineae; dilated aortic root; mitral valve prolapse throughout systole; tricuspid valve prolapse
 Typical ruptured chordae tendineae; mitral valve prolapse
 Mitral valve prolapse throughout systole; left ventricular dysfunction (PEP/ET=0.87)
 Typical ruptured chordae tendineae; mitral valve prolapse throughout systole
 Typical ruptured chordae tendineae; aortic root dilatation; mitral valve prolapse; tricuspid valve prolapse
 Diastolic aortic valve gap; tricuspid valve prolapse
 Aortic root enlarged
 Aortic root enlarged
 Aortic root enlarged

Mitral valve flutter secondary to aortic regurgitation

insisted upon, the incidence appears quite low—in our study 3 per cent (14/499).

The relation between primary myxomatous degeneration and mitral valve prolapse remains a significant and largely unanswered question. Interestingly, five of our six patients with primary myxomatous degeneration of the mitral valve had preoperative echocardiographic evidence of mitral valve prolapse. Whether the converse is always true is uncertain.

It has been argued that patients with primary valvular myxomatous degeneration show rapid

clinical deterioration once symptoms appear, have more complications at operation, and do less well after it than patients who have valvular regurgitation of other kinds.^{2,3} Preoperative catheterisation studies in our patients showed a wide range of ventricular function and symptoms that had been present for anything from months to years. The rapidity of clinical deterioration is difficult to assess, since many of our patients were referrals from other institutions, but it is our impression that this was no greater in general than expected. Most of our patients with mitral regurgitation had experienced

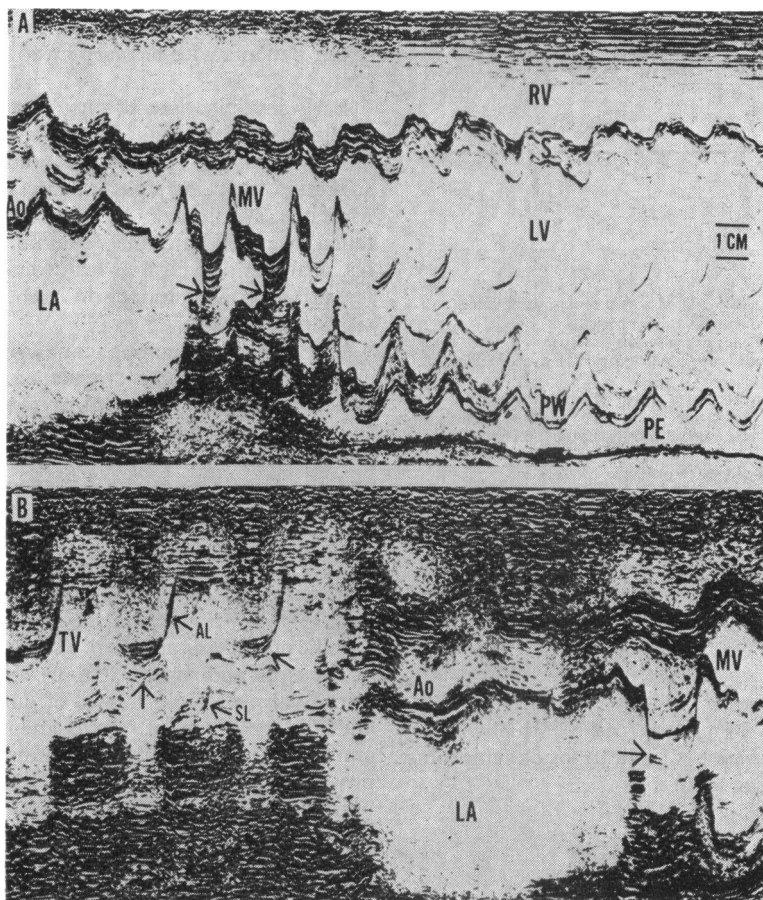


Fig. 2 Patient with primary myxomatous degeneration of the mitral valve, mitral and tricuspid valve prolapse, and dilatation of the aortic root (case 2). (A) Echocardiographic "sweep" of the left ventricle from the base toward the apex. The mitral valve (MV) shows pronounced systolic prolapse (unlabelled arrows) and hypermobility of the prolapsing valve components. The left atrium (LA) is much enlarged as is the left ventricle (LV) and right ventricle (RV). There is a pericardial effusion (PE) seen posteriorly. PW, posterior wall; S, septum; Ao, aortic root. (B) Echocardiographic sweep (continuous recording) from the tricuspid valve (TV) through the aortic root (Ao) to the mitral valve (MV). There is an increased excursion of the anterior (AL) and septal leaflets (SL) as well as systolic prolapse of both anterior and septal leaflets. A hypermobile portion of the mitral valve (unlabelled arrow) is also seen prolapsing back towards the left atrium (LA) as in (A).

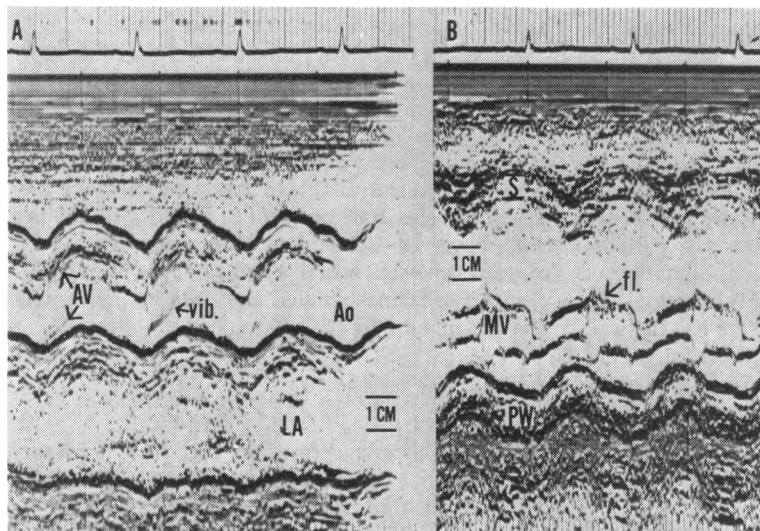


Fig. 3 Patient with primary myxomatous degeneration of the aortic valve. (A) Echocardiogram of the aortic root (Ao), aortic valve (AV), and left atrium (LA). There is prominent high frequency vibration (vib) of the aortic leaflets. (B) Echocardiogram of the mitral valve and base of the left ventricle. The mitral valve (MV) shows diastolic fluttering (fl.) of aortic regurgitation. PW, posterior wall; S, septum.

an acute onset of symptoms, a finding consistent with the high incidence of ruptured chordae tendineae in them.

Complications at operation are difficult to assess. In one of our 14 patients (7%) bleeding was hard to control, a non-specific finding. There were no instances of dissection at clamp sites or of valvular dehiscence, problems previously reported in patients with primary valvular myxomatous degeneration.² Prognosis remains in question. At first glance, the perioperative mortality rate of 21 per cent (three deaths in 14 patients) in our patients appears alarmingly high, particularly as the current mor-

tality rate for valvular replacement at our hospital is less than 5 per cent, but two of the patients who died had severely compromised ventricular function before operation and the third patient had a dissecting aortic aneurysm. Follow-up in the 11 remaining patients for periods ranging from 24 to 36 months suggests a generally favourable course.

PREDICTIVE VALUE OF ECHOCARDIOGRAPHY AND ANGIOGRAPHY IN PRIMARY MYXOMATOUS DEGENERATION

In previous studies of primary myxomatous

Table 3 Surgical data: severe myxomatous degeneration

Case no.	Procedure	Operative findings	Complications
<i>Mitral valve disease</i>			
1	MVR 31 mm porcine	RCT ant. leaflet MV	R hemisphere CVA
2	MVR 35 mm porcine	RCT; "floppy" MV; dilated MV annulus; pericardial adhesions	Hypotension, ? bleeding; died 48 hours postop
3	MVR 33 mm porcine	"Floppy" MV; RCT anterior leaflet MV	None
4	MVR large ball valve	"Floppy" MV; 3 RCT post leaflet MV; dilated MV annulus	Hypotension responsive to pressors
5	MVR 35 mm porcine	Very dilated MV annulus	None
6	MVR 35 mm porcine	RCT; massively dilated MV annulus	Hypotension; died 24 hours postop
<i>Aortic valve disease</i>			
8	AVR	Severe destruction of AV caused by SBE	None
9	AVR; replace ascending aorta	"Floppy" AV; aneurysm of ascending and descending aorta	Intraoperative oozing; died 72 hours postop; LV rupture
10	AVR 23 mm porcine	"Floppy" AV	None
11	AVR 27 mm porcine	AV leaflets heavily rolled with central orifice	None
12	AVR 23 mm porcine; replace ascending aorta	Aneurysm of ascending aorta; stretched aortic annulus	None
13	AVR 21 Björk-Shiley	"Floppy" AV	None
14	AVR	"Floppy" AV; dilated ascending aorta	None
<i>Aortic and mitral valve disease</i>			
15	AVR 27 mm porcine MVR 33 mm porcine	"Floppy" AV and MV	None

Abbreviations: AV, aortic valve; AVR, aortic valve replacement; CVA, cerebrovascular accident; MV, mitral valve; MVR, mitral valve replacement; RCT, ruptured chordae tendineae, SBE, subacute bacterial endocarditis.

degeneration, no echocardiographic data have been reported.

Eleven of our patients had echocardiograms and in 10 of them the diagnosis of primary myxomatous degeneration was suggested by this examination. Echocardiograms were particularly helpful in degeneration of the mitral valve where prolapse and/or a pattern suggesting ruptured chordae tendineae were shown in all patients. In patients with degeneration of the aortic valve, dilatation of the aortic root was a common, helpful finding.

In contrast, catheterisation data were less helpful. While regurgitant lesions were shown in all 13 patients, no specific haemodynamic or angiographic pattern emerged for patients with mitral regurgitation, though three of those with aortic regurgitation

had an aneurysm or root dilatation.

For years, the relative merits of echocardiography versus angiography in documenting mitral valve prolapse have been debated.³⁶⁻⁴⁰ In our patients, all with pathologically proven primary myxomatous degeneration, a pure form of the pathology thought to underly mitral valve prolapse, echocardiography was diagnostic in 83 per cent of cases, with 100 per cent observer agreement, but angiography, in contrast, showed mitral valve prolapse in only 33 per cent of frames studied and observer agreement was not unanimous.

Conclusion

Using the criteria defined in this study, primary myxomatous degeneration was an infrequent pathological finding in 499 valves replaced for aortic or mitral regurgitation, occurring in approximately 3 per cent. It can usually be distinguished pathologically from rheumatic and other forms of valvular disease. Its aetiology is unknown. Previous suggestions that it may be secondary to syphilitic aortitis, congenital heart disease, or Marfan's syndrome were not confirmed, but the presence of other cardiac abnormalities in a high percentage of the patients suggests that it may be part of some more generalised disorder. The pathological findings of primary myxomatous degeneration are identical to those seen in patients with clinical mitral valve prolapse. Valve replacement may carry a higher than normal mortality (21% of our patients died) though the small number of patients and the presence of other clinical complications make this uncertain. Nevertheless, the possibility, which previous reports have also suggested underlines the importance of making the diagnosis preoperatively. Echocardiography appears to be more useful than angiography in diagnosis.

ANGIOGRAPHIC SILHOUETTES OF THE MITRAL VALVE




Fig. 4 Angiographic silhouettes of the mitral valve. Tracings were taken from the end-systolic left ventricular angiographic frame in the RAO projection. Tracings from the five patients with myxomatous degeneration of the mitral valve who had cardiac catheterisation are on the left. Tracings of five normal controls used for comparison are on the right.

References

- 1 Frable WJ. Mucinous degeneration of the cardiac valves—the “floppy valve” syndrome. *J Thorac Cardiovasc Surg* 1969; **58**: 62-70.
- 2 McKay R, Yacoub MH. Clinical and pathological findings in patients with “floppy” valves treated surgically. *Circulation* 1973; **47**, suppl 3: 63-73.
- 3 Salomon NW, Stinson EB, Griep RB, Shumway NB. Surgical treatment of degenerative mitral regurgitation. *Am J Cardiol* 1976; **38**: 463-8.
- 4 Read RC, Thal AP, Wendt VE. Symptomatic valvular myxomatous transformation (the floppy valve syndrome): a possible forme fruste of the Marfan syndrome. *Circulation* 1965; **32**: 897-910.

- 5 Roberts WC, Perloff JK. Mitral valvular disease. A clinicopathologic survey of the conditions causing the mitral valve to function abnormally. *Ann Intern Med* 1972; **77**: 939-75.
- 6 Sherman EB, Char F, Dungan WT, Campbell GS. Myxomatous transformation of the mitral valve producing mitral insufficiency. *Am J Dis Child* 1970; **119**: 171-5.
- 7 McCarthy LJ, Wolf PL. Mucoïd degeneration of heart valves: "blue valve syndrome". *Am J Clin Pathol* 1970; **54**: 852-6.
- 8 Pomerance A. Ballooning deformity (mucoïd degeneration) of atrioventricular valves. *Br Heart J* 1969; **31**: 343-51.
- 9 Jamshidi A, Klein-Robbenhaar J. Myxomatous transformation of the aortic and mitral valve with subaortic "sail-like" membrane. *Am J Med* 1970; **49**: 114-7.
- 10 Pomerance A. Aging and degenerative changes. In: Pomerance A, Davies MJ, eds. *The pathology of the heart*. London: Blackwell Scientific Publication, 1975: 47-9.
- 11 Davis RH, Schuster B, Knoebel SB, Fisch C. Myxomatous degeneration of the mitral valve. *Am J Cardiol* 1971; **28**: 449-55.
- 12 Kern WH, Tucker BL. Myxoid changes in cardiac valves: pathological, clinical and ultrastructural studies. *Am Heart J* 1972; **84**: 294-301.
- 13 O'Brien KP, Hitchcock GC, Barratt-Boyes BG, Lowe JB. Spontaneous aortic cusp rupture associated with valvular myxomatous transformation. *Circulation* 1968; **37**: 273-8.
- 14 Bittar N, Sosa JA. The billowing mitral valve leaflet. Report on fourteen patients. *Circulation* 1968; **38**: 763-70.
- 15 Goodman D, Kimbiris D, Linhart JW. Chordae tendineae rupture complicating the systolic click-late systolic murmur syndrome. *Am J Cardiol* 1974; **33**: 681-4.
- 16 Jeresaty RM. Mitral valve prolapse-click syndrome. *Prog Cardiovasc Dis* 1973; **15**: 623-52.
- 17 Shrivastava S, Guthrie RB, Edwards JE. Prolapse of the mitral valve. *Mod Concepts Cardiovasc Dis* 1977; **46**: 57-61.
- 18 Marshall CE, Shappell SD. Sudden death and the ballooning posterior leaflet syndrome. Detailed anatomic and histochemical investigation. *Arch Pathol* 1974; **98**: 134-8.
- 19 Trent JK, Adelman AG, Wigle ED, Silver MD. Morphology of a prolapsed posterior mitral valve leaflet. *Am Heart J* 1970; **79**: 539-43.
- 20 Pomerance A. Aging changes in human heart valves. *Br Heart J* 1967; **29**: 222-31.
- 21 Procacci PM, Savran SV, Schreiter SI, et al. Prevalence of clinical mitral valve prolapse in 1169 young women. *N Engl J Med* 1976; **294**: 1086-8.
- 22 DeMaria AN, Amsterdam EA, Vismara LA, Neumann A, Mason DT. Arrhythmias in the mitral valve prolapse syndrome: prevalence, nature and frequency. *Ann Intern Med* 1976; **84**: 656-60.
- 23 Gooch AS, Vicencio F, Maranhao V, Goldberg N. Arrhythmias and left ventricular asynergy in the prolapsing mitral leaflet syndrome. *Am J Cardiol* 1972; **29**: 611-20.
- 24 Swartz MH, Teicholz LE, Donoso E. Mitral valve prolapse: a review of associated arrhythmias. *Am J Med* 1977; **62**: 377-89.
- 25 Corrigan D, Bolen J, Hancock EW, Popp RL. Mitral valve prolapse and infective endocarditis. *Am J Med* 1977; **63**: 215-22.
- 26 Leichtman D, Nelson R, Gobel FL, Alexander CS, Cohn JN. Bradycardia with mitral valve prolapse: a potential mechanism of sudden death. *Ann Intern Med* 1976; **85**: 453-7.
- 27 Devereaux RB, Perloff JK, Reichel N, Josephson ME. Mitral valve prolapse. *Circulation* 1976; **54**: 3-14.
- 28 Salazar AE, Edwards JE. Friction lesions of ventricular endocardium: relation to chordae tendineae of mitral valve. *Arch Pathol* 1970; **90**: 364-376.
- 29 Feigenbaum H. *Echocardiography*. 2nd ed. Philadelphia: Lea and Feibinger, 1976.
- 30 Grossman W. *Cardiac catheterization and angiography*. Philadelphia: Lea and Feibinger, 1974.
- 31 Humphries WC Jr, Hammer WJ, Lemole G, McDonough MT, McCurdy RR, Spana JF Jr. Echocardiographic equivalents of a flail mitral leaflet. *Am J Cardiol* 1977; **40**: 802-7.
- 32 Rippe JM, Angoff G, Sloss LJ, Wynne J, Alpert IS. Multiple floppy valves: an echocardiographic syndrome. *Am J Med* 1979; **66**: 817-24.
- 33 Roberts WC, Virmani R. Aschoff bodies at necroscopy in valvular heart disease: evidence from an analysis of 543 patients over 14 years of age that rheumatic heart disease, at least anatomically, is a disease of the mitral valve. *Circulation* 1978; **57**: 803-7.
- 34 Torii S, Bashey RI, Nakao K. Acid mucopolysaccharide composition of human heart valve. *Biochim Biophys Acta* 1965; **101**: 285-91.
- 35 McKusick VA. *Heritable disorders of connective tissue*. 3rd ed. St. Louis: CV Mosby, 1966.
- 36 Dillon JC, Haine CL, Change S, Feigenbaum H. Use of echocardiography in patients with prolapsed mitral valve. *Circulation* 1971; **43**: 503-7.
- 37 Smith ER, Fraser DB, Purdy JW, Anderson RN. Angiographic diagnosis of mitral valve prolapse: correlation with echocardiography. *Am J Cardiol* 1977; **40**: 165-70.
- 38 DeMaria AN, Neumann A, Lee G, Mason DT. Echocardiographic identification of the mitral valve prolapse syndrome. *Am J Med* 1974; **62**: 819-29.
- 39 Popp RL, Brown OR, Silverman JF, Harrison DC. Echocardiographic abnormalities in the mitral valve prolapse syndrome. *Circulation* 1974; **49**: 428-33.
- 40 DeMaria AN, King JF, Bogren HG, Lies JE, Mason DT. The variable spectrum of echocardiographic manifestations of the mitral valve prolapse syndrome. *Circulation* 1974; **50**: 33-41.

Requests for reprints to Dr Joseph S Alpert, Division of Cardiovascular Medicine, University of Massachusetts Medical Center, 55 Lake Avenue, North, Worcester, Massachusetts 01605, USA.