

British Heart Journal, 1976, **38**, 327–340.

Sequential chamber localization—*logical approach to diagnosis in congenital heart disease*

Elliot A. Shinebourne, Fergus J. Macartney, and Robert H. Anderson¹

From the Department of Paediatrics, Cardiothoracic Institute, Brompton Hospital, London, and the Thoracic Unit, Hospital for Sick Children, Great Ormond Street, London

A nomenclature is described for congenital heart disease employing sequential chamber localization. It is an eclectic system based in part upon the previous classifications of Van Praagh and Kirklin. It links together the atrial, ventricular, and arterial segments of the heart and then permits tabulation of associated anomalies. The atrial segment of the heart can exist as situs solitus, situs inversus, or situs ambiguus. Atrioventricular connexions can be concordant or discordant. In certain circumstances the terms concordant and discordant cannot be used. These are in the presence of primitive ventricle and in the presence of situs ambiguus. Alternative terms are described for these contingencies. Ventriculo-arterial connexions can be (a) normal; (b) transposition; (c) double outlet ventricle; or (d) single arterial trunk. These are defined as connexions; relations are relegated to secondary position. Associated anomalies are categorized in terms of venous return, atria, atrioventricular junction, ventricles, and great arteries. Controversial topics are discussed with regard to previous definitions.

For a nomenclature to be of value in modern paediatric cardiology, it must be capable of describing any combination of cardiac malformations which may be encountered. Furthermore, it should, as far as is possible, allow for the precise classification of such malformations to be made during a patient's life. At the present time, it is usual to define given cardiac malformations as discrete entities, as exemplified by the terminologies agreed upon by the International Society of Cardiology (1970) and the New York Heart Association (1973). However, complex cardiac malformations are being reported with increasing frequency which do not lend themselves to categorization within these rigid classifications. It is our belief that in order to describe such hearts adequately it is necessary to adopt a concept of nomenclature based upon sequential chamber localization. Such an approach has been formulated by Van Praagh and his colleagues (Van Praagh, Ongley, and Swan, 1964a;

Van Praagh *et al.*, 1964b; Van Praagh and Van Praagh, 1966; Van Praagh, 1968; Van Praagh *et al.*, 1971; Van Praagh, 1972, 1973). During the evolution of these concepts, Van Praagh has found it necessary to effect radical alterations in certain definitions. In the case of 'transposition', the new definition of Van Praagh *et al.* (1971) provoked considerable controversy (Van Mierop, 1971). However, the new definition was essential since the segmental approach is concerned with descriptions of *connexions*. Because the *same* connexions can exist with considerable variation in spatial *relationships* it has become necessary to relegate relations to a secondary role. This philosophy is exemplified by Kirklin's modification of the segmental approach (Kirklin *et al.*, 1973). We are convinced that this emphasis on connexions is fully justified, and that it aids the understanding of many complex anomalies (Anderson, Shinebourne, and Gerlis, 1974a). This review, therefore, will outline our eclectic nomenclature based upon identification of segmental connexions.

¹R.H.A. is a British Heart Foundation Senior Research Fellow.

A: Basis of segmental nomenclature

As the term sequential chamber localization implies, the system is based upon identification of the positions of the different segments of the heart (Table 1), and the nomenclature to be described

TABLE 1 Table indicating possibilities for description of three segments of heart

| Segment | Possibilities |
|----------------|---|
| Atria | Solitus Inversus Ambiguus |
| Ventricles | Concordant Discordant Primitive ventricle 'd' or 'l' (with situs ambiguus) Normally connected |
| Great arteries | Transposed Double outlet ventricle Single arterial trunk |

enables the segments to be 'linked' together. The individual segments considered for the purposes of connexions are the atrial chambers, the ventricular chambers, and the great arteries together with their supporting conus. A full range of anomalies can then be enumerated within this framework by cataloguing in turn anomalies of venous return, deformations of the atria, abnormalities of the atrioventricular junction, malformations of the ventricles, and anomalies of the great arteries (Table 2).

TABLE 2 Examples of anomalies which may occur in the various portions of the heart*

| Region | Examples of anomalies |
|---------------------------------|--|
| Venous return | Anomalous systemic return Anomalous pulmonary return |
| Atrial chambers | Atrial septal defect Cor triatriatum |
| Atrioventricular junction | Atrioventricular canal AV valve atresia |
| Ventricular chambers | Ventricular septal defect Anomalous muscle bundle |
| Great arteries and cono-truncus | Conal septal defect Coarctation Persistent ductus arteriosus |

*This is not meant to be an exhaustive catalogue but only gives typical examples.

B: Chamber localization

In order to connect the chambers together, it is firstly necessary to consider how the different cardiac chambers can be recognized. In our opinion

such differentiation must be based upon morphological characteristics as follows:

(1) Morphological right atrium (Fig. 1a)

In the normal heart this chamber receives the systemic venous return. The superior vena cava, inferior vena cava, and coronary sinus enter the smooth walled sinus venarum, which is separated from the trabeculated right auricle by the prominent crista terminalis. The auricular appendage is typically blunt ending. On its septal surface the right atrium exhibits the limbus of the fossa ovalis. Remnants of the embryonic venous valves, the Eustachian and Thebesian valves, commonly guard the entrances to the inferior caval vein and the coronary sinus.

(2) Morphological left atrium (Fig. 1b)

This chamber in the normal heart receives the pulmonary venous return through four pulmonary veins. These veins enter a smooth walled segment which is not separated from the trabeculated auricle by a crista. On its septal aspect, the left atrium presents the flap valve of the septum primum. A characteristic feature of the left atrium is its 'finger-shaped' auricular appendage.

(3) Morphological right ventricle (Fig. 2a)

In the normal heart this ventricle always possesses an infundibulum and contains the tricuspid valve. Though the cusp pattern of the tricuspid valve is variable, its papillary muscle pattern of a single anterior muscle, multiple posterior muscles, and a conal muscle, is typical. The tricuspid valve is separated from the pulmonary valve by the crista supraventricularis while a prominent trabecula septomarginalis is present on the septal surface. The trabeculations of the right ventricle are coarse.

(4) Morphological left ventricle (Fig. 2b)

This ventricle contains the easily recognizable bicuspid mitral valve with its paired papillary muscles. The mitral valve is in fibrous continuity with the aortic valve, consequently there is no infundibulum. The trabeculations of the left ventricle are fine.

C: Plan for sequential analysis

The order of procedures is first to establish atrial situs, second to ascertain atrioventricular connexions, and third to decide the ventriculo-arterial connexions.

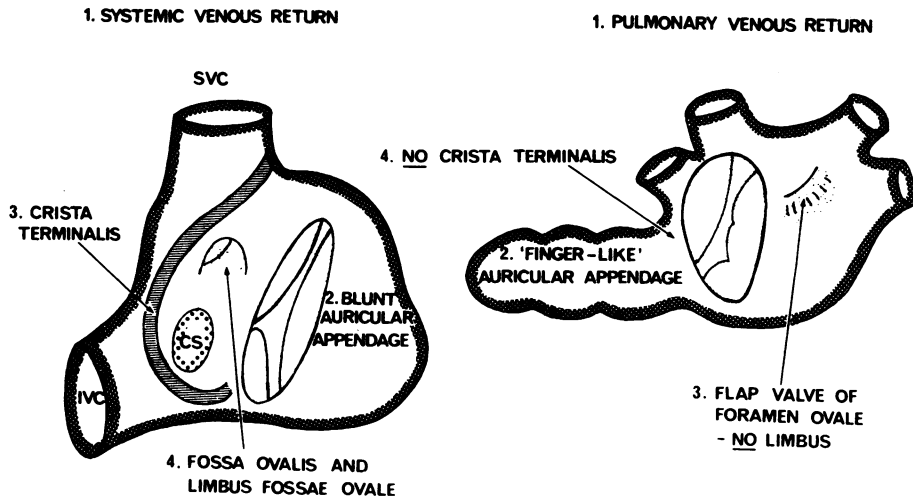


FIG. 1 Diagrams illustrating the morphological differences between the normal right atrium (left hand diagram) and left atrium (right hand diagram).

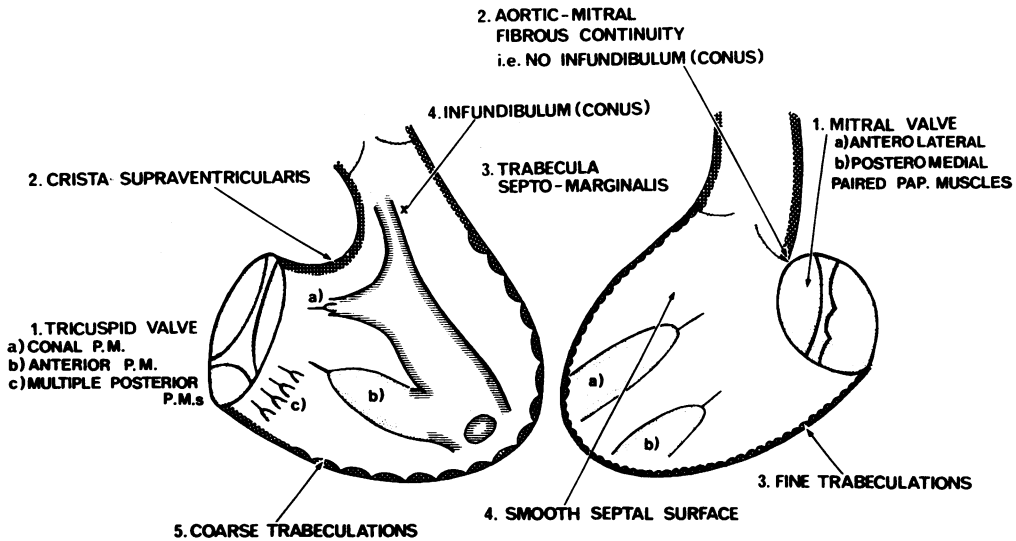


FIG. 2 Diagrams illustrating the morphological differences between the normal right ventricle (left hand diagram) and right ventricle (right hand diagram).

(a) Establish atrial situs

Atrial situs is defined as either *solitus*, *inversus*, or *ambiguus* (Fig. 3). In *situs solitus* the morphological right atrium is right-sided and the left atrium is left-sided. In *situs inversus* the right atrium is left-sided and left atrium right-sided. In *situs ambiguus*

it is not possible to identify separate right and left atria on morphological criteria. Thus, a common atrial chamber receiving both systemic and pulmonary venous returns is usually associated with bilateral right or left auricular appendages. The simplest method of establishing these atrial positions

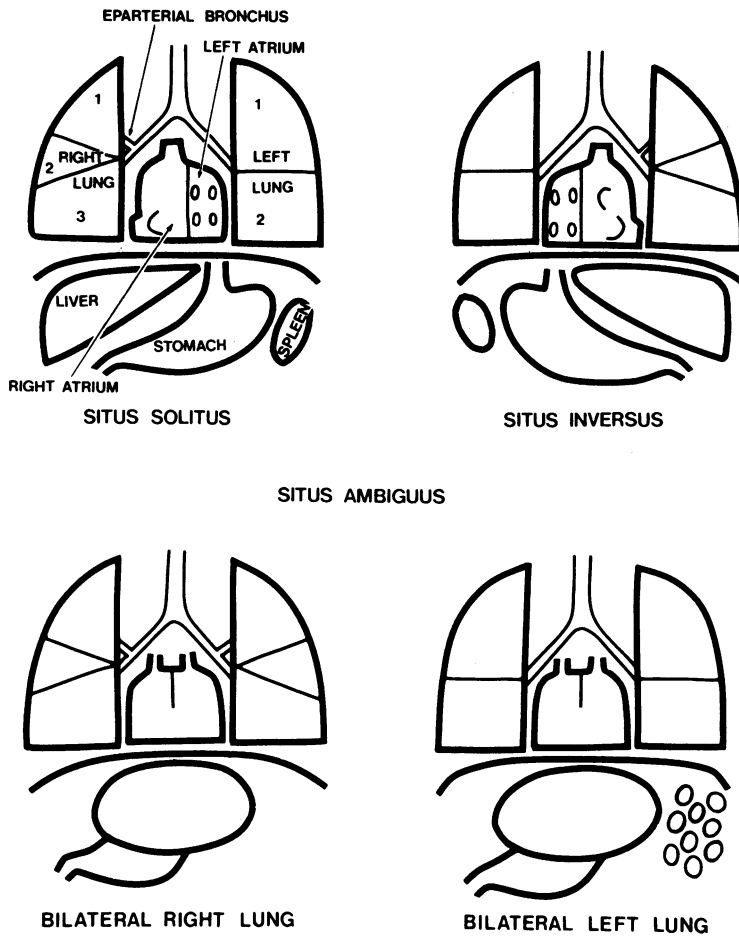


FIG. 3 Diagram illustrating the features of *situs solitus*, *situs inversus*, and *situs ambiguus*. The latter can exist in two forms: that with bilateral right lung is usually associated with asplenia and that with bilateral left lung is usually associated with polysplenia (see text for further discussion).

before cardiac catheterization is by examination of the plain and penetrated chest radiograph. Thus, if the liver is right-sided, the inference can usually be made that the inferior vena cava and right atrium are also right-sided and that there is *situs solitus*. Conversely, if the liver is left-sided, then the morphological right atrium will usually be left-sided and viscerocardiac *situs inversus* will be present. When the liver is central, then *situs ambiguus* usually exists. However, in this situation error can be introduced by this method of determining situs from position of abdominal organs. Firstly, *situs ambiguus* may be 'missed' if there is insufficient gas in the stomach and intestines to outline the liver. Secondly, abdominal and atrial situs do not always correspond

(Lev *et al.*, 1968; Hollman, 1968; Hastreiter and Rodriguez-Coronel, 1968; Lev *et al.*, 1971; Losekoot, 1973; Liberthson *et al.*, 1973). It is, therefore, also important to assess thoracic situs, i.e. position of morphological right (trilobed) and left (bilobed) lungs. This can usually be established from examination of the main bronchi on the penetrated chest radiograph (Van Mierop, Eisen, and Schiebler, 1970). In 95 per cent of cases, the radiographic length of the morphological left main bronchus is at least twice that of the right main bronchus, thus making identification of thoracic situs a simple procedure. Where the ratio of bronchial lengths is less than 2, and particularly if it is less than 1.5, then thoracic isomerism (*situs*

ambiguus) is likely to be present. Under these circumstances, or if the bronchi cannot be visualized on the plain film, then bronchial tomography will permit objective assessment of bronchial situs (Partridge *et al.*, 1975). This method allows very sharp lines to be drawn between the three types of situs discussed above. In contrast, the majority of situs ambiguus patients studied by Partridge *et al.* (1975) had lateralized rather than central livers. On the basis of thoracic situs, it is further possible to separate situs ambiguus into two categories of (i) bilateral right lung and (ii) bilateral left lung. These categories have different implications as far as associated cardiovascular anomalies are concerned. It has been previously assumed that bilateral right lungs were always associated with asplenia, whereas bilateral left lungs were always associated with polysplenia. In most studies of necropsy material this has indeed been the case (Moller *et al.*, 1967; P. Stanger, 1975, personal communication). However, the study of Partridge *et al.* (1975) showed that in two patients with haematological evidence of asplenia (presence of Howell-Jolly bodies) the lungs were arranged as for situs solitus and situs inversus, respectively. Furthermore, in the

patient with situs solitus, the anticipated severe cardiac anomalies associated with asplenia were not present. In a clinical context, therefore, it appears that the splenic 'state' is considerably harder to establish than thoracic situs, and conveys less information. We are unaware of any exceptions to the rule that atrial situs may be predicted from bronchial anatomy. However, this 'rule' has been tested in relatively few patients. Most data from necropsy studies have been concerned with lung lobulation rather than bronchial anatomy, and lobulation occasionally does not predict atrial situs correctly (Lev *et al.*, 1968, 1971; Libberthson *et al.*, 1973). Equally, lung lobulation does not always correspond with bronchial anatomy (Landing *et al.*, 1971).

(b) Ascertain atrioventricular connexions
(Fig. 4)

When the morphological right atrium connects with the morphological right ventricle and the morphological left atrium connects with the morphological left ventricle, then *atrioventricular concordance* is present irrespective of the ventricular positions within the chest (Anderson *et al.*, 1974a). In

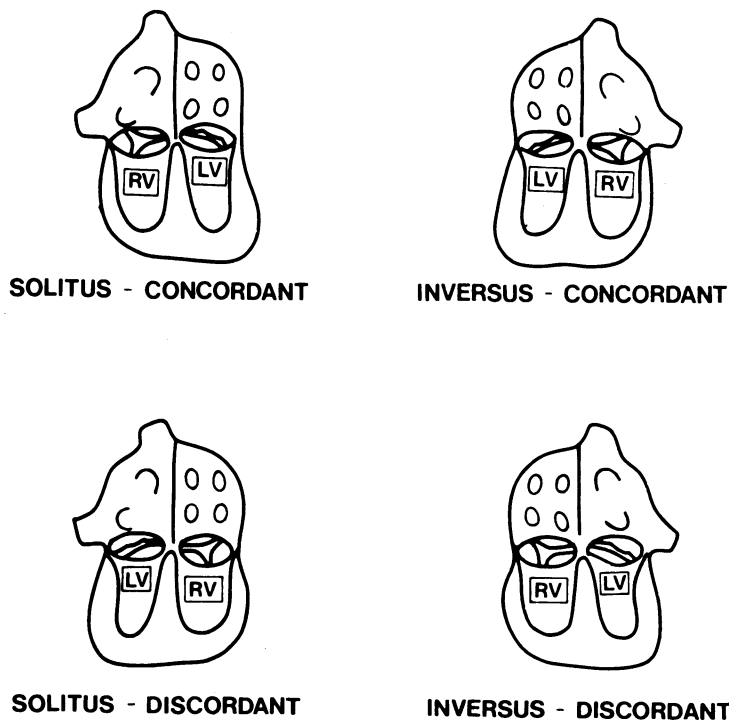


FIG. 4 Diagrams illustrating atrioventricular concordance and discordance. The atria are as depicted in Fig. 3 (RV=right ventricle; LV=left ventricle).

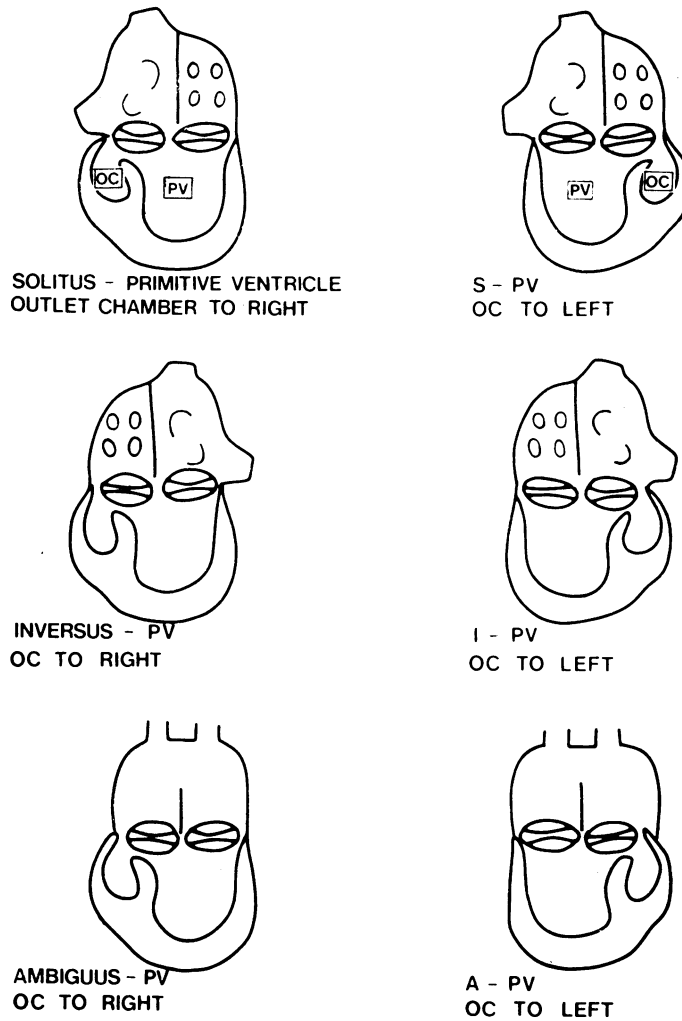


FIG. 5 Diagram illustrating the position of the outlet chamber (OC) in primitive ventricle (PV) in relation to atrial situs. Since both atrioventricular valves open to the primitive ventricle and cannot be distinguished clinically they are shown as bicuspid structures. The outlet chamber can be to the right or left in association with situs solitus, inversus, or ambiguus (solitus (S), inversus (I), ambiguus (A)).

contrast, when the morphological right atrium drains to the morphological left ventricle, and left atrium to right ventricle, atrioventricular discordance exists, again irrespective of chamber position within the chest. These connexions are established angiographically. The terms concordant and discordant presume the presence of two identifiable atria and two identifiable ventricles. In the living patient, angiographic criteria for the identification of the morphological right ventricle are (a) presence of coarse trabeculations, especially during diastole,

and (b) presence of an infundibulum with consequent discontinuity of atrioventricular and semilunar valves. A further feature is the triangular shape of the ventricle in the anteroposterior projection. Criteria for the identification of the morphological left ventricle are (a) a smooth outline to the ventricle during diastole and (b) absence of an infundibulum, the atrioventricular valve being in fibrous continuity with the semilunar valve. In some malformed hearts the morphological left ventricle may possess an infundibulum. The left ventricular

chamber usually has a globular appearance in both anteroposterior and lateral projections.

In situations where both atrioventricular valves open into the same ventricular chamber, where one atrioventricular valve straddles a septum, or in the presence of situs ambiguus, use of the terms *concordance* and *discordance* is not justified. When the atrioventricular valves enter a common chamber, or when one valve straddles the septum, having stated viscerotrial situs, we would then indicate that the atria connect with a *primitive ventricle* (Fig. 5, 6). A primitive ventricle exists when the

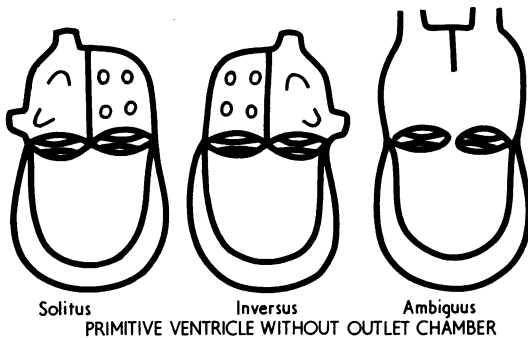


FIG. 6 Diagram illustrating varieties of primitive ventricle without outlet chamber.

posterior septum normally present between the atrioventricular valves is absent. In our experience, all hearts with primitive ventricles can be further categorized as primitive ventricle with outlet chamber, or primitive ventricle without outlet chamber (Fig. 5, 6; Anderson, Becker, and Wilkinson, 1975b). When an outlet chamber is present, it can be right- or left-sided (Fig. 5). In primitive ventricle it is not possible to distinguish between the tricuspid and mitral valves by angiographic techniques. Indeed, these distinctions frequently cannot be made even by direct examination of necropsy specimens of primitive ventricle. It is, therefore, more accurate to refer to these structures in hearts with primitive ventricle as the right and left atrioventricular valves. Furthermore, in most cases of tricuspid atresia, and in some cases of mitral atresia, the ventricular morphology is identical to that found in primitive ventricle (Anderson and Becker, 1975; Macartney *et al.*, 1976). In these situations, therefore, it would be more accurate to consider the hearts as variants of primitive ventricle and to refer to atresia of the right and left atrioventricular valves respectively. In situs solitus, hearts with straddling right atrioventricular valves have been shown to

resemble hearts with primitive ventricle and outlet chamber (Liberthson *et al.*, 1971). Our studies support this viewpoint, and suggest that the septum straddled is the bulboventricular septum between primitive ventricle and outlet chamber rather than the posterior interventricular septum between right and left ventricles (Fig. 7). For this reason, we believe it to be more accurate to refer to these hearts also as primitive ventricle and to avoid use of the terms 'concordant' or 'discordant' in relation to atrioventricular connexions. Examination of our specimens with straddling left atrioventricular valves indicated that in this circumstance also the atrioventricular valve straddled the bulboventricular septum in some cases. More frequently, the straddling left valve was recognizable as a mitral valve and normally formed right and left ventricles were present; in these instances the septum straddled was recognized as the interventricular septum. As Quero Jimenez *et al.* (1973) have indicated, the condition may be termed double inlet right ventricle. Using angiographic criteria, however, the cases could still resemble primitive ventricle with both valves entering a common chamber. Unless we identified two ventricles with certainty, and established the nature of the septum present, we would not use the terms 'concordant' or 'discordant' in this circumstance.

The other occasion on which the terms 'concordant' and 'discordant' may not be properly used is when there is situs ambiguus (Fig. 8). When situs ambiguus coexists with primitive ventricle, the nomenclature is simply situs ambiguus-primitive ventricle (with or without outlet chamber). When two normally formed ventricles are present, we employ the terms d-loop and l-loop as suggested by Van Praagh *et al.* (1964a).

(c) Decide ventriculo-arterial connexions

As with atrioventricular connexions, this segmental interconnexion is established by angiocardiology carried out in a manner which will profile the anterior interventricular (bulboventricular) septum. There are three basic patterns in which the great arteries may be connected to their underlying ventricles. These are (i) *normal connexions*; (ii) *transpositions*; and (iii) *double outlet ventricle* (Fig. 9). These connexions presuppose identification of two ventricles and a septum (or primitive ventricle and outlet chamber with a bulboventricular septum) and identification of the ventricular origin of both arteries. The situation in which only one great artery can be identified as arising from a ventricle is defined as *single arterial trunk* (Fig. 10). In defining these connexions, no account is taken of either the

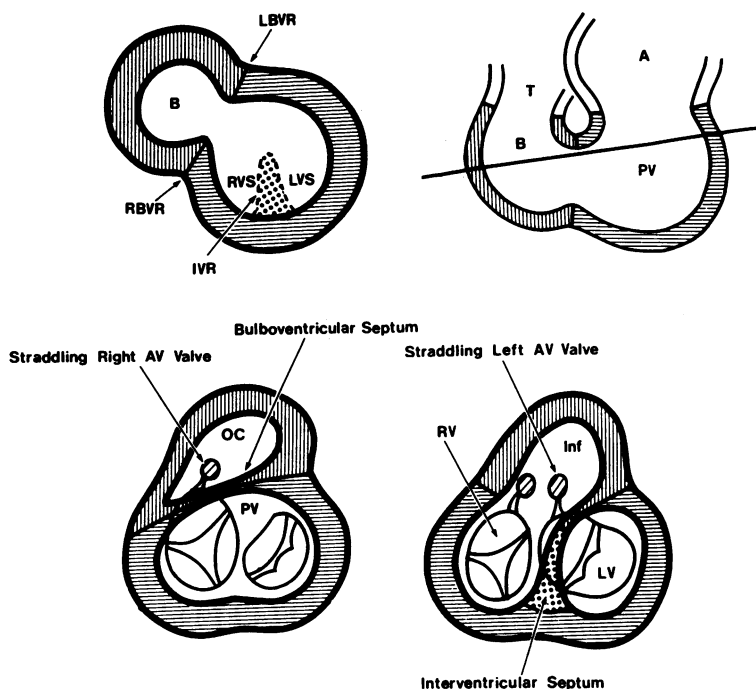


FIG. 7 Diagrams illustrating the concept of straddling atrioventricular valves. The top right hand diagram is a frontal section through the primitive heart tube (A =primitive atrium; PV =primitive ventricle; B =bulbus; T =truncus). The top left hand diagram is a cross-section at the level of the line. The right and left bulboventricular ridges ($LBVR$, $RBVR$) separate bulbus from primitive ventricle. The primitive ventricle itself is divided into the right ventricular sinus (RVS) and left ventricular sinus (LVS) by the interventricular ridge (IVR). Should the bulbus persist as an outlet chamber (OC) with primitive ventricle (PV), then the right atrioventricular valve can straddle the bulboventricular septum (lower left hand diagram). The left atrioventricular valve may also straddle the bulboventricular septum in primitive ventricle with outlet chamber. Further (lower right hand diagram) the mitral valve may also straddle the interventricular septum when right and left ventricles are normally separated. (Inf =infundibulum.)

spatial interrelations of the arteries or the condition of their coni. These may be subsequently specified if so desired.

(i) **Normal connexions** The great arteries are normally connected when the aorta arises from the morphological left ventricle (or primitive ventricle) and the pulmonary artery arises from the morphological right ventricle (or outlet chamber). In almost all circumstances such normally connected arteries will also be normally related. The normally related aortic valve is posterior and on the opposite side from the morphological left ventricle with respect to the pulmonary valve. Thus, when the left ventricle is left-sided the normally related aortic valve is to the right of the pulmonary valve. In contrast,

when the left ventricle is right-sided the normally related aortic valve is left-sided. Rarely will the situation be encountered in which the great arteries are normally connected but in which the valvar interrelations are not normal as described above. This ventriculo-arterial relation has been termed anatomically corrected malposition (Van Praagh *et al.*, 1975). A variant of this situation in which ventriculo-arterial connexions are normal, but relations are again abnormal, has been termed 'isolated ventricular inversion' (Van Praagh and Van Praagh, 1966; Quero-Jimenez and Raposo-Sonenfeld, 1975). One of us has recently argued that both these situations should be classified as 'anatomically corrected malposition' (Anderson *et al.*, 1975a; Anderson and Wilkinson, 1975). It is

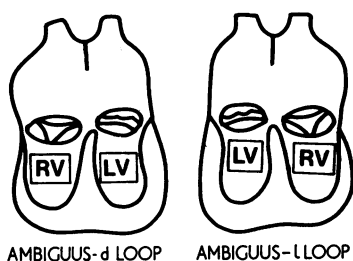


FIG. 8 Diagram illustrating the nomenclature in atrioventricular connexions in situs ambiguus. Since the atria either have the characteristics of two right or two left atria, concordance and discordance are not justifiable terms.

now evident that such arguments are unnecessary if it is accepted that in all these instances the ventriculo-arterial connexions are normal. If this is established from the outset, then the abnormal relations can be specified as d- or l-malposition. (In all instances, the terms d- or l- as applied to a ventriculo-arterial connexion indicate the right or left spatial position of the aortic valve with regard to the pulmonary valve).

(ii) Transposition Transposition is present when both great arteries are placed across the septum so as to arise from morphologically inappropriate ventricles, the aorta from the right and the pulmonary artery from the left (or aorta from outlet chamber and pulmonary artery from primitive ventricle). Since primitive ventricle without outlet chamber does not possess a septum, all ventriculo-arterial connexions in these hearts fall into the double outlet category (see below). Since the term transposition describes the connexion, the terms d- or l- as applied to transposition are used to indicate the spatial relation of aortic to pulmonary valve, and convey no information regarding atrioventricular connexions. These would be described in our segmental nomenclature. The heart described as solitus-concordant-l-transposition would therefore have a left-sided aortic valve arising from the normally connected right ventricle. It would be a 'complete' transposition. In contrast, 'congenitally corrected' transposition would be described as solitus-discordant-l-transposition. In some circumstances the aortic valve may be directly in front of the pulmonary valve, and in these cases we would employ the term o-transposition (Squarcia, Ritter, and Kincaid, 1973). Another unusual form of transposition, in which the aorta is posterior, may be termed p-transposition (Van Praagh *et al.*, 1971; Wilkinson *et al.*, 1975).

(iii) Double outlet ventricle We have followed the precedent of Kirklin *et al.* (1973) and defined a double outlet connexion as that in which more than one and a half great arteries arise from the same ventricular or outlet chamber. A bilateral conus is not, therefore, a prerequisite for double outlet ventricle. It is well established that a continuum exists between normal connexions, double outlet ventricle, and transposition (Van Mierop and Wigglesworth, 1963; Lev *et al.*, 1972; Goor and Edwards, 1973; Anderson *et al.*, 1974b). Nowhere is this more apparent than in the situation where tetralogy of Fallot (considered by us to be a normal connexion) merges with double outlet right ventricle with pulmonary stenosis (solitus-concordant-DORV with d-malposition and pulmonary stenosis: Becker, Connor, and Anderson, 1975; Shinebourne, Anderson, and Bowyer, 1975). In this situation, we suggest that it is consistent to consider cases in which more than half the aorta arises from the right

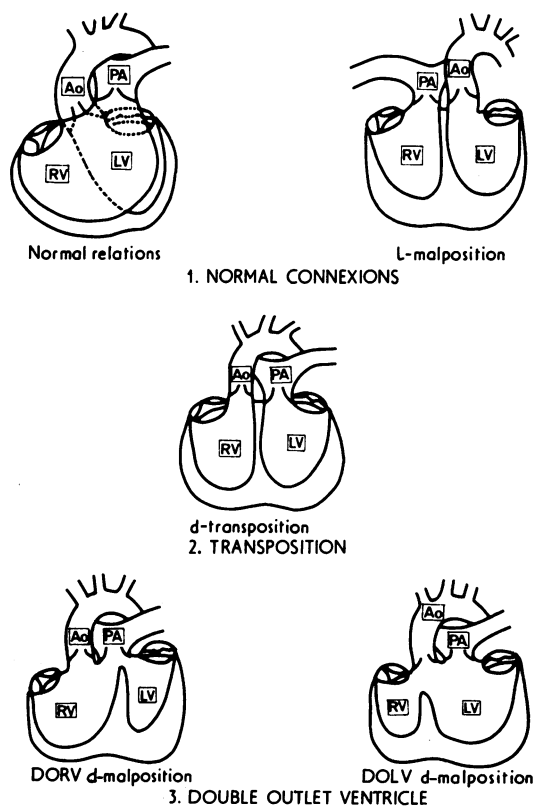


FIG. 9 Diagrams illustrating ventriculo-arterial connexions. Though the great arteries are illustrated only in d-position for the second two categories, they can also exist in l-position (see text for discussion).

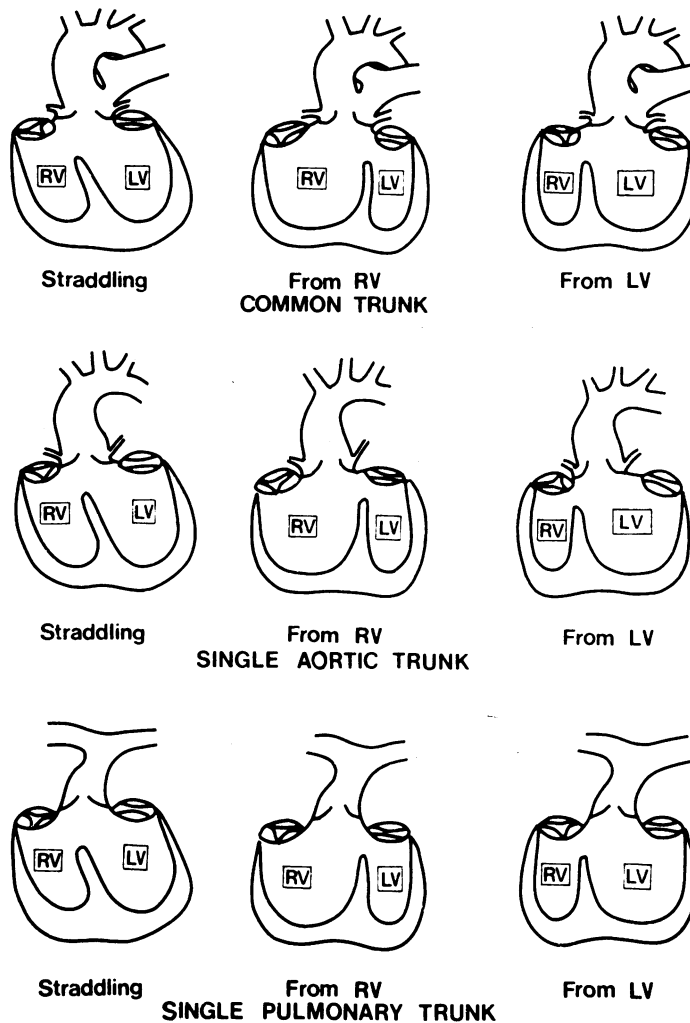


FIG. 10 Diagram illustrating the varieties of single arterial trunk. In addition to common truncus this category is required when the ventricular origin of either an atretic pulmonary artery or an atretic aorta cannot be identified: hence the categories single aortic trunk and single pulmonary trunk.

ventricle as DORV irrespective of presence or absence of aortic-mitral fibrous continuity. Kirklin and Karp (1970) are inconsistent in this respect and continue to refer to such cases with aortic-mitral continuity as tetralogy. Likewise, arguments relative to the precise nature of the 'Taussig-Bing anomaly' (Taussig and Bing, 1949; Van Praagh, 1968; Hinkes, Rosenquist, and White, 1971) are resolved if connexions are considered rather than the state of the subpulmonary conus. Thus, if more than half the pulmonary artery arises from the right ventricle, the connexion is DORV irrespective of valvar con-

tinuity or discontinuity. If more than half is from the left ventricle it is transposition. When the artery directly overrides it is arbitrarily placed into one or other category (Kirklin *et al.*, 1973). The varying great arterial interrelations of DORV or DOLV are described as d-malposition or l-malposition.

As mentioned above, all ventriculo-arterial connexions in primitive ventricle without outlet chamber are examples of double outlet malposition, since there is only one ventricular chamber. For the purposes of diagnosis in this instance, the great arterial interrelations can be described as d-

malposition or l-malposition, and the anterior or posterior position of the aorta indicated if necessary.

(iv) **Single arterial trunk** (Fig. 10). The single trunk can be a common truncus, an aorta, or a pulmonary artery, and each can arise from the morphological right ventricle, the morphological left ventricle, or in an overriding position. We specify single aortic trunk or a single pulmonary trunk when it is impossible to establish the origin of an atretic artery from the ventricles. This precludes the necessity of making paradoxical classifications such as 'double outlet right ventricle with pulmonary atresia' or of diagnosing 'transposition with pulmonary atresia' when it is not possible to determine if the pulmonary artery has indeed been placed across the septum. Positive identification of a common arterial trunk is made when coronary arteries and one or both pulmonary arteries arise from the ascending portion of the single arterial trunk.

D: Tabulate associated anomalies present (Table 2)

Any number of anomalies within each segment of the heart can accompany any possible combination of the above connexions. Tabulation and definition of all possibilities is not our present purpose. However, they can be conveniently grouped as (i) anomalies of venous return; (ii) anomalies of atrial anatomy; (iii) anomalies of the atrioventricular junction; (iv) anomalies of ventricular anatomy; (v) anomalies of conal anatomy and of the aortic arches and their derivatives.

E: Cardiac malpositions

Having specified connexions and anomalies within the heart, it may be considered desirable to specify the position of the heart within the chest, remembering that this conveys no information relevant to the internal cardiac anatomy or connexions. The heart may be within the right chest (dextrocardia), within the left chest (laevocardia), or centrally placed (mesocardia). Similarly, the apex of the heart may point to the left, right, or not be identifiable. Rotation of the heart about its long axis may also occur. If our nomenclature is used positional abnormalities of the heart within the chest will not affect interpretation of the anomaly (Anderson *et al.*, 1974a). In addition, it becomes apparent that terms such as dextrocardia, dextroversion, or dextrorotation add little to, or may confuse, understanding of the anomaly.

Discussion

It is of paramount importance to realize that a great difference exists between a connexion and a relation. A connexion automatically links two adjacent cardiac segments, whereas a relation does not, being more concerned with spatial orientation. To illustrate this point, in the variety of transposition known as posterior (p-) transposition (Van Praagh *et al.*, 1971; Wilkinson *et al.*, 1975), the arteries are normally related, i.e. the aorta is posterior and to the opposite side from the pulmonary artery with respect to the morphological left ventricle. However, the connexions are abnormal, the aorta arising from the right ventricle and the pulmonary artery from the left ventricle. Conversely, in anatomically corrected malposition the connexions are normal but the relations abnormal. In determining the course of blood through these hearts, it is the connexions which are important. It is in the emphasis on either connexions or relations that the two segmental approaches proposed on the one hand by Van Praagh (Van Praagh *et al.*, 1964a; Van Praagh, 1972) and on the other by de la Cruz and her colleagues (de la Cruz and Nadal-Ginard, 1972; de la Cruz *et al.*, 1974) differ so radically. The Van Praagh concept is based upon connexions throughout the heart. The de la Cruz hypothesis states atrioventricular connexions but is dependent on relations at ventriculo-arterial (or arterio-ventricular as described by these authors) level. This can be illustrated by reference to the categories of ventriculo-arterial connexions defined by Van Praagh (1973), namely transposition and double outlet ventricle. Within the connexions concept, these categories are discrete entities, and diagnosis of one category would exclude the other. In contrast, de la Cruz and her colleagues (1974) define the terms as relations. Thus, for them a double outlet ventricle can coexist with transposition if the aorta is in anterior position. They also use the terms 'concordant' and 'discordant' in an entirely different fashion from that proposed by Kirklin *et al.* (1973). For de la Cruz *et al.* (1974), an arterio-ventricular relation is concordant when the orientation of the great arteries can be used to predict the spatial relations and identities of the underlying ventricles. If a ventriculogram has been performed in order to establish this orientation, then this system is unnecessary, since the ventricle can be identified by morphological criteria and then used as a framework to establish ventriculo-arterial connexions. It is for this reason that we employ a concept based on connexions, and there is no doubt in our minds that such a scheme is superior to the alternative offered by de la Cruz and her colleagues (1972, 1974).

Kirklin and his colleagues' modification of the segmental approach of Van Praagh *et al.* (1971) was essentially one of using the terms 'concordant' and 'discordant' to express atrioventricular connexions (the terms having been introduced by Van Praagh *et al.*, 1964b) and extending their usage to ventriculo-arterial connexions. They indicated that both 'normal relations' and 'anatomically corrected malposition' could be considered as concordant ventriculo-arterial connexions, whereas transposition was a discordant connexion (Kirklin *et al.*, 1973). As we have indicated, one of us (R.H.A.) recently argued for the existence of anatomically corrected malposition as a discrete ventriculo-arterial relation, and further argued that 'isolated ventricular inversion' should be considered as the same relation (Anderson *et al.*, 1975a; Anderson and Wilkinson, 1975). However, such argument is unnecessary if it is realized that in all these relations the *connexions* are normal. We, therefore, recognize that the *connexions* between ventricles and arteries are of prime importance and that spatial relations and conal morphology are of secondary importance. We prefer the use of the terms 'normally connected', 'transposition', and 'double outlet ventricle' since we feel that use of 'concordant' and 'discordant' at both atrioventricular and ventriculo-arterial levels could lead to confusion (c.f. Kirklin *et al.*, 1973).

We have concentrated on connexions as our primary criteria and it has been necessary to demote in importance considerations of either spatial interrelations or conal morphologies. Thus, definition of transposition no longer requires the presence of subaortic conal musculature, as explained previously by Van Praagh *et al.* (1971). Similarly, we have followed the precedent of Kirklin *et al.* (1973) and do not insist upon the presence of bilateral conal musculature to define double outlet right ventricle. This concept for double outlet seems to us consistent with the approach to transposition, and more logical than that which insists upon presence of bilateral conal musculature. However, the latter definition is widely employed and has persuasive advocates (Baron, 1971). Choice of definitions is largely a matter of philosophy, but we would consider it inconsistent if we were to employ a 'connexions' approach while at the same time retaining a 'conal' definition for double outlet right ventricle. There are more practical reasons for adopting definitions based on ventricular connexions. It is often difficult using angiographic criteria to establish with certainty if a conus is present beneath a valve. Indeed, the distinction may not be possible following necropsy study, and to deal with this problem the subtle terms 'discontiNuity' and 'discontiGuity' have been introduced. Such niceties

are unnecessary if connexions are the sole arbiter of how arteries are attached to their underlying ventricles.

In our terminology we have catered for exceptional situations where our original definitions are either paradoxical or ambiguous. This situation is present at the atrioventricular junction when either situs ambiguus is present, or two ventricular sinuses cannot be identified. In the first instance we used the terms d-loop and l-loop as proposed by Van Praagh *et al.* (1964a). We do not use these terms throughout because we consider them inferior to 'concordant' and 'discordant' when the latter terms can be properly employed. In the second instance, we have used the term 'primitive ventricle' to describe hearts in which the posterior interventricular septum is lacking. Problems of nomenclature concerning the univentricular heart are considerable (Harley, 1958; Van Praagh *et al.*, 1964a; de la Cruz and Miller, 1968; Lev *et al.*, 1969; Liberthson *et al.*, 1971; Macartney *et al.*, 1976). Many of the disagreements are the result of differing opinions regarding embryogenesis, and are therefore difficult to resolve. In terms of both nomenclature and surgical approach, the important feature of all these hearts, which by definition have absence of the posterior septum, is presence or absence of the anterior bulboventricular septum. This determines the presence or absence of an outlet chamber. The precise nature of the outlet and main chambers is of less importance, and as Lev *et al.* (1969) have indicated, whichever concept of embryogenesis is espoused the main ventricular chamber will always be the embryonic primitive ventricle. It is for this reason that we have adopted Lev's term 'primitive ventricle' and qualified it with regard to presence or absence of the outlet chamber. Our investigations indicate that hearts with atresia of an atrioventricular orifice can exist with the ventricular morphology of primitive ventricle, with or without outlet chamber (Anderson *et al.*, 1975b; Macartney *et al.*, 1976). We believe that exclusion of such hearts from the category of the univentricular heart is artificial (Van Praagh *et al.*, 1964a; Gasul, Arcilla, and Lev, 1966).

When the primitive ventricle possesses an outlet chamber, it also possesses an anterior bulboventricular septum. In these circumstances we have followed the precedent of Van Praagh *et al.* (1971) and used definitions of ventriculo-arterial connexions as for the heart with right and left ventricles and an interventricular septum. In contrast, when primitive ventricle does not possess an outlet chamber it is composed of one chamber which always gives rise to both great arteries. In this

situation, therefore, we have categorized arterial connexions as double outlet ventricle.

Another necessary alternative category is single arterial trunk. We have used this in an attempt to avoid paradoxical and semantically unsound definitions. In most instances in which there is either aortic or pulmonary atresia it is possible to identify the ventricular origin of the atretic artery using angiographic criteria. In these instances, we would categorize the connexion as if continuity were present and specify the atresia as an associated anomaly of the great arterial segment. However, where ventricular origin cannot be positively identified, then we believe it is more accurate to use the term 'single arterial trunk'.

In summary, we have outlined a concept of nomenclature and classification based upon the sequential identification of the cardiac chambers and their connexions. The concept is in essence a modification of that promoted by Van Praagh and his colleagues over the past decade (1964 to 1973). We accept that our presently employed definitions may require modification in the future. However, we contend that the system can cater for any heart as yet encountered and reported.

We are indebted to many of our colleagues for discussions leading up to the nomenclature presented. In particular, we thank Drs. James L. Wilkinson, Royal Liverpool Children's Hospital, and Anton E. Becker, Wilhelmina Gasthuis, Amsterdam. Our thoughts regarding this nomenclature were considerably influenced by lengthy discussions with Dr. John W. Kirklín of Birmingham, Alabama, and we are grateful to him for his help.

References

- Anderson, R. H., Shinebourne, E. A., and Gerlis, L. M. (1974a). Criss-cross atrioventricular relationships producing paradoxical atrioventricular concordance or discordance: their significance to nomenclature of congenital heart disease. *Circulation*, **50**, 176.
- Anderson, R. H., Wilkinson, J. L., Arnold, R., Becker, A. E., and Lubkiewicz, K. (1974b). Morphogenesis of bulboventricular malformations. II Observations on malformed hearts. *British Heart Journal*, **36**, 948.
- Anderson, R. H., and Becker, A. E. (1975). Morphological observations in specimens of tricuspid atresia with reference to bulboventricular morphogenesis (abstract). *British Heart Journal*, **37**, 552.
- Anderson, R. H., Becker, A. E., and Wilkinson, J. L. (1975b). Morphogenesis and nomenclature of univentricular hearts (abstract). *British Heart Journal*, **37**, 781.
- Anderson, R. H., Becker, A. E., Losekoot, T. G., and Gerlis, L. M. (1975a). Anatomically corrected malposition of great arteries. *British Heart Journal*, **37**, 993.
- Anderson, R. H., and Wilkinson, J. L. (1975). Isolated ventricular inversion with situs solitus. *British Heart Journal*, **37**, 1202.
- Baron, M. G. (1971). Radiologic notes in cardiology—angiographic differentiation between tetralogy of Fallot and double-outlet right ventricle. *Circulation*, **43**, 451.
- Becker, A. E., Connor, M., and Anderson, R. H. (1975). Tetralogy of Fallot—morphometric and geometric study. *American Journal of Cardiology*, **35**, 402.
- De la Cruz, M. V., Amoedo, M., Rivera, F., and Attie, F. (1974). Arterioventricular relations and their classification. Two specimens of arterioventricular discordance and review of published reports. *British Heart Journal*, **36**, 539.
- De la Cruz, M. V., and Miller, B. L. (1968). Double-inlet left ventricle: two pathological specimens with comments on the embryology and on its relation to single ventricle. *Circulation*, **37**, 249.
- De la Cruz, M. V., and Nadal-Ginard, B. (1972). Rules for the diagnosis of visceral situs, truncocoanal morphologies and ventricular inversions. *American Heart Journal*, **84**, 19.
- Gasul, B. M., Arcilla, R. A., and Lev, M. (1966). *Heart Disease in Children*, p. 289. J. B. Lippincott, Philadelphia.
- Goor, D. A., and Edwards, J. E. (1973). The spectrum of transposition of the great arteries: with specific reference to developmental anatomy of the conus. *Circulation*, **48**, 406.
- Harley, H. R. S. (1958). The embryology of cor triloculare batriatum with bulbar (rudimentary) cavity. *Guy's Hospital Reports*, **107**, 116.
- Hastreiter, A. R., and Rodriguez-Coronel, A. (1968). Discordant situs of thoracic and abdominal viscera. *American Journal of Cardiology*, **22**, III.
- Hinkes, P., Rosenquist, G. C., and White, R. I. (1971). Roentgenographic reexamination of the internal anatomy of the Taussig-Bing heart. *American Heart Journal*, **81**, 335.
- Hollman, A. (1968). Dextrocardia, levocardia and mesocardia. In *Paediatric Cardiology*, p. 659. Ed. by H. Watson. Lloyd-Luke, London.
- International Society of Cardiology (1970). Classification of Heart Disease in Childhood. VRB Offsetdrukking, Groningen.
- Kirklín, J. W., and Karp, R. B. (1970). *The Tetralogy of Fallot from a Surgical Viewpoint*, p. 20. W. B. Saunders, Philadelphia.
- Kirklín, J. W., Pacifico, A. D., Bargerón, L. M., and Soto, B. (1973). Cardiac repair in anatomically corrected malposition of the great arteries. *Circulation*, **48**, 153.
- Landing, B. H., Lawrence, T.-Y. K., Payne, V. C., and Wells, T. R. (1971). Bronchial anatomy in syndromes with abnormal visceral situs, abnormal spleen and congenital heart disease. *American Journal of Cardiology*, **28**, 456.
- Lev, M., Bharati, S., Meng, C. C. L., Liberthson, R. R., Paul, M. H., and Idriss, F. (1972). A concept of double-outlet right ventricle. *Journal of Thoracic and Cardiovascular Surgery*, **64**, 271.
- Lev, M., Liberthson, R. R., Eckner, F. A. O., and Arcilla, R. A. (1968). Pathologic anatomy of dextrocardia and its clinical implications. *Circulation*, **37**, 979.
- Lev, M., Liberthson, R. R., Golden, J. G., Eckner, F. A. O., and Arcilla, R. A. (1971). The pathologic anatomy of mesocardia. *American Journal of Cardiology*, **28**, 428.
- Lev, M., Liberthson, R. R., Kirkpatrick, J. R., Eckner, F. A. O., and Arcilla, R. A. (1969). Single (primitive) ventricle. *Circulation*, **39**, 577.
- Liberthson, R. R., Hastreiter, A. R., Sinha, S. N., Bharati, S., Novak, G. M., and Lev, M. (1973). Levocardia with visceral heterotaxy-isolated levocardia: pathologic anatomy and its clinical implications. *American Heart Journal*, **85**, 40.
- Liberthson, R. R., Paul, M. H., Muster, A. J., Arcilla, R. A., Eckner, F. A. O., and Lev, M. (1971). Straddling and displaced atrioventricular orifices and valves with primitive ventricles. *Circulation*, **43**, 213.
- Losekoot, T. G. (1973). Mirror-image dextrocardia with situs solitus of the abdominal organs in a normal heart. *European Journal of Cardiology*, **1**, 49.

- Macartney, F. J., Partridge, J. R., Scott, O., and Deverall, P. B. (1976). Common or single ventricle: an angiocardio-graphic and hemodynamic study of 42 patients. *Circulation*. In the press.
- Moller, J. H., Nakib, A., Anderson, R. C., and Edwards, J. E. (1967). Congenital cardiac disease associated with polysplenia. *Circulation*, **36**, 789.
- New York Heart Association, Criteria Committee (1973). *Nomenclature and Criteria for Diagnosis of the Diseases of the Heart and Great Vessels*, 7th ed. Little Brown, Boston.
- Partridge, J. B., Scott, O., Deverall, P. B., and Macartney, F. J. (1975). Visualization and measurement of the main bronchi by tomography as an objective indicator of thoracic situs in congenital heart disease. *Circulation*, **51**, 188.
- Quero Jimenez, M., Perez Martinez, V. M., Maitre Azcárate, M. J., Merino Batres, G., and Moreno Granados, F. (1973). Exaggerated displacement of the atrioventricular canal towards the bulbus cordis (rightward displacement of the mitral valve). *British Heart Journal*, **35**, 651.
- Quero-Jimenez, M., and Raposo-Sonenfeld, I. (1975). Isolated ventricular inversion with situs solitus. *British Heart Journal*, **37**, 293.
- Shinebourne, E. A., Anderson, R. H., and Bowyer, J. J. (1975). Variations in clinical presentation of Fallot's tetralogy in infancy. *British Heart Journal*, **37**, 946.
- Squarcia, U., Ritter, D. G., and Kincaid, O. W. (1973). Dextrocardia: angiocardio-graphic study and classification. *American Journal of Cardiology*, **32**, 965.
- Taussig, H. B., and Bing, R. J. (1949). Complete transposition of the aorta and a levoposition of the pulmonary artery. Clinical, physiological and pathological findings. *American Heart Journal*, **37**, 551.
- Van Mierop, L. H. S. (1971). Transposition of the great arteries. I Clarification or further confusion? *American Journal of Cardiology*, **28**, 735.
- Van Mierop, L. H. S., Eisen, S., and Schiebler, G. L. (1970). The radiographic appearance of the tracheobronchial tree as an indicator of visceral situs. *American Journal of Cardiology*, **26**, 432.
- Van Mierop, L. H. S., and Wiglesworth, F. W. (1963). Pathogenesis of transposition complexes. II. Anomalies due to faulty transfer of the posterior great artery. *American Journal of Cardiology*, **12**, 226.
- Van Praagh, R. (1968). What is the Taussig-Bing malformation? *Circulation*, **38**, 445.
- Van Praagh, R. (1972). The segmental approach to diagnosis in congenital heart disease. *Birth Defects: Original Article Series*, **8**, No. 5, p.4. Williams and Wilkins, Baltimore.
- Van Praagh, R. (1973). Do side-by-side great arteries merit a special name? *American Journal of Cardiology*, **32**, 874.
- Van Praagh, R., Durnin, R. C., Jockin, H., Wagner, H. R., Kornis, M., Garabedian, H., Ando, M., and Calder, A. L. (1975). Anatomically corrected malposition of the great arteries (S, D, L). *Circulation*, **51**, 20.
- Van Praagh, R., Ongley, P. A., and Swan, H. J. C. (1964a). Anatomic types of single or common ventricle in man: morphologic and geometric aspects of 60 necropsied cases. *American Journal of Cardiology*, **13**, 367.
- Van Praagh, R., Perez-Trevino, C., Lopez-Cuellar, M., Baker F. W., Zuberbuhler, J. R., Quero, M., Perez, V. M., Moreno, F., and Van Praagh, S. (1971). Transposition of the great arteries with posterior aorta, anterior pulmonary artery, subpulmonary conus and fibrous continuity between aortic and atrioventricular valves. *American Journal of Cardiology*, **28**, 621.
- Van Praagh, R., and Van Praagh, S. (1966). Isolated ventricular inversion: a consideration of morphogenesis, definition and diagnosis of non-transposed and transposed great arteries. *American Journal of Cardiology*, **17**, 395.
- Van Praagh, R., Van Praagh, S., Vlad, P., and Keith, J. D. (1964b). Anatomic types of congenital dextrocardia. Diagnostic and embryologic implications. *American Journal of Cardiology*, **13**, 510.
- Wilkinson, J. L., Arnold, R., Anderson, R. H., and Acerete, F. (1975). 'Posterior' transposition reconsidered. *British Heart Journal*, **37**, 757.

Requests for reprints to Dr. R. H. Anderson, Department of Paediatrics, Cardiothoracic Institute, Brompton Hospital, Fulham Road, London SW3 6HP.