

## Left ventricular apical thin point

J. W. B. BRADFIELD,<sup>1</sup> GILLIAN BECK,<sup>2</sup> AND R. J. VECHT

From the Departments of Pathology and Cardiology, St. Mary's Hospital, London

*The wall thickness of the apex of the left ventricle has been measured at its thinnest point in 60 adult hearts at necropsy. This measured 2 mm or less in 97 per cent of them and 1 mm or less in 67 per cent.*

Some types of sutureless epicardial pacemaker electrode are anchored into the ventricular myocardium by a corkscrew 6 mm long by 4 mm diameter (Naclerio and Varriale, 1974). Recently a patient died from haemorrhage at the site of insertion into the left ventricle. At necropsy, the ventricular thickness at the apical site of insertion was 4 mm (Vecht *et al.*, 1976). The first object of the present study was to find out how often the adult left ventricle is less than 6 mm at its apical thin point.

Imaging of the myocardium using Thallium-201 has recently been introduced as a clinical investigation. With this technique defects at the apex of the left ventricle are common in normal hearts and have been attributed to local anatomical thinness of the myocardium (Cook *et al.*, 1976). The second object of our study was to find out whether this thin point exists.

### Methods

The 60 hearts were all from adults varying in age from 34 to 87, with a mean age of 68 years. Thirty-seven per cent were from women.

#### HEART APICES

These were obtained at necropsy. Any heart which showed evidence of local disease was excluded from the series. In the rest the apex was amputated about 3 cm from its tip and fixed in 10 per cent buffered formol saline. Each specimen comprised the apex and part of each ventricular free wall together with the distal part of the septum.

#### MEASUREMENTS

The height of the amputated apex was measured,

<sup>1</sup>Present address: The Johns Hopkins Medical Institutions, Divisions of Nuclear Medicine and Radiation Health, 615 North Wolfe Street, Baltimore, Maryland 21205, U.S.A.

<sup>2</sup>Part of this study was done as a Student Pathology Project at St. Mary's Hospital Medical School.

Received for publication 22 November 1976

as was the minimum left ventricular wall thickness at the level of amputation. The left ventricular myocardium was cut into sagittal slices at 5 mm intervals. The right ventricular myocardium was then cut into coronal slices at 5 mm intervals. Each slice of the left ventricle was inspected and at its thinnest point the thickness of the muscle and of the overlying epicardial fat were measured. This sometimes required bisection of the relevant 5 mm slice, as the thinnest point was always very small. The thickness of the left ventricular wall was then measured in the adjacent slices (i.e. 5 mm to each side of the thin point). The thickness of muscle and fat in the right ventricle was also measured at its thinnest point which was often not at the apex.

All measurements are expressed as mean  $\pm$  1 standard deviation.

### Results

#### LEFT VENTRICLE

##### Myocardium

The architecture of the apex of the left ventricle was remarkably constant. At the apex itself there was always one point where the myocardial thickness was 3 mm or less. The individual measurements are shown in Fig. 1a. In the whole series the mean thickness of the muscle at its apical thin point was  $1.3 \pm 0.7$  mm. In some hearts the thin point measured less than 1 mm. An example of such a slice is shown in Fig. 2, and a photomicrograph shown in Fig. 3 shows how few strands of muscle separate endocardium from epicardial fat. In 2 out of the 60 hearts examined there were 2 apical thin points.

Fig. 1 also shows that the left ventricular myocardial thickness increased rapidly on each side of the apical thin point, so that when measured 5 mm away on one side the myocardial thickness was already  $3.7 \pm 2.3$  mm on the thinner side (Fig. 1b) and  $7.9 \pm 6.3$  mm on the thicker side (Fig. 1c). In the whole series the line of amputation

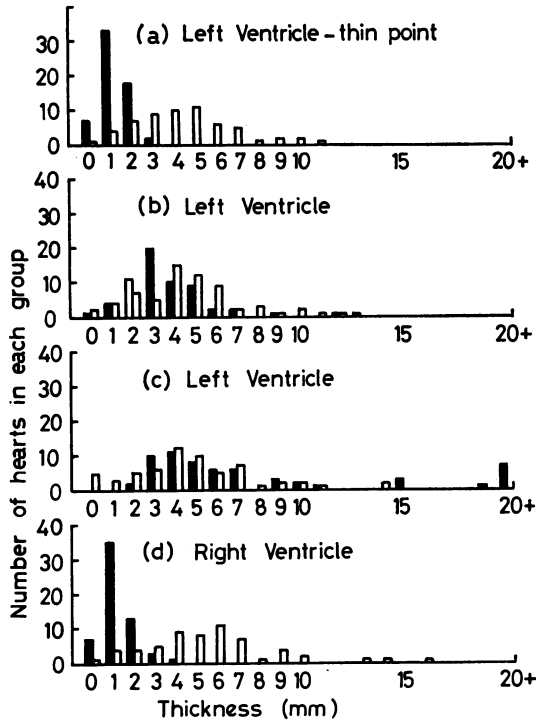


Fig. 1 Histogram shows the thickness of muscle and fat in the ventricles of 60 hearts at necropsy. Solid columns—muscle; open columns—epicardial fat. A measured thickness of less than 0.5 mm is recorded as 0 mm. (a) Left ventricular thickness of muscle and fat at apical thin point; (b) Thickness of thinner 5 mm slice of left ventricular wall adjacent to apical thin point; (c) Thickness of the 5 mm slice of left ventricular wall on the other side of the apical thin point; (d) Least thickness of right ventricle. The position of measurement varied in different samples.

was  $29.0 \pm 6.8$  mm from the apical thin point and here the wall thickness was  $14.0 \pm 3.5$  mm.

*Epicardial fat*

Fig. 1a, b, and c also show the thickness of the fat overlying the myocardium at the apex. This measured between 4.5 and 4.7 mm and is well illustrated in Fig. 2. At the apical thin point the epicardial fat was usually more than three times the thickness of the myocardium.

**RIGHT VENTRICLE**

In the right ventricle the architecture of the apex was different from that on the left side. The lumen was more convex and there was no single apical thin point. Instead there were several points

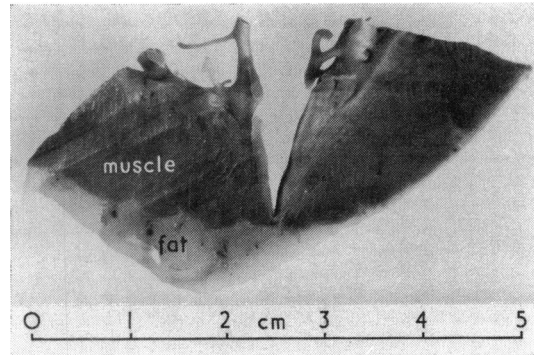


Fig. 2 Sagittal slice of myocardium from the apex of the left ventricle of a 755 g heart. The piece has been arranged so as to display the apical thin point at which the endocardium comes to within 1 mm of the epicardial fat.

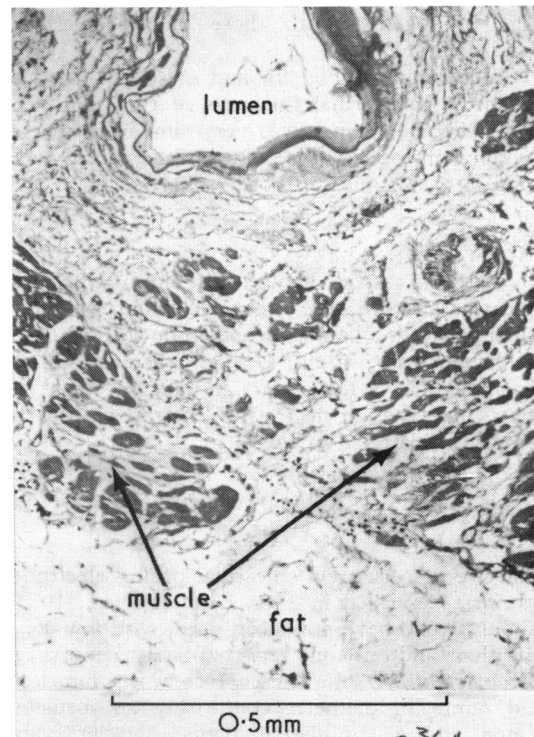


Fig. 3 Histological section of apical thin point of the left ventricle of a 270 g heart (haematoxylin and eosin.  $\times 110$ ). Note the paucity of muscle between lumen and epicardial fat.

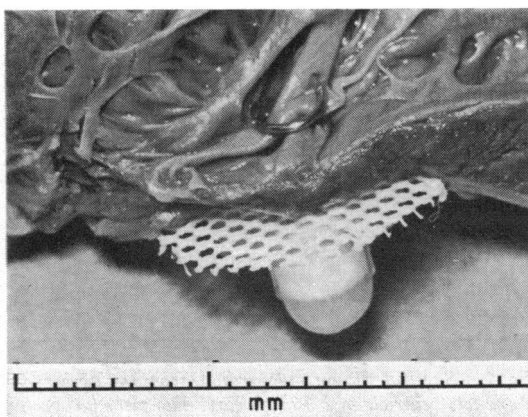


Fig. 4 Epicardial corkscrew electrode inserted into the apex of a left ventricle at necropsy. The apex has been opened to show complete penetration of the corkscrew into the lumen.

of equal thickness between trabeculations of the muscle. The individual dimensions are shown in Fig. 1d together with those of the overlying epicardial fat.

Comparison of Fig. 1a and d shows that the minimum myocardial thickness of the right ventricle of  $1.3 \pm 0.8$  mm was very similar to that at the apex on the left side, and that the pad of overlying fat was similar in both regions.

#### PACEMAKER INSERTION

In order to assess how far a 6 mm corkscrew epicardial pacemaker electrode would penetrate when inserted, a corkscrew electrode (Model 6917, Medtronic Inc., Minn., U.S.A.) was screwed the recommended 3 turns into an unfixed fresh left ventricular apex at necropsy. Penetration into the lumen is illustrated in Fig. 4.

#### Discussion

The use of corkscrew epicardial pacing electrodes was first described in 1973 (Hunter *et al.*, 1973). About 30 000 have now been used, with few complications and only one reported fatal haemorrhage (Vecht *et al.*, 1976). The corkscrew is 6 mm long and 4 mm in diameter comprising an insulated region and a stimulating region (Naclerio and Varriale, 1974). Our experience with postmortem hearts showed that the recommended 3 turns were sufficient to insert the thread of the corkscrew the full 6 mm so that the Dacron netting guard came to

lie against the epicardium. Recommendations for the site of implantation vary. Some authors suggest that the corkscrew be inserted as near to the apex of the ventricle as possible (O'Neill and Spagna, 1974). Failing this the anterior aspect of the right ventricle is the site of choice. In our series of measurements most hearts had one small point at the apex of the left ventricle at which the thickness of the myocardium was only 1 to 2 mm, sometimes less. The overlying epicardial fat was almost always thicker than this but provides no grip for a corkscrew. In view of this it is not surprising that it was easy to insert the pacemaker into a postmortem heart in such a way as to cause penetration into the lumen of the left ventricle. This result differs from that of a previous report in which penetration was never observed during a series of 25 insertions into right ventricular myocardium (Naclerio and Varriale, 1974), even though the thickness of the latter is usually less than 3 mm (Olsen, 1973; and Fig. 1d).

Clinically, many thousands of epicardial pacemakers have been inserted in this way and it seems likely that a proportion of these have penetrated the ventricular wall. The fact that there has been only one reported case of fatal haemorrhage means that the left ventricular apical thin point must be of sufficiently small area to allow adequate anchorage by the surrounding muscle. The finding in two hearts of double apical thin points in the left ventricle is more disconcerting in that this variation might allow the intervening piece of muscle to be pulled out by a corkscrew electrode screwed into both thin points. Because of this we suggest that the preferred site of insertion of this type of epicardial electrode should be away from the exact apex of the left ventricle.

The arrangement of the muscle at the left ventricular apex illustrated by these measurements carries implications about the way in which muscle at the apex contracts. It seems unlikely that the very thin strands of myocardial muscle at this site could withstand the pressure generated within that chamber during systole. More probably the whorled arrangement of the muscle fibres (Thane, 1892; Fox and Hutchins, 1972) allows the narrow funnel to close off at the onset of systole so that the thinnest point is protected from the high pressure generated at the peak of contraction. No such arrangement is found in the right ventricle where the convexity of the lumen allows transmission of the lower pressure to the thin areas at the apex.

These anatomical findings are also important for the correct interpretation of cardiac radionuclide studies. During Thallium-201 myocardial imaging there is an area of decreased activity of the apex

of the left ventricle in about 50 per cent of normal hearts (Cook *et al.*, 1976). The postulate that this is the result of local anatomical thinning is here substantiated. In addition gated blood pool studies using Technetium 99m-labelled albumin confirm that as systole begins the left ventricular myocardium contracts in such a way as to constrict the apical region (J. W. B. Bradfield—personal observations).

In short, the impression of pathologists that the left ventricle is very thin at its apex, even in hypertrophied hearts, is confirmed by measurements. Appreciation of the presence of this left ventricular apical thin point is important (i) for the design and use of corkscrew epicardial pacemakers, (ii) for the interpretation of myocardial images produced by radionuclides, and (iii) for the understanding of muscle contraction at the apex of the left ventricle.

We thank Drs. R. O. Barnard, W. K. Blenkinsopp, W. V. Bogomoletz, R. B. Hartley, and S. Wilson for their help.

#### References

- Cook, D. J., Bailey, I., Strauss, H. W., Rouleau, J., Wagner, H. N., and Pitt, B. (1976). Thallium-201 for myocardial imaging: appearance of the normal heart. *Journal of Nuclear Medicine*, **17**, 583-589.
- Fox, C. C., and Hutchins, G. M. (1972). The architecture of the human ventricular myocardium. *Johns Hopkins Medical Journal*, **130**, 289-299.
- Hunter, S. W., Bolduc, L., Long, V., and Quattlebaum, F. W. (1973). A new myocardial pacemaker lead (sutureless). *Chest*, **63**, 430-433.
- Naclerio, E. A., and Varriale, P. (1974). 'Screw-in' electrode. New method for permanent ventricular pacing. *New York State Journal of Medicine*, **74**, 2391-2395.
- Olsen, E. G. J. (1973). *The Pathology of the Heart*. Intercontinental Medical Book Corp., New York.
- O'Neill, J. E., and Spagna, P. M. (1974). *Implantation of the Model 6917 Sutureless Lead Wire. Subxiphoid and Infradiaphragmatic Approach*. Medtronic, Minneapolis.
- Thane, G. D. (1892). In *Quain's Elements of Anatomy*, 10th ed., vol. 2, part 2. Longmans, Green, London.
- Vecht, R. J., Fontaine, C. J., and Bradfield, J. W. B. (1976). Fatal outcome arising from use of a sutureless 'corkscrew' epicardial pacing electrode inserted into apex of left ventricle. *British Heart Journal*, **38**, 1359-1362.

Requests for reprints to Dr. R. J. Vecht, Waller Cardio-Pulmonary Unit, St. Mary's Hospital, Praed Street, London W2 1NY.