

# Two-dimensional sector scanner echocardiography in cyanotic congenital heart disease<sup>1</sup>

A. B. HOUSTON, N. L. GREGORY, AND E. N. COLEMAN

*From the Department of Cardiology and the University Department of Child Health, Royal Hospital for Sick Children, and the Department of Clinical Physics and Bio-Engineering, Glasgow*

*A wide angle (60°) mechanical sector scanner producing a real-time two-dimensional echocardiogram has been used to assess the anatomy of the great arteries in 30 infants and children with cyanotic congenital heart disease. Longitudinal scans show the relations of the mitral valve and ventricular septum to the posterior great artery, and transverse scans show the spatial relations of the great arteries.*

*In 19 patients the echocardiographic examination was preceded by angiocardigraphic diagnosis. Echocardiographic examination in 10 with complete transposition of the great arteries showed parallel great arteries; in 4 with Fallot's tetralogy, normally related great arteries with a narrow right ventricular outflow and an overriding aorta; in 4 with double outlet right ventricle, parallel great arteries, but in only 2 of these an unambiguous right ventricular origin of both great arteries; in 1 with persistent truncus arteriosus, a single artery with abnormal cusp echoes.*

*In 9 infants and 2 children, aged 9 and 16 years, echocardiographic examination was followed by angiocardigraphy. In the 9 infants the assessment of great artery size and relation by echocardiography closely correlated with that determined by angiocardigraphy. In the older child whose previous cardiac catheterisation without angiocardigraphy had suggested transposition of the great arteries, echocardiography showed normally related great arteries which were subsequently confirmed by angiocardigraphy. In the younger child with corrected transposition of the great arteries the echocardiographic appearance was initially misinterpreted as normally related great arteries.*

*Two-dimensional echocardiography, because of its capacity to display the anatomy of the ventricular outflow tracts, permits better planning of the subsequent cardiac catheterisation and angiocardigraphy in children with cyanotic congenital heart disease.*

The findings of time-position echocardiography in transposition of the great arteries (Dillon *et al.*, 1973; Gramiak *et al.*, 1973), double outlet right ventricle (Chesler *et al.*, 1971), persistent truncus arteriosus (Chung *et al.*, 1973a), Fallot's tetralogy (Chung *et al.*, 1973b), total anomalous pulmonary venous drainage (Paquet and Gutgesell, 1975), and in cyanotic newborn infants (Godman *et al.*, 1974) have been reported. To increase the information available from echocardiography two-dimensional real-time scanning systems have recently been introduced and have proved of value in cyanotic congenital heart disease (Sahn *et al.*, 1974; Henry *et al.*, 1975; Maron *et al.*, 1975).

A wide angle (60°) mechanical sector scanner producing two-dimensional echocardiograms (Shaw *et al.*, 1976) has been used to assess great artery anatomy in infants and children with cyanotic congenital heart disease. The wide angle swept by the single element of this scanner displays simultaneously both ventricular outflow tracts. In making a preliminary report on this aspect of its clinical application we now describe and assess the results obtained in two groups of infants and children in whom the definitive diagnosis was made by cardiac catheterisation and angiocardigraphy.

## Subjects and methods

Thirty patients with cyanotic congenital heart disease were studied. In 19 with known anomalies of the origin of the great arteries the diagnosis of

<sup>1</sup>Supported in part by a research grant from the Equipment Research Committee of the Chief Scientist's Organisation of the Scottish Home and Health Department.

Received for publication 4 April 1977

complete transposition of the great arteries (10), double outlet right ventricle (4), Fallot's tetralogy (4), or persistent truncus arteriosus (1) had been made by angiocardiology; the age range was from 4 weeks to 16 years.

In 11 patients echocardiographic assessment of great artery size and position was made before elucidation of the abnormality by angiocardiology; the age range was 3 days to 16 years.

The ultrasonic equipment used was a mechanical 60° sector scanner (Shaw *et al.*, 1976) incorporating later developments (Houston *et al.*, 1977). In the initial part of the study a 2.5 MHz 12.5 mm diameter transducer was used but when a 5.0 MHz 6 mm diameter transducer became available it was used where appropriate. All illustrations in this report were obtained as still frame photographs from the television monitor. The convention adopted in transverse views is that the patient's left is to the right of the illustration, anterior being upwards.

The scanning planes employed were longitudinal and transverse as previously described (Houston *et al.*, 1977). The initial approach was, where possible, to obtain a longitudinal section through the great artery continuous with the anterior mitral leaflet and to determine its relation to the ventricular septum. A transverse scan was then obtained through this great artery and an attempt made to display a normal right ventricular outflow and main pulmonary artery crossing in front. In the absence of this normal relation the scanning plane was adjusted in an attempt to show the adjacent circular spaces characteristic of the parallel vessels in transposition of the great arteries (King *et al.*, 1973; Henry *et al.*, 1975); to confirm that such a circular space represented a great artery the semilunar valve echo was sought. In complex abnormalities where there was no mitral leaflet continuity with the posterior artery, the technique was modified with the intention of locating the ventricular septum and great arteries.

## Results

### COMPLETE TRANSPOSITION OF THE GREAT ARTERIES

In all 10 patients with complete transposition of the great arteries a high transverse scan showed two circular spaces (Fig. 1) which were confirmed as representing great arteries by the demonstration of central linear cusp echoes in diastole. It was not possible to display both great arteries at valve level in a single transverse scan in 3 of the 10 patients (Fig. 2). These illustrations were obtained with the scanner directly transverse and tilted to carry out a headwards sweep as with time-position

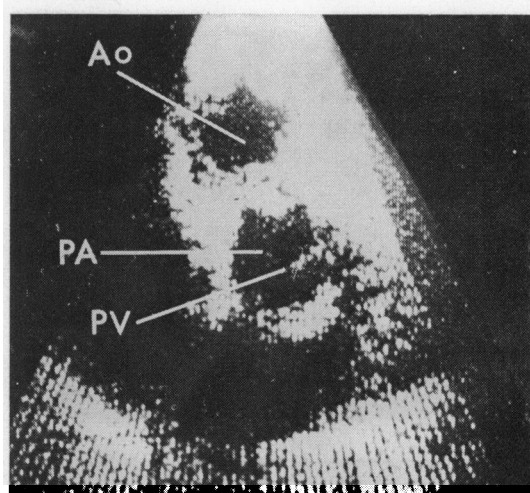


Fig. 1 High transverse scan from an 8-day-old infant using the 5 MHz transducer. Both great arteries appear as circular echo-free spaces in systole. The aorta (Ao) lies anterior to and to the right of the pulmonary artery (PA), showing the typical configuration of the great arteries in cases of complete transposition of the great arteries. The pulmonary valve cusps (PV) are shown in the closed position in diastole.

echocardiography. In Fig. 2a a small posterior vessel, the pulmonary artery, is apparent. As the scanning plane passes upwards (Fig. 2b) the pulmonary cusp echoes are lost and a larger anterior vessel, with central cusp echoes, appears to the right; this indicates that the valve of the anterior vessel lies to the right and superior to the posterior one. The posterior vessel appears to give rise to an elongated transverse echo-free space passing posterior to the anterior artery (Fig. 2b and c). We consider that this represents the bifurcation of the pulmonary artery and confirms the identity of the posterior vessel. Definite evidence of branching of the posterior great artery was noted in 4 of the 10 patients. In all 10 the echocardiographic spatial relations were found to correspond to those determined by angiocardiology.

### DOUBLE OUTLET RIGHT VENTRICLE

The 4 patients with double outlet right ventricle had echocardiographic evidence of two parallel vessels in the transverse scan. When the posterior great artery and the ventricular septum were viewed simultaneously their relation was seen to vary throughout the heart cycle, the septum moving posteriorly with respect to the great artery root during systole. The diastolic position was considered to give the best indication of the relation of the great

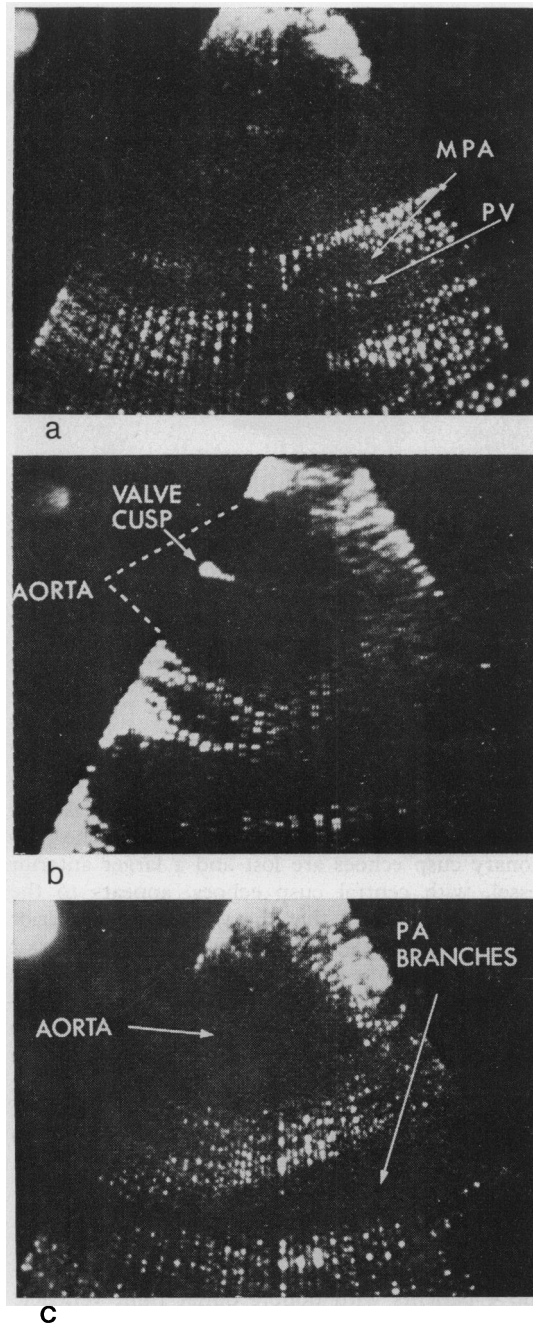


Fig. 2 High transverse scans from a patient with complete transposition of the great arteries and pulmonary artery hypoplasia obtained as the scanning plane is tilted superiorly from (a) the level of the pulmonary valve (PV), to (b) the aortic valve, and to (c) a supra-aortic level. The light in the upper left of the picture indicates the onset of the QRS complex, i.e. end-diastole.

arteries to the ventricles. This confirmed that both arteries arose from the same ventricle in 2 cases. In the other 2, less than one-and-a-half vessels appeared to arise from the right ventricle. Longitudinal scans showed an abnormal relation between the anterior mitral leaflet and the posterior artery in 1 patient from each of these pairs; mitral-semilunar valve continuity was interrupted by intervening conal tissue.

#### PERSISTENT TRUNCUS ARTERIOSUS

The one patient with persistent truncus arteriosus had a single large anterior vessel (Fig. 3) overriding the ventricular septum. Within this vessel a double central echo and several eccentric echoes were seen, representing the abnormal truncal valve cusps.

#### FALLOT'S TETRALOGY

In the 4 patients with tetralogy a high transverse scan confirmed normally related great arteries. Three of these showed overriding of the aorta on longitudinal scan (Fig. 4). The fourth showed no overriding in diastole but the aorta and ventricular septum moved asynchronously, the septum being posterior to the anterior wall of the aorta in systole.

#### ECHOCARDIOGRAPHY BEFORE ANGIOCARDIOGRAPHY

The Table shows the data on the 11 cyanotic patients (including 9 infants) in whom an echocardiographic assessment of great artery anatomy was made before the elucidation of the anomaly by

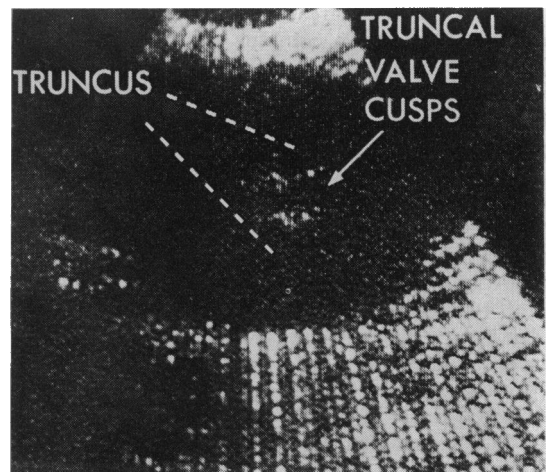


Fig. 3 Transverse scan from the patient with persistent truncus arteriosus at the level of the truncal valve cusps.

angiocardiography. In all 9 infants the echocardiographic assessment of great artery size and relation showed close correlation with the angiocardiographic findings. In 2 of the 4 patients with complete transposition of the great arteries, branching of the posterior artery confirmed that it was the pul-

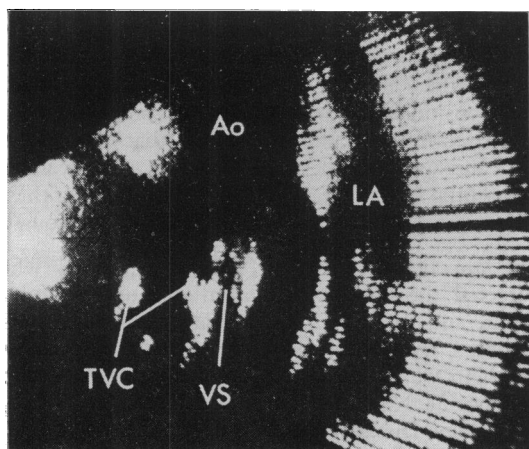


Fig. 4 Longitudinal scan from a patient with Fallot's tetralogy showing the aorta (Ao) overriding the ventricular septum (VS); LA, left atrium; TVC, tricuspid valve cusps.

Table Echocardiographic assessment of the anatomy of the great arteries compared with subsequent angiographic findings

Age	Transducer (MHz)	Echocardiogram	Angiocardiogram
3 d	5.0	CTGA	CTGA
8 d	5.0	CTGA	CTGA
10 d	5.0	CTGA	CTGA
6 w	2.5	Normal relations; narrow RVO and MPA	Hypoplastic RV and RVO
6 w	2.5	CTGA; narrow MPA	CTGA; hypoplastic MPA
2 m	2.5	Normal relations; wide RVO and MPA	TAPVD
4 m	2.5	Normal relations; narrow RVO and MPA	Primitive ventricle with outflow chamber
6 m	2.5	Overriding aorta; narrow RVO	Fallot's tetralogy
10 m	2.5	Overriding aorta; narrow RVO	Fallot's tetralogy
9 y	2.5	Normal relations; narrow RVO	Corrected TGA
16 y	2.5	Normal relations; narrow RVO and MPA	Primitive ventricle with outflow chamber; normally related arteries

CTGA, complete transposition of the great arteries; RVO, right ventricular outflow; MPA, main pulmonary artery; RV, right ventricle; TAPVD, total anomalous pulmonary venous drainage.

monary artery. The 16-year-old patient appeared to have normally related great arteries with a narrow right ventricular outflow and main pulmonary artery. The diagnosis of transposition of the great arteries with tricuspid atresia had been made at a previous cardiac catheterisation but because of arrhythmia no angiocardiogram had been obtained. Angiocardiography performed subsequent to the echocardiographic examination confirmed that he had normally related great arteries. An incorrect diagnosis of normally related great arteries with a narrow outflow was made in the 9-year-old child with corrected transposition. Review of the videotape recording showed that the anterior wall of the anterior left vessel had been misinterpreted as a thick immobile pulmonary valve; failure to recognise the semilunar cusp echo posterior to this caused the diagnostic error.

## Discussion

Time - position echocardiography allows exact measurement of the distances between structures along the axis of the ultrasound beam. The determination of the relations of different structures not lying along a single beam is dependent on the operator's assessment of small changes he makes in transducer angulation; the technique is difficult, particularly when it is applied to the rapidly beating heart of a restless infant. Two-dimensional echocardiography allows exact determination of the relation of structures, thus facilitating the assessment of great artery anatomy. Other workers who have reported on the use of real-time two-dimensional echocardiography in the assessment of great artery anomalies have concluded that the method is of diagnostic value (Sahn *et al.*, 1974; Henry *et al.*, 1975; Maron *et al.*, 1975). There were some differences between their techniques and their findings in normal high transverse scans; their experience and ours have been discussed elsewhere (Houston *et al.*, 1977). We have found that a high transverse scan can show the aortic origin as a circular space with a central diastolic cusp echo, and the pulmonary artery either in the same manner when the great arteries are parallel, or as an anterior crescentic space representing the right ventricular outflow and main pulmonary artery crossing in the normal way.

In the tetralogy of Fallot or other conditions in which there are normally related great arteries the circular aorta and crescentic right ventricular outflow and main pulmonary outflow are recognised. In complete transposition of the great arteries the diagnosis is suggested by the abnormal relation of the great arteries shown by echocardiography as

two echo-free circles which represent the vessels lying parallel at their origin; it is not dependent upon the separate identification of the aorta and the pulmonary artery. If, in some of the rarer types of transposition of the great arteries (Van Praagh, 1973), there should be any diagnostic difficulty it may be important to show branching of an artery which can thus be positively identified as the pulmonary artery. A problem is likely to arise when only one artery can be viewed in transverse section and no right ventricular outflow or other artery is visible, making a differential diagnosis between persistent truncus arteriosus and pulmonary atresia difficult. The abnormal eccentric cusp echoes reported by Sahn *et al.* (1974) and confirmed in our patient would be an important feature in the positive diagnosis of persistent truncus. For the diagnosis of double outlet right ventricle as defined by Lev *et al.* (1972) more than one-and-a-half great arteries should arise from the right ventricle. Echocardiographic examination of our patients showed that the relation of the great arteries to the ventricular septum varied throughout the cardiac cycle. We considered that the position in diastole was likely to show the closest agreement with findings at necropsy or operation and we used this in our assessment of their relation. In 2 of our patients more than half of one great artery appeared to be posterior to the septum, the inferior margin of the ventricular septal defect being used in this assessment. Subsequent review of the material has led to the suggestion that the superior and lateral margins of the septal defect may have been posterior to both great arteries. Chesler *et al.* (1971) with echocardiography showed mitral-semilunar valve discontinuity in double outlet right ventricle, whereas Cameron *et al.* (1976) found continuity in a minority of cases at necropsy. Two of our patients showed mitral-semilunar valve continuity and one of these on echocardiography also failed to satisfy the criterion of Lev *et al.* (1972). Thus the recognition that the ventricular septum is posterior to both arteries or that there is definite mitral-semilunar valve discontinuity is likely to be diagnostic of double outlet right ventricle, but our findings suggest that failure to recognise either by echocardiography does not exclude the diagnosis.

Correct assessment of the size of the great arteries and relation was made in 10 of the 11 patients examined before angiocardiology. In the 9-year-old child with corrected transposition an incorrect echocardiographic assessment was made while scanning and without viewing the videotape recording. This has stressed the importance of reviewing the recording before giving a diagnostic opinion. Newborn infants were not included until

the 5 MHz transducer became available because the 2.5 MHz transducer could not consistently provide scans of diagnostic quality.

In conclusion we believe that the results obtained from this wide angle sector scanner in the study of the size and relation of the great arteries have shown a satisfactory correlation with the angiographic diagnosis. The extensive planar display which it provides makes it particularly suited to the exploratory role which the diagnosis of complex congenital malformations demands, and in this respect more effective than the linear display to which time-position echocardiography is confined. When it is used in the planning of the cardiac catheterisation and angiocardiology of infants with cyanotic congenital heart disease we are convinced that these investigations can be performed more expeditiously.

We are indebted to Mr. A. Shaw, B.Sc., who directed the development of the scanning equipment, and to Mr. D. J. Wheatly, F.R.C.S., who initiated its clinical application. We acknowledge the help we have received from Dr. E. M. Sweet, Dr. M. McNair, and Miss J. L. McLardy of the Radiology Department of the Royal Hospital for Sick Children, Glasgow.

#### References

- Cameron, A. H., Acerete, F., Quero, M., and Castro, M. C. (1976). Double outlet right ventricle. Study of 27 cases. *British Heart Journal*, **38**, 1124-1132.
- Chesler, E., Joffe, H. S., Beck, W., and Schrire, V. (1971). Echocardiographic recognition of mitral-semilunar valve discontinuity. An aid to the diagnosis of origin of both great vessels from the right ventricle. *Circulation*, **43**, 725-732.
- Chung, K. J., Alexson, C. G., Manning, J. A., and Gramiak, R. (1973a). Echocardiography in truncus arteriosus. The value of pulmonic valve detection. *Circulation*, **48**, 281-286.
- Chung, K. J., Nanda, N. C., Manning, J. A., and Gramiak, R. (1973b). Echocardiographic findings in tetralogy of Fallot. *American Journal of Cardiology*, **31**, 126.
- Dillon, J. C., Feigenbaum, H., Konecke, L. L., Keutel, J., Hurwitz, R. A., Davis, R. H., and Chang, S. (1973). Echocardiographic manifestations of D-transposition of the great vessels. *American Journal of Cardiology*, **32**, 74-78.
- Godman, M. J., Tham, P., and Kidd, B. S. L. (1974). Echocardiography in the evaluation of the cyanotic newborn infant. *British Heart Journal*, **36**, 154-166.
- Gramiak, R., Chung, K. J., Nanda, N., and Manning, J. (1973). Echocardiographic diagnosis of transposition of the great vessels. *Radiology*, **106**, 187-189.
- Henry, W. L., Maron, B. J., Griffith, J. M., Redwood, D. R., and Epstein, S. E. (1975). Differential diagnosis of anomalies of the great arteries by real-time two-dimensional echocardiography. *Circulation*, **51**, 283-291.
- Houston, A. B., Gregory, N. L., Shaw, A., Wheatley, D. J., and Coleman, E. N. (1977). Two-dimensional echocardiography with a wide angle (60°) sector scanner. *British Heart Journal*, **39**, 1071-1075.
- King, D. L., Steeg, C. N., and Ellis, K. (1973). Demonstration of transposition of the great arteries by cardiac ultrasonography. *Radiology*, **107**, 181-186.

- Lev, M., Bharati, S., Meng, C. C. L., Liberthson, R. R., Paul, M. H., and Idriss, F. (1972). A concept of double-outlet right ventricle. *Journal of Thoracic and Cardiovascular Surgery*, **64**, 271-281.
- Maron, B. J., Henry, W. L., Griffith, J. M., Freedom, R. M., Kelly, D. T., and Epstein, S. E. (1975). Identification of congenital malformations of the great arteries in infants by real-time two-dimensional echocardiography. *Circulation*, **52**, 671-677.
- Paquet, M., and Gutgesell, H. (1975). Echocardiographic features of total anomalous pulmonary venous connection. *Circulation*, **51**, 599-605.
- Sahn, D. J., Terry, R., O'Rourke, R., Leopold, G., and Friedman, W. F. (1974). Multiple crystal cross-sectional echocardiography in the diagnosis of cyanotic congenital heart disease. *Circulation*, **50**, 230-238.
- Shaw, A., Paton, J. S., Gregory, N. L., and Wheatley, D. J. (1976). A real-time 2-dimensional ultrasonic scanner for clinical use. *Ultrasonics*, **14**, 35-40.
- Van Praagh, R. (1973). Do side by side great arteries merit a special name? *American Journal of Cardiology*, **32**, 874-876.

Requests for reprints to Dr. A. B. Houston, Royal Hospital for Sick Children, Yorkhill, Glasgow G3 8SJ.