

Near fatal puerperal thrombosis on Björk-Shiley mitral valve prosthesis

ANDREW A. McLEOD, KEVIN P. JENNINGS, AND EDWARD R. TOWNSEND

From the Departments of Cardiology and Cardiothoracic Surgery, King's College Hospital, London

SUMMARY A 22-year-old woman required emergency mitral valve replacement three weeks *post partum* because of thrombotic obstruction of her prosthetic mitral valve. Low dose subcutaneous heparin was administered from the 17th week of pregnancy. Though there was a successful fetal outcome, heparin did not prevent thrombosis on the prosthesis and its continuation into the puerperium proved nearly fatal.

There is as yet no established policy for anticoagulant therapy in pregnant patients with prosthetic heart valves. The most favourable outcome for fetus and mother is associated with biological valves which do not require lifelong anticoagulation (Oakley and Doherty, 1976). Coumarin anticoagulants in pregnant patients with non-biological valves may result in fetal malformation and haemorrhagic complications (Pettifor and Benson, 1975). We describe a case of a healthy 22-year-old parous woman with a Björk-Shiley mitral valve prosthesis. She had a large valve, a normal sized left atrium, and remained in sinus rhythm. Subcutaneous low dose heparin during pregnancy did not prevent almost complete occlusion of her prosthesis by thrombus which appeared to increase gradually throughout the pregnancy, and necessitated emergency replacement of her prosthesis in the puerperium.

Case report

The patient is a 22-year-old woman. A cardiac murmur was first heard at the age of 11 years and at 16 years cardiac catheterisation disclosed mild mitral regurgitation. Pregnancy at 18 was uneventful apart from induction of labour at 39 weeks for proteinuria and falling urinary oestriol levels. Eighteen months later she noticed that she tired easily, and by 1975 she was dyspnoeic on minimal exercise and unable to perform housework. Repeat catheterisation revealed severe mitral regurgitation and at operation in June 1975 a 'floppy' mitral valve was excised and a No. 29 Björk-Shiley valve inserted. She was subsequently placed on warfarin. Her life

was dramatically improved and she became pregnant later the same year but miscarried at 12 weeks.

At routine examination in March 1976, shortly before she became pregnant for a third time, a systolic murmur was noted. This was interpreted as a paravalvar leak. There were no symptoms, and an echocardiogram (Fig. 1) showed a normal sized left atrium and a normally functioning prosthesis. She had a threatened abortion and was admitted to hospital at about 10 weeks' gestation. At the 17th week of pregnancy, warfarin was discontinued and subcutaneous heparin, 5000 units b.d., was started and continued throughout pregnancy and into the puerperium.

She was admitted for rest at 27 weeks for dyspnoea and remained in hospital until the birth of her baby. Labour was uneventful and a healthy boy was delivered. She began breast feeding, and was discharged after 8 days feeling well. Subcutaneous heparin therapy was continued.

She was readmitted as an emergency 3 weeks after delivery with a one-day history of malaise, weakness, dyspnoea, and dizziness on mild exercise.

On examination she was unwell, pale, and peripherally cyanosed, temperature 37.5°C. She was in sinus rhythm, rate 120/min, blood pressure 100/70 mmHg. There was no peripheral oedema but her jugular venous pressure was raised at 8 cm. She was tachypnoeic and there were widespread inspiratory crepitations at both lung bases. The cardiac apex was forceful but not displaced. There was a soft, long, ejection-type systolic murmur, maximal at the apex. No closing click was audible from the prosthetic valve. Her congestive cardiac failure was treated with intravenous frusemide, and blood




Fig. 1 Echocardiogram of Björk-Shiley mitral valve prosthesis (mv) showing sharp opening and closure pattern and good excursion. Depth marks at 1 cm intervals.

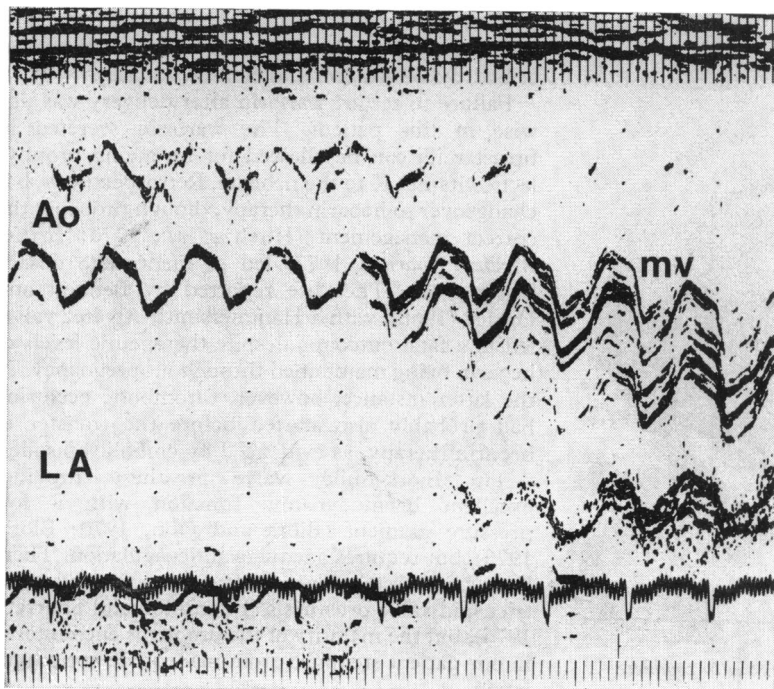


Fig. 2 Echocardiogram showing reduced excursion of Björk-Shiley mitral valve prosthesis (mv), with reduced opening and closure rates. The left atrium is greatly enlarged. LA, left atrium; Ao, aortic root; depth marks at 1 cm intervals.

cultures were taken to exclude infective endocarditis.

After improving at first, she deteriorated severely over the ensuing few hours. Her blood pressure fell to 80/30 mmHg, and the heart rate rose to 160 beats/min. In addition to the earlier cardiac findings, a pronounced parasternal heave was felt. An electrocardiogram showed sinus tachycardia, a QRS axis of $\pm 120^\circ$, and widespread ST segment depression and T wave inversion. The chest x-ray film showed severe pulmonary oedema. Clinically, thrombosis on the prosthesis was diagnosed. An echocardiogram showed a very large left atrium (Fig. 2), and a reduced prosthetic excursion, with slow opening and closure rates.

Emergency operation was undertaken by Mr Angus Macarthur through a right thoracotomy using cardiopulmonary bypass. The Björk-Shiley prosthesis was found to be completely occluded by thrombus apart from a small slit-like aperture in the major orifice (Fig. 3). The prosthesis was excised and replaced with a 31 Hancock porcine xenograft valve. After operation she was ventilated for 48 hours as the pulmonary oedema was slow to resolve. Thereafter she made an uneventful recovery, and was started on short-term warfarin therapy.

Discussion

Although the number of young women with

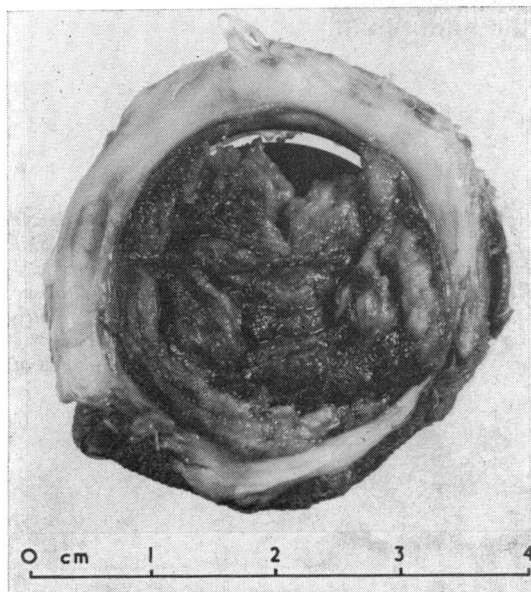


Fig. 3 Excised prosthesis showing virtually complete encapsulation by thrombus; scales in cm.

rheumatic heart disease has declined, patients with valve replacements can perhaps justifiably expect to live a normal life, including successful pregnancy, with the aid of effective drug therapy and continuing technological improvement in valve prostheses. The case reported here illustrates a young woman with good myocardial function whose desire to obtain a healthy infant at term, and also to allow breast feeding, almost caused her death.

Oakley and Doherty (1976) have reviewed experience of pregnancies in patients with valve prostheses in the United Kingdom, and biological valves are clearly preferable. In addition, aortic valve prostheses appear to be safer than mitral as regards the likelihood of thromboembolism.

A murmur was noticed in our patient shortly before she became pregnant, but this was interpreted as a paravalvar leak. The possibility of thrombotic malfunction was considered but the echocardiogram (Fig. 1) showed apparently satisfactory function. Echocardiography of the Björk-Shiley prosthesis is very dependent on transducer position and angulation (Douglas and Williams, 1974), but the initial tracings obtained here showed sharp opening and closure, with good excursion, and a normal left atrial size. It seems likely that thrombosis on the prosthesis increased thereafter and was hastened by the introduction of low-dose heparin therapy. The echocardiogram taken during the emergency showed limited excursion of the disc, with reduced opening and closing velocities. The appearance however was not as gross as that described by Bourdillon and Sharratt (1976).

Failure to restart warfarin after delivery was unwise in this patient. The warfarin secreted in breast milk can be allowed for by giving prophylactic vitamin K to the neonate. Retrospectively, her changeover to heparin therapy, though probably the correct management (Hirsh *et al.*, 1970; *British Medical Journal*, 1977) led to inadequate dosage being given. The case reported by Bennett and Oakley (1968), with a Hammersmith-Alvarez valve, led to a fatal outcome, despite therapeutic levels of heparin being maintained throughout pregnancy. In the latter instance, however, thrombotic occlusion had probably also started before the transfer to heparin therapy, as evidenced by embolic episodes.

The Björk-Shiley valve prosthesis provides excellent haemodynamic function with a low pressure gradient (Björk and Olin, 1970; Björk, 1975), but requires adequate anticoagulation. There have been recent doubts about its suitability as a tricuspid valve prosthesis (Bourdillon and Sharratt, 1976), but the majority of the problems encountered in our patient stemmed from inadequate anticoagulation.

This case illustrates the value of echocardiography in emergency assessment of prosthetic valve function, but it is important to note that there may have been significant dysfunction at the time that the echocardiogram appeared normal. Our patient received low doses of heparin and this undoubtedly predisposed to prosthetic valve malfunction, but thrombus formation had probably begun even while adequate levels of warfarin were being maintained. This reinforces the impression gained from the review of Oakley and Doherty (1976) that biological valves are the prostheses of choice for women who wish to become pregnant, and that, in any other situation, meticulous control of anticoagulation is required.

We thank Dr S. Oram and Mr A. M. Macarthur for permission to publish this case report. We are grateful to Dr D. E. Jewitt and Dr P. J. Richardson for help with various aspects of this patient's routine and emergency care.

References

- Bennett, G. G., and Oakley, C. M. (1968). Pregnancy in a patient with a mitral valve prosthesis. *Lancet*, **1**, 616-619.
- Björk, V. O. (1975). Four and one half years experience with the aortic and mitral Björk-Shiley tilting disc valve. *Journal of Cardiovascular Surgery*, Suppl., p. 347.
- Björk, V. O., and Olin, C. (1970). A hydrodynamic evaluation of the new tilting disc valve (Björk-Shiley) for mitral valve replacement. *Scandinavian Journal of Thoracic and Cardiovascular Surgery*, **4**, 37-43.
- Bourdillon, P. D. V., and Sharratt, G. P. (1976). Malfunction of Björk-Shiley valve prosthesis in tricuspid position. *British Heart Journal*, **38**, 1149-1153.
- British Medical Journal* (1977). Anticoagulants and heart valve replacement in pregnancy. Leading article, **1**, 1047-1048.
- Douglas, J. E., and Williams, G. D. (1974). Echocardiographic evaluation of the Björk-Shiley prosthetic valve. *Circulation*, **50**, 52-57.
- Hirsh, J., Cade, J. F., and O'Sullivan, E. F. (1970). Clinical experience with anticoagulant therapy during pregnancy. *British Medical Journal*, **1**, 270-273.
- Oakley, C., and Doherty, P. (1976). Pregnancy in patients after valve replacement. *British Heart Journal*, **38**, 1140-1148.
- Pettifor, J. M., and Benson, R. (1975). Congenital malformations associated with the administration of oral anticoagulants during pregnancy. *Journal of Pediatrics*, **86**, 459-462.

Requests for reprints to Dr. A. A. McLeod, Cardiac Department, King's College Hospital, Denmark Hill, London SE5 9RS.