

**Segment**



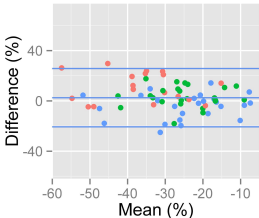
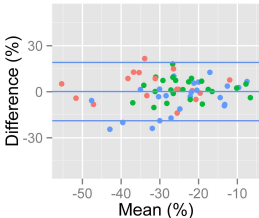
Subtricuspid



Anterior Wall



Apical



**Segment**



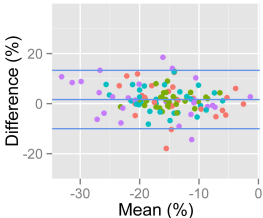
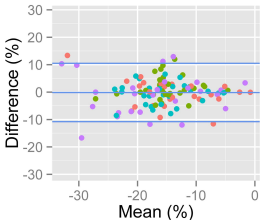
Subtricuspid



Anterior Wall



Apical



**Segment**    ● Outflow Tract    ● Free Wall    ● Angle    ● Inferior