

# Intracoronary ultrasound: current state of the art

Peter P Kearney, Ian R Starkey, George R Sutherland

For the last 30 years, coronary angiography has been the definitive method of evaluating coronary artery anatomy. The introduction of percutaneous coronary revascularisation and the growing appreciation of the pathophysiological and prognostic importance of arterial wall morphology have led to the realisation that angiography is inherently limited in defining the distribution and extent of coronary wall disease and in accurately measuring irregular lumina. Intravascular ultrasound has been developed in direct response to these demands and after a period of technical evolution now offers a highly informative complementary method of imaging the coronary arteries.

## Technical considerations

Intravascular imaging creates complex new demands in transducer design and manufacture, but despite this a range of effective miniaturised transducers has been developed which can be used to image vessels of  $\leq 1.0$  mm internal lumen diameter. The necessary reduction in transducer size decreases both power output and sensitivity, and in addition reduces the length of the "near field" where beam width and hence lateral resolution is stable. Fortunately, lateral resolution is proportional to transducer diameter and improves within the near field as transducer size decreases. The near field is lengthened by increasing transmitter carrier frequency. The limited power and sensitivity of the miniaturised transducer and greater attenuation of higher frequency signals is mitigated by low attenuation and effective acoustic coupling in the blood filled lumen and the short distances interrogated.

Both mechanical and solid state transducers have been developed, with each transducer type having specific strengths and weaknesses. Mechanical transducers operate at higher frequencies, provide better resolution, and have been miniaturised to a greater extent than their solid state counterparts. On the other hand, electronic systems do not suffer from the rotation angle artefact that arises from non-uniform transducer rotation. Imaging with solid state transducers is devoid of guidewire and strut shadow artefacts as the transducers are arranged circumferentially on the catheter surface. Theoretically, combination imaging/therapeutic devices may more easily be configured without moving parts or a drive shaft. The image quality delivered by both types of transducer has improved very significantly in the last two years, and further refinements are anticipated.

## Ultrasonic appearance of the normal arterial wall

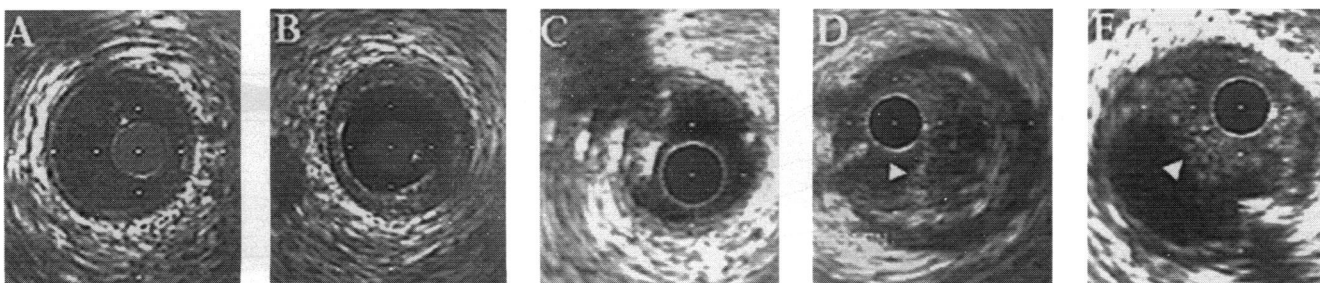
Arteries may be categorised on the basis of the histology of the media. The larger, central components of the arterial tree (aorta, carotids, common iliac and pulmonary arteries) are "elastic" arteries, so called because their media is composed of sheets of smooth muscle cells separated by multiple lamellae of elastin and collagen. On the other hand, connective tissue is relatively sparse in "muscular" arteries, such as the external iliac, femoral, renal, mesenteric, and coronary arteries. Identification of the outer border of the vessel with ultrasound depends on the presence of an ultrasonic interface between the outer layers of the vessel wall.<sup>1</sup> The media of muscular arteries appears as a distinct hypoechoic layer, sandwiched between the relatively more echodense intima and adventitia, giving rise to the so called three layer appearance (fig 1A).<sup>2,3</sup> A high concentration of smooth muscle cells in the adventitia or fibrous degeneration of the media may lead to ultrasonic homogeneity and a poorly delimited outer border in muscular arteries.<sup>4</sup> The outer border of elastic arteries is usually ill defined because of the high echogenicity of the elastic media and absence of an acoustic interface, unless provided by hypoechoic adventitia composed of loose connective tissue.<sup>3</sup>

Medial thickness is thus difficult to assess with intracoronary ultrasound. The thickness of the inner echogenic layer, conventionally interpreted as intima, correlates more closely with the combined thickness of intima and media, possibly because of collagen accumulation within the media.<sup>5</sup> Trailing edge "blooming" of echoes from the highly reflective internal elastic lamina also increases the width of intimal echoes. Conversely, the width of the media may be overestimated by limited grey scale assignation in ultrasound systems with a narrow dynamic range, leading to an artefactually wide sonolucent zone deep to the intimal leading edge.<sup>6</sup> In normal coronary arteries in young subjects, in which intimal thickness is less than the resolving power of the imaging system, the intima may not be visible.<sup>7</sup>

## Vessel and plaque area measurement

In view of the difficulties encountered in identifying the inner border of the media, vessel cross sectional area is best measured by tracing the outer perimeter of the echolucent layer (the so called external elastic lamina area), to encompass intima + media and lumen area.

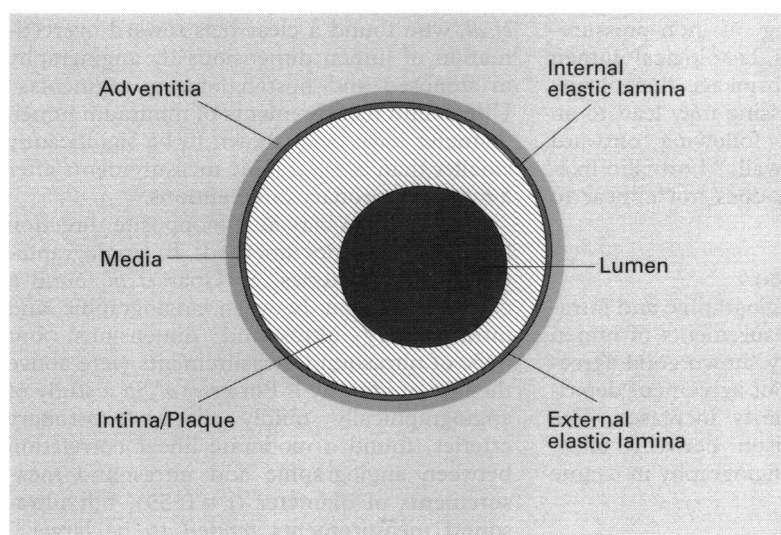
Department of  
Cardiology, Western  
General Hospital,  
Crewe Road South,  
Edinburgh EH4 2XU  
P P Kearney  
I R Starkey  
G R Sutherland  
Correspondence to:  
Dr P P Kearney.



**Figure 1** (A) Normal arteries are circular, and usually have a thin intimal leading edge giving rise to a “three layer” appearance. (B) Moderately echodense circumferential intimal thickening is evident. This appearance corresponds to plaques composed of fibrous tissue and smooth muscle cells. (C) Calcium is distinguished by a highly echodense leading edge and distal acoustic shadowing. In this image a small eccentric calcific plaque is seen from 7 to 11 o’clock with characteristic reverberations radiating outward within the acoustic shadow. (D) Lipid accumulations or “atheroma” may be identified as echolucent zones within the body of a plaque. In this unstable lesion, a semilunar echolucent area, characteristic of a lipid pool, is evident within a large eccentric plaque (11 to 7 o’clock). The catheter blank occupies much of a small eccentrically placed lumen (7 to 11 o’clock) which is separated from the lipid pool by a thin fibrous cap (arrow head). (E) Intracoronary thrombus may have a granular finely speckled ultrasound appearance. This patient with an impending infarction due to thrombotic subtotal occlusion of the mid right coronary artery had reaccumulation of thrombus (seen here separating the catheter blank from the remainder of a large lumen) after intracoronary thrombolytic therapy.

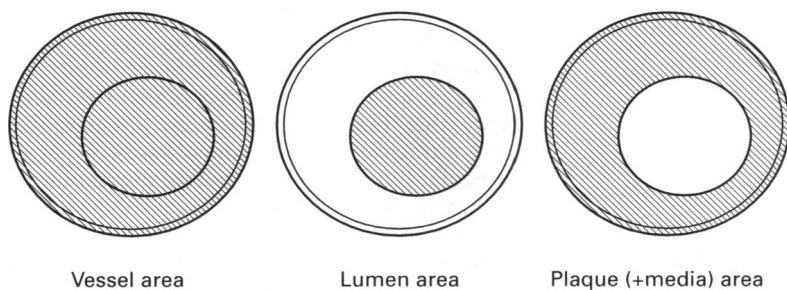
“Plaque”, “lesion”, or “intimal” cross sectional area is calculated from the difference of vessel and lumen areas (fig 2). The vessel cross sectional area stenosis (intima + medial area divided by vessel area  $\times 100$ ) measured from intracoronary ultrasound images or histological sections is inherently different from angiographically assessed “percentage stenosis”, an expression of luminal narrowing at the stenosis

relative to interpolated or reference segment lumen dimensions. The relationship between lumenographic and tomographic percentage stenosis is neither linear nor predictable because of the diffuse nature of coronary atherosclerosis (up to 40% of angiographically normal “reference” segments of vessels undergoing intervention is occupied by plaque<sup>8,9</sup>) and because of adaptive vessel enlargement at the site of disease.<sup>10</sup> Both factors diminish the focal impact of atherosclerotic wall thickening on lumen dimensions and may account for the poor correlation noted between intracoronary ultrasound and angiographic percentage stenosis narrowing (fig 3).<sup>11,12</sup>



**The quantitative accuracy of intravascular ultrasound**

Studies in phantoms and comparisons with histology have confirmed the accuracy of intravascular ultrasound measurements. Several comparative studies have shown that direct measurement of lumen dimensions with intravascular ultrasound may disclose significant overestimation of lumen size by angiography. As outlined below, the data in this regard are far from consistent, and require further clarification (table 1).



**Figure 2** Upper panel: A diagram of the arterial wall structure. Lower panel: Examples of intravascular ultrasound measurements of vessel, lumen, and plaque cross sectional area. Vessel cross sectional area is measured by tracing the outer perimeter of the echolucent layer (media), corresponding with the course of the external elastic lamina. The perimeter of the blood/intima interface is traced to measure the cross sectional area of the lumen. “Plaque”, “lesion”, or “intima” cross sectional area is calculated from the difference between vessel and lumen areas.

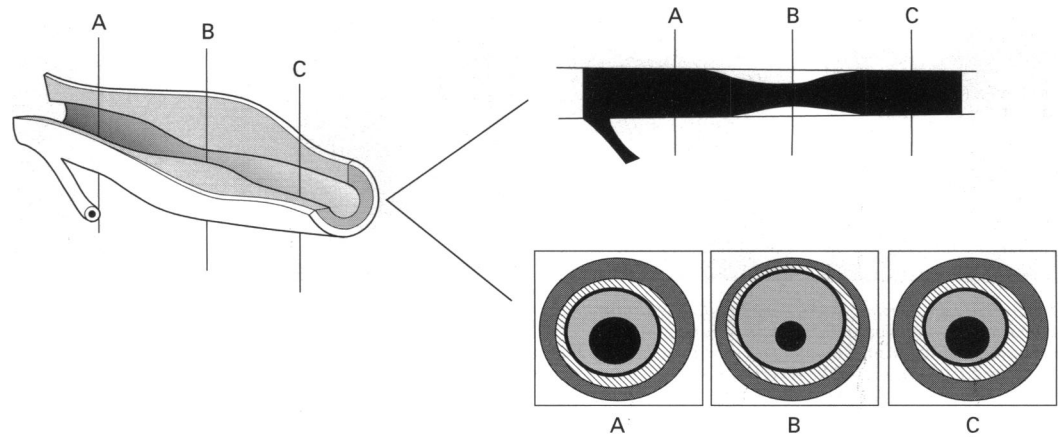
**IN VITRO PHANTOM CORRELATIONS**

In vitro ultrasound measurements of cylindrical phantoms of known dimensions are highly accurate, although non-coaxial alignment of the catheter (not eccentric coaxial alignment) leads to geometrically predictable overestimation of lumen size.<sup>3</sup> A further study has shown that intracoronary ultrasound measurements of irregularly shaped phantom lumens are more accurate and smaller than quantitative angiographic measurements and correlate better with measured flow rates.<sup>19</sup>

**IN VITRO HISTOLOGICAL CORRELATIONS**

Ultrasound and histological measurements of lumen area, vessel area, and plaque area correlate closely<sup>3,4,20</sup> but correlation alone fails to convey the direction and extent of any measurement bias that exists. A more informative

**Figure 3** Left panel: A schematic illustration of a focally stenosed coronary arterial segment. Line A transects the proximal lumen, B the point of minimum lumen dimensions, and C the distal lumen. Right upper panel: The angiographic appearance of the same vessel with lines A and C transecting the "normal" reference segments against which the diameter stenosis is evaluated by either caliper or automated edge detection systems. In the right lower panel, intravascular ultrasound (IVUS) shows considerable intimal thickening at points A and C, and vessel cross sectional area expansion at the point of focal luminal stenosis B. Both factors explain the discrepancy between the > 90% vessel cross sectional area stenosis measured by IVUS and the angiographically derived calculated lumen cross sectional area stenosis of 70% between points A/C and B.



measure of agreement was applied by Anderson *et al.*,<sup>21</sup> who found that the intravascular ultrasound device markedly overestimated lumen area. The bias could not be accounted for by a small calibration error or tissue shrinkage and may have arisen from the narrow dynamic range and limited image quality of the ultrasound system employed in the study. Even when using state of the art scanning equipment, exact comparison of ultrasound and histology measurements is limited by technical factors. Geometric distortion following sectioning of non-pressure-perfused vessels reduces histological lumen area. Significant tissue shrinkage that occurs during histological processing may lead to an increase in lumen size following outward radial contraction of the wall.<sup>20</sup> Formalin fixation, on the other hand, does not appear to affect vessel dimensions.<sup>20</sup>

#### ANGIOGRAPHIC CORRELATION

Comparisons between angiographic and intracoronary ultrasound measurements of lumen dimensions have generally shown good agreement in normal vessels, but agreement deteriorates as lumen irregularity increases. The first systematic comparison between ultrasound and quantitative angiography in canine

peripheral arteries showed a close correlation for lumen dimensions that worsened after balloon angioplasty. Ultrasonically measured lumen dimensions tended to be slightly smaller, particularly after angioplasty.<sup>13</sup> The same group found that the correlation between ultrasound and angiography was excellent in the circular lumina of normal human arteries, but deteriorated in diseased, eccentric lumina, where again ultrasound dimensions were smaller.<sup>15</sup> Similar findings have recently been reported by De Scheerder *et al.*, who found a clear bias toward overestimation of lumen dimensions by angiography in stenosed and postangioplasty segments.<sup>14</sup> Ultrasound measurements of minimum lumen diameter have been shown to be significantly smaller than angiographic measurements after a range of coronary interventions.<sup>22</sup>

A systematic bias in the opposite direction has also been documented. In angiographically normal arteries, St Goar *et al* found a close correlation between angiographic and intracoronary ultrasound dimensions, but 83% of ultrasound measurements were above the line of identity.<sup>16</sup> Porter *et al.*, in a study of angiographically mildly diseased coronary arteries, found a moderate linear correlation between angiographic and ultrasound measurements of diameter ( $r = 0.59$ ), but ultrasound measurements tended to be larger.<sup>12</sup> Tobis *et al* found a poor correlation between intracoronary ultrasound and angiographic measurements for normal reference segments ( $r = 0.26$ ) which further deteriorated after angioplasty ( $r = 0.12$ ).<sup>11</sup> Although frequently cited as an example of the marked discrepancy that may occur between angiographic and intracoronary ultrasound assessments of irregular lumina, the ultrasound measurement of lumen area at the angioplasty site was 33% larger than lumen area calculated from angiographic diameters. A similar pattern has been reported in several later intracoronary ultrasound studies of different coronary interventions.<sup>18 23 24</sup> Possible explanations for this bias are listed in table 2.

#### QUALITATIVE VALIDATION

In an early *in vitro* study, Gussenhoven *et al* noted that different plaque constituent tissue

**Table 1** *In vivo* correlations of ultrasound and angiographic lumen diameter measurement. Values are means (SD)

Reference	Correlation coefficient	Direction of bias	Minimum diameter (mm)	
			IVUS	Angiography
		<i>"Normal segments"</i>		
Nissen, <i>et al</i> <sup>13†</sup>	0.98	IVUS < angio	5.6	5.7
De Scheerder <sup>14</sup>	0.92	IVUS < angio	3.5 (0.7)	3.6 (0.7)
Nissen, <i>et al</i> <sup>15</sup>	0.92	IVUS < angio	2.88 (0.57)	2.83 (0.52)
Tobis, <i>et al</i> <sup>8</sup>	0.26	IVUS > angio	3.0 (1.1)	3.0 (1.0)
St Goar, <i>et al</i> <sup>16</sup>	0.86	IVUS > angio	3.8 (0.9)	3.4 (0.8)
		<i>Diseased segments</i>		
De Scheerder <sup>14</sup>	0.47	IVUS < angio	2.1 (0.4)	2.7 (0.4)
Nissen, <i>et al</i> <sup>15</sup>	0.77	IVUS < angio	3.11 (0.76)	3.17 (0.83)
Mintz, <i>et al</i> <sup>17</sup>	0.83	IVUS > angio	1.6 (0.6)	1.1 (0.8)
Port, <i>et al</i> <sup>12</sup>	0.59	IVUS > angio	3.3 (0.9)	2.7 (0.8)
		<i>Postintervention</i>		
De Scheerder <sup>14</sup>	0.28	IVUS < angio	1.9 (0.3)	2.1 (0.5)
Nissen, <i>et al</i> <sup>13†</sup>	0.86	IVUS ≤ angio	6.7	6.6
Tobis, <i>et al</i> <sup>8</sup>	0.12	IVUS > angio	2.2 (0.6)	1.9 (0.5)
Davidson, <i>et al</i> <sup>18</sup>	0.28	IVUS > angio	—	—

IVUS = intravascular ultrasound

†Canine peripheral arteries. All other studies were performed in living human subjects.

Table 2 Possible explanations for discrepancy between angiographic and ultrasound measurements

Angiographic underestimation of lumen diameter
False lumen (dissection) not incorporated into angiographic measurement of diameter
Reduced contrast density at wall/lumen interface as a result of non-laminar flow
IVUS overestimation of lumen dimensions
Low dynamic range leading to weak intimal signal dropout
Scanner miscalibration
Rotation angle artefact in eccentrically positioned catheters
Non-coaxial alignment of catheter within the vessel (rare in the coronary arteries)
Direct splinting of disrupted vessel wall by catheter
Indirect splinting of vessel wall (increased intraluminal pressure and wall tension)
Observer bias (selection of minimum lumen diameter is operator dependent and unstandardised)

IVUS = intravascular ultrasound.

types appeared to have distinctive ultrasonic characteristics.<sup>2</sup> Lipid deposits were hypo-echoic fibromuscular lesions and fibrous lesions of intermediate echogenicity, and calcium was brightly echogenic with distal acoustic shadowing (fig 1, B-D). Subsequent studies have confirmed that grey scale levels do correspond with tissue type, but with variable sensitivity and specificity (table 3). The sensitivity for lipid deposits may be reduced by echogenic inclusions, and the specificity may be reduced by a narrow system dynamic range, giving rise to a subintimal echolucent zone regardless of tissue type.<sup>6</sup> Ultrasonic identification of lipid or calcification is also dependent on the radial thickness of the deposits, which must be more than 0.25 mm to be detectable.<sup>25</sup> Intra-arterial thrombus has been reported to produce "granular" echoes of variable echodensity (fig 1E)<sup>27</sup> and bright, finely speckled echoes,<sup>28,29</sup> although the pattern appears to be neither sensitive<sup>26</sup> nor specific.<sup>29a</sup> Platelet-rich thrombi are echolucent, in contrast to whole blood thrombi which generate a characteristic fine speckled ultrasonic appearance.<sup>30</sup>

#### REPRODUCIBILITY

The short term reproducibility of intracoronary ultrasound measurements appears to be high, particularly for the measurements that can be obtained directly.<sup>31</sup> Medium and long term variability has not been examined and must be established before this technique is confidently applied to the study of restenosis, arterial remodelling, and the effects of lipid lowering therapy. The development of a reproducible method of longitudinal orientation within the vessel is a prerequisite for min-

imising interstudy quantitative variability. The qualitative reproducibility of intracoronary ultrasound identification of tissue type and the mechanisms of angioplasty (including vessel wall tears, dissections, stretch, or "compression") is also largely unknown. Better image quality, objective methods of tissue characterisation, and the application of widely accepted definitions are important factors in minimising variability.

#### Safety and feasibility

Reports to date indicate that despite its invasive nature, intracoronary ultrasound imaging is associated with only a minor incidence of complications. Of 2207 studies performed in 22 centres, 92% of cases were free of complications and the commonest event was vasospasm, reported in 2.9% of cases.<sup>32</sup> Other procedural events attributable to the use of intracoronary ultrasound, including dissection, thrombosis, embolisation, and acute occlusion, occurred in 0.3% of cases, and major complications (myocardial infarction and emergency coronary artery bypass graft) in 0.1%. Procedural and major complications of doubtful relationship to intracoronary ultrasound occurred in 0.4% and 0.2% of cases respectively. Events were commoner in patients with unstable angina or acute myocardial infarction, but neither centre experience nor catheter size appeared to influence the rate of complications. Quantitative angiographic follow up of patients who have undergone intracoronary ultrasound examination for assessment of transplant artery status revealed no evidence to suggest accelerated intimal thickening in instrumented vessels.<sup>33</sup>

#### Angiographically "normal" arteries

Coronary angiography is an insensitive method for detecting early atheromatous thickening of the arterial wall, partly because of vascular remodelling that allows plaque to occupy an average of 40% of coronary vessel cross section before luminal encroachment occurs. This phenomenon of so called "Glagovian" adaptive enlargement has been documented in vivo using intracoronary ultrasound<sup>34</sup> and in the same study, vessel area was found to be greater at the site of focal luminal stenoses than in proximal segments. The plaque burden in the so called "normal reference segments" of vessels undergoing coronary intervention averages 35–40%.<sup>8,9</sup> Angiographically normal or near normal left main coronary arteries are also commonly diseased. Atherosclerotic plaques were evident in 90% of a series of patients undergoing percutaneous coronary intervention<sup>35</sup> and in 45% of a mixed series undergoing diagnostic and postinterventional study.<sup>36</sup> It must be remembered that the epidemiology of coronary disease is largely based on the number of vessels in which "significant" (> 50% lumen diameter reduction) luminal stenoses have been angiographically documented and that the prognostic significance of non-obstructive

Table 3 In vitro comparisons between intravascular ultrasound tissue characterisation and histology

Study	Tissue	Sensitivity	Specificity
Potkin, <i>et al</i> <sup>20</sup>	Lipid	78% (7/9)	97% (100/103)
	Fibrous	96% (81/84)	93% (26/28)
	Calcific	100% (19/19)	100% (93/93)
DiMario, <i>et al</i> <sup>4</sup>	Lipid plaque	89% (32/36)	97% (62/64)
	Fibrous plaque	67% (32/48)	100% (52/52)
	Calcium	97% (35/36)	98% (63/64)
Peters, <i>et al</i> <sup>25</sup>	Lipid deposits	46% (16/35)	97% (67/69)
	Calcific deposits	77% (20/26)	100% (78/78)
Siegel, <i>et al</i> <sup>26</sup>	Normal	100% (12/12)	95% (58/61)
	Stable atheroma	100% (18/18)	90% (52/58)
	Disrupted intima	84% (26/31)	96% (44/46)
	Thrombus	57% (8/14)	90% (51/57)

plaques in vessels which have adaptively enlarged has yet to be established.

### Coronary wall pathology

#### CORONARY WALL MORPHOLOGY

Intravascular ultrasound characterises vessel wall morphology more accurately than angiography. Calcification is evident approximately twice as often on ultrasound as on fluoroscopy (76% *v* 48%<sup>37</sup>). Lesion eccentricity is seen in 77% of lesions with ultrasound (a figure similar to that documented at necropsy), in contrast to one third of angiographic stenoses.<sup>38 39</sup>

#### CARDIAC ALLOGRAFT ARTERIOPATHY

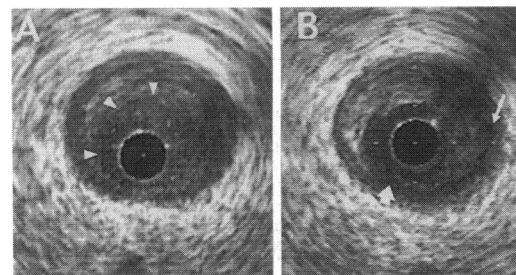
Allograft arteriopathy is the major cause of late cardiac transplant failure, but in its early stages luminal compromise is absent or too diffuse to be angiographically evident. Intravascular ultrasound is superior to angiography in determining the presence of graft arteriopathy.<sup>40</sup> Even when minimal irregularities on angiography were considered abnormal, intimal thickening was seen in twice as many patients on ultrasound (34%) as had angiographically evident disease (15%). Studies of vasomotion<sup>41-44</sup> and combined cross sectional and Doppler ultrasound studies<sup>42 43</sup> following pharmacological provocation have been used to correlate the morphology and function of allograft arteries.

#### ACUTE CORONARY DISEASE

Intracoronary ultrasound is well suited to the *in vivo* study of acute coronary lesion morphology. Plaque rupture has been identified with the technique following myocardial infarction,<sup>45</sup> and echolucent zones—possibly indicative of lipid deposits—occur more frequently in acute than in stable coronary lesions and are a more sensitive indicator of instability than angiographic criteria.<sup>9</sup> A configuration of echo markers specific for unstable angina and highly suggestive of mural thrombus has been found on preinterventional imaging of unstable lesions.<sup>46</sup> These consist of a fine echodense line running circumferentially within the lesion, suggesting an acoustic interface between thrombus and the underlying plaque, and close conformation of the new lumen shape after intervention with the inner layer, delimited by the line present before intervention (fig 4).

#### CORONARY VASOMOTOR FUNCTION

The vasomotor activity of the coronary arteries is readily assessed by real time tomographic measurement of lumen area change.<sup>47</sup> In combination with intracoronary Doppler, absolute coronary flow can be calculated and the differential effects of therapeutic agents on conductance and resistance vessels studied.<sup>42 48</sup> The degree of change in lumen cross sectional area during the cardiac cycle is a measure of vessel wall distensibility. Increasing intimal thickness in coronary arteries correlates in a non-linear fashion to reduced distensibility, and following balloon angioplasty and direc-



*Figure 4 Difficulties arise in identifying intracoronary thrombus. A set of echographic markers highly suggestive of thrombus has been identified in acute coronary lesions, illustrated in this lesion before angioplasty (A) where a subtle echographic interface (arrowheads) demarcates an inner layer of probable thrombus. Angioplasty resulted in remodelling or displacement of the layer, producing considerable lumen enlargement in the absence of significant vessel stretch (B). The plaque has torn at its thinnest point (large arrow) and a subintimal dissection runs counterclockwise from 6 to 3 o'clock (as far as the small arrow).*

tional atherectomy the distensibility of heavily diseased vessel segments is comparable to normal vessels and greater than mildly diseased segments.<sup>49</sup>

### The study of coronary interventions

#### PERCUTANEOUS BALLOON ANGIOPLASTY

Until the introduction of intracoronary ultrasound, *in vivo* study of coronary balloon angioplasty had been thwarted by the limitations of angiography in documenting changes within the vessel wall. Although necropsy data suggest a central role for intimal and medial dissection in successful angioplasty, dissections are evident on angiography in only 20–30% of cases. Angiographic dissection has been found to correlate with both lower<sup>50</sup> and higher<sup>51</sup> rates of restenosis, and one study showed no apparent effect.<sup>52</sup> The confusion may in part be related to the limitations of angiography in detecting, characterising, and quantitating dissections and also to the heterogeneity of angiographic appearances after percutaneous transluminal angioplasty (PTCA) that are described by the term “dissection”. Plaque tears are identified twice as often by ultrasound as by angiography.<sup>18 38</sup> Detailed geometric analysis of intracoronary ultrasound images of plaques before dilatation can identify stress points where plaque rupture is likely to occur<sup>53</sup> and the size and location of dissections relates to the presence of calcification, probably as a result of increased local shear stress at the junction of compliant and non-compliant plaque components.<sup>54</sup> The positive contribution of dissection to lumen gain is supported by data documenting a 30% greater increase in lumen area in lesions with tears than in those that appear to have a smooth walled dilatation.<sup>38</sup> Perinterventional imaging using a combination balloon/intravascular ultrasound catheter in peripheral vessels has shown that plaques began to tear at low inflation pressure ( $\leq 2$  atmospheres) and that elastic recoil (averaging 30%) occurs almost immediately after balloon deflation.<sup>55</sup>

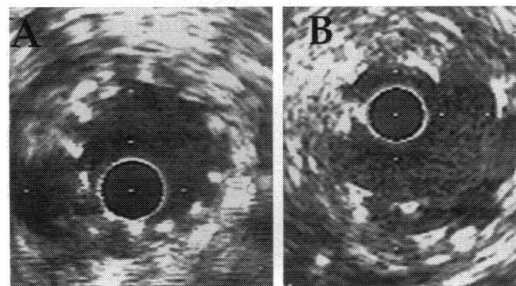
Plaque fracture does not lead to an increase in lumen area unless a concomitant increase in overall vessel size (vessel expansion) or decrease in plaque area (compression, axial remodelling, or displacement) occurs. Vessel expansion or stretch is operative in most cases of coronary angioplasty, and plaque area reduction appears to play a minor role<sup>56</sup> with the possible exception of unstable lesions.<sup>46</sup> In contrast, plaque compression appears to be the major contributor to lumen gain in peripheral vessels.<sup>57</sup>

The proportion of patients reported to have dissections after angioplasty is very variable, ranging from 41%<sup>18</sup> to 83%.<sup>58</sup> Technical and methodological factors contribute to the variable findings between studies. False positive identification of dissection may arise from a limited dynamic range<sup>6</sup> and dissections may be missed because of calcific shadowing,<sup>59</sup> an unfavourable angle of incidence,<sup>60</sup> or wall wrapping by the imaging catheter. No definitions for plaque tear, rupture, fissure, or dissection are uniformly applied, although two classifications of intracoronary ultrasound morphology after angioplasty have been proposed.<sup>61, 62</sup> Categorical classification of morphology on the basis of findings in one tomographic slice within the lesion is convenient but fails to take into account the longitudinal extent or the variability of changes within the lesion, and the reproducibility of these classifications is not documented. Three dimensional reconstruction will redress some of these shortcomings by providing axial as well as cross sectional assessment, volumetric analysis, and a reproducible means of matching segments before and after intervention.

Preliminary ultrasound data concerning mechanisms of restenosis suggest that contrary to prevailing beliefs chronic remodelling and recoil of the arterial wall may account for the major part of late loss of early lumen gain.<sup>63</sup>

#### CORONARY STENTS

The metallic struts or coils of intracoronary stents are poorly visualised on fluoroscopy but are easily seen with ultrasound. Confirmation of full stent expansion and complete apposition of struts against the vessel wall, as well as

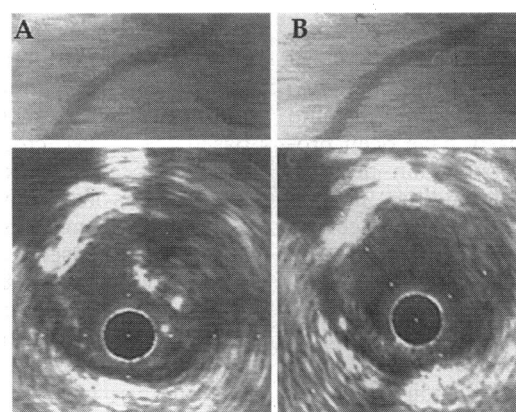
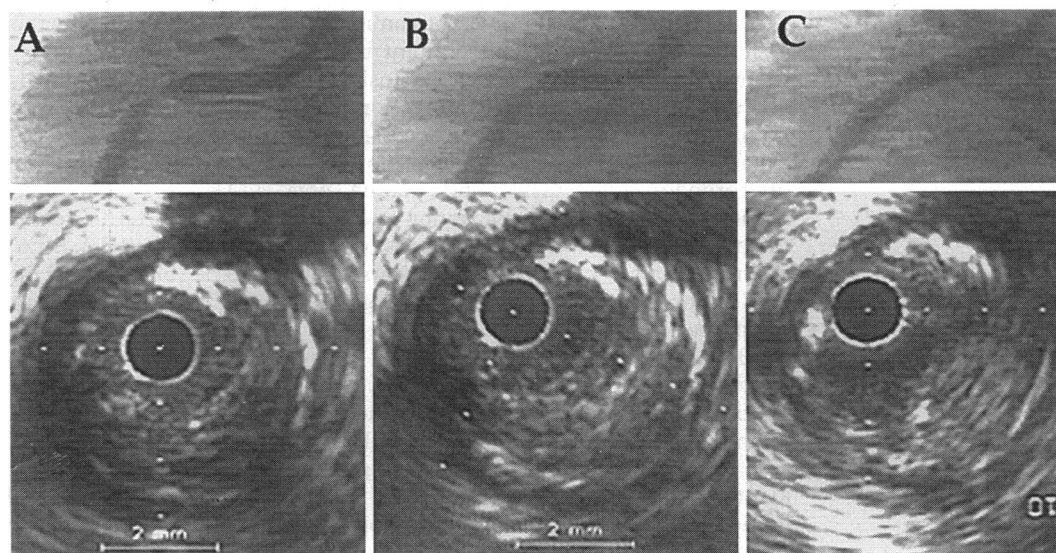


*Figure 5 The metallic struts of coronary stents are difficult to visualise on fluoroscopy but are readily seen with ultrasound. In A the struts, evident as point echodensities, are arranged symmetrically around the endoluminal surface, are fully apposed to the vessel wall and the lumen is circular. An eccentric plaque is seen outside the stent from 6 to 12 o'clock. In contrast, the struts of the stent in B are asymmetrically and incompletely apposed to the wall of the vein graft in which it is inserted.*

accurate sizing of the balloon and positioning of the stent with respect to the lesion or dissection membrane is afforded by ultrasonic guidance (fig 5). A recent observational study has reported the acute outcome of stent insertion guided by intracoronary ultrasound.<sup>64</sup> Despite angiographic success (comparable in absolute terms to that documented in previous stent trials), 80% of lesions were adjudged to be suboptimally dilated by ultrasound criteria and underwent repeat dilatation at higher pressures or with larger balloons. Minimum intrastent cross sectional area increased by one third following repeat dilatation. An equivalent increase in angiographic minimum lumen diameter (MLD) of 14% was evident on postprocedural quantitative angiography and reduction of residual stenosis from 9% to -4%, but importantly angiographic measurements were larger than intracoronary ultrasound measurements of minor lumen diameters. Lumen eccentricity was not significantly improved after repeat dilatation, and incomplete apposition of stent struts was infrequently documented. Sizing decisions based on vessel cross sectional area have recently been abandoned by this group of investigators in favour of reference to lumen area proximal and distal to the lesion, since reference to vessel area in compensated segments may lead to balloon oversizing with adverse consequences.

Mudra *et al*<sup>65</sup> found a substantial overestimation of minimum lumen diameter by quantitative coronary angiography relative to intracoronary ultrasound measurements both after initial stent insertion and after further dilatation as a result of lumen eccentricity and incomplete strut apposition. Minimum lumen diameter increased by 25% following ultrasound guidance. A comparison of the angiographic outcome in lesions undergoing stenting guided by intracoronary ultrasound with lesions undergoing standard stent insertion revealed a final MLD of 2.95 mm and percent stenosis of -4% in the ultrasound guided group compared to 2.56 mm and 11% respectively in the standard group.<sup>66</sup> Transient distal vessel spasm occurred more frequently in the ultrasound guided group, but there was no increase in dissections or vessel wall perforation.

Despite these encouraging results, neither acute nor long term clinical outcome has been shown to be improved by ultrasound guidance of stent insertion. Larger intrastent dimensions and absence of intrastent stenosis provides the rheologic conditions that may reduce subacute thrombosis and possibly restenosis rates. A strategy of dispensing with anticoagulation following optimal stent insertion, associated with a low incidence of thrombotic and haemorrhagic complications, has been adopted both with<sup>67</sup> and without ultrasound guidance.<sup>68</sup> A randomised trial (MUSIC) is currently underway to show whether or not anticoagulation can be replaced by aspirin therapy in cases in which optimal stent deployment has been confirmed with ultrasound.



**Figure 6** Upper panel: (A) In this patient 3 weeks after inferior wall myocardial infarction, angiography (top) revealed a tight concentric stenosis in the proximal right coronary artery. Intracoronary ultrasound at the stenosis (bottom) showed wedging of the catheter blank within a large eccentric lesion and a demarcated inner layer encircling the lumen. A focus of deep calcification is evident at 12 to 2 o'clock. (B) Following balloon angioplasty, angiography suggested a moderate result, but ultrasound showed inadequate lumen gain that appeared to be the result of vessel stretch and incomplete remodelling of the inner layer. (C) Directional coronary atherectomy gave rise to an excellent angiographic appearance (top) and although intracoronary ultrasound confirmed a doubling of lumen area, and showed a number of discrete "bites" into the plaque by the atherectomy device (3 and 6 o'clock), a residual plaque burden of > 60% of vessel cross sectional area was still present.

Lower panel: (A) Despite the excellent angiographic profile of the vessel, a discrete calcific flap was identified on ultrasound distal to the point of previous stenosis which was probably dislodged by the distal end of the atherectome. (B) A short balloon inflation tacked the flap back into place (lower panel). The angiogram was not appreciably different after wall wrapping.

There are conflicting data concerning the mechanisms of stent restenosis. Results of one study suggested that stent collapse, possibly as a result of stent strut mechanical fatigue or extraneous tissue hyperplasia, contributes more to late loss of lumen area than intimal hyperplasia.<sup>69</sup> Subsequent reports point to neointimal hyperplasia as the principal cause of late loss of lumen gain in coronary stents.<sup>70</sup> Further studies are required to clarify the issue.

#### DIRECTIONAL ATHERECTOMY

Knowledge of plaque constitution, shape, and depth should help in assessing the suitability of a lesion for directional coronary atherectomy (DCA) and to safely maximise lumen gain. Superficial calcification (at or near the endoluminal surface of the plaque) is associated with a significantly lower tissue yield than either deep calcification or no calcification. De Lezo *et al*<sup>71</sup> also found that tissue yield was lower from echogenic than from echolucent plaques, although the latter appeared to have a higher rate of subsequent angiographic restenosis. Contrary to the view that lumen gain results predominantly from lesion "dot-tering", ultrasound data suggest that plaque excision (manifest ultrasonically as plaque area reduction) is the predominant contributor to lumen enlargement.<sup>56</sup> A residual plaque burden averaging 50% of vessel area is evident

despite an angiographically successful outcome<sup>38</sup> (fig 6).

#### ROTATIONAL ATHERECTOMY

A sharply delineated, uniformly cylindrical lumen is seen with intracoronary ultrasound after rotational atherectomy.<sup>23</sup> A slightly larger lumen diameter relative to the largest burr used is attributed to off centre rotation of the burr during ablation, or to radial expansion of the vessel following a reduction in the circumferential and radial extent of vessel wall calcification. Fissures and dissections are infrequent and limited in their axial and radial extent, and the principal mechanism of lumen enlargement is selective ablation of hard plaque.<sup>72</sup>

#### Clinical utility

There is much debate on whether the great deal of new information afforded by intracoronary ultrasound will translate into demonstrable clinical benefit, a point of pressing importance as the technique is undeniably costly, has the attendant risks of an invasive procedure, and can add substantially to the

costs and duration of coronary interventions by revealing the apparent need for further intervention. The small and non-randomised investigations of the last four years conducted with earlier versions of scanning technology have not provided evidence to support an indispensable role for intracoronary ultrasound in routine clinical practice, but a number of large randomised trials designed to answer these questions are currently under way. Work published to date strongly supports the following applications of the technique.

*(1) Clarification of ambiguous angiographic appearances*

Intracoronary ultrasound is of undoubted benefit in clarifying anatomy in cases of ostial or very short "napkin ring" stenoses, and where branch overlap or lumen eccentricity obscures the area of interest.<sup>73</sup> Atheromatous plaque occupying  $\geq 50\%$  of vessel area has been found in 50% of patients with angiographically mild coronary disease,<sup>12</sup> but unless significant luminal compromise is also demonstrated its identification should not necessarily influence management, as the significance of non-obstructive atheroma remains to be established.

*(2) Decision making during coronary interventions*

In GUIDE I, imaging after PTCA (112 lesions) or DCA (46 lesions) resulted in 48% of cases in a change of therapeutic strategy (using either the same device or switching to a more appropriate device, depending on lesion morphology).<sup>38</sup> Mintz *et al* found that pre-interventional imaging influenced their subsequent therapeutic strategy in 40% of cases.<sup>17</sup> This included revascularisation of doubtful lesions in 6%, and deciding against revascularisation in 7%, while in 26% the revascularisation strategy was changed. None of these observational studies permits evaluation of the impact of intracoronary ultrasound on short or long term outcome. Nevertheless, ultrasound may prove to be indispensable to the further development and survival of the "second generation" interventional techniques, particularly directional and rotational atherectomy, to allow their targeted and cost-effective application to specific lesion types, and to maximise lumen gain.

*(3) Prediction of clinical outcome following coronary intervention*

Intracoronary ultrasound is a sensitive means of determining lesion shape, calcification, and presence of dissection, variables that are poorly characterised by angiography and have each been ascribed conflicting predictive significance in angiographic studies. The prognostic significance of these variables must be established before clinical decision making can rationally be based on ultrasound data and to this end several investigators have correlated morphological and quantitative ultrasound findings with subsequent clinical outcome. In one series of 69 patients undergoing PTCA, DCA, and excimer laser

therapy, dissections evident on ultrasound were associated with a greater likelihood of an adverse outcome (principally restenosis).<sup>74</sup> Conversely, Honye *et al* concluded that smooth walled dilatation was significantly more likely to lead to restenosis, but in this study only those who had recurrent symptoms (20%) underwent angiographic follow up.<sup>61</sup> Mintz *et al* have reported preliminary follow up of 124 patients undergoing PTCA, DCA, rotational atherectomy, stent insertion, and laser angioplasty. Angiographic restenosis (defined as a  $> 50\%$  stenosis at a six month angiographic follow up) was associated with smaller minimum lumen area after intervention, and, contrary to angiographic data, with lower rather than higher acute luminal gain, an observation consistent with the "bigger is better" hypothesis.<sup>75</sup> Calcification and dissections were also more prevalent in those who restenosed. The PICTURE and GUIDE II trials are multicentre studies that have enrolled 200 and 250 patients respectively to assess the predictive value of the morphological and quantitative findings of intracoronary ultrasound immediately after intervention. Both studies are nearing completion and it is expected that they will be reported during 1995. A small number of reference centres evaluate all balloon angioplasty procedures with ultrasound; we frequently study angiographically "hazy" lesions in which the degree of lumen gain is uncertain with intracoronary ultrasound, but as with the majority of its clinical indications formal justification for either approach is required.

*(4) Ultrasound guidance of stent insertion*

Discussed in detail in a preceding section, this is an extensively studied and particularly promising application of ultrasound. Incomplete stent expansion is frequently revealed allowing an informed approach to safely maximising the stent cross sectional area with the appropriately sized (diameter and length) balloon. In the absence of outcome data, we routinely perform ultrasound before and after stent insertion, although a more selective approach in cases of uncertain angiographic appearances may prove sufficient. In the ASSURE trial (Adjunctive Stenting in Suboptimal Ultrasound Result) we are randomising all patients with angiographically successful angioplasty but incomplete dilatation by ultrasound criteria to either stenting or no further intervention as a potential strategy to reduce restenosis with selective stenting.

### Future developments

Three dimensional reconstruction is an important new development that is separately addressed in this supplement by Di Mario *et al*. Establishing a means of accurate longitudinal orientation within the vessel is critical to the issue of the long term reproducibility of intracoronary ultrasound quantitation. Transducers are undergoing further miniaturisation (a 0.021 inch imaging guidewire is being developed) and efforts to produce more



effective focused transducers are underway. A micromotor has been manufactured to allow combination of the advantages of mechanical single element transducers with optimal catheter shaft characteristics, and to eliminate rotation angle artefacts. The feasibility of forward look imaging has been tested with a prototype 4.0 mm diameter forward looking catheter that provides B mode images up to 2.0 cm in front of the catheter tip.<sup>76</sup> Radio frequency signal based tissue characterisation is being actively researched by several groups, and if successful would objectify important elements of image interpretation and could form the basis of an automated system of lesion quantitation. Therapeutic combination devices (balloon or atherectomy + imaging catheters) are already available, but their widespread application awaits demonstration of the clinical value of stand alone intracoronary ultrasound in the current set of clinical trials.

### Conclusions

Intravascular ultrasound is a method of imaging that provides unique information concerning vascular morphology and function. It has already taught us a great deal about the mechanisms of coronary interventional procedures and promises to revolutionise our understanding of the process of restenosis. The changes that occur in allograft arteriopathy and coronary atheroma during lipid lowering therapy are currently under intensive investigation with intracoronary ultrasound, promising to afford more effective preventive and therapeutic strategies. The precise role of intravascular ultrasound in clinical practice is currently being assessed in multicentre trials that will be reported in the near future. Its incorporation into regular practice is dependent on a convincing demonstration of cost-effectiveness and clinical value. Improvements in image quality and catheter design now appear to be reaching a plateau, with similar image quality being offered by different systems. A problem which remains is the lack of a common terminology that should be addressed by consensus agreement on standard definitions of the morphological and quantitative variables encountered in intravascular ultrasound imaging. Likely future developments include three dimensional reconstruction, the ability to characterise wall constituents better using radio frequency data, and combination with Doppler analysis to enable full characterisation of the functional status of the artery. On the basis of preliminary experience, it would appear that intravascular ultrasound is likely to become an integral part of the assessment and treatment of coronary artery disease.

- 1 Pignoli P, Tremoli E, Poli A, Oreste P, Paoletti R. Intimal plus medial thickness of the arterial wall; a direct measurement with ultrasound imaging. *Circulation* 1986; 74:1399-406.
- 2 Gussenhoven E, Essed C, Lancée C, Mastik F, Frietman P, van Egmond F, et al. Arterial wall characteristics determined by intravascular ultrasound imaging: an in vitro study. *J Am Coll Cardiol* 1989;14:947-52.
- 3 Nishimura RA, Edwards WD, Warnes CA, Reeder GS, Holmes DR, Tajik AJ, et al. Intravascular ultrasound imaging: in vitro validation and pathologic correlation. *J Am Coll Cardiol* 1990;16:145-54.
- 4 DiMario C, The S, Madretsma S, von Suylen R, Wilson R, Bom N, et al. Detection and characterization of vascular lesions by intravascular ultrasound: an in vitro study correlated with histology. *J Am Soc Echocardiogr* 1992;5:135-46.
- 5 Porter TR, Radio SJ, Anderson JA, Michels A, Xie F. Composition of coronary atherosclerotic plaque in the intima and media affects intravascular ultrasound measurements of intimal thickness. *J Am Coll Cardiol* 1994;23:1079-84.
- 6 Fitzgerald PJ, Briskeen AF, Brennan JM, Hargrave VK, MacGregor JS, Yock PG. Errors in ultrasound image interpretation and measurement due to limited dynamic range (abstr). *Circulation* 1991;84:II-438.
- 7 Fitzgerald P, St Goar F, Connolly A, Pinto F, Billingham M, Popp R, et al. Intravascular ultrasound imaging of coronary arteries. Is three layers the norm? *Circulation* 1992;86:154-8.
- 8 Tobis JM, Mallery J, Gessert J, Griffith J, Mahon D, Bessen M, et al. Intravascular ultrasound cross-sectional arterial imaging before and after balloon angioplasty in vitro. *Circulation* 1989;80:873-82.
- 9 Hodgson J, Reddy D, Suneja R, Nair R, Lesnefsky E, Sheehan H. Intracoronary ultrasound imaging: correlation of plaque morphology with angiography, clinical syndrome and procedural results in patients undergoing coronary angioplasty. *J Am Coll Cardiol* 1993;21:35-44.
- 10 Glagov S, Weisenberg E, Zarins C, Stankunavicius R, Kolletis G. Compensatory enlargement of human atherosclerotic arteries. *N Engl J Med* 1987;316:1371-5.
- 11 Tobis JM, Mallery J, Mahon D, Lehmann K, Zalesky P, Griffith J, et al. Intravascular ultrasound imaging of human coronary arteries in vivo. Analysis of tissue characterization in comparison with in vitro histological specimens. *Circulation* 1991;83:913-26.
- 12 Porter TR, Sears T, Xie F, Michels A, Mata J, Welsh D, et al. Intravascular ultrasound study of angiographically mildly diseased coronary arteries. *J Am Coll Cardiol* 1993;22:1858-65.
- 13 Nissen SE, Grines CL, Gurley JC, Sublett K, Haynie D, Diaz C, et al. Application of a new phased array ultrasound imaging catheter in the assessment of vascular dimensions. In vivo comparison to cineangiography. *Circulation* 1990;81:660-6.
- 14 De Scheerder I, De Man F, Herregods MC, Wilczek K, Barrios L, Raymenants E, et al. Intravascular ultrasound versus angiography for measurement of luminal diameters in normal and diseased coronary arteries. *Am Heart J* 1994;127:243-51.
- 15 Nissen SE, Gurley JC, Grines CL, Booth DC, McClure R, Berk M, et al. Intravascular ultrasound assessment of lumen size and wall morphology in normal subjects and patients with coronary artery disease. *Circulation* 1991; 84:1087-99.
- 16 St Goar F, Pinto F, Alderman E, Fitzgerald P, Stadius M, Popp R. Intravascular ultrasound imaging of angiographically normal coronary arteries: an in vivo comparison with quantitative angiography. *J Am Coll Cardiol* 1991;18:952-8.
- 17 Mintz GS, Pichard AD, Kovach JA, Kent KM, Satler LF, Javier SP, et al. Impact of preintervention intravascular ultrasound imaging on transcatheter treatment strategies in coronary artery disease. *Am J Cardiol* 1994;73: 423-30.
- 18 Davidson CJ, Sheikh KH, Kisslo KB, Phillips HR, Peter RH, Behar VS, et al. Intracoronary ultrasound evaluation of interventional technologies. *Am J Cardiol* 1991; 68:1305-9.
- 19 Moriuchi M, Goffon IL, Begman A, Griffith J, Tobis JM. Anatomic and functional assessment of stenosis severity with intravascular ultrasound imaging in vitro. *Am J Cardiac Imaging* 1992;6:109-16.
- 20 Potkin BN, Bartorelli AL, Gessert JM, Neville RF, Almagor Y, Roberts WC, et al. Coronary artery imaging with intravascular high-frequency ultrasound. *Circulation* 1990;81:1575-85.
- 21 Anderson MH, Simpson IA, Katritsis D, Davies MJ, Ward DE. Intravascular ultrasound imaging of the coronary arteries: an in vitro evaluation of measurement of area of the lumen and atheroma characterisation. *Br Heart J* 1992;68:276-81.
- 22 DeFranco A, Tuzcu EM, Moliterno DJ, Elliott J, Berkalp B, Franco I, et al. Overestimation of lumen size after coronary interventions: implications for randomised trials of new devices. *Circulation* 1994;abstract supplement.
- 23 Mintz GS, Potkin BN, Keren G, Satler LF, Pichard AD, Kent KM, et al. Intravascular ultrasound evaluation of the effect of rotational atherectomy in obstructive atherosclerotic coronary artery disease. *Circulation* 1992;86: 1383-93.
- 24 Laskey WK, Brady ST, Kussmaul WG, Waxler AR, Krol J, Hermann HC, et al. Intravascular ultrasonographic assessment of the results of coronary artery stenting. *Am Heart J* 1993;125:1576-83.
- 25 Peters RJ, Kok WE, Havenith MG, Rijsterborgh H, van der Wal A, Visser CA. Histopathologic validation of intracoronary ultrasound imaging. *J Am Soc Echocardiogr* 1994;7:230-41.
- 26 Siegel R, Ariani M, Fishbein M, Chae J, Park J, Maurer G, et al. Histopathologic validation of angioscopy and intravascular ultrasound. *Circulation* 1991;84:109-17.
- 27 Pandian N, Kreis A, Brockway B. Detection of intrarterial thrombus by intravascular high frequency two-dimensional ultrasound in vitro and in vivo studies. *Am J Cardiol* 1990;65:1280-3.

- 28 Lee DY, Eigler N, Fishbein MC, Bhambi B, Maurer G, Siegel RJ. Identification of intracoronary thrombus and demonstration of thrombectomy by intravascular ultrasound imaging. *Am J Cardiol* 1994;73:522-3.
- 29 Comess K, Fitzgerald PJ, Yock PG. Intracoronary ultrasound imaging of graft thrombosis. *N Engl J Med* 1992;327:1691-2.
- 29a Jain A, Ramee S, Mesa J, Collins T, White C. Intracoronary thrombus: chronic urokinase infusion and evaluation with intravascular ultrasound. *Cathet Cardiovasc Diagn* 1992;26:212-4.
- 30 Frimerman A, Miller HI, Hallman M, Laniado S, Keren G. Intravascular ultrasound characterization of thrombi of different composition. *Am J Cardiol* 1994;73:1053-7.
- 31 Hausmann D, Lundkvist A-J, Friedrich GJ, Mullen WL, Fitzgerald PJ, Yock PG. Intracoronary ultrasound imaging: Intraobserver and interobserver variability of morphometric measurements. *Am Heart J* 1994;128:674-80.
- 32 Hausmann D, Erbel R, Alibelli-Chemarin MJ, et al. The safety of intracoronary ultrasound. A multicentre survey of 2207 examinations. *Circulation* 1995;91:623-30.
- 33 Pinto FJ, St Goar FG, Gao SZ, Chenzbraun A, Fischell TA, Alderman EL, et al. Immediate and one-year safety of intracoronary ultrasonic imaging. Evaluation with serial quantitative angiography. *Circulation* 1993;88:1709-14.
- 34 Ge J, Erbel R, Zamorano J, Koch L, Kearney P, Gorge G, et al. Coronary artery remodeling in atherosclerotic disease: an intravascular ultrasonic study in vivo. *Coronary Artery Dis* 1993;4:981-6.
- 35 Hermiller J, Buller C, Tenaglia A, Kisslo K, Phillips H, Bashore T, et al. Unrecognised left main coronary artery disease in patients undergoing interventional procedures. *Am J Cardiol* 1993;71:173-8.
- 36 Gerber TC, Erbel R, Gorge G, Ge J, Rupprecht HJ, Meyer J. Extent of atherosclerosis and remodeling of the left main coronary artery determined by intravascular ultrasound. *Am J Cardiol* 1994;73:666-71.
- 37 Mintz GS, Douek P, Pichard AD, Kent KM, Satler LF, Popma JJ, et al. Target lesion calcification in coronary artery disease: an intravascular ultrasound study. *J Am Coll Cardiol* 1992;20:1149-55.
- 38 Fitzgerald PJ, Yock PG. Mechanisms and outcomes of angioplasty and atherectomy assessed by intravascular ultrasound imaging. *J Clin Ultrasound* 1993;21:579-88.
- 39 Waller B. The eccentric coronary atherosclerotic plaque: morphologic observations and clinical relevance. *Clin Cardiol* 1989;12:14-20.
- 40 Pflugfelder PW, Boughner DR, Rudas L, Kostuk WJ. Enhanced detection of cardiac allograft arterial disease with intracoronary ultrasonographic imaging. *Am Heart J* 1993;125:1583-91.
- 41 Anderson TJ, Meredith IT, Uehata A, Mudge GH, Selwyn AP, Ganz P, et al. Functional significance of intimal thickening as detected by intravascular ultrasound early and late after cardiac transplantation. *Circulation* 1993;88:1093-100.
- 42 Drexler H, Fischell TA, Pinto FJ, Chenzbraun A, Botas J, Cooke JP, et al. Effect of L-arginine on coronary endothelial function in cardiac transplant recipients. Relation to vessel wall morphology. *Circulation* 1994;89:1615-23.
- 43 Mills RM, Billett JM, Nichols WW. Endothelial dysfunction early after heart transplantation. Assessment with intravascular ultrasound and Doppler. *Circulation* 1992;86:1171-4.
- 44 Pinto FJ, St Goar FG, Fischell TA, Stadius ML, Valantine HA, Alderman EL, et al. Nitroglycerin-induced coronary vasodilatation in cardiac transplant recipients: evaluation with in vivo intracoronary ultrasound. *Circulation* 1992;85:69-77.
- 45 Zamorano J, Erbel R, Ge J, Gorge G, Kearney P, Koch L, et al. Spontaneous plaque rupture visualized by intravascular ultrasound. *Eur Heart J* 1994;15:131-3.
- 46 Kearney P, Koch L, Ge J, Gorge G, Erbel R. PTCA mechanisms in stable and unstable angina analysed with intracoronary ultrasound before and after intervention (abstr). *Circulation* 1993;88:1-579.
- 47 Ge J, Erbel R, Rupprecht HJ, Koch L, Kearney P, Gorge G, et al. Comparison of intravascular ultrasound and angiography in the assessment of myocardial bridging. *Circulation* 1994;89:1725-32.
- 48 Sudhir K, MacGregor JS, Barbant SD, Foster E, Fitzgerald PJ, Chatterjee K, et al. Assessment of coronary conductance and resistance vessel reactivity in response to nitroglycerin, ergonovine and adenosine: in vivo studies with simultaneous intravascular two-dimensional and Doppler ultrasound. *J Am Coll Cardiol* 1993;21:1261-8.
- 49 Reddy KG, Suneja R, Nair RN, Dhawale P, Hodgson JM. Measurement by intracoronary ultrasound of in vivo arterial distensibility within atherosclerotic lesions. *Am J Cardiol* 1993;72:1232-7.
- 50 Hirshfeld JW, Schwartz JS, Jugo R, MacDonald RG, Goldberg S, Savage MP, et al, and the M-HEART investigators. Restenosis after coronary angioplasty: a multivariate statistical model to relate lesion and procedure variables to restenosis. *J Am Coll Cardiol* 1991;18:647-56.
- 51 Guiteras Val P, Bourassa MG, David PR, et al. Restenosis after successful percutaneous transluminal coronary angioplasty: the Montreal Heart Institute experience. *Am J Cardiol* 1987;60:50-55B.
- 52 Hermans WR, Resting BJ, Foley DP, Deckers JW, Rutsch W, Emanuelsson H, et al, on behalf of the MERCATOR study group. Therapeutic dissection after successful coronary balloon angioplasty: no influence on restenosis or on clinical outcome in 693 patients. *J Am Coll Cardiol* 1992;20:767-80.
- 53 Lee R, Loree H, Cheng G, Lieberman E, Jaramillo N, Schoen F. Computational structural analysis based on intravascular ultrasound imaging before in vitro angioplasty: prediction of plaque fracture locations. *J Am Coll Cardiol* 1993;21:777-82.
- 54 Fitzgerald P, Ports T, Yock P. Contribution of localized calcium deposits to dissection after angioplasty: an observational study using intravascular ultrasound. *Circulation* 1992;86:64-70.
- 55 Isner J, Rosenfield K, Losordo D, Rose L, Langevin E, Rasvi S, et al. Combination balloon-ultrasound imaging catheter for percutaneous transluminal angioplasty—validation of imaging, analysis of recoil and identification of plaque fracture. *Circulation* 1991;84:739-54.
- 56 Braden GA, Herrington DM, Downes TR, Kutcher MA, Little WC. Qualitative and quantitative contrasts in the mechanisms of lumen enlargement by coronary balloon angioplasty and directional coronary atherectomy. *J Am Coll Cardiol* 1994;23:40-8.
- 57 Losordo D, Rosenfield K, Pieczek A, Baker K, Harding M, Isner J. How does angioplasty work? Serial analysis of human iliac arteries using intravascular ultrasound. *Circulation* 1992;86:1845-58.
- 58 Potkin BN, Keren G, Mintz GS, Douek PC, Pichard AD, Satler LF, et al. Arterial responses to balloon coronary angioplasty: an intravascular ultrasound study. *J Am Coll Cardiol* 1992;20:942-51.
- 59 Coy K, Park J, Fishbein M, Laas T, Diamond G, Adler L, et al. In vitro validation of three-dimensional intravascular ultrasound for the evaluation of arterial injury after balloon angioplasty. *J Am Coll Cardiol* 1992;20:692-700.
- 60 DiMario C, Madretsma S, Linker D, The S, Bom N, Serruys P, et al. The angle of incidence of the ultrasonic beam: a critical factor for the image quality in intravascular ultrasonography. *Am Heart J* 1993;125:442-8.
- 61 Honye J, Mahon D, Jain A, White C, Ramee S, Wallis J, et al. Morphological effects of coronary balloon angioplasty in vivo assessed by intravascular ultrasound imaging. *Circulation* 1992;85:1012-25.
- 62 Gerber T, Erbel R, Gorge G, Ge J, Rupprecht H-J, Meyer J. Classification of morphologic effects of percutaneous transluminal coronary angioplasty assessed by intravascular ultrasound. *Am J Cardiol* 1992;70:1546-54.
- 63 Mintz GS, Kovach JA, Pichard AD, Kent KM, Satler LF, Popma JJ, et al. Geometric remodelling is the predominant mechanism of clinical restenosis after coronary angioplasty (abstr). *J Am Coll Cardiol* 1994;23:138A.
- 64 Nakamura S, Colombo A, Gaglione A, Almagor Y, Goldberg SL, Maiello L, et al. Intracoronary ultrasound observations during stent implantation. *Circulation* 1994;89:2026-34.
- 65 Mudra H, Klaus V, Blasini R, Rieber J, König A, Kroetz M, et al. Intracoronary ultrasound guidance of stent deployment leads to an increase of luminal gain not discernible by angiography. *J Am Coll Cardiol* 1994; Abstract supplement:117A.
- 66 Popma JJ, Colombo A, Almagor Y, Wong SC, Mintz GS, Pichard AD, et al. Quantitative angiographic analysis of a new ultrasound-guided stent implantation technique. *J Am Coll Cardiol* 1994; Abstract supplement:135A.
- 67 Colombo A, Hall B, Almagor Y, Maiello L, Gaglione A, Nakamura S, et al. Results of intravascular ultrasound guided coronary stenting without subsequent anticoagulation. *J Am Coll Cardiol* 1994; Abstract supplement: 335A.
- 68 Morice M-C, Bourdonnec C, Biron Y, Fajadet J, Glatt B, Royer T, et al. Coronary stenting without coumadin. Phase II. *J Am Coll Cardiol* 1994; Abstract supplement:335A.
- 69 Keren G, Bartorelli A, Bonner R, Douek P, Leon M. Intravascular ultrasound examination of coronary stents. In: Tobis J, Yock P, eds *Intravascular ultrasound imaging*, 1st ed. New York: Churchill Livingstone, 1992:219-30.
- 70 Klaus V, Blasini R, Regar E, Rieber J, König A, Mudra H. Mechanism of coronary in-stent restenosis: neointimal proliferation or stent compression? Serial assessment by intravascular ultrasound (abstr). *Circulation* 1993;88:1-598.
- 71 De Lezo JS, Romero M, Medina A, Pan M, Pavlovic D, Vaamonde R, et al. Intracoronary ultrasound assessment of directional coronary atherectomy: immediate and follow-up findings. *J Am Coll Cardiol* 1993;21:298-307.
- 72 Kovach JA, Mintz GS, Pichard AD, Kent KM, Popma JJ, Satler LF, et al. Sequential intravascular ultrasound characterization of the mechanisms of rotational atherectomy and adjunct balloon angioplasty. *J Am Coll Cardiol* 1993;22:1024-32.
- 73 White CJ, Ramee SR, Collins TJ, Jain A, Mesa JE. Ambiguous coronary angiography: clinical utility of intravascular ultrasound. *Cathet Cardiovasc Diagn* 1992;26:200-3.
- 74 Tenaglia A, Buller C, Kisslo K, Phillips H, Stack R, Davidson C. Intracoronary ultrasound predictors of adverse outcomes after coronary artery interventions. *J Am Coll Cardiol* 1992;20:1385-90.
- 75 Kuntz RE, Baim D. Defining coronary restenosis. *Circulation* 1993;88:1310-23.
- 76 Evans JL, Ng KH, Vonesh MJ, Kramer BL, Meyers SN, Mills TA, et al. Arterial imaging with a new forward-viewing intravascular ultrasound catheter. I. Initial studies. *Circulation* 1994;89:712-7.