

SHORT CASES IN CARDIOLOGY

Department of
Cardiology, University
Hospital NHS Trust,
Selly Oak Hospital,
Birmingham

M Pitt
M K Davies
A J B Brady

Correspondence to:
Dr M Pitt, Department of
Cardiology, University
Hospital NHS Trust, Selly
Oak Hospital, Raddlebarn
Road, Selly Oak,
Birmingham B29 6JD, UK.

Accepted for publication
25 April 1996

Hypereosinophilic syndrome: endomyocardial fibrosis

M Pitt, M K Davies, A J B Brady

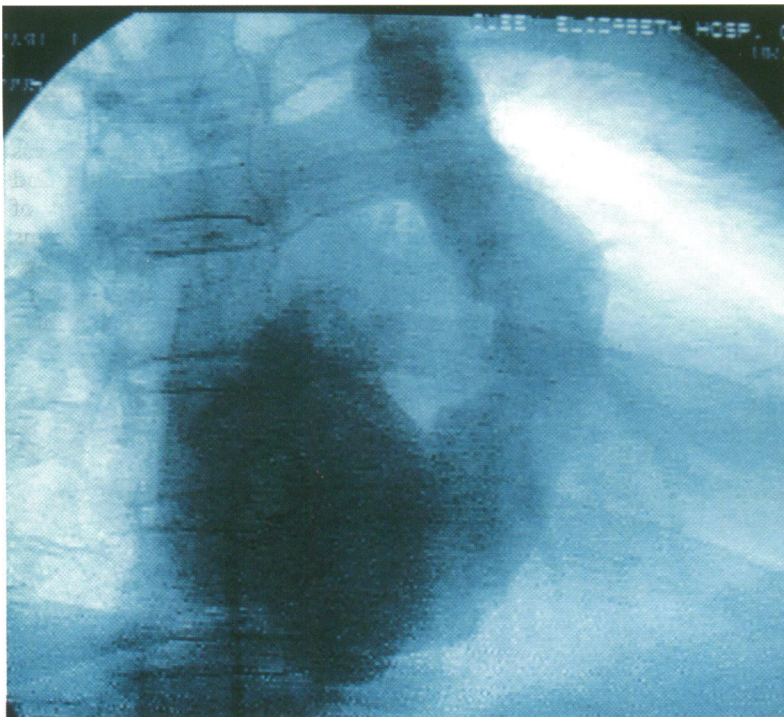


Figure 1 Right atrial angiogram (posteroanterior view).

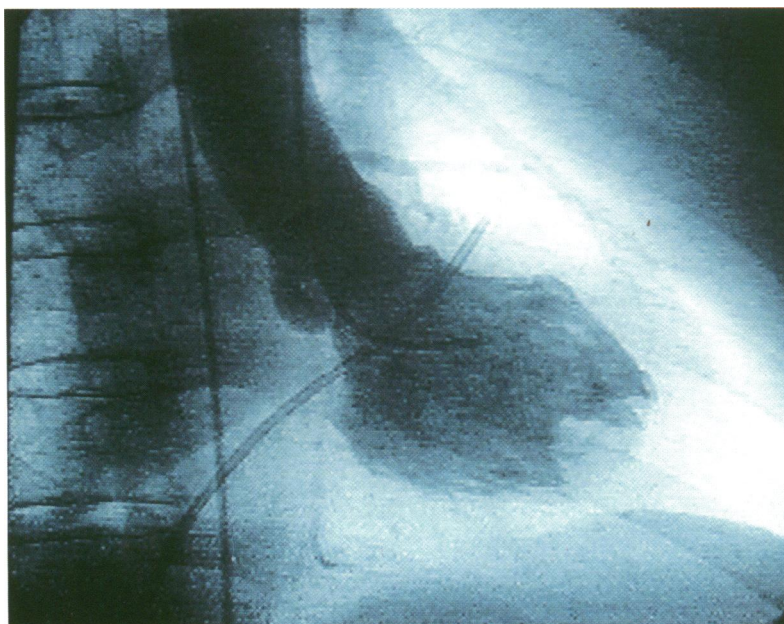


Figure 2 Left ventricular angiogram (right anterior oblique view).

A 56 year old white woman presented in 1994 with features of an inflammatory polyarthritis with slightly raised inflammatory markers, negative rheumatoid factor, and normal white cell count (including differential). She responded to the non-steroidal anti-inflammatory drug (NSAID), nabumetone.

A year later dyspnoea developed. On examination her jugular venous pressure was grossly raised with a positive Kussmaul's sign. No clinical features of right ventricular hypertrophy, pulmonary hypertension, or left heart disease were apparent. The electrocardiogram was normal. The chest x ray showed a normal heart size and clear lung fields. Good echocardiographic images were extremely difficult to obtain but no significant pericardial effusion was seen. A clinical diagnosis of constrictive pericarditis or a restrictive cardiomyopathy was made.

Mild airflow obstruction, with a minimal decrease in carbon monoxide transfer coefficient was seen on pulmonary function testing. Sputum examination showed no pathogens and no eosinophils. High resolution thoracic computerised tomography (CT) scans showed mild emphysematous change and no pericardial thickening or calcification. Lung ventilation/perfusion scanning showed no mismatched defects.

There was considerable peripheral blood eosinophilia (eosinophil count $4-8 \times 10^9/l$, normal $0.7 \times 10^9/l$). She had never travelled abroad and there was no evidence of parasite infection, underlying malignancy, or autoimmune disease.

Right heart catheterisation showed normal pulmonary artery pressures and a mean pulmonary artery wedge pressure of 12 mm Hg. Mean right atrial pressure was 10 mm Hg with no prominent "v" wave of tricuspid regurgitation. No stable right ventricular position could be obtained because the catheter passed directly from the right atrium into the right ventricular outflow tract. A right atrial angiogram revealed the virtual absence of the right ventricular cavity (fig 1).

Left ventricular angiography showed a filling defect and a puckered appearance at the left ventricular apex with little mitral regurgitation (fig 2). Cardiac biopsy was not performed.

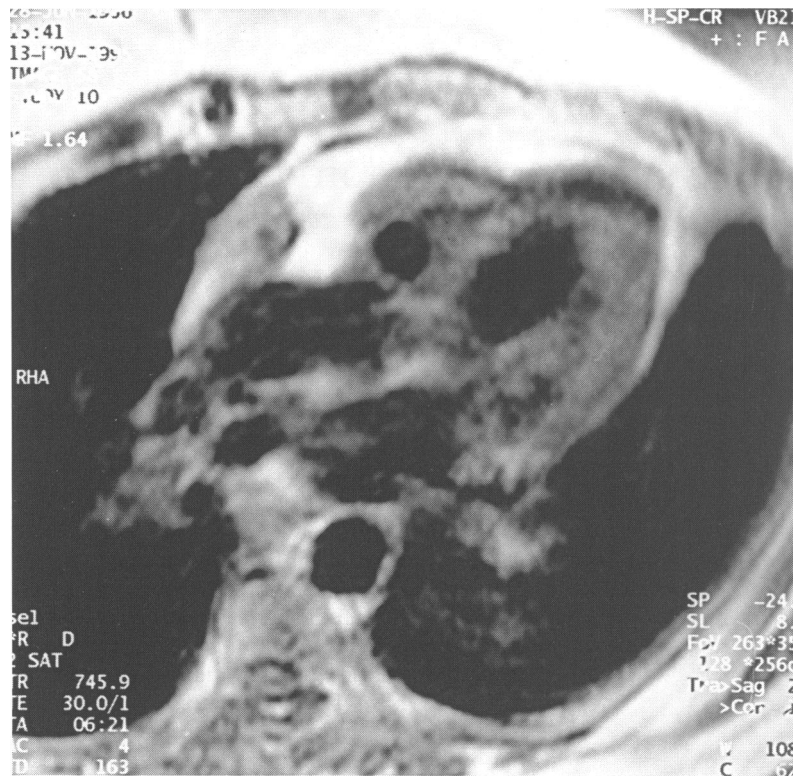


Figure 3 Magnetic resonance image.

Subsequent cardiac magnetic resonance imaging (MRI) revealed grossly thickened right and left ventricular walls with broadening of the intra-atrial septum. The right ventricular cavity was virtually obliterated (fig 3).

Bone marrow examination showed a marked increase in mature eosinophils with no

blast cells seen and no evidence of dysplasia or lymphoid neoplasia. Treatment with high dose oral steroids was started. There was a prompt fall in the eosinophil count and a slight improvement in the dyspnoea only.

Endomyocardial fibrosis is a rare disorder in the United Kingdom. It is closely related to the hypereosinophilic syndrome. Eosinophil degranulation within cardiac endocardium causes tissue damage by necrotic, thrombotic, and subsequently fibrotic change.¹

In this case the radiological features and especially the contemporary MRI images, suggested that extensive endomyocardial fibrotic change had already occurred.

Non-steroidal anti-inflammatory drugs inhibit cyclo-oxygenase activity. Arachidonic acid is diverted to the synthesis of the products of lipoxygenase, many of which, such as the leukotrienes, have eosinophilic chemotactic activity. Nabumetone, one of the NSAIDs, has been reported to be closely associated with a case of pulmonary fibrosis and eosinophilia in one elderly patient.²

In our case, nabumetone treatment was temporally associated with eosinophilia and onset of dyspnoea, raising the possibility of drug induced disease. Nevertheless, symptoms and eosinophilia did not significantly change after drug withdrawal. Future management will involve assessment for cardiac transplantation.

- 1 Olsen EGJ, Spry CJF. Relation between eosinophilia and endomyocardial disease. *Prog Cardiovasc Dis* 1985;27: 241.
- 2 Forice A, Atherton A, Gleeson F, Stewart S. Pulmonary fibrosis associated with nabumetone. *Postgrad Med J* 1991;67:1021-2.