

Natural history and outcome of aortic stenosis diagnosed prenatally

John M Simpson, Gurleen K Sharland

Abstract

Objective—To document the growth of the left heart structures and outcome of fetuses with aortic stenosis.

Design—Retrospective echocardiographic and clinical study.

Setting—Tertiary centre for fetal cardiology.

Patients—27 consecutive fetuses with aortic stenosis.

Main outcome measures—Survival of affected fetuses. Measurement of left ventricular end diastolic volume (LVEDV), aortic root diameter, and ejection fraction.

Results—Before 25 weeks' gestation, the LVEDV was normal or increased in all cases. In six of eight fetuses studied sequentially, the LVEDV fell across normal centiles. Initial ejection fraction was reduced in 23 fetuses (88%). Before 28 weeks' gestation, the aortic root was normal in all but one case, but after 29 weeks, 11 of 13 fetuses had values below the 50th centile. In two fetuses prenatal aortic valvoplasty was attempted, 10 babies had postnatal interventions, and there were six survivors. Biventricular repair was attempted in eight cases, of whom five survived. A first stage Norwood operation was performed in three babies, of whom one survived. The four fetuses with the highest aortic root z scores had successful biventricular repair. The two fetuses with initially normal ejection fractions survived. Successful biventricular repair was achieved even where the LVEDV was below the 5th centile.

Conclusions—In aortic stenosis diagnosed prenatally, failure of growth of the left ventricle and aortic root often occurs. The outcome of affected fetuses is better than previously reported. Prenatal echocardiography may assist selection of

suitable candidates for biventricular versus Norwood repair.

(Heart 1997;77:205-210)

Keywords: aortic stenosis; fetal heart; echocardiography

Critical aortic stenosis can be diagnosed accurately prenatally.¹⁻⁵ Treatment of aortic stenosis postnatally is associated with a significant mortality.⁶⁻⁹ During prenatal life, case reports have suggested that impairment of the growth of left sided cardiac structures may occur in such fetuses.^{10,11} This is clinically important because, postnatally, a decision has to be made whether to attempt a biventricular repair or to opt for a staged Norwood approach.¹² Criteria which may influence such a decision include the size and the function of the left ventricle and diameter of the aortic root.^{8,13-17} Prenatal aortic valvoplasty has also been advocated, to promote growth of the left ventricle thereby increasing the potential for a biventricular circulation.^{18,19}

The aim of this study was to quantify the left ventricular volume, the left ventricular ejection fraction, and the aortic root size in consecutive fetuses with aortic stenosis and to observe whether such measurements might help to predict if biventricular repair is possible.

Methods

Patients included were selected from those judged to be at increased risk for congenital heart disease²⁰ who were referred to a tertiary centre for fetal cardiology between January 1991 and December 1995. During this period 7021 fetuses were scanned, of whom 27 (0.38%) had aortic stenosis, based on echocardiographic visualisation of a stenotic, dysplastic aortic valve with reduced excursion (fig 1 A, B) or increased Doppler velocity across the

Department of Fetal Cardiology, Guy's Hospital, London, United Kingdom
J M Simpson
G K Sharland

Correspondence to:
Dr J M Simpson, Research Fellow in Fetal and Paediatric Cardiology, Department of Fetal Cardiology, 15th Floor, Guy's Hospital, London SE1 9RT.

Accepted for publication 29 October 1996

Figure 1 (A) The left ventricular outflow tract in aortic stenosis (non-continuing pregnancy). The left ventricle (LV) is dilated and the aortic valve (double arrow) is dysplastic. (B) View of the aortic arch (case 10). The aortic valve (AoV) is dysplastic and there is poststenotic dilatation of the ascending aorta (AAO).

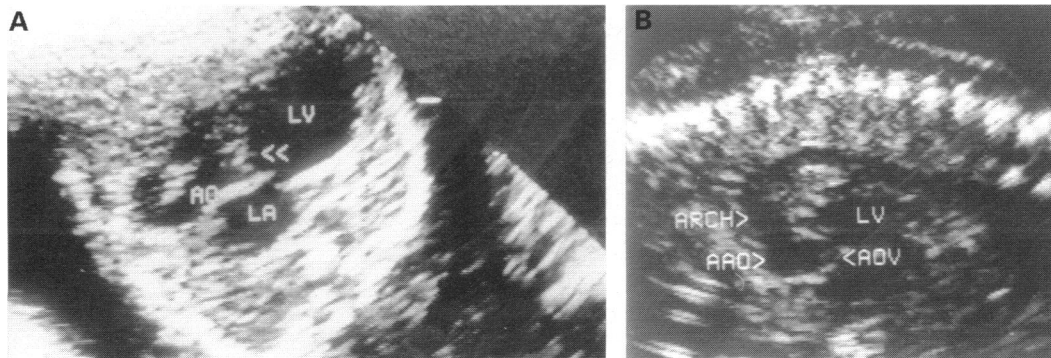


Table 1 Summary of prenatal findings and postnatal course of 12 fetuses with aortic stenosis

| Case number | Referral reason | Gestation at presentation | Gestation at delivery | Procedures | Associated lesions/anomalies | Mitral regurgitation | EFE | Outcome |
|-------------|-----------------|---------------------------|-----------------------|--|---------------------------------------|----------------------|-----|-------------------------|
| 1 | FH | 18 | 38 | Balloon valvoplasty (day 2) | Craniosynostosis | + | + | Alive |
| 2 | FH | 29 | 39 | Balloon valvoplasty (day 1) | Nil | - | - | Alive |
| 3 | ?CHD | 19 | 39 | Nil | Nil, twin pregnancy | - | + | Neonatal death (day 1) |
| 4 | ?CHD | 20 | 38 | Nil | Pulmonary stenosis, dysplastic kidney | + | + | Neonatal death (day 1) |
| 5 | ?CHD | 34 | 38 | Prenatal balloon valvoplasty (34 weeks) and two postnatal balloon valvoplasties (day 3, day 60) | Nil | + | + | Alive |
| 6 | ?CHD | 25 | 38 | Norwood operation, stage 1 (day 2) | Nil | + | + | Neonatal death (day 2) |
| 7 | ?CHD | 33 | 38 | Balloon valvoplasty (day 1) | Nil | - | - | Alive |
| 8 | ?CHD | 34 | 38 | Failed balloon valvoplasty (day 2) Surgical valvotomy (day 2); ligation of arterial duct (day 26) | Nil | + | + | Infant death (day 30) |
| 9 | ?CHD | 30 | 34 | Failed prenatal balloon valvoplasty; postnatal surgical valvotomy (week 1) | Nil | + | + | Neonatal death (day 21) |
| 10 | ?CHD | 20 | 38 | Surgical valvotomy (week 1) | Nil | - | + | Alive |
| 11 | ?CHD | 35 | 39 | Norwood operation, stage 1 (day 3) | Nil | ++ | + | Neonatal death (day 3) |
| 12 | ?CHD | 30 | 38 | Balloon valvoplasty (day 1); Norwood operation, stage 1 (day 9) | Pierre-Robin syndrome, cleft palate | + | + | Alive |

EFE, endocardial fibroelastosis; ?CHD, suspected congenital heart disease; FH, family history of congenital heart disease.

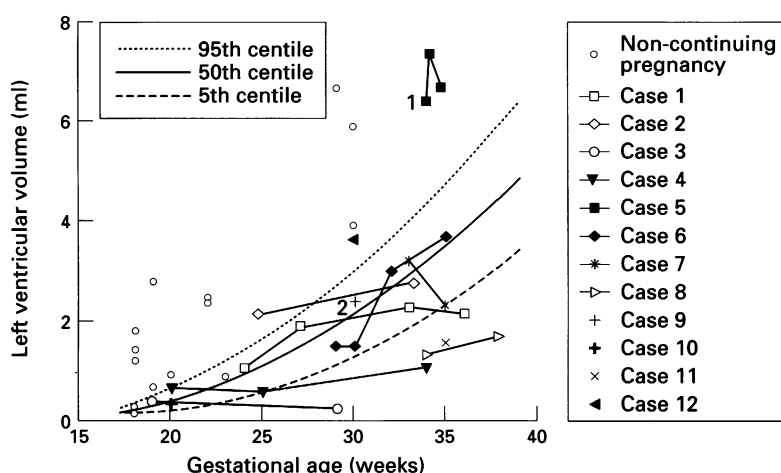


Figure 2 Graph of left ventricular end diastolic volume versus gestational age in fetuses with aortic stenosis. 1 Balloon dilatation of aortic valve performed in utero following first scan. 2 Failed attempt at balloon dilatation of aortic valve in utero (case 9).

aortic valve, or both. The median gestational age at presentation was 22 weeks (range 18 to 35). Gestational age was determined by obstetric ultrasound criteria (femoral length or biparietal diameter). Twenty four fetuses were referred because of suspected congenital heart disease, two because of aortic stenosis in a previous child, and one because of maternal diabetes mellitus. Fetuses with abnormal cardiac connections were excluded. One hundred and

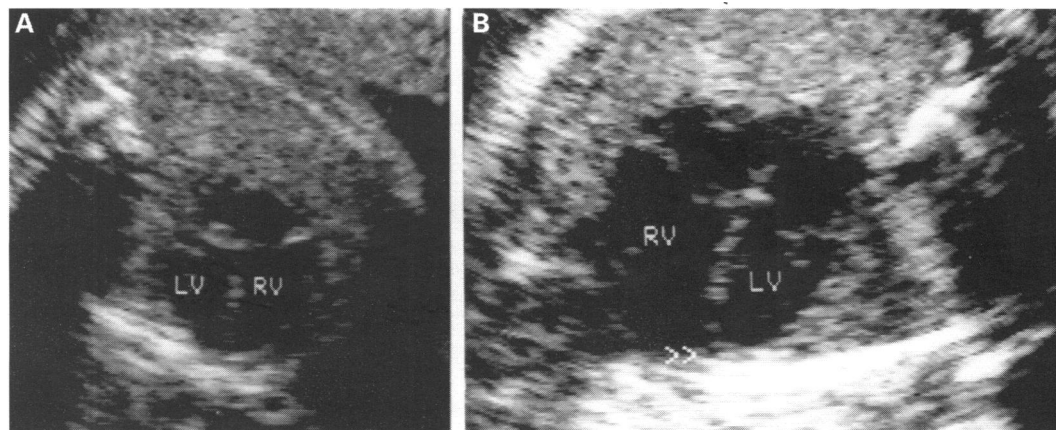
thirty fetuses with mitral or aortic atresia and a severely hypoplastic left ventricle (hypoplastic left heart syndrome) were excluded, as well as 86 fetuses with suspected coarctation of the aorta.

Information about outcome was obtained from case note, echocardiogram, and necropsy review. For infants who were not treated at our centre, relevant data were obtained from attending paediatric cardiologists, obstetricians, and paediatricians. The median duration of follow up of survivors was 12 months (range 8 to 60).

ECHOCARDIOGRAPHIC METHOD

Fetal echocardiograms were performed using Advanced Technology Laboratories Ultramark 4, Hewlett Packard 77020A, or Toshiba SS-270A ultrasound machines, with 5 MHz or 3.5 MHz probes as appropriate. All videotapes were analysed by a single observer (JMS), using the Hewlett Packard system. The left ventricular end diastolic (LVEDV) and end systolic volumes (LVESV) were calculated using a single plane method of discs in the four chamber view. Although a biplane view would have been better,²¹ the single plane four chamber view was selected because it was obtained in all cases and is an accepted standard view in the fetus.²² The ejection fraction was calculated and expressed as a percentage. The aortic

Figure 3 Sequential views of the heart at 24 and 33 weeks' gestation in a fetus (case 1) with aortic stenosis. (A) At 24 weeks the left and right ventricles form the apex and are of equal size. (B) At 33 weeks the right ventricle is much larger than the left and the right ventricle forms the apex (double arrow).



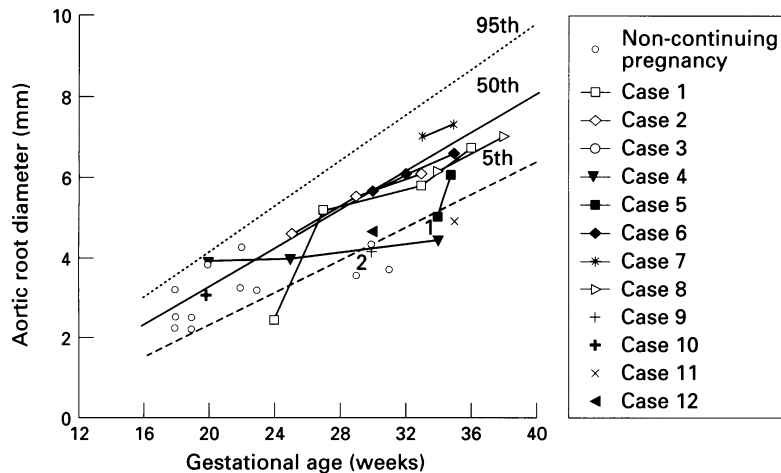


Figure 4 Aortic root diameter versus gestational age in fetuses with aortic stenosis. (Centiles marked with solid and dotted lines.) 1 Balloon dilatation of aortic valve performed in utero following first scan. 2 Failed attempt at balloon dilatation of aortic valve in utero (case 9).

root was measured by cross sectional echocardiography at the level of the aortic valve at end diastole, with the aortic valve closed. The ventricular volumes and ejection fractions were compared with normal ranges, calculated using the method of Altman,^{23,24} from 75 normal fetuses using the same echocardiographic method (Simpson JM, unpublished observations). The normal ranges of the aortic root were based on data from 296 fetuses studied in our department.²⁵

STATISTICAL ANALYSIS

The values of LVEDV and aortic root diameter are presented in scattergram format; z scores of LVEDV and aortic root diameter were calculated for the final scan before delivery. Detailed statistical comparisons of survivors versus non-survivors were not performed in view of relatively small number of fetuses who underwent interventions.

STUDY LIMITATIONS

The timing of prenatal scans was not standardised nor were serial scans performed in all cases, making precise comparison of findings at equivalent gestational ages impossible. The analysis of prenatal findings was retrospective and so did not influence postnatal management. The limitation of retrospective data in predicting future outcomes is well recognised and so such data should be interpreted with caution.

Results

OUTCOME OF PREGNANCY

Fifteen sets of parents (56%) elected to terminate the pregnancy after the initial scan. The details of the continuing pregnancies are shown in table 1. Six of the 15 terminated fetuses did not have a necropsy examination because the parents declined, but the other nine had necropsies, which confirmed the diagnosis of aortic stenosis in all cases. Eight of the nine necropsies showed endocardial fibroelastosis of the left ventricle and one of these fetuses was also severely hydropic.

LEFT VENTRICULAR END DIASTOLIC VOLUME

The LVEDV values of all 27 fetuses are shown in fig 2. Before 25 weeks' gestation the LVEDV was within or above the normal range, but beyond 25 weeks there was a wide scatter of volumes, ranging from below the 5th centile to well above the 95th centile. Two fetuses (cases 8 and 11) presented at 34 and 35 weeks' gestation, respectively with LVEDV values below the 5th centile. Neither of these cases fell into a typical pattern of hypoplastic left heart syndrome as there was demonstrable flow into and out of the left ventricle, but with stenosis of the aortic valve. Indeed, in one of these babies (case 8), biventricular repair was attempted postnatally. Thus these two cases were included in the study. Eight cases (cases 1-8) were studied sequentially, of whom six (cases 1, 3, 4, 6, 7, and 8) showed a subnormal rate of left ventricular growth.

LEFT VENTRICULAR EJECTION FRACTION

The median ejection fraction at presentation was 21% (range 0-58%; normal range 50-80%). Three fetuses had a normal ejection fraction at presentation, of whom two were studied sequentially (cases 1 and 2). In case 1, between 28 and 34 weeks' gestation, the ejection fraction fell from 57% to 16%, which coincided with a decreased rate of left ventricular growth (fig 3). Case 2 had a normal ejection fraction throughout gestation, with well maintained left ventricular growth. These two fetuses were referred because of a family history of aortic stenosis, and had a normal four chamber view at presentation, in contrast to all the remaining cases.

AORTIC ROOT DIAMETER

The aortic root diameter in 26 fetuses is shown in fig 4. One fetus had images of poor quality for measurement. Between 17 and 28 weeks' gestation, the aortic root diameter was within the normal range for 12 of 13 fetuses. Beyond 28 weeks' gestation, the aortic root was below the 5th centile in six of 13 cases. The seven fetuses with sequential measurements showed a normal rate of growth in all except one (case 4).

POSTNATAL OUTCOME

The case details of all 12 continuing pregnancies are shown in table 1, and a flow diagram of interventions is shown in fig 5. In two cases (cases 3 and 4) postnatal intervention was not undertaken and both babies died in the first 48 hours of life. The first baby (case 3) was one of twins, while the other twin was healthy, and the parents declined surgical treatment. The second baby (case 4) had a stenotic and regurgitant pulmonary valve (Doppler gradient 3.5 m/s) and a dysplastic kidney, in addition to aortic stenosis with a hypoplastic left ventricle at term (fig 2).

In two fetuses prenatal balloon aortic valvoplasty was attempted; this was successful in one (case 5), but in the other (case 9) it was not possible to cross the aortic valve with a balloon catheter. The baby with the successful prenatal valvoplasty (case 5) presented late in

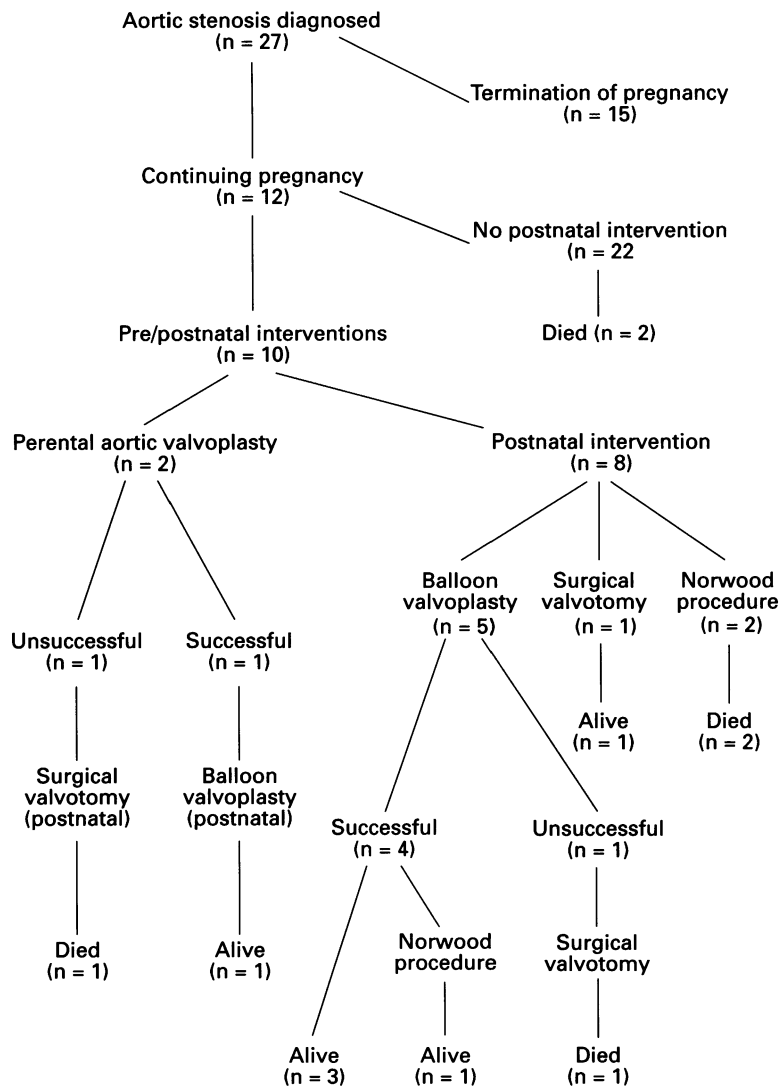


Figure 5 Flow diagram of outcome of aortic stenosis diagnosed prenatally.

Table 2 Outcome of aortic stenosis according to final z score of left ventricular end diastolic volume (LVEDV). Results are presented in order from largest to smallest z score

| Case number | LVEDV z score | Type of repair undertaken | Outcome |
|-------------|---------------|---------------------------|----------|
| Case 4 | 4.8 | Biventricular | Survived |
| Case 12 | 2.9 | Norwood | Survived |
| Case 9 | 0.55 | Biventricular | Died |
| Case 2 | 0.54 | Biventricular | Survived |
| Case 6 | -0.21 | Norwood | Died |
| Case 10 | -0.63 | Biventricular | Survived |
| Case 7 | -1.36 | Biventricular | Survived |
| Case 1 | -1.88 | Biventricular | Survived |
| Case 11 | -2.42 | Norwood | Died |
| Case 8 | -3.63 | Biventricular | Died |

Table 3 Outcome of aortic stenosis according to final z score of aortic (Ao) root. Results are presented in order from largest to smallest z score

| Case number | Ao root z score | Type of repair undertaken | Outcome |
|-------------|-----------------|---------------------------|----------|
| Case 7 | 0.476 | Biventricular | Survived |
| Case 10 | -0.351 | Biventricular | Survived |
| Case 2 | -0.369 | Biventricular | Survived |
| Case 1 | -0.523 | Biventricular | Survived |
| Case 6 | -0.556 | Norwood | Died |
| Case 8 | -0.77 | Biventricular | Died |
| Case 12 | -1.46 | Norwood | Survived |
| Case 5 | -2.07 | Biventricular | Survived |
| Case 9 | -2.16 | Biventricular | Died |
| Case 11 | -2.46 | Norwood | Died |

gestation, at 34 weeks, with a dilated poorly functioning left ventricle (ejection fraction 25%). Twenty four hours after the valvoplasty, there was no demonstrable left ventricular contraction but, one week later, the ejection fraction had increased to 33%, although the LVEDV was little changed from that before valvoplasty (fig 2). This child was alive at the age of 4 years and the details of this baby's clinical course and of the intrauterine balloon aortic valvoplasty technique have been described elsewhere.^{18,19}

Six infants (cases 1, 2, 5, 7, 8, and 12) had balloon aortic valvoplasty postnatally (which was technically successful in five cases) and in four of these a biventricular circulation was successfully achieved. One baby (case 12) subsequently underwent a first stage Norwood procedure. Three cases (8, 9, and 10) had a surgical valvotomy in the neonatal period, with two deaths. Two further cases (6 and 11) had a Norwood procedure as a primary intervention and both died.

The two fetuses with a normal ejection fraction on the initial prenatal scan had a successful balloon valvoplasty postnatally and survived (cases 1 and 2, table 1). The relation of the z score of LVEDV and aortic root diameter at the final prenatal scan to the attainment of a biventricular circulation is shown in tables 2 and 3. Four of the seven fetuses with z scores greater than -1.65 (5th centile) for LVEDV survived with a biventricular circulation. One fetus with a z score of -1.88 (below the 5th centile) had a successful biventricular repair. The aortic root diameters at the final prenatal scan (table 3) tended to be in the low normal range. The four fetuses with the highest z scores all survived after balloon valvoplasty or surgical valvotomy.

Discussion

The aim of this study was to document the spectrum, the progression, and the outcome of aortic stenosis detected prenatally. Two other reports have addressed the issue of left ventricular growth and function, but comparisons between those and our present study are impossible. The study of Sharland *et al*² included five fetuses with critical aortic stenosis with endocardial fibroelastosis, and six with "primary" endocardial fibroelastosis, that is, without any evidence of left ventricular out-flow tract obstruction. Those with aortic stenosis showed a reduced rate of growth of left ventricular length and width. None of the fetuses in our study was found to have "primary" endocardial fibroelastosis. The ability to separate these two groups has improved because of advances in ultrasound equipment permitting better imaging of the aortic valve, and improved ability to measure high Doppler velocities across obstructed valves. Hornberger *et al*⁴ also described a subnormal rate of growth of the mitral valve, left ventricle, and aorta in fetuses with left heart obstruction but that study encompassed a large number of different conditions, such as aortic atresia and mitral atresia. Our exclusion of such fetuses

was deliberate, because the issue of biventricular versus Norwood approach does not arise.

Our volumetric findings show that failure of growth of the left ventricle is a frequent occurrence in fetuses with aortic stenosis. This has implications for antenatal counselling of parents with regard to the possibility of a biventricular repair. Prenatal balloon aortic valvoplasty has been performed with the aim of improving left ventricular growth and function. In this series, when this was performed successfully there was no early increase in ejection fraction and little change in left ventricular end diastolic volume, but the period during which the fetus was studied prenatally was relatively short. The failure of left ventricular growth early in pregnancy, which we have documented, suggests that prenatal balloon valvoplasty may have to be performed in the midtrimester, which would be technically more difficult and potentially more hazardous. This approach may have been justified, taking into consideration the uniformly poor outcome for critical aortic stenosis diagnosed prenatally described in a previous report.² However, in our study, survival of six of 10 babies in whom interventions were undertaken makes this suggestion less justifiable.

The increased survival may be due, in part, to improved prenatal detection of less severe cases of aortic stenosis, but better postnatal management may also have contributed. This is supported by the fact that, at this centre, the mortality of critical aortic stenosis presenting in the neonatal period has decreased from 82% (9/11) between 1985 and 1990, to 27% (3/11) between 1991 and 1995.²⁶ These results—taken together with the improving results of the Norwood operation in the United Kingdom²⁷—also make the argument for prenatal intervention less compelling. If, however, reports of serious late complications following a Norwood repair, such as poor neurological outcome,²⁸ are confirmed by larger studies, then prenatal intervention may become justifiable, with the aim of increasing the chance of a successful biventricular repair.

The prognostic value of ejection fraction in postnatal studies of aortic stenosis is controversial.¹⁴⁻¹⁷ Although a small proportion of fetuses in our study had a normal ejection fraction, both survived with a biventricular circulation, so this would appear to be an encouraging feature. We have described the outcome in relation to LVEDV and aortic root z scores, because they have been implicated as significant prognostic factors in postnatal studies.^{8 13 14 16 17} Biventricular repair was successfully achieved in fetuses with z scores as low as -1.88 (below the 5th centile) but the fetus with the lowest z score did not survive an attempt at biventricular repair. Conversely, LVEDV z score within the normal range does not necessarily mean that a successful biventricular repair will be possible, as was shown in two of our cases. With regard to the aortic root, the four fetuses with the largest aortic root z scores all survived biventricular repair but this was also successful in a fetus with an aortic root more than two standard deviations

below normal. Thus there may be a critical LVEDV or aortic root size below which biventricular repair is not attainable but it is not possible, from our study, to define this point. An interaction of factors such as ejection fraction, left ventricular size, and aortic root size may contribute to the attainability of a biventricular circulation, which has also been suggested by postnatal studies of this condition.¹⁴

In summary, our data show that failure of growth of the left ventricle is common in fetuses with aortic stenosis and that ejection fraction is often, although not invariably, reduced. Prenatal assessment of LVEDV, ejection fraction, and aortic root size may be of value in decision making with regard to biventricular versus Norwood repair, but this needs to be determined with a prospective series. The survival of babies with aortic stenosis diagnosed prenatally has improved compared with previous reported series.

- Huhta JC, Carpenter RJ, Moise KJ, Deter RL, Ott DA, McNamara DG. Prenatal diagnosis and postnatal management of critical aortic stenosis. *Circulation* 1987; 75:573-6.
- Sharland GK, Chita SK, Fagg NLK, Anderson RH, Tynan MJ, Cook AC, et al. Left ventricular dysfunction in the fetus: relation to aortic valve anomalies and endocardial fibroelastosis. *Br Heart J* 1991;66:419-24.
- Allan LD, Sharland GK, Milburn A, Lockhart SM, Groves AMM, Anderson RH, et al. Prospective diagnosis of 1006 consecutive cases of congenital heart disease in the fetus. *J Am Coll Cardiol* 1994;23:1452-8.
- Hornberger LK, Sanders SP, Rein AJJT, Spevak PJ, Parness IA, Colan SD. Left heart obstructive lesions and left ventricular growth in the midtrimester fetus. A longitudinal study. *Circulation* 1995;92:1531-8.
- Yasukochi S, Satomi G, Harada Y. Successful neonatal balloon aortic valvoplasty following diagnosis of critical aortic stenosis. *Cardiol Young* 1995;5:363-6.
- Zeevi B, Keane JF, Castaneda AR, Perry SB, Lock JE. Neonatal critical valvar aortic stenosis. A comparison of surgical and balloon dilation therapy. *Circulation* 1989; 80:831-9.
- Kitchiner DJ, Jackson M, Walsh K, Peart I, Arnold R. Incidence and prognosis of congenital aortic valve stenosis in Liverpool (1960-1990). *Br Heart J* 1993;69:71-9.
- Bu'Lock FA, Joffe HS, Jordan SC, Martin RP. Balloon dilation (valvoplasty) as first line treatment for severe stenosis of the aortic valve in early infancy: medium term results and determinants of survival. *Br Heart J* 1993; 70:546-53.
- Gatzoulis MA, Rigby ML, Shinebourne EA, Redington AN. Contemporary results of balloon valvuloplasty and surgical valvotomy for congenital aortic stenosis. *Arch Dis Child* 1995;73:66-9.
- Allan LD, Sharland GK, Tynan MJ. The natural history of the hypoplastic left heart syndrome. *Int J Cardiol* 1989; 25:343-6.
- Danford DA, Cronican P. Hypoplastic left heart syndrome: progression of left ventricular dilation and dysfunction to left ventricular hypoplasia in utero. *Am Heart J* 1992; 123:1712-3.
- Murdison KA, Baffa JM, Farrell PE, Chang AC, Barber G, Norwood WI, et al. Hypoplastic left heart syndrome: outcome after initial reconstruction and before modified Fontan procedure. *Circulation* 1989;80:70-8.
- Latson LA, Cheatham JP, Gutgesell HP. Relation of the echocardiographic estimate of left ventricular size to mortality in infants with severe left ventricular outflow obstruction. *Am J Cardiol* 1981;48:887-91.
- Rhodes LA, Colan SD, Perry SB, Jonas RA, Sanders SP. Predictors of survival in neonates with critical aortic stenosis. *Circulation* 1991;84:2325-35.
- Gundry SR, Behrendt DM. Prognostic factors in valvotomy for critical aortic stenosis in infancy. *J Thorac Cardiovasc Surg* 1986;92:747-54.
- Hammon JW, Lupinetti FM, Maples MD, Merrill WH, Frist WH, Graham TP, et al. Predictors of operative mortality in critical valvular aortic stenosis presenting in infancy. *Ann Thorac Surg* 1988;45:537-40.
- Mocellin R, Sauer U, Simon B, Comazzi M, Sebening F, Buhlmeier K. Reduced left ventricular size and endocardial fibroelastosis as correlates of mortality in newborns and young infants with severe aortic stenosis. *Pediatr Cardiol* 1983;4:265-72.
- Maxwell D, Allan JD, Tynan MJ. Balloon dilatation of the aortic valve in the fetus: a report of two cases. *Br Heart J* 1991;65:256-8.
- Allan LD, Maxwell DJ, Carminati M, Tynan MJ. Survival after fetal aortic balloon valvoplasty. *Ultrasound Obstet Gynecol* 1995;5:90-1.

- 20 Sharland GK, Allan LD. Detection of congenital abnormalities of the cardiovascular system by ultrasound. In: Chamberlain G, ed. *Modern antenatal care of the fetus*. Oxford: Blackwell Scientific Publications, 1990: 356.
- 21 Schiller NB, Shah PM, Crawford M, DeMaria A, Devereux R, Feigenbaum H, et al. Recommendations for quantitation of the left ventricle by two-dimensional echocardiography. *J Am Soc Echocardiogr* 1989;2:358-67.
- 22 Allan LD. Normal fetal cardiac anatomy—cross-sectional echocardiography. In: *Manual of fetal echocardiography*. Lancaster: MTP Press, 1986:11-47.
- 23 Altman DG. Construction of age-related reference centiles using absolute residuals. *Stat Med* 1993;12:917-24.
- 24 Altman DG, Chitty LS. Charts of fetal size: 1. Methodology. *Br J Obstet Gynaecol* 1994;101:29-34.
- 25 Sharland GK, Allan LD. Normal fetal cardiac measurements derived by cross-sectional echocardiography. *Ultrasound Obstet Gynaecol* 1992;2:175-81.
- 26 Chee A, Rosenthal E, Huggon I, Qureshi SA, Baker E, Tynan MJ. Balloon dilatation of the aortic valve in neonatal critical aortic stenosis [abstract]. *Heart* 1996;75 (suppl 1):29.
- 27 Bu'Lock FA, Stumper O, Jagtap R, Silove ED, De Giovanni JV, Wright JG, et al. Surgery for infants with a hypoplastic systemic ventricle and severe outflow obstruction: early results with a modified Norwood procedure. *Br Heart J* 1995;73:456-61.
- 28 Rogers BT, Msall ME, Buck GM, Lyon NR, Norris MK, Roland JM, et al. Neurodevelopmental outcome of infants with hypoplastic left heart syndrome. *J Pediatr* 1995;126:496-8.