

SUPPLEMENTAL DIGITAL CONTENT 1

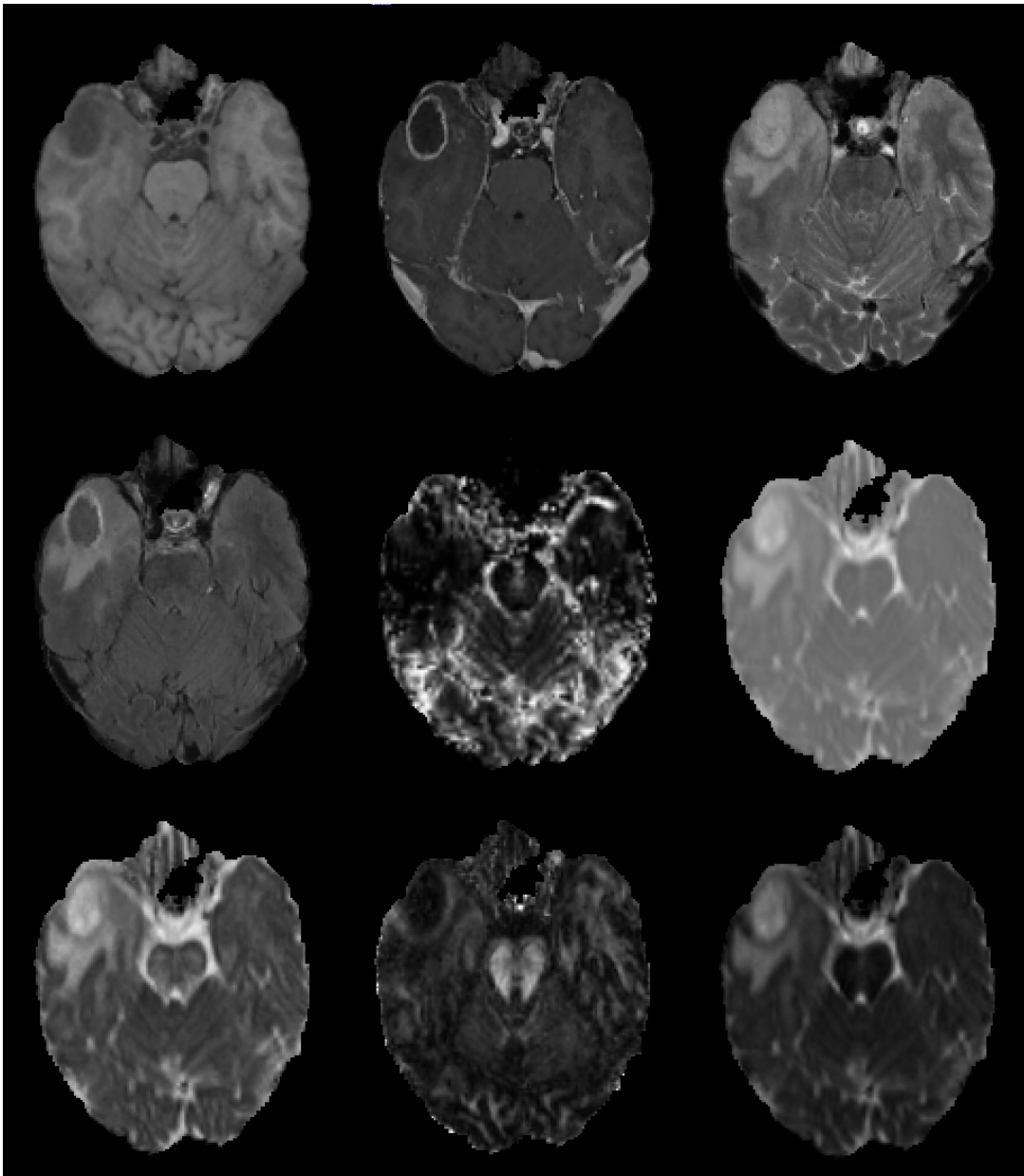


FIGURE. Magnetic resonance imaging (MRI) modalities. Snapshots of the preoperative images processed and used as inputs to infiltration model. **Top left to bottom right**, T₁-weighted, T₁-weighted contrast-enhanced, T₂-weighted, fluid-attenuated inversion recovery, relative cerebral blood volume, trace, axial diffusivity, fractional anisotropy, and radial diffusivity.