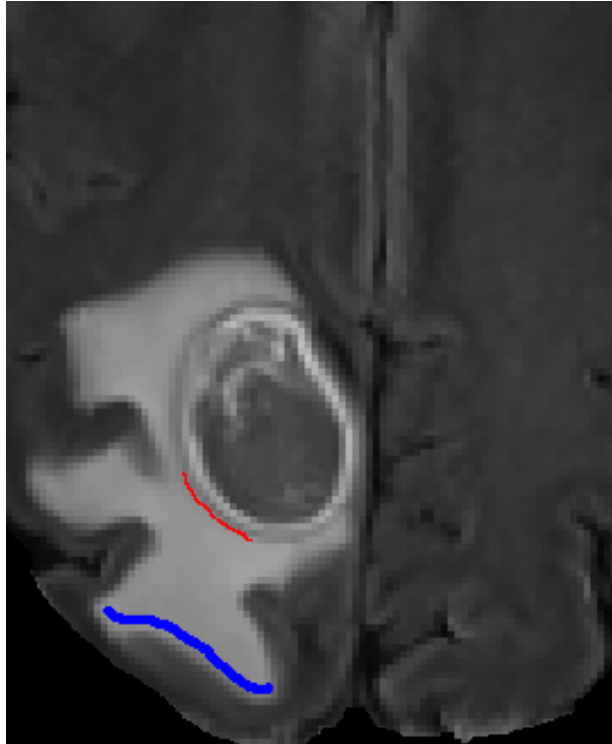


## SUPPLEMENTAL DIGITAL CONTENT 4



**FIGURE.** Regions of interest: Near-Far Regions of Interest. The figure depicts the near (**red**) and far (**blue**) region of interest. The red region is immediately adjacent to contrast enhancing tumor and the blue region is on the periphery of edema.