immune system, detection of inflammation, and serology testing for syphilis were normal. An EEG and visual, auditory, and somatosensory evoked potentials were normal. Brain and spinal cord MRI was normal. Analysis of CSF gave a protein content of 0·10 g/l with no pleocytosis and normal immunological findings. Three EMGs performed at two-year intervals (1985, 1987, and 1989) showed no evidence of denervation. A muscle biopsy performed in 1985 was normal. In June 1993, after 17 years of evolution, the patient's condition was stationary.

Mills described eight cases of a very slow advancing form of hemiplegia beginning usually in the extremity of a lower limb, then spreading up to the homolateral upper limb.[1-3] Five more cases were published between 1927 and 1951.[4-7] In those 13 and in our two cases pyramidal signs were always seen on the side of hemiplegia and often bilaterally (seven of 15 cases). A moderate amyotrophy without fasciculations is common (six of 15). The palsy can involve the face (five of 15). Sensory disturbances are usually absent but in a few cases (three of 15) minimal hypaesthesias have been noted. The manifestations very gradually worsen. Progression is more often ascending (13 of 15) than descending (two of 15). Involvement of both sides of the body has been reported in advanced stages (five of 15). A family history of the syndrome was not noted in any of the cases. The clinical picture presented by our two patients is identical to that described by Mills.[1-3] After an 18 and 17 year duration of development all manifestations were still unilateral except for increased tendon reflexes in case 2.

Mills' syndrome is supposedly due to primary degeneration of the corticospinal pyramidal pathways. Pathological examination has been performed in only one case[2]: the results showed non-specific, staged, irregular lesions of the pyramidal tracts predominating on one side at the level of the spinal cord and in the brainstem. The motor cortex was not involved; Betz cells were normal.

The scarcity of case reports and the availability of only one case confirmed by necropsy raise doubt as to the authenticity of this syndrome. Moreover, many reports date back to times when diagnostic methods did not allow reliable differential diagnosis. In this regard it should be said that ascending hemiplegia with Mills' syndrome-like features could be due to a variety of causes—for example, brain tumours, abnormalities of the cervical spine or cervico-occipital junction, small lacunar infarctions, pontine lesions, multiple sclerosis, or early stage amyotrophic lateral sclerosis. In our two cases the very slow progession of symptoms and the absence of any peripheral motor neuron involvement are inconsistant with amyotrophic lateral sclerosis. Similarly brain MRI, CSF examination, and evoked potentials in both cases ruled out multiple sclerosis. Finally, compression of the cervical spinal cord was not found.

Mills' syndrome could be considered as a variant of primary lateral sclerosis, which is characterised by a pure upper motor neuron syndrome related to a bilateral degeneration of the corticospinal pyramidal tracts. Several cases of primary lateral sclerosis have been documented after elimination of all other causes of spastic syndromes.[8-10] Pringle *et al*[10] proposed clinical and laboratory diagnostic criteria for primary lateral sclerosis: all of them are present in our two cases except for negative Lyme disease and HTLV-1 serologies which have not been tested. But Pringle *et al*[10] specified that these tests have to be done in endemic areas only and the south east of France is not such an area. Thus we propose that Mills' syndrome could be considered as the hemiplegic form of primary lateral sclerosis. We hope that this report will incite others to publish similar findings. Many more cases documented with current diagnostic technology will allow the confirmation or otherwise of the nosological authenticity of Mills' syndrome.

JEAN-LOUIS GASTAUT
FABRICE BARTOLOMEI
Service de Neurologie,
Hôpital de Sainte-Marguerite,
Marseille, France

Correspondence to: Dr Gastaut, Service de Neurologie, Hôpital de Sainte-Marguerite, BP 29, 13274 Marseille Cedex 09, France.

1 Mills CK. A case of unilateral progressive ascending paralysis probably presenting a new form of degenerative disease. *J Nerv Ment Dis* 1900;27:195–200.
2 Mills CK, Spiller WG. A case of progressively developing hemiplegia later becoming triplegia resulting from primary degeneration of the pyramial tracts. *J Nerv Ment Dis* 1903;30:385–97.
3 Mills CK. Unilateral ascending paralysis and unilateral descending paralysis. *JAMA* 1906;47:1638–45.
4 Guillain G, Thevenard D, Decourt J. Un cas de paralysie spinale ascendante chronique à prédominance unilatérale. *Rev Neurol* 1927; 1:585–98.
5 Decourt J. Un cas d'hémiplégie spinale ascendante chronique. *Rev Neurol* 1930;2: 557–60.
6 Lhermitte J, Albessar V. L'hémiplégie ascendante progressive à évolution prolongée. *Gazette des Hôpitaux (Paris)* 1934;11: 185–90.
7 Cossa P, Lombard P, Martin P. Sur deux cas de syndrome pyramidal lentement progressif et secondairement bilatéralisé. Syndrome de Mills? *Rev Neurol* 1951;84:327–30.
8 Gastaut JL, Michel B, Figarella-Branger D, Somma-Mauvais H. Chronic progressive spinobulbar spasticity. A rare form of primary lateral sclerosis. *Arch Neurol* 1988; 45:509–13.
9 Younger DS, Chou S, Hays AP, *et al.* Primary lateral sclerosis. A clinical diagnosis reemerges. *Arch Neurol* 1988;45:1304–7.
10 Pringle CE, Hudson AJ, Munoz DG, Kiernan JA, Brown WF, Ebers GC. Primary lateral sclerosis. Clinical features, neuropathology, and diagnostic criteria. *Brain* 1992;115: 495–520.

Separation of voluntary and limbic activation of facial and respiratory muscles in ventral pontine infarction

Selective paralysis of voluntary as opposed to limbically activated respiration has been described in a lesion affecting the ventral pons. We report a case in which we have also observed the activation of separate pathways serving voluntary and emotionally influenced facial expression as well as respiration.

A 27 year old white man developed sudden neck pain spreading to the right side of the face associated with deafness in the right ear and profuse vomiting. Two hours later he developed difficulty in walking, sonorous breathing, and episodes of shaking of all four limbs without loss of consciousness. He was unable to communicate and held his teeth clenched. On admission to hospital he developed a transient (10 minute) left hemiplegia followed three hours later by a complete right hemiplegia. Two hours later he became tetraplegic. Subsequent examination showed that he was responsive and alert: eye movements were full, volitional movements of the jaw, face, palate and tongue were absent but spontaneous and volitional blinking was preserved. He was unable to cough or take and hold his breath to command but spontaneous respiratory rhythm was preserved: he tended to obstruct his upper airway but when this was alleviated by intubation and, later, a tracheostomy, ventilation was adequate. He had an increase in extensor limb tone and the tendon reflexes were brisk with extensor plantar responses. Sensory testing was normal. General examination was unremarkable.

Magnetic resonance imaging showed an area of infarction in the right side of the pons extending inferiorly across the midline (figs 1 and 2). Cerebral angiography showed filling of the posterior inferior cerebellar arteries bilaterally but no contrast entered the basilar artery supporting the diagnosis of occlusion of the basilar artery. Clotting studies, other blood investigations, and echocardiography were normal.

Five days after the onset of the illness the patient was self ventilating via a tracheostomy when awake or asleep, with normal oxygen saturations and $PaCO_2$. The respira-

Figure 1 T2 weighted axial MRI at the level of the pons showing an area of increased signal in the ventral aspect of the pons extending across the midline to the left.

Figure 2 T1 weighted midline sagittal MRI showing a low signal area in the ventral pons.

tory rhythm was regular and he could not vary it voluntarily, cough, or take a deep breath to command. Tracheal suction generated vigorous coughing. Spontaneous and volitional blinking remained preserved but he could not voluntarily contract the muscles of the upper or lower face; In response to emotional stimuli, however, there were brisk and pronounced contractions of the upper and lower facial muscles that were generally of similar pattern whether he was upset or amused. When this occurred there were concomitant respiratory gasps involving both thoracic muscles and diaphragm on inspiration and abdominal muscles and latissimus dorsi on expiration.

At about five months and just before discharge he had regained some limited volitional control of facial muscles particularly on the right but emotionally induced movements remained much more pronounced. Some voluntary jaw opening and tongue movements had returned, his tracheostomy had been closed, and he was able to take limited nutrition by mouth. Before discharge records of his respiration showed that during quiet breathing his respiratory rate was 21/min with a tidal volume of 0·37 litres: a maximum inspiration from functional residual volume was 0·63 litres, and a maximum expiration from end tidal inspiration was 0·66 litres: involuntary sighs of up to 2·5 litres were recorded. He could hold his breath voluntarily for 10·5 seconds. Carbon dioxide rebreathing yielded a normal ventilatory response and ventilation was maintained in sleep with a normal Pa_{CO_2}. He remained tetraparetic.

This patient shows similar respiratory findings to those recently reported,[1 2] with loss of voluntary control of respiration but preservation of metabolic control and evidence of activation in response to emotional stimuli. Voluntary control of facial muscles other than blinking was also lost although pronounced activation with emotional stimuli was preserved. Separate nonvolitional pathways to the motor nuclei of the facial nerve are known to exist in uncontrolled crying or laughter as seen after stroke,[3] whether due to a lesion in the brainstem or due to cortical damage. Such displays of sentiment are activated by the limbic system and are usually under inhibitory cortical control. In this patient the loss of corticobulbar fibres descending through the ventral pons may affect volitional facial and respiratory movement, but emotionally stimulated activity must be mediated independently by fibres descending in the dorsal or lateral pons to terminate on the facial motor nucleus in the caudal third of the ventrolateral tegmentum, and on pontomedullary respiratory motor neurons.

We are grateful to Dr Owain Gibby (Royal Gwent Hospital) for permission to report a patient under his care and to Mr M Saunders (Lung Function Laboratory, Llandough Hospital, Cardiff) for assistance with respiratory recordings.

K DAWSON
M D HOURIHAN
C M WILES
Departments of Neurology and Radiology, University Hospital of Wales, Cardiff CF4 4XN, UK
J C CHAWLA
Department of Neurological Rehabilitation, Rookwood Hospital, Cardiff, UK

Correspondence to: Dr K Dawson, Ward C4 (Neurology), University Hospital of Wales, Cardiff CF4 4XN, UK.

1 Munschauer FE, Mador MJ, Ahuja A, Jacobs L. Selective paralysis of voluntary but not limbically influenced automatic respiration. *Arch Neurol* 1991;**48**:1190–2.
2 Plum F. Breathing is controlled independently by voluntary, emotional, and metabolically related pathways. *Arch Neurol* 1992;**49**:441.
3 Van Gijn J. Treating uncontrolled crying after stroke. *Lancet* 1993;**432**:816–7.

Screening for cognitive dysfunction in neurodegenerative illness

The current profusion of clinical trials of antidementia compounds adds renewed urgency for accurate patient screening. There are a number of brief assessment instruments for use by the clinician to aid in the determination of dementia or other cognitive dysfunction. All scales may not, however, be equivalent or interchangeable. We have investigated the equivalence of two particularly frequently used scales (mini-mental state examination[1] and the Mattis dementia rating scale[2]) in three clinically demented populations: a Huntington's disease group (n = 15), an Alzheimer's disease group (n = 13), and a Parkinson's disease group (n = 10). The Mattis scale and mini-mental examination were strongly correlated in the Alzheimer's disease sample (r = 0·78), but not in the Huntington's disease group (r = 0·15) or the Parkinson's disease group (r = 0·15). Further investigation of the subscales in each test yielded a possible explanation for these discrepancies. The tests comprise sets of subscales, each of which assesses function in a different domain of cognitive function. The only common domain covered by both tests is attention and memory. If these are the only domains of interest, then either test will suffice. Both functions are affected in Alzheimer's disease, which may underlie the strong correlation between the two tests in this group. Due to subcortical influences in Huntington's disease and Parkinson's disease, however, frontal lobe dysfunction tends to be a prominent part of the clinical presentation. Only the Mattis dementia rating scale assesses frontal lobe function in its conceptualisation, and initiation and perseveration subscales. In our samples, these two subscales were sensitive to overall dementia severity in the Huntington's disease group and the Parkinson's disease group, but not in the Alzheimer's disease group. No subtest scores on the mini-mental state exam achieved this level of sensitivity to subcortical dementia. Therefore, when integrity of the subcortex and frontal lobe may be of concern, the Mattis dementia rating scale seems to be the more appropriate screening tool to use.

L McFADDEN
M SAMPSON
E MOHR
Institute of Mental Health Research, Royal Ottawa Hospital, 1145 Carling Ave, Ottawa, Ontario, Canada K1Z 7K4

1 Folstein MF, Folstein SE, McHugh PR. Mini-mental state. *J Psychiatr Res* 1975;**12**: 189–98.
2 Mattis S. Mental status examination for organic mental syndrome in the elderly patient. In: Belak L, Karasu TB, eds. *Geriatric psychiatry*. New York: Grune and Stratton, 1976.

Role of the pulvinar in ideomotor praxis

The production of learned skilled movements (praxis) is mediated by a modular network of cortical and subcortical structures that may include the thalamus. We report a patient with a left medial occipital, inferior temporal, and pulvinar infarct who showed a bilateral ideomotor limb apraxia. We attribute her apraxia to the pulvinar lesion.

The patient was a 76 year old, right handed woman who had a left posterior cerebral artery embolic infarct. We followed up the patient from five to the end of 17 months after the stroke during which time her examination did not change. On examination she had a right homonymous hemianopia and mild increase of reflexes on the right with normal strength and sensation. She was fully orientated except to year. She produced fluent anomic speech with preserved auditory comprehension and repetition, had amnesia, colour anomia, acalculia, a lexical agraphia, and read by a letter by letter strategy. Her figure copying was apraxic. Oral praxis was normal. She showed an ideomotor limb apraxia bilaterally.

Magnetic resonance imaging of the brain with horizontal, coronal, and sagittal slices was performed at five months after the stroke (figure). The stroke involved the left medial occipital lobe, inferoposterior temporal lobe, and the pulvinar nucleus of the thalamus.

We tested the patient with several sections of the Florida apraxia battery. She was able to recognise all tools (for example, hammer, scissors) used in testing.

She was given the name of each of 20 tools (transitive gestures) and 10 intransitive gestures (meaningful gestures that do not involve tool use—for example, salute) and asked to demonstrate the appropriate gesture. She was asked to use her left hand to perform all requested gestures and, subsequently, to use her right hand. Error types[1] included content errors (the correct movement but for the wrong tool), temporal errors, spatial errors (errors in the movement, relation of the hand to the tool, or the

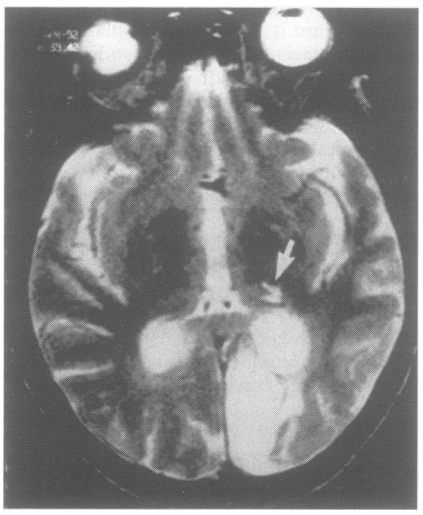

MRI of the brain performed five months after the patient's stroke. The infarct involves the left medial occipital lobe, inferoposterior temporal lobe, and the pulvinar nucleus of the thalamus.