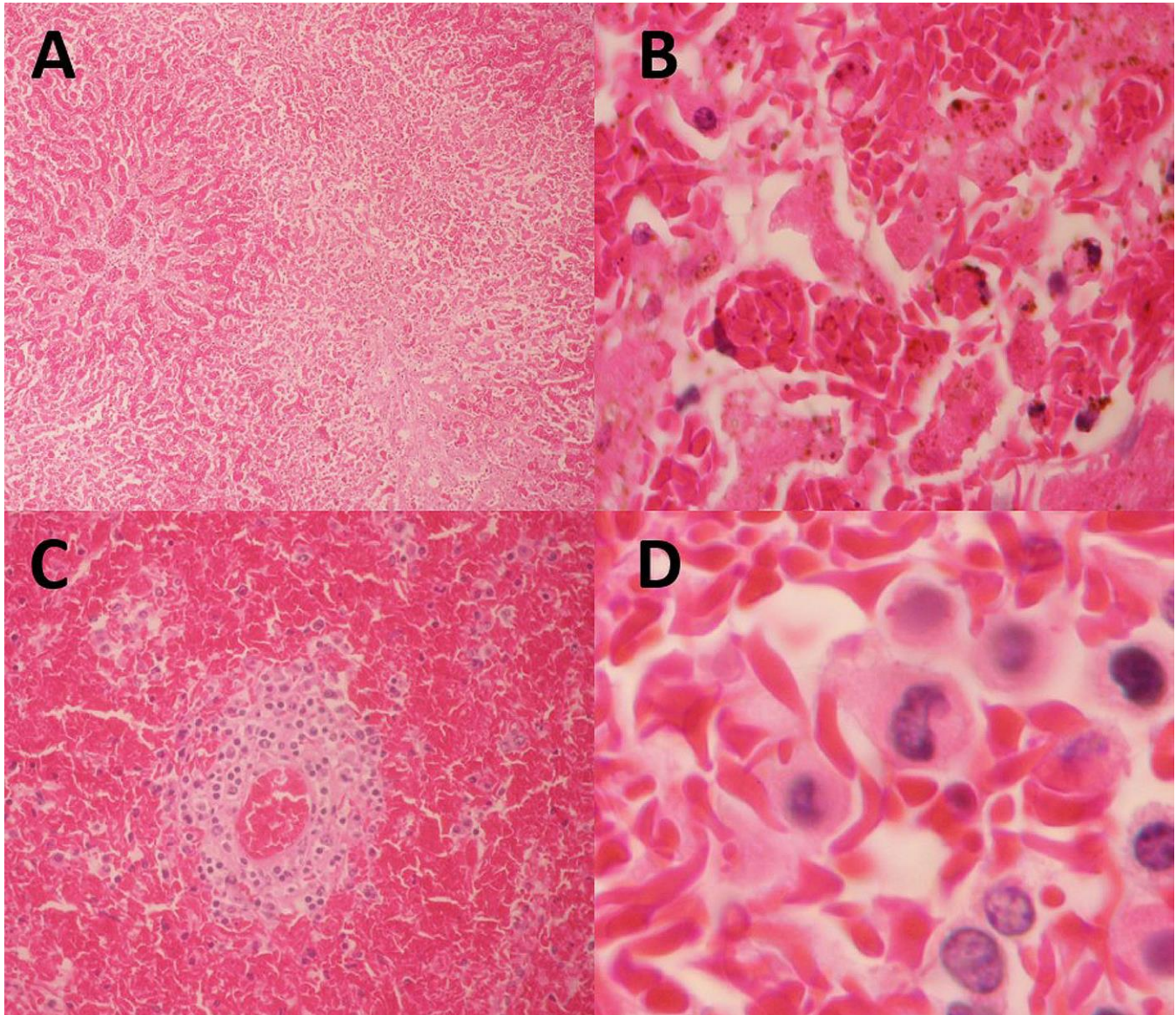


Fatal Zika Virus Infection in Patient with Sickle Cell Disease, Colombia

Technical Appendix



Technical Appendix Figure. Autopsy findings for liver and spleen of a 15-year-old girl with sickle cell disease who died of Zika virus infection, Colombia. A) Liver showing panacinar necrosis. B) Liver showing erythrophagocytosis of Kupffer cells. C) Spleen showing severe decrease of white pulp (functional asplenia). D) Spleen showing multiple splenic drepanocytes (splenic sequestration). (Hematoxylin and eosin stained) (Original magnification, $\times 10$ in A, $\times 40$ in B and C, $\times 60$ in D.)