

Electrocardiogram during cardiac rupture by myocardial infarction

A. A. H. Meurs, A. K. Vos, J. B. Verhey, and J. Gerbrandy

From the Department of Internal Medicine, the Cardiological Department, and the Pathological Department of the University Hospital 'Dijkzigt', Rotterdam, Netherlands

In 100 patients with acute myocardial infarction the electrocardiogram was continuously registered during 72 hours. Nine patients died of ventricular rupture (eight of the left ventricular free wall and one of the ventricular septum). In eight cases death occurred while the electrocardiogram was being recorded. A specific pattern of electrocardiographic changes seems to occur during acute tamponade, i.e. slowing of sinus rhythm followed by nodal rhythm.

Rupture of the left ventricle as a result of acute myocardial infarction is uncommon. Fabre (1965) indicates an incidence of 3 per cent (14/454), Lawrie *et al.* (1967) 0.75 per cent (3/400), and Dissmann *et al.* (1967) 6 per cent (13/216). Septal rupture is even less frequent: Horeau *et al.* (1967) give it as 1.2 per cent (39/3257).

The time of muscle rupture is variable. Fabre (1965) reported a preponderance of ruptures within 24 hours after the onset of infarction. Lodge-Patch (1951) noted a longer interval; 7 out of 9 cases ruptured within 3 to 10 days.

Electrocardiographic records during myocardial rupture have thus far not been described. Morton, Gardner, and McKinnon (1966) recorded an electrocardiogram just after the patient had gone into shock. Dissmann and coworkers (1967) reviewed 13 patients with myocardial rupture who had been monitored by means of an oscilloscope. Morton *et al.* noted in the terminal electrocardiogram, after rupture, a decrease in the amplitude of the QRS complex, and suggested that this was due to haemopericardium. Their detailed descriptions of the electrocardiographic events failed to indicate the changes during the exact moment of rupture.

It is the purpose of this study to describe the appearance of the electrocardiogram as it was recorded immediately preceding and during the occurrence of cardiac rupture in 8 patients admitted to hospital with acute myocardial infarction, and to report the relation between the time of rupture and the histological findings at necropsy.

Subjects and methods

The records of 100 consecutive cases of acute myocardial infarction at the University Hospital Dijkzigt were analysed. In each instance a continuously recorded cardiogram was available, taken over a period of 72 hours after admission. Of this group of 100 patients, 34 died; in 26 of the 34 the cardiogram was being recorded while death occurred. Nine deaths were due to ventricular rupture, eight of the left ventricular free wall and one of the ventricular septum (Table 1).

The diagnosis of myocardial infarction was based on the same criteria as proposed by Lawrie *et al.* (1967). The duration of the infarction was estimated from the history (onset of severe pain) and by a significant rise of the serum transaminase levels, within a 12-hour period. Patients whose infarction was judged to have occurred more than 24 hours before admission were excluded.

The cardiogram was registered with an ink-writing needle at a paper speed of 6½ mm. per second, by means of a Sanborn Viso Gardiette, Model 52.

Results

Clinical observations The entire series consisted of 19 women and 81 men. Thus the frequency of myocardial rupture appeared significantly higher among the women (4/19 = 21%, 5/81 = 6%). All patients who eventually died of a myocardial rupture were initially classified as having mild infarctions on the basis of clinical evaluation. All were without congestive cardiac failure or hypotension. All patients were treated in the conventional way with bed-rest, salt restriction, analgesics, sedatives, and oral anticoagulants. Digitalis, anti-arrhythmic agents, and α and β sympathomimetics were given where necessary.

A pacemaker catheter was inserted in 3 of the 5 patients with complete heart block. Of the 9 patients who developed myocardial rupture, 8 had received nicoumolone but none of them had had a prolongation of the prothrombin time beyond twice the control level.

Findings at necropsy The post-mortem findings are shown in Table 1, and the time of rupture in Fig. 1. There is a good correlation between the 'clinical' and 'histological' age of the myocardial infarction when the criteria of Lodge-Patch (1951) are applied. In two patients (Cases 6 and 7) there was evidence of an acute reinfarction. All ruptures occurred in areas of infarction with histological ages of less than 3 to 4 days. The size of the cardiac tear was $\frac{1}{2}$ to $1\frac{1}{2}$ cm. in those who died suddenly (Cases 1 to 5). The patients who had a less acute clinical course (Cases 7 to 9) differed in that one was found to have a clot in the perforation opening (Case 7), one had a minute rupture of only 2 mm. (Case 8), while Case 9, the only one which had had an attempt at pericardial aspiration, had a septal rupture with a tear of 3 cm. The tamponade in all cases was caused by intrapericardial blood varying in amounts from 250 to 550 ml.

Electrocardiographic findings In every instance there was a change in the cardiogram which, in retrospect, may represent the time of rupture. Visitors were present at the time Cases 4 and 9 went into shock and an entry was made on the recording paper. Cases 1 to 5 and Case 7 were found to have sudden alterations in the baseline of the electrocardiogram indicating sudden changes in

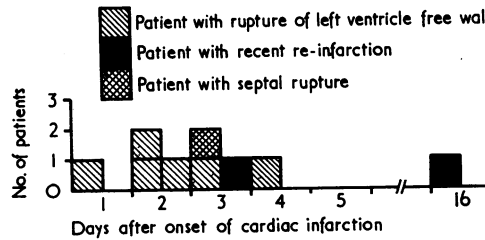


FIG. 1 Time of cardiac rupture after onset of acute infarction in 9 patients.

respiration and/or muscular activity. At the same time there was an acute change in the heart rate. Fig. 2 shows the electrocardiographic changes in composite strips of 4 patients. Cases 8 and 9 did not show these irregularities. In these instances the clinical events were less acute.

A seemingly consistent pattern was observed in all patients who died suddenly (Cases 1 to 5), with the following sequence: (1) a sudden slowing of the sinus rhythm (in 4 cases during 15 to 25 seconds); (2) a change to a nodal rhythm (varying from 15 seconds to 9 minutes); (3) a return to sinus rhythm (varying from 8 to 90 seconds); (4) a second episode of nodal rhythm; (5) an agonal rhythm (dying heart rhythm) (for full details see Table 2). In these 5 patients no decrease of amplitude of the QRS complex was visible.

Case 7, though differing clinically from the first 5 cases, showed similar electrocardiographic changes. In this instance the phase of return to sinus rhythm lasted for 67 minutes, while in all others this phase was a matter of seconds. At necropsy in this patient a

TABLE 1 Electrocardiographic and pathological findings in 9 patients with cardiac rupture during acute infarction

Patient No.	Age Sex (yr.)	Electrocardiogram site of infarction	Findings at necropsy					Clinical age (dy.)
			Site of arterial clot	Site of perforation	Size of cardiac tear	Haemopericardium	Histological age (dy.)	
1	77 F	Anterior	Left desc. anterior	Anterior left ventricle	$\frac{1}{2}$ cm.	250 ml.	$\frac{1}{2}$	$\frac{1}{2}$
2	91 F	"	" " "	" " "	$1\frac{1}{2}$ cm.	350 ml.	$1\frac{1}{2}$	$1\frac{1}{2}$
3	64 F	Antero-septal	" " "	" " "	?	400 ml.	$1\frac{1}{2}$	$1\frac{1}{2}$
4	80 F	Postero-lateral	Left circumflex	Posterior left ventricle	$1\frac{1}{2}$ cm.	400 ml.	4	$3\frac{1}{2}$
5	76 M	Antero-septal	Left desc. anterior	Anterior left ventricle	$\frac{1}{2}$ cm.	350 ml.	$2\frac{1}{2}$	3
6	65 M	Posterior	Right coron. art.	Posterior left ventricle	$1\frac{1}{2}$ cm.	550 ml.	16	$14 + 6$ hr.
7	66 M	Anterior	Left circumflex	Anterior left ventricle	$\frac{1}{2}$ cm.	350 ml. + clot	3	$4\frac{1}{2} + 6$ hr.
8	70 M	Postero-lateral	" "	Lateral left ventricle	2 mm.	250 ml.	2	2
9	74 M	Postero-septal	Right coron. art.	Septum left ventricle	3 cm.	(100 ml.)	$2\frac{1}{2}$	3

thrombus was found in the perforation opening.

The remaining two patients (Case 8 with the minute rupture of 2 mm. and the only one in whom resuscitation was tried and Case 9 with the septal rupture) not only had a clinical course which differed from that in the others but also deviated in their electrocardiographic pattern since they had first a speeding up of the sinus rhythm and then went into ventricular tachycardia.

Discussion

In this series, the incidence of rupture of the left ventricle was 9 per cent of the total series, and 26 per cent (9/34) of all causes of death after acute myocardial infarction. There appears no ready explanation for this high percentage when compared to those recorded in published papers.

Of the 9 patients with cardiac tamponade, 6 showed similar electrocardiographic events. The slowing of the sinus rhythm and the nodal rhythm was probably a vagal effect due to stretching of the pericardial sac by the sudden outpouring of blood. The peculiar temporary return to sinus rhythm may be explained by a temporary relaxation of the pericardial sac. Presumably when the entire space was filled and cardiac contraction was seriously impaired a nodal rhythm resumed. The question may be raised whether this sequence is a typical pattern with predictive value.

Case 8 with rupture of the left ventricular free wall and sinus tachycardia followed by ventricular tachycardia was the only one to be resuscitated: the rupture may have been caused by the heart massage.

Observations on 6 patients who went into

FIG. 2 *Electrocardiograms at the moment of rupture in 4 patients (Cases 1, 3, 4, and 5) with acute myocardial infarction.*

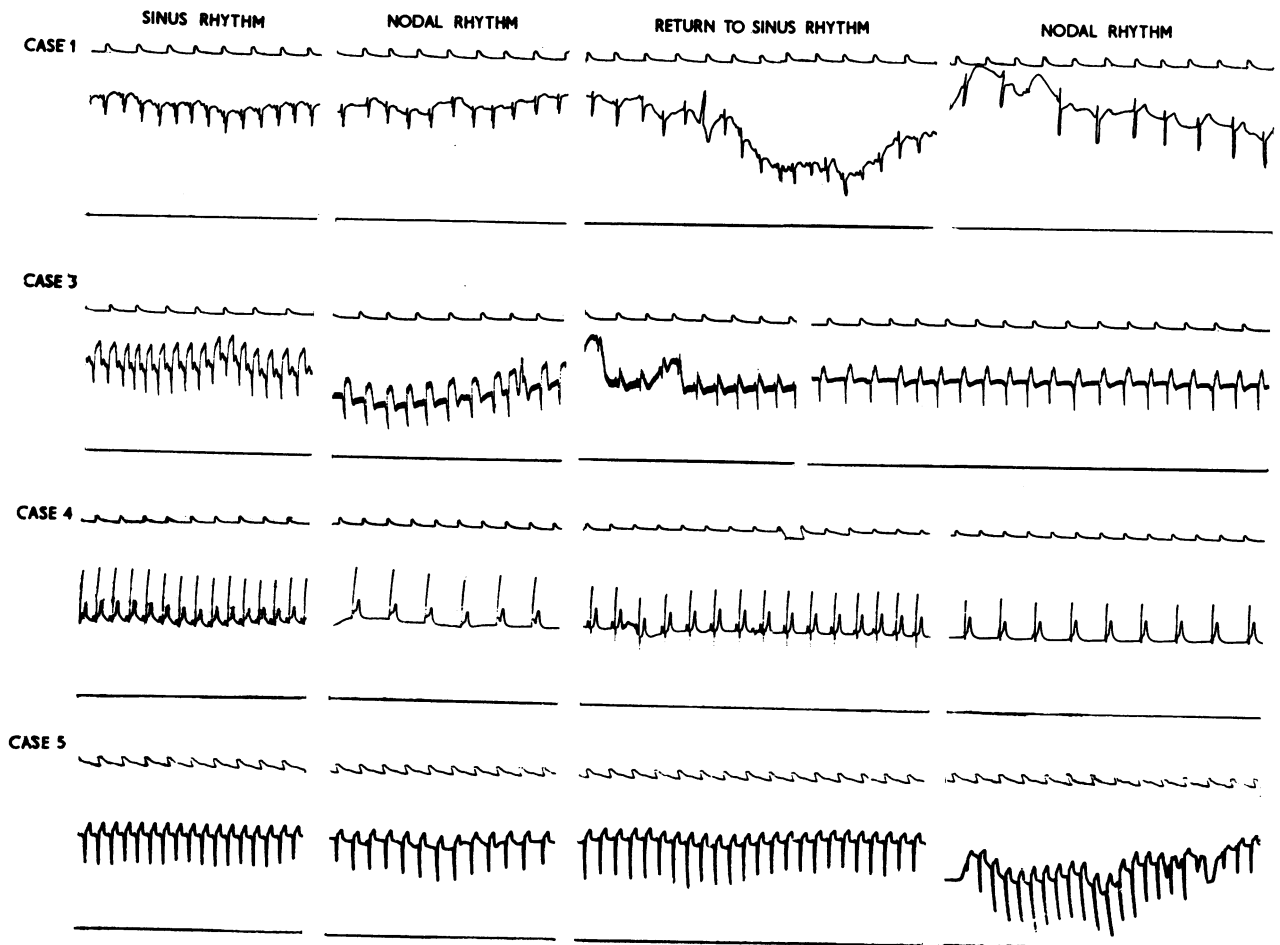


TABLE 2 *Electrocardiographic findings during myocardial rupture in 8 patients with acute infarction, and in 1 (Case 9) with septal rupture*

Patient No.	Age Sex (yr.)	Rhythm before rupture	Time before rupture	Sinus rhythm after rupture	Other rhythms	Nodal rhythm	Return to sinus rhythm	Nodal rhythm	Dying heart rhythm
1	77 F	Sinus rhythm	96 p.m.	15 sec.		78 p.m.	8 sec.	10 min.	12 min.
2	91 F	" "	120 p.m.	25 sec. 60 min.	1 min. Wandering pacemaker	9 min. 56 p.m.	97 p.m.	48 p.m.	19 min.
3	64 F	" "	120 p.m.	20 sec. 80 min.		2 min. 90 p.m.	20 sec. 84 p.m.	14 min. 72 p.m.	3 min.
4	80 F	" "	90 p.m.	20 sec. 66 min.		2 min. 50 p.m.	1½ min. 48 p.m.	2 min. 42-60 p.m.	2½ min.
5	76 M	" "	102 p.m.	15 sec. 84 min.		27 sec. 72 p.m.	55 sec. 96 p.m.	13 min. 82-100 p.m.	
6	65 M	" "	98 p.m.	20 sec. 66 p.m.		3 min. 44-60 p.m.	67 min. 144 p.m.	1 min. 40 p.m.	20 min.
8	70 M	" "	100 p.m.	5 min. 170 p.m.	7 min. Ventr. tachyc. 180 p.m.	Attempt at resuscitation during ±½ hr.			15 min.
9	74 M	" "	120 p.m.	28 min. 150 p.m.	1½ min. Ventr. tachyc. 145 p.m.				20 min.

shock after other cardiovascular disturbances during myocardial infarction revealed only a speeding of the sinus rhythm, and at necropsy no tamponade could be shown. Thus the tentative conclusion may be reached, that the sequence, slowing of the sinus rhythm - nodal rhythm - return to sinus rhythm - slow(er) nodal rhythm - in a patient suffering an acute myocardial infarction will predict imminent cardiac tamponade; circulatory collapse occurring under these circumstances should lead to immediate pericardial drainage.

Conclusions

Rupture of the left ventricular free wall is probably not as rare in acute myocardial infarction as has been thought. A slowing of the pre-existing rhythm followed by a nodal rhythm in a characteristic fashion in acute myocardial infarction may be an indicator of acute cardiac tamponade. Circulation collapse under these circumstances requires immediate pericardial puncture and/or operation. For early detection of acute tamponade

an electrocardiogram is not sufficient: continuous recording of haemodynamic parameters appears to be necessary.

References

- Dissmann, W., Schüren, K. P., Buschmann, H. J., Meyer, V., Schröder, R., and Thimme, W. (1967). Die klinische Diagnose der Herzruptur. *Zeitschrift für Kreislaufforschung*, **56**, 1067.
- Fabre, J. (1965). Pronostic et décours de l'infarctus du myocarde. *Schweizerische medizinische Wochenschrift*, **95**, 1553.
- Horeau, J., Nicolas, G., Bouhour, J. B., Orioux, J., and Gaillard, A. (1967). Les ruptures du septum interventriculaire dans l'infarctus du myocarde. *Actualités Cardiologiques et Angéiologiques Internationales*, **16**, 225.
- Lawrie, D. M., Greenwood, T. W., Goddard, M., Harvey, A. C., Donald, K. W., Julian, D. G., and Oliver, M. F. (1967). A coronary-care unit in the routine management of acute myocardial infarction. *Lancet*, **2**, 109.
- Lodge-Patch, I. (1951). The ageing of cardiac infarcts, and its influence on cardiac rupture. *British Heart Journal*, **13**, 37.
- Morton, D. E., Gardner, J. W., and McKinnon, G. E. (1966). Electrocardiogram in ventricular rupture after myocardial infarction. Case report. *American Heart Journal*, **72**, 817.