

Haemodynamic Features of Severe Endomyocardial Fibrosis of Right Ventricle, Including Comparison with Constrictive Pericarditis

K. SOMERS*, D. P. BRENTON, P. G. D'ARBELA, J. M. FOWLER,
B. R. KANYEREZI, AND N. K. SOOD

From the Department of Medicine, Mulago Hospital, and the Department of Physiology, Makerere University Medical School, Kampala, Uganda

Endomyocardial fibrosis, first described from Uganda by Davies (1948), is a disease of the heart characterized by a fibrosis of the endocardium and subendocardial layers of either the left or right ventricle or both. The fibrosis affects mostly the inflow tracts and the apices of the ventricles, and involvement of the papillary muscles may lead to mitral or tricuspid incompetence. The ventricular outflow tracts are unaffected and the aortic and pulmonary valves are normal. Van der Geld *et al.* (1966) have demonstrated a predisposition to auto-immune reactivity to the heart in endomyocardial fibrosis. Connor *et al.* (1967, 1968) have recently published a detailed account of the histopathology of endomyocardial fibrosis in Uganda. From a clinical survey of all cardiac diseases, excluding hypertensive heart disease, at Mulago Hospital, Somers and D'Arbela (1964) found the incidence of endomyocardial fibrosis to be approximately 12 per cent.

Over the past three years 28 patients with severe endomyocardial fibrosis of the right ventricle have been investigated here by right heart catheterization. Their clinical features are described elsewhere (Somers, Brenton, and Sood, 1968). This present paper records the observations made during catheterization of these patients, and compares the data with those obtained in 11 patients with constrictive pericarditis. The effect of an intravenous administration of a digitalis preparation in 11 patients with right ventricular endomyocardial fibrosis is reported. The results of a similar study have been published by Parry and Abrahams (1963). Many of their

patients had moderate pulmonary hypertension suggesting associated left ventricular endomyocardial fibrosis.

PATIENTS AND METHODS

The diagnosis of right ventricular endomyocardial fibrosis was suspected on clinical grounds in patients who presented with signs of severe right-sided heart failure without symptoms, signs, or radiological evidence of pulmonary congestion or pericardial calcification. Right heart catheterization was performed in these patients via an antecubital or saphenous vein. Pressures were measured using Statham pressure transducers and a 4-channel direct-writing Sanborn recorder. A point midway between the plane of the patient's sternum and the plane of the catheter table was taken as the zero pressure baseline. Cardiac outputs were measured by the direct Fick principle, a Kipp haemoreflexor being used to measure the oxygen content of blood samples from the pulmonary artery and either the brachial or femoral artery. Oxygen uptake was measured with a Benedict-Roth spirometer. The diagnosis of right ventricular endomyocardial fibrosis was confirmed in 19 of the 28 patients by cine-angiographic studies, the appearances being typically those described by Cockshott (1965). In a further 3 patients the diagnosis was confirmed at necropsy. In another 3 patients confirmatory evidence was obtained from the appearances of the heart at thoracotomy which had been undertaken to exclude constrictive pericarditis.

In 11 patients with right ventricular endomyocardial fibrosis either digoxin or acetyl strophanthin was injected through a cardiac catheter into the right atrium. The dose was 1.0–1.5 mg. according to the patient's size, diluted in 10 ml. of normal saline. With digoxin serial measurements of right atrial pressure and heart rate were made for 45 minutes and with acetyl strophanthin for 55 minutes. At the time of study 6 of the 11 patients were in regular rhythm and atrial fibrillation was present in the other 5. In some patients the cardiac output was

Received July 27, 1967.

* In receipt of grants from the Medical Research Council, London, and the British Heart Foundation.

TABLE I
RIGHT ATRIAL PRESSURES (MM. HG)

	a Wave	x Trough	v Wave	y Trough	Right atrial mean pressure
Endomyocardial fibrosis: 20 patients in sinus rhythm	16-29 (22.5)	8-23 (16.8)	14-28 (22.2)	6-19 (12.8)	11-26 (18.6)
Endomyocardial fibrosis: 8 patients with atrial fibrillation	—	—	19-34 (26.6)	11-28 (17.0)	16-31 (22.9)
Constrictive pericarditis: 10 patients in sinus rhythm	14-30 (22.2)	7-23 (15.3)	11-26 (20.2)	9-22 (13.4)	9-25 (17.9)

Note: The range of pressures is given in each instance with the average of the range underneath in brackets.

measured before and after injection of digoxin or acetyl strophanthin. Five of the 11 patients had never been treated with digitalis before the catheter study, and in the other 6 patients digitalis treatment was stopped at least 7 days before the catheterization.

Nine of the 11 patients diagnosed as having constrictive pericarditis had pericardial calcification and all of them had pericardiectomies performed by Mr. P. A. James in Mulago Hospital.

RESULTS

Right Atrial Pressures. Right atrial pressure records were obtained from all the patients with endomyocardial fibrosis for measurement of the *a*, *x*, *v*, and *y* waves and the mean right atrial pressure. Table I presents the range of values obtained in these patients and their averages, and contrasts them with similar data from 10 patients with constrictive pericarditis in sinus rhythm. The comparison is further presented in diagrammatic form in Fig. 1. Since tricuspid incompetence is probably the rule in severe right ventricular endomyocardial fibrosis, a dominant *v* wave might have been expected in all these patients. However, of the 20 patients in sinus rhythm, only 7 had a *v* wave bigger than the *a* wave (see Fig. 2, 3, and 4). Patients with endomyocardial fibrosis and atrial fibrillation tended to have higher right atrial pressures than those in sinus rhythm (Table I). The configurations of the right atrial tracings in patients with endomyocardial fibrosis and constrictive pericarditis were very similar. No patient with constrictive pericarditis had a *v* wave taller than the *a* wave. In both conditions the *y* descent is often the most obvious wave in the jugular venous pulse and its size and steepness is evident in the atrial pressure tracings (Fig. 2, 4, and 5). Right atrial pressure changes during inspiration and expiration were measured in some patients. Only rough comparisons were possible between patients with endomyo-

cardial fibrosis and those with constrictive pericarditis, because there was no standardization between patients of the depth and duration of inspiration and expiration. A rise of right atrial pressure during inspiration occurred in 7 out of 9 patients with constrictive pericarditis and a fall in the other 2. In 6 out of 15 patients with endomyocardial fibrosis, the right atrial pressure was either unchanged or increased during inspiration but it fell in the other 9.

Right Ventricular Pressures. Table II illustrates the range of values and the average values for the ventricular pressures in 27 patients with endomyocardial fibrosis and the 11 patients with constrictive pericarditis. The typical dip-and-plateau form of the right ventricular pressure tracing in endomyocardial fibrosis has been illustrated and described by others (Shillingford and Somers, 1961; Parry and Abrahams, 1963). Typical examples are

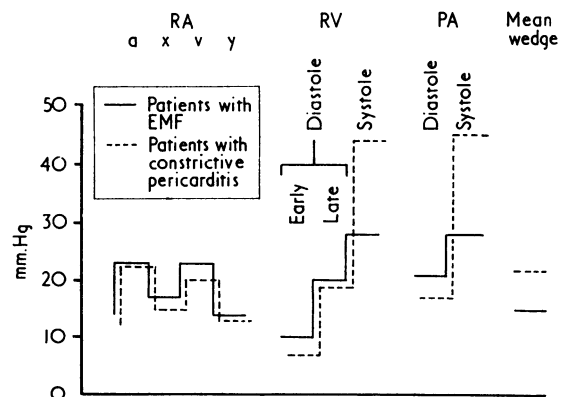


FIG. 1.—A comparison of the average pressures (mm. Hg) in 20 patients with endomyocardial fibrosis and 10 patients with constrictive pericarditis. Sinus rhythm was present in all the patients.

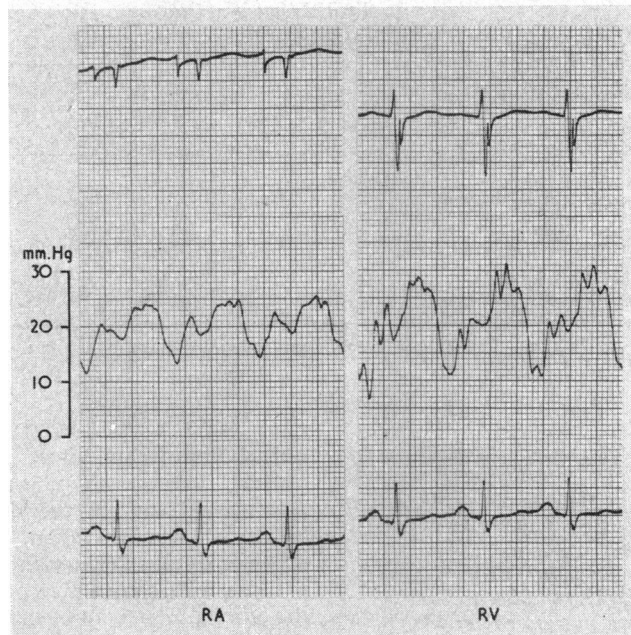


FIG. 2.—Patient with endomyocardial fibrosis in sinus rhythm. From above downwards, the traces are the intracardiac electrogram, right atrial (RA) and right ventricular (RV) pressures, and standard lead II electrocardiogram. Note the large dominant *v* wave in the atrial tracing, which is only slightly smaller than the ventricular systolic pressure. The right ventricular tracing has a dip-and-plateau form, the plateau being the same height as the atrial *a* wave.

shown in Fig. 1, 5, and 6. From the nadir of the dip in early diastole the pressure ascends rapidly to a plateau in late diastole, which is well seen in patients with atrial fibrillation and a slow ventricular

rate (Fig. 6). When the patient is in sinus rhythm the atrial *a* wave is superimposed upon this plateau (Fig. 5) following which the pressure usually rises further as a result of ventricular systole. In

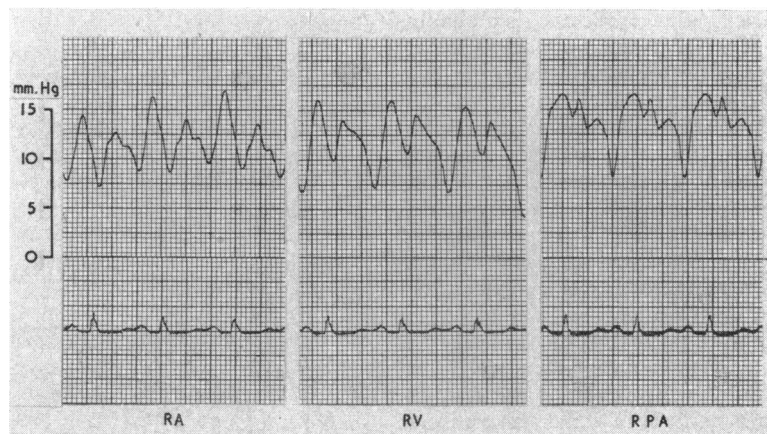

FIG. 3.—Patient with endomyocardial fibrosis in sinus rhythm. The traces are right atrial (RA), right ventricular (RV) and right pulmonary artery (RPA) pressures and standard lead II electrocardiogram. The *a* wave is dominant in the atrial tracing and is the highest deflection in the right ventricle and right pulmonary artery. The atrial *v* wave is equal in height to the ventricular pressure in systole.

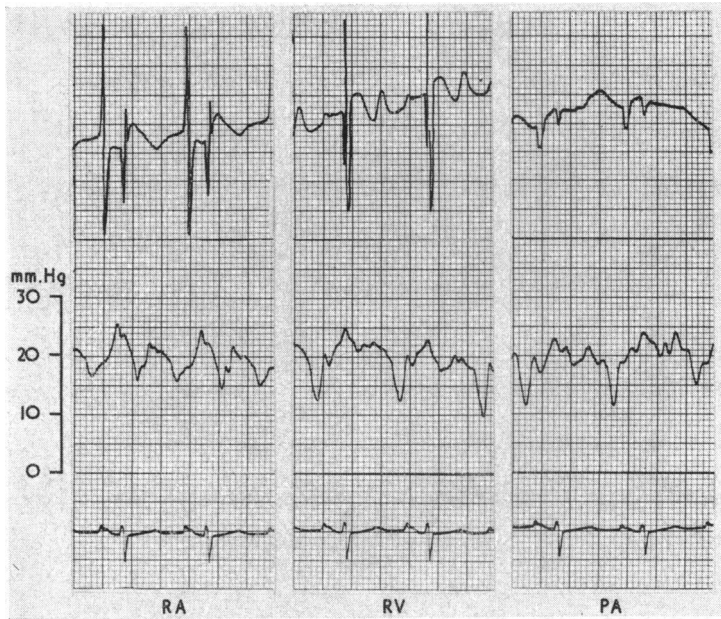


FIG. 4.—Patient with endomyocardial fibrosis in sinus rhythm. From above downwards, the traces are the intracardiac electrogram, right atrial (RA), right ventricular (RV), and right pulmonary artery (PA) pressures, and standard lead II electrocardiogram. The *a* wave is dominant in the atrial tracing and is the highest deflection in the right ventricle and right pulmonary artery. The atrial *v* wave is equal in height to the ventricular pressure in systole.

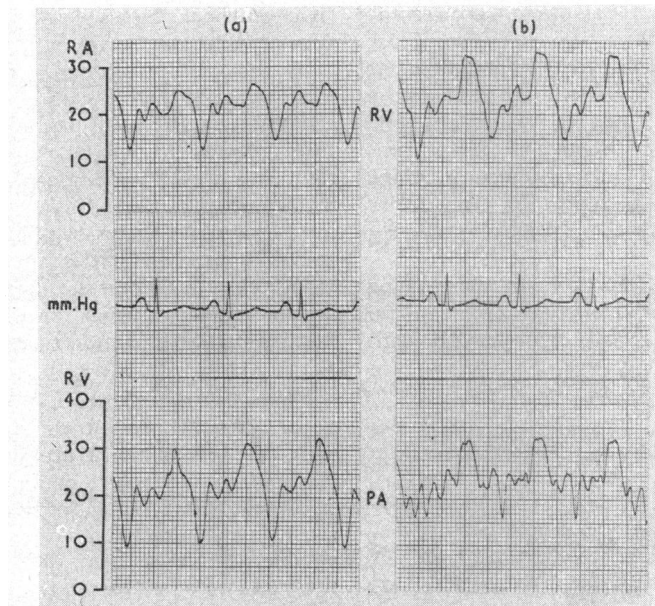


FIG. 5.—Double lumen catheter tracings from a patient with endomyocardial fibrosis in sinus rhythm. Right atrial (RA), and right ventricular (RV) traces were recorded simultaneously (a), as were right ventricular and pulmonary artery (PA) traces (b). The right ventricular tracing is dip-and-plateau in form. Two waves are visible on the plateau and both appear in the right atrial tracing before the *v* wave. The second of the 2 is the atrial *a* wave.

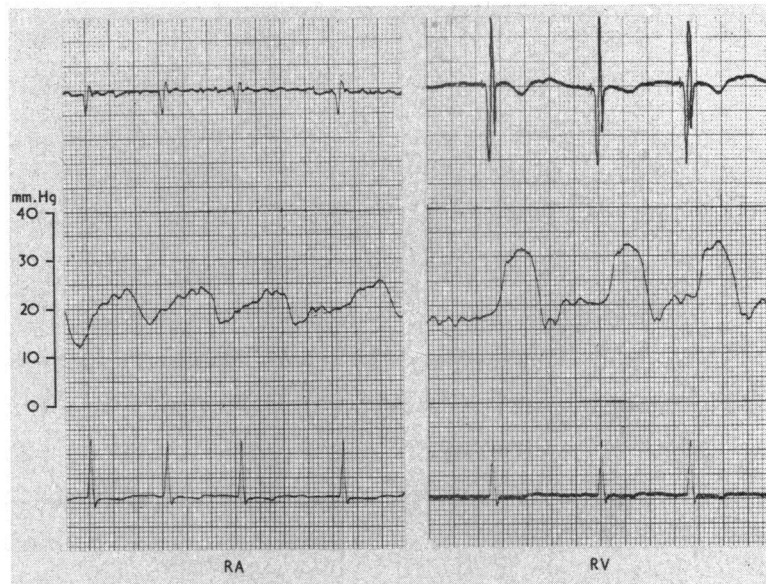


FIG. 6.—Patient with endomyocardial fibrosis and atrial fibrillation. From above downwards, the pressure tracings are intracardiac electrogram, right atrial (RA) and right ventricular (RV) pressures, and standard lead II electrocardiogram. Note the dip-and-plateau form of the right ventricular tracing.

patients with severe endomyocardial fibrosis of the right ventricle the rise of pressure during ventricular systole is very small and sometimes is less than that due to atrial contraction. Fig. 3 and 4 are recordings from 2 patients in whom peak right ventricular pressures were reached not in ventricular systole but during atrial systole. In 10 of the 28 patients the peak ventricular systolic pressure was equal to the height of the atrial *v* wave so that there was presumably gross tricuspid incompetence in these patients. In 7 other patients the ventricular systolic pressure exceeded the atrial by 5 mm. Hg or less.

The dip-and-plateau form of ventricular tracing also occurs in patients with constrictive pericarditis. Reference to Table II reveals that patients with

constrictive pericarditis nearly always have a mild or moderate pulmonary hypertension (Fig. 1) which has some diagnostic usefulness. The ratios of the right ventricular systolic pressure to the right ventricular end-diastolic pressure are plotted in Fig. 7. Only one patient with endomyocardial fibrosis had a ratio greater than 2.0, and only one patient with constrictive pericarditis had a ratio less than 2.0. Low ratios would only be expected in patients with right ventricular endomyocardial fibrosis since involvement of the left ventricle in this disease causes varying degrees of pulmonary hypertension and therefore high ratios. However, a very low ratio seems to favour the diagnosis of right ventricular endomyocardial fibrosis rather than constrictive pericarditis (see discussion).

TABLE II
RIGHT VENTRICULAR PRESSURES (MM. HG)

	Early diastolic	End-diastolic	Systolic	Right ventricular mean pressure
Endomyocardial fibrosis: 26 patients	1-25 (10.4)	11-28 (19.7)	16-48 (28.4)	14-32 (21.1)
Constrictive pericarditis: 11 patients	2-14 (7.1)	14-26 (19.5)	33-54 (44.1)	19-35 (26.9)

Note: The range of pressures is given in each instance with the average of the range underneath in brackets.

Pulmonary Pressures and Pulmonary Valve Function. Table III presents the range of pressures and their averages in the 2 groups of patients. Pulmonary artery pressure measurements were made in 26 patients with endomyocardial fibrosis, but satisfactory pulmonary wedge tracings were only obtained in 21 of them. Measurements of these pressures were made in all the 11 patients with constrictive pericarditis. The comparison between the 2 groups of patients is further illustrated in Fig. 1. Six of the patients with endomyocardial fibrosis had mild pulmonary hypertension (mean pulmonary artery pressure > 25 mm. Hg) with pulmonary

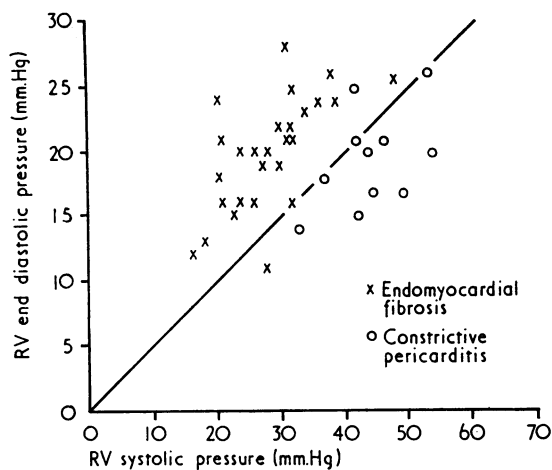


FIG. 7.—Right ventricular systolic and end-diastolic pressure in 27 patients with endomyocardial fibrosis and 11 patients with constrictive pericarditis. Points on the straight line have a systolic: end-diastolic pressure ratio of 2.0.

capillary pressures above the upper limit of normal (15 mm. Hg). This was most probably due to associated left ventricular endomyocardial fibrosis which was supported by the finding of a grade 2/4 mitral systolic murmur in 3 of them (Somers *et al.*, 1968). The other patients with endomyocardial fibrosis had pulmonary pressures in the normal range. Increased pulmonary pressures above normal were usual in the patients with constrictive pericarditis, and the pulmonary arterial pulse pressures were higher than in patients with endomyocardial fibrosis.

From a consideration of the pressure tracings in right ventricular endomyocardial fibrosis Parry and Abrahams (1963) suggested that the pulmonary valve might open during diastole rather than after the onset of ventricular systole. If the end-diastolic pressure in the ventricle exceeds the diastolic pressure in the pulmonary artery, then the pulmonary valve would open before the onset of ventricular systole, that is, during late diastole. That this occurs in some patients can be established by examining the information in Tables II and III, and the individual pressure records illustrated in Fig. 3 and 4.

From Tables II and III it can be seen that the average end-diastolic pressure in the right ventricle exceeds the average diastolic pressure in the pulmonary artery, suggesting that in some of the patients the pulmonary valve opens in late diastole. The point is better established by examining the individual pressure records. From Fig. 3 and 4 it can be decided that the pulmonary valve closed normally in these patients as the ventricle relaxed

and its pressure fell below the pressure in the pulmonary for only a very brief period, possibly as short as 0.04–0.08 sec., the pulmonary valve opening after this interval during ventricular diastole. Since these pressures were not recorded simultaneously this is an approximate calculation. In another patient (Fig. 8), the peak pulmonary artery pressure (19 mm. Hg) is reached at a point corresponding to the peak of the R wave in the electrocardiogram. The pressure could not have been rising at this point in the pulmonary artery unless the pulmonary valve had been open in diastole.

TABLE III
PULMONARY PRESSURES (MM. HG)

	Pulmonary artery diastolic	Pulmonary artery systolic	Pulmonary artery mean	Pulmonary capillary pressure
Endomyocardial fibrosis: 26 patients	7–27 (16.8)	16–48 (28.0)	12–40 (22.5)	7–28* (14.8)
Constrictive pericarditis: 11 patients	17–29 (21.5)	37–61 (45.2)	24–40 (30.9)	13–27 (22.1)

* Denotes that capillary pressures were measured in 21 patients.
Note: The range of pressures is given in each instance with the average of the range underneath in brackets.

Systemic Arterial Pressures. Systemic arterial pressures were measured in the femoral artery by intra-arterial needle in 26 patients with endomyocardial fibrosis and in all the 11 patients with constrictive pericarditis. The average systolic pressures in the two groups were 127 and 133 mm. Hg, respectively, and the average diastolic pressures were 77 and 80 mm. Hg. Changes in pressure due to inspiration and expiration were measured in some patients. The average inspiratory fall of pressure (pulsus paradoxus) in 15 patients with endomyocardial fibrosis was 10 mm. Hg systolic and 7 mm. Hg diastolic. The average fall of pressure in 7 patients with constrictive pericarditis was 21 mm. Hg systolic and 7 mm. Hg diastolic.

Cardiac Output and Stroke Volume. Measurements of cardiac output and stroke volume were made in 24 out of the 28 patients with endomyocardial fibrosis. The range of values and the average for the group are shown in Table IV where they are compared to the data available from the 11 patients with constrictive pericarditis. The cardiac index in most patients with endomyocardial fibrosis was low but in a few patients was normal or even raised, perhaps due to anaemia. Under resting conditions the more anaemic patients appeared to

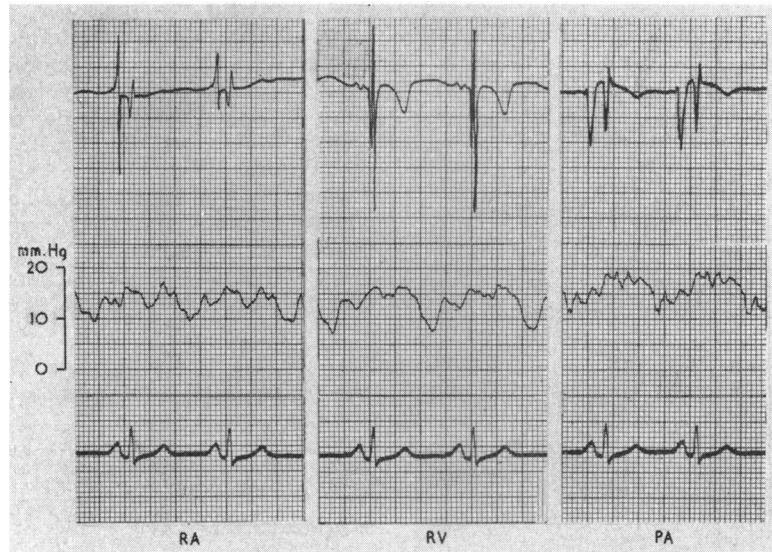


FIG. 8.—Patient with endomyocardial fibrosis in sinus rhythm. From above downwards, the traces are the intracardiac electrogram, right atrial (RA), right ventricular (RV), and pulmonary artery (PA) pressures, and standard lead II electrocardiogram. The *a* and *v* waves are equal in size in the atrial tracing which has a similar configuration to the right ventricular tracing. A peak systolic pressure of 19 mm. Hg is reached in the pulmonary artery before the onset of ventricular systole.

obtain their oxygen by increasing cardiac output rather than by increased oxygen extraction from the blood (Table V).

The values obtained from cardiac index, stroke, and heart rates were very similar in endomyocardial fibrosis and constrictive pericarditis. Slight arterial desaturation was present in both groups, being a little more marked in endomyocardial fibrosis. Breathing 100 per cent oxygen restored the systemic arterial saturation to normal values in all the patients with endomyocardial fibrosis.

Effects of Digoxin and Acetyl Strophanthin. Eleven patients received one of these two drugs.

The dose of acetyl strophanthin was always 1.5 mg. The dose of digoxin was either 1.0 or 1.5 mg., depending on the size of the patient. No toxic effects were found in any patient after these doses apart from occasional ectopic beats. Six of the 11 patients were in regular rhythm at the time of study. Atrial fibrillation was present in the other five.

Patients with Atrial Fibrillation. Six studies were performed in 5 patients (Fig. 9). Heart rates in these 6 studies ranged from 74 to 140/min. before administering digoxin or acetyl strophanthin. The average rate was 106/min. The heart rates, 45–55 minutes after the drugs, ranged from 67 to 110/min.,

TABLE IV
HAEMOGLOBIN CONCENTRATIONS, OXYGEN SATURATIONS, CARDIAC INDICES,
AND STROKE INDICES

	Haemoglobin (g./100 ml.)	Per cent arterial saturation	Per cent mixed venous saturation	Cardiac index (l./m. ² /min.)	Stroke index (ml./m. ² /min.)	Heart rate/min.
Endomyocardial fibrosis: 24 patients	5.4–16.0 (11.0)	82.5–95.4 (88.8)	36.6–58.0 (48.7)	1.5–5.7 (2.7)	21–52 (29.0)	65–140 (96)
Constrictive pericarditis: 11 patients	10.1–18.8 (12.5)	70.0–97.0 (91.3)	36.0–67.0 (56.0)	1.7–3.9 (2.6)	19–48 (30.0)	60–130 (91)

Note: The range of values is given in each instance with the average for the range underneath in brackets.

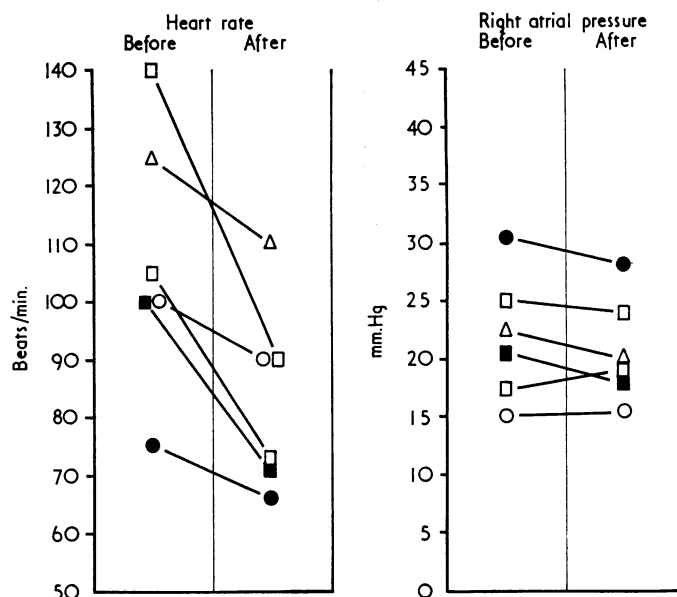


FIG. 9.—Heart rates and right atrial pressures in 5 patients with endomyocardial fibrosis and atrial fibrillation. Plotted values are those recorded before giving digoxin or acetyl strophanthin and those 45–55 minutes after the drugs. Each patient is shown by a different symbol. One patient (indicated by an open square □) was studied on two separate occasions.

the average being 83/min. The average fall of heart rate therefore was 23 beats/minute. Slowing of the heart was not accompanied by any significant change of right atrial pressure, the largest fall being 3 mm. Hg. The average fall was only 1 mm. Hg from an average right atrial pressure of 19 mm. Hg before the drugs were given. In only one patient was the cardiac output measured before and after the drugs and there was no significant increase in cardiac output 55 minutes after acetyl strophanthin.

Patients in Regular Rhythm. Six studies were performed in 6 patients. Before administration of the drugs the heart rates ranged from 75 to 110

beats/min., with an average rate of 93/minute. 45–55 minutes after digoxin or acetyl strophanthin the heart rates ranged from 70 to 100 beats/min., with an average rate of 88/min. The average fall of heart rate therefore was 5 beats/min. The largest fall of right atrial pressure in these 6 patients was 2 mm. Hg. The average change of right atrial pressure for the 6 patients after 45–55 minutes was zero. In 4 of the 6 patients the cardiac output was unchanged after digoxin. In the other 2 the cardiac index increased from 3.8 l./m.²/min. to 4.5 l./m.²/min. and from 2.9 l./m.²/min. to 3.3 l./m.²/min. Both of these patients had a small fall of right atrial pressure of 2 mm. Hg.

TABLE V

HAEMOGLOBIN SATURATIONS, CARDIAC INDICES, AND STROKE INDICES IN ANAEMIC AND NON-ANAEMIC PATIENTS WITH ENDOMYOCARDIAL FIBROSIS

	Haemoglobin (g./100 ml.)	Per cent arterial saturation	Per cent mixed venous saturation	Cardiac index (l./m. ² /min.)	Stroke index (ml./m. ² /min.)	Heart rate/min.
Anaemia: 10 patients	8.8	89.2	46.1	3.1	31.0	104
No anaemia: 14 patients	12.5	88.5	50.4	2.4	27.0	87

Note: Figures given are the average for each group. Patients were classified as "anaemic" if their haemoglobin values were below 11.0 g./100 ml.

DISCUSSION

The unique haemodynamic features found in patients with endomyocardial fibrosis of the right ventricle are attributed to the unilateral nature of the cardiac constriction. All the patients with endomyocardial fibrosis described here had severe disease of the right ventricle and most of them had little or no constriction of the left ventricle. Chronic constrictive pericarditis almost always causes constriction of both ventricles. Goodwin *et al.* (1961) have classified endomyocardial fibrosis as a constrictive cardiomyopathy and have also included in this group cardiac amyloidosis and scleroderma. None of these latter diseases, however, has been described as affecting only the right ventricle.

A number of patients with endomyocardial fibrosis had a pericardial effusion at the time of cardiac catheterization. In general the haemodynamic findings in patients with and without pericardial effusions were identical. Usually the pericardial effusion seems to cause little cardiac compression in patients with endomyocardial fibrosis though it may occasionally do so, as in Case 1 of Somers *et al.* (1968).

The high end-diastolic pressure in the right ventricle in endomyocardial fibrosis is consequent upon the low compliance of the chamber. This results in relatively large increases in pressure in early diastole following the dip, and the prominence of the atrial *a* wave in the ventricular pressure tracing. Right atrial enlargement is usual in right ventricular endomyocardial fibrosis but varied in degree among the patients reported here, and was not always obvious on the chest radiograph even when clearly demonstrable by angiocardiography. Associated P wave abnormalities occurred in half the patients in sinus rhythm, the abnormality being a wide bifid P wave (P mitrale) in most patients, but a typical P pulmonale was seen in 3 of them. Atrial fibrillation seemed to be associated with the presence of either a giant right atrium or a pericardial effusion, as it was present in half of the 16 patients with these features but absent in the other 12 patients with endomyocardial fibrosis without these features.

Tricuspid incompetence was probably present in all of the 28 patients with endomyocardial fibrosis. At necropsy severe degrees of right ventricular endomyocardial fibrosis are always associated with involvement of the papillary muscles and chordae by the fibrotic process and with a wide atrioventricular valve ring. Classical clinical features suggestive of tricuspid incompetence, such as a systolic venous wave in the neck, hepatic pulsation, or systolic murmur were found in only about one-third of the patients. The right atrial pressure tracing may suggest the presence of tricuspid in-

competence if there is a curtailed *x* descent and a dominant *v* wave, but these features were present in less than half of the patients in sinus rhythm. Cine-angiography has shown tricuspid incompetence in patients with endomyocardial fibrosis having a dominant *a* wave in the right atrial trace.

As the end-diastolic pressure in the right ventricle rises it approaches the pulmonary artery diastolic pressure in value and may exceed it. Under these circumstances it is probable that the pulmonary valve opens at the time of atrial contraction or even before. How much blood flows into the pulmonary artery during diastole cannot be determined simply from a study of pressure tracings, but it is possible that in the most severe cases the pulmonary artery is almost continuously perfused with blood from the high diastolic pressures in the ventricle. From the appearances of a typical right ventricular pressure tracing it appears that ventricular contraction is very weak because systole produces such a relatively small rise of pressure. However, the steep pressure rise which takes place in early systole in the normal heart occurs in the isometric phase when both tricuspid and pulmonary valves are shut. In severe endomyocardial fibrosis of the right ventricle, the tricuspid valve is incompetent and the pulmonary valve may open in late diastole. There is then no isometric phase of ventricular contraction as such, so that a steep rise of ventricular pressure in systole would not occur. This might explain why an apparently vigorous pulsation of the infundibulum of the right ventricle seen on cine-angiography is accompanied by such a poor systolic wave in the ventricular pressure tracing.

Although the numbers of patients with endomyocardial fibrosis and constrictive pericarditis in this study are small, the two groups seem worthy of comparison. They showed similar degrees of right ventricular constriction as judged by the values for the end-diastolic pressures which were almost the same in both groups. Values for the cardiac index, stroke index, and heart rate were similar in the two groups and restriction of filling of the right ventricle alone in endomyocardial fibrosis is just as effective in limiting cardiac output as restriction of both ventricles by pericardial disease. However, the cardiac output is probably not fixed since it appears to rise in compensation for an anaemia and has been reported to rise when patients with endomyocardial fibrosis do exercise (Parry and Abrahams, 1963). Constriction of both ventricles by pericardial disease, however, raises the pressure in the pulmonary circulation, whereas they are normal in pure right ventricular endomyocardial fibrosis. If both left and right ventricles are involved in endomyocardial fibrosis, then the pressure tracings may be identical

to those obtained in constrictive pericarditis. However, at least some of the patients with left ventricular endomyocardial fibrosis develop severe pulmonary hypertension (Abrahams and Brigden, 1961; Shillingford and Somers, 1961) which is not a feature of constrictive pericarditis. Early diastolic pressures in the right ventricle tend to be higher in endomyocardial fibrosis than in constrictive pericarditis. This probably indicates a more rigid and less distensible state of the ventricle in the former condition in which increase in volume in early diastole is severely limited. A value of less than 2.0 for the ratio of the systolic to end-diastolic pressure in the right ventricle was found in only one of the patients with constrictive pericarditis. A review of other published data in this condition indicates that a ratio below 2.0 may occur (Wilson *et al.*, 1954; Wood, 1961), but a ratio below 1.6 would be strongly in favour of a diagnosis of endomyocardial fibrosis. A dominant *v* wave in the right atrial trace is also helpful in excluding constrictive pericarditis, for though *v* may equal *a* in this condition it never exceeded it in our patients. This has also been the experience of others. The point is valueless in atrial fibrillation where there is no *a* wave to compare with the *v* wave. The angiographic appearances of severe right ventricular endomyocardial fibrosis described by Cockshott (1965) are distinctive and valuable in making this diagnosis certain.

Neither digoxin nor acetyl strophanthin seemed to have much effect in the patients with endomyocardial fibrosis in sinus rhythm. The most constant effect of intravenous digitalis preparations in patients with cardiac failure is a fall of right atrial pressure starting within about 10 minutes of administering the drug. Slowing of the heart rate and increased cardiac output may also be demonstrable (McMichael and Sharpey-Schafer, 1944). A fall of right atrial pressure greater than 3 mm. Hg did not occur in any of the 11 patients with endomyocardial fibrosis studied. The number of studies was few, but they confirm a clinical impression that digitalis preparations have little therapeutic value in this group of patients. Parry and Abrahams (1963) also administered digoxin to their patients during catheter studies and found little therapeutic response, but did not state whether or not they were in sinus rhythm. Slowing of the heart rate was observed in patients with endomyocardial fibrosis and atrial fibrillation after giving digoxin or acetyl strophanthin, but was not accompanied by a fall in right atrial pressure in our studies.

SUMMARY

The results of cardiac catheterization in 28 patients with severe endomyocardial fibrosis of the

right ventricle are described. The reduced compliance of the right ventricle results in a high end-diastolic pressure in this chamber and an increase in the right atrial pressure. The *a* and *v* waves of the right atrial trace are approximately equal in size in most patients, but either the *a* or the *v* wave may be the larger of the two. The *y* descent is always steep. In the absence of left ventricular endomyocardial fibrosis the pulmonary pressures are normal. Cardiac output and stroke volume are usually low in these patients. Patients with constrictive pericarditis have very similar right atrial pressure curves, but there is usually a greater rise of pressure during right ventricular systole and mild to moderate pulmonary hypertension. Digitalis preparations caused slowing of the heart rate in patients with endomyocardial fibrosis and atrial fibrillation, but this was not accompanied by any significant fall of right atrial pressure.

We are grateful to Professor J. F. Goodwin for much helpful advice and to Professor J. A. Tulloch for his encouragement. Mr. B. J. Milton and Mr. D. Havey have given skilled technical assistance without which these studies could not have been done. Mr. W. Serumaga drew the graphs and Mr. J. E. Busulwa supplied the photographs. The usefulness of intracardiac electrography was demonstrated to us by Dr. D. Emslie-Smith whose visit to Mulago Hospital was sponsored by Professor Sir I. G. W. Hill.

Generous research grants from the Medical Research Council (London) and National and Grindlays Bank (Uganda) to one of us (K.S.) financed the purchase of the equipment of the cardiac catheter laboratory. We have also received capital and recurrent support from the British Heart Foundation. A gift of acetyl strophanthin was made to us by Sandoz Ltd.

REFERENCES

- Abrahams, D., and Brigden, W. (1961). Syndrome of mitral incompetence, myocarditis, and pulmonary hypertension in Nigeria. *Brit. med. J.*, **2**, 134.
- Cockshott, W. P. (1965). Angiocardiography of endomyocardial fibrosis. *Brit. J. Radiol.*, **38**, 192.
- Connor, D. H., Somers, K., Hutt, M. S. R., Manion, W. C., and D'Arbela, P. G. (1967). Endomyocardial fibrosis in Uganda (Davies' disease) Part I, an epidemiologic, clinical, and pathologic study. *Amer. Heart J.*, **74**, 687.
- , —, —, —, and — (1968). Part II. *Amer. Heart J.*, **75**, 107.
- Davies, J. N. P. (1948). Endocardial fibrosis in Africans. *E. Afr. med. J.*, **25**, 10.
- Goodwin, J. F., Gordon, H., Hollman, A., and Bishop, M. B. (1961). Clinical aspects of cardiomyopathy. *Brit. med. J.*, **1**, 69.
- McMichael, J., and Sharpey-Schafer, E. P. (1944). The action of intravenous digoxin in man. *Quart. J. Med.*, n.s. **13**, 123.
- Parry, E. H. O., and Abrahams, D. G. (1963). The function of the heart in endomyocardial fibrosis of the right ventricle. *Brit. Heart J.*, **25**, 619.
- Shillingford, J. P., and Somers, K. (1961). Clinical and haemodynamic patterns in endomyocardial fibrosis. *Brit. Heart J.*, **23**, 433.

- Somers, K., Brenton, D. P., and Sood, N. K. (1968). Clinical features of endomyocardial fibrosis of the right ventricle. *Brit. Heart J.*, **30**, 309.
- , and D'Arbela, P. G. (1964). Heart diseases in Uganda. *Proc. Third Asian-Pacific Congr. Cardiol.*, **1**, 164.
- van der Geld, H., Peetoom, F., Somers, K., and Kanyerezi, B. R. (1966). Immunohistological and serological studies in endomyocardial fibrosis. *Lancet*, **2**, 1210.
- Wilson, R. H., Hoseth, W., Sadoff, C., and Dempsey, M. E. (1954). Pathologic physiology and diagnostic significance of the pressure pulse tracings in the heart in patients with constrictive pericarditis and pericardial effusion. *Amer. Heart J.*, **48**, 671.
- Wood, P. (1961). Chronic constrictive pericarditis. *Amer. J. Cardiol.*, **7**, 48.