

SHORT REPORT

The treatment of Gilles de la Tourette syndrome by limbic leucotomy

M Robertson, M Doran, M Trimble, A J Lees

Abstract

A patient with Gilles de la Tourette syndrome and severe self-injurious compulsions who had failed to respond to drug treatment and behavioural therapy obtained a complete and sustained resolution of his destructive behaviour and improvement in his tics following bilateral limbic leucotomy.

The Gilles de la Tourette syndrome is characterised by the presence of multiple motor and vocal tics which wax and wane in severity. Other commonly associated features include echo-phenomena, copro-phenomena, attention deficits and obsessional-compulsive behaviour. The disorder is usually lifelong, but the tics may be helped by dopamine receptor antagonist drugs and the compulsions by behavioural therapy. Self-injurious behaviour is also common.¹

Considerable clinical overlap exists between primary obsessional-compulsive disorder and Gilles de la Tourette syndrome and it has even been suggested that they may be different phenotypic expressions of the same genetic abnormality.² Compulsive behaviour occurs in both disorders but in Gilles de la Tourette syndrome there appears to be less voluntary resistance and whereas self-injurious behaviour is common it is extremely rare in primary obsessive-compulsive disorder.

There have been a few neurosurgical attempts to alleviate severe cases of Gilles de la Tourette syndrome. Improvement in both tics and compulsions has been reported following stereotactic coagulation of the rostral intralaminar and medial thalamic nuclei,^{3,4} lesions in the cerebellar dentate nuclei⁵ and following frontal lobotomies.^{6,7} Severe primary obsessive-compulsive disorder has also benefited following surgical lesions in the orbital frontal cortex and anterior cingulum. In a review of 374 patients from twelve neurosurgical series, 64% of patients improved considerably and a further 24% moderately.⁸ We report the case of a man with Gilles de la Tourette syndrome and compulsive self-injurious behaviour who was successfully treated by limbic leucotomy.

Case report

A nineteen year old trainee computer programmer was referred to the National Hospital for Nervous Diseases with a suspected diagnosis of Gilles de la Tourette syndrome. He had been born at term by Caesarian section following an ante partum haemorrhage due to placenta previa; he was nursed in an incubator for the first four days of his life. Developmental milestones were normal and he had had no severe febrile illnesses in the first five years of life. At five and a half years he developed inappropriate eye-winking and facial grimacing.

Over the next ten years he displayed a wide repertoire of motor tics. At fifteen he was compelled to open and close doors and showed other forms of checking behaviour. He had distasteful intrusive thoughts related to lurid scenes he had seen on television. Inapposite vocalisations began a year later with grunts which he attempted to incorporate covertly into conversation. Coprolalia and self-injurious behaviour began at the same time at seventeen years with head-banging, lip-biting, burning himself with cigarettes and putting his hand onto hot frying pans being the most destructive activities. He became fearfully obsessed that he might jump off high buildings. Two years later he developed an irresistible desire to touch the back of his eye. On several occasions he succeeded in this causing orbital haemorrhages and damage to the inner chamber of his eye, ulceration of the cornea and abrasions of his eyelids with chemosis. These serious injuries resulted in several emergency admissions to ophthalmological departments. Both eyes were attacked, but the right was favoured and he was unable to give a rational explanation for this abnormal behaviour.

On examination he had frequent eye-winking tics, facial grimaces, neck twitches and grunts. Both eyes were severely traumatised with conjunctival haemorrhages. A CAT scan of the brain and an electroencephalogram were normal. A pre-operative MRI scan revealed a single high signal focus in the region of the right globus pallidus of uncertain pathological significance (see figure). Neuropsychological assessments revealed a WAIS verbal IQ of 117 and a performance IQ of 114.

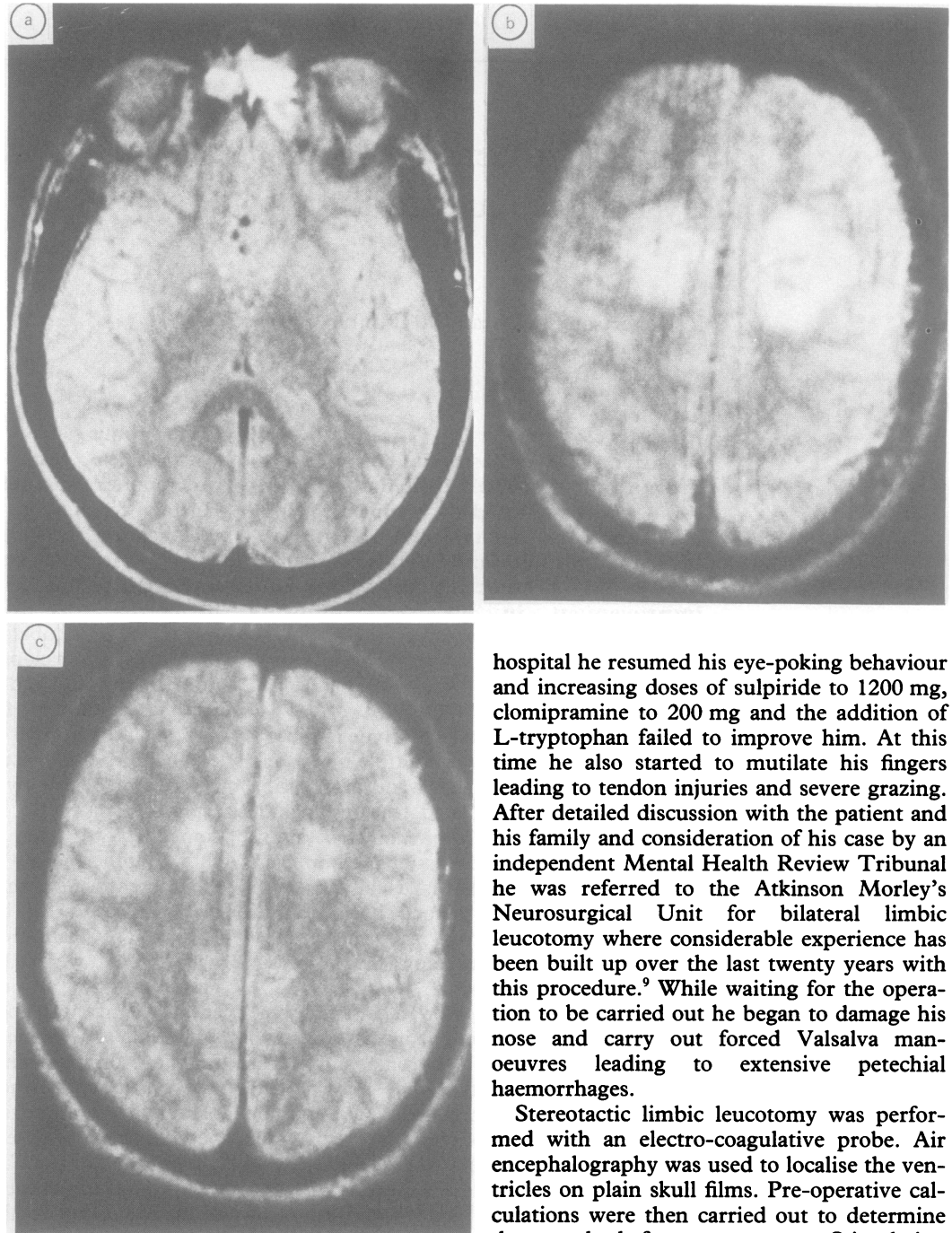
**The National Hospital
for Nervous Diseases,
London**
Department of
Neurology
M Doran
A J Lees
Department of
Psychiatry
M Trimble
**Academic
Department of
Psychiatry, The
Middlesex Hospital,
London**
M Robertson

Correspondence to:
Dr Lees, Department of
Neurology, The National
Hospital for Nervous
Diseases, Queen Square,
London WC1N 3BG,
United Kingdom.

Received 17 July 1989
and in revised form
13 October 1989.

Accepted 23 November 1989

Figure (A) MRI scan showing small high signal focus in the right globus pallidus seen in the patient pre-operatively; (B) MRI scan to show the surgical lesions following bilateral cingulotomy; (C) post-operative MRI scan six months following surgery.



He was treated with the D2 receptor antagonist drug sulpiride 200 mg twice a day with almost complete resolution of his tics. No improvement in his self-injurious compulsions occurred, however, despite a subsequent increase in the sulpiride to 1000 mg a day in three divided doses. He was admitted to a psychiatric ward as it was felt that he was in imminent danger of enucleating his right eye. At this time he was agitated and pessimistic with suicidal thoughts, disturbed sleep and weight loss. He was treated with chlorprothixene, another dopamine antagonist, in doses up to 500 mg a day and clomipramine 100 mg daily. Twenty four hour personal nursing care using response prevention behavioural techniques led to minor improvement over the two weeks.

However, shortly after his discharge from

hospital he resumed his eye-poking behaviour and increasing doses of sulpiride to 1200 mg, clomipramine to 200 mg and the addition of L-tryptophan failed to improve him. At this time he also started to mutilate his fingers leading to tendon injuries and severe grazing. After detailed discussion with the patient and his family and consideration of his case by an independent Mental Health Review Tribunal he was referred to the Atkinson Morley's Neurosurgical Unit for bilateral limbic leucotomy where considerable experience has been built up over the last twenty years with this procedure.⁹ While waiting for the operation to be carried out he began to damage his nose and carry out forced Valsalva manoeuvres leading to extensive petechial haemorrhages.

Stereotactic limbic leucotomy was performed with an electro-coagulative probe. Air encephalography was used to localise the ventricles on plain skull films. Pre-operative calculations were then carried out to determine the standard fourteen targets. Stimulation studies with a small bipolar electrode were conducted for the lower medial quadrant target through burr holes, confirmation of the correct location being taken when transient apnoea occurred. Lesions were made in both lower medial quadrants of the frontal lobes and separate lesions made in each anterior cingulum.^{10 11}

The patient was agitated immediately post-operatively, but then made an uneventful post-operative recovery and within two days of surgery his compulsions had markedly lessened and within six weeks had disappeared completely; he was then treated with further behavioural therapy. A post-operative scan showed bilateral, almost symmetrical signals in the centrum semiovale in the posterior part of each frontal lobe. These altered signals extended up to small cortical lesions and down to the anterior part of the cella media (figure).

A further MRI scan six months later showed a reduction in the size of the altered signal (figure); both the post-operative scans failed to demonstrate the area of altered signal in the globus pallidus seen pre-operatively. Post-operatively he had mild apathy, a mild degree of general intellectual impairment and some minor organisational problems and difficulties in concentration. His Leyton Obsessional Score fell from 17 pre-operatively to 8 post-operatively and the Maudsley Compulsions Check List to 1 post-operatively. He had a low Beck Depression Inventory Score of 4 both pre- and post-operatively. He was discharged after two months post-operative inpatient care to continue behavioural therapy as an outpatient. Over the next two months he became more self-motivated and was able to start a training programme as a decorator and then subsequently to obtain a job.

On review after two years he was socially independent, free from destructive behaviour and there had been a 75% reduction in the severity of his tics, which were now restricted to a single stereotyped shoulder tic. According to his mother he was now the same as before the operation with bouts of verbal aggression, and periods of self-doubt and anxiety. He continued on 1600 mg/day of sulpiride.

Discussion

The cingulate cortex may be important in the mediation of emotionally charged language. Stimulation of the anterior cingulate cortex in humans has led to a number of clumsy yet coordinated movements including: licking and rubbing the fingers and thumb together, glancing eye movements, oscillatory hand movements and touching the lips. These bear some similarity to the stereotyped movements often seen in Gilles de la Tourette syndrome.¹² Stimulation of this area also causes vocalisations in squirrel monkeys and there are a few reports of akinetic mutism in humans following bilateral damage. The anterior cingulate cortex has a rich dopamine innervation from the ventro tegmental area of the midbrain and there are extensive connections between this area of the limbic system and the corpus striatum.

Self-injurious behaviour is frequent in patients with Gilles de la Tourette syndrome who are referred to hospital. The dopaminergic system and neuropeptides have been implicated and it is of interest that a recent necropsy examination of a patient with Gilles de la Tourette syndrome showed total absence of dynorphin-like positive woolly fibres in the dorsal part of the external segment of the globus pallidus with similar, but milder, abnormalities in the ventral pallidum.¹³ However, attempts to modify tics and self-injurious behaviour with the opiate antagonist naloxone have been inconclusive.^{14,15} Self-injurious behaviour seems to be associated in patients with Gilles de la Tourette syndrome with high scores on obsessional and hostility measurements and there is also a correlation between the severity of tic disorder and the presence of self-injurious behaviour.¹

It would seem reasonable to look on self-injurious behaviour in Gilles de la Tourette patients as a particular form of compulsive behaviour but one which is rarely seen in primary obsessive-compulsive disorders. Self-inflicted eye injuries are more commonly seen in patients with schizophrenia or borderline personality disorders. We have, however, reported a further patient with Gilles de la Tourette syndrome and this particular form of mutilatory behaviour.¹

Further support for the possibility of anterior cingulate cortex involvement in the pathogenesis of Gilles de la Tourette syndrome comes from a positron emission tomographic study of cerebral glucose utilisation in 12 untreated patients in which a 15% reduction was noted in frontal cingulate and insular cortices.¹⁶ In their paper on the use of anterior cingulectomies in the treatment of psychiatric illness Whitty *et al*¹⁷ reported that the appearance of purposeless movements such as patting the bedclothes or rubbing the face occurred post-operatively in several patients and in one case a tic-like sniff developed.

They also report operating on a twenty five year old schizophrenic who had bizarre grimaces, mannerisms and echolalia as well as compulsive destructive outbursts who improved considerably following surgery.

In 1988 at the American Academy of Neurology, Kurlan *et al* described two patients with Gilles de la Tourette syndrome and severely disabling obsessive-compulsive disorder who were treated with stereotactic radio frequency anterior cingulotomy. A 22 year old man with rituals which made it impossible for him to dress, converse, eat or maintain urinary continence had a cingulotomy performed at the age of seventeen with transient improvement; a repeat cingulotomy four months later resulted in modest, persistent improvement. A second patient aged twenty eight, also with Gilles de la Tourette syndrome, had marked ritualistic slowness and was improved by surgery. Neither of these patients had self-injurious compulsions.¹⁸

We recommend that limbic leucotomy should be considered in patients with severe self-injurious behaviour related to Gilles de la Tourette syndrome. It is unclear at this stage whether disabling obsessions or tics and vocalisations can be lastingly improved by this procedure.

- Robertson MM, Trimble MR, Lees AJ. Self-injurious behaviour and the Gilles de la Tourette syndrome. A clinical study and review of the literature. *Psychol Med* 1989;19:611-26.
- Pauls DL, Leckman JF. The inheritance of Gilles de la Tourette syndrome and associated behaviours. *New Eng J Med* 1986;315:993-7.
- Hassler R, Dieckmann G. Traitement stereotaxique des tics et cris inarticulés ou copralalique considérés comme phénomène d'obsession motrice au cours de la maladie de Gilles de la Tourette. *Rev Neurol* 1970;123:89-106.
- De Devitiis E, Errico A, Cerillo A. Stereotactic surgery in Gilles de la Tourette syndrome. *Acta Neurochir (Wien) (suppl 24)* 1977:73.
- Nadvornick P, Sramka M, Lisy L, Suicka I. Experiences with dentatomy. *Confin Neurol* 1972;34:320-4.
- Baker EFW. Gilles de la Tourette syndrome treated by bimedial frontal leucotomy. *Canad Med Assoc J* 1962;86:746-7.

- 7 Stevens H. The syndrome of Gilles de la Tourette and its treatment. *Med Ann DC* 1964;33:277-9.
- 8 Yaryura-Tobias JA, Neziroglu FA. *Obsessive-compulsive Disorders*. New York: Marcel Dekker 1983:54.
- 9 Mitchell-Heggs N, Kelly D, Richardson A. Stereotactic limbic leucotomy—a follow up at 16 months. *Brit J Psychiat* 1976;128:226-40.
- 10 Richardson AE, Kelly D, Mitchell-Heggs N. Lesion site determination in stereotactic limbic leucotomy. In: Sweet WH, et al, eds. *Neurosurgical Treatment in psychiatry, pain and epilepsy*. Baltimore: University Park Press, 1977: 363-5.
- 11 Richardson AE. Stereotactic limbic leucotomy. Surgical technique. *Brit Postgraduate Med J* 1973;49:860-4.
- 12 Tailarach J, Bancaud J, Geier S, Bordas-Ferrer M, Bonis A, Szilka G. The cingulate gyrus and human behaviour. *Electroencephalogr Clin Neurophysiol* 1973;34:45-52.
- 13 Haber SN, Kowall NW, Vonsattel JP, Bird ED, Richardson EP. Gilles de la Tourette syndrome: a post-mortem neuropathological and immunohistochemistry study. *J Neurol Sci* 1986;65:225-41.
- 14 Sandyk R. The effects of naloxone in Tourette syndrome. *Annals of Neurol* 1985;18:367-8.
- 15 Gadoth N, Gordon CR, Streifer J. Naloxone in Gilles de la Tourette syndrome. *Annals of Neurol* 1985;21:415.
- 16 Chase TN, Geoffrey V, Gillespie M, Burrows GH. Études structurales et fonctionelles du syndrome de Gilles de la Tourette. *Rev Neurol* 1988;142:851-5.
- 17 Whitty CWM, Duffield JE, Tow PM, Cairns H. Anterior cingulectomy in the treatment of mental disease. *Lancet* 1952;i:475-81.
- 18 Kurlan R, Calne E, Lichter E. Surgical treatment of severe obsessive-compulsive disorder associated with Tourette's syndrome (abs) *Neurology* 1988;38(suppl 1):203.