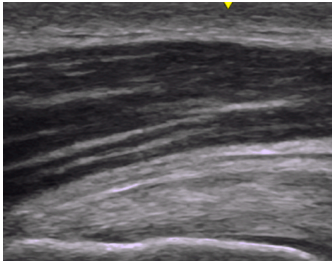
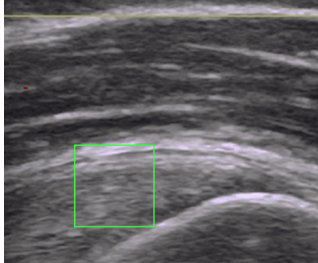
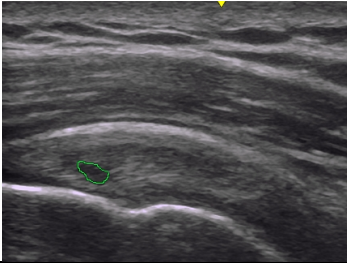
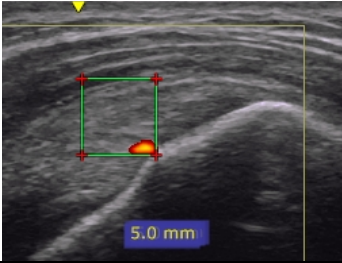
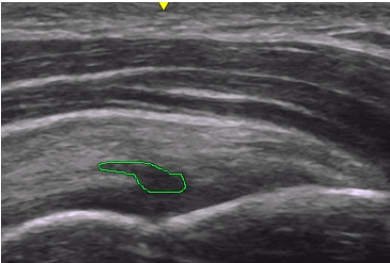
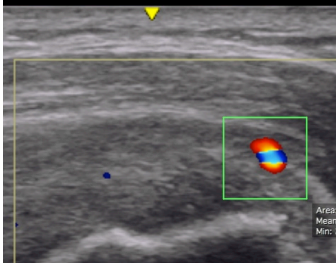
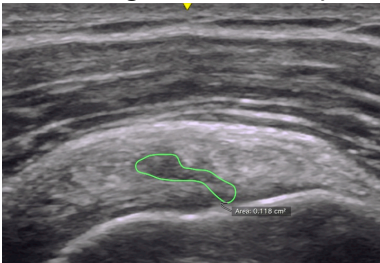
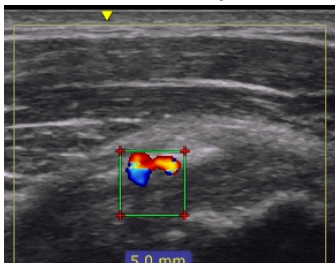


Appendix: Illustration of grading levels for fibrillar disruption and neovascularity

	Fibrillar disruption	Neovascularity
Grade 0	<p>Normal</p> 	<p>Normal (No signal)</p> 
Grade 1	<p>Mild (Involving under 25% of the height of the tendon)</p> 	<p>Mild (Single small signal in the Region Of Interest, ROI)</p> 
Grade 2	<p>Moderate (Involving 25-50% of the height of the tendon)</p> 	<p>Moderate (Doppler activity in less than 25% of the ROI)</p> 
Grade 3	<p>Severe (Involving more than 50% of the height of the tendon)</p> 	<p>Severe (Doppler activity in 25-50% of the ROI)</p> 
Grade 4	<p>Partial rupture (Disruption of the fibers in the full thickness of the tendon)</p> <p>No picture available</p>	<p>Extreme (Doppler activity in more than 50% of the ROI)</p> 