

Laryngeal electromyography in multiple system atrophy with autonomic failure

G M GUINDI, R BANNISTER, W P R GIBSON, AND J K PAYNE

From the National Hospital for Nervous Diseases, Guy's Hospital, and The Royal National Throat, Nose and Ear Hospital, London

SUMMARY In five patients with multiple system atrophy, electromyographic studies using a new surface electrode technique, showed unequivocal evidence of denervation of the posterior crico-arytenoid muscle, and in three of them, of the interarytenoid muscle or crico-pharyngeal sphincter. By comparison, only minor electromyographic abnormalities were found in one-third of patients with other extra-pyramidal syndromes, though in two cases, the abnormalities were of a different kind from those found in multiple system atrophy.

It is recognised that laryngeal stridor and defects of phonation are a feature of multiple system atrophy with autonomic failure (Shy-Drager syndrome).^{1,2} Necropsy studies have revealed marked histological changes in the posterior crico-arytenoid muscles, probably as a result of neurogenic atrophy, but Guidini *et al*³ have drawn attention to the occurrence of similar but much less severe changes in the majority of the normal adult population. A method of laryngeal electromyography (LEMG) using surface electrodes has been recently developed and is particularly suitable for the study of laryngological disorders.⁵ The opportunity was therefore taken to study the abnormalities in five patients with multiple system atrophy and autonomic failure in order to elucidate the nature of the muscular disorder giving rise to vocal cord disorder in these patients. They were compared with two patients with idiopathic Parkinsonism and autonomic failure, six patients with idiopathic Parkinsonism only, and one patient with idiopathic Parkinsonism with bilateral pyramidal signs. In recent years, both clinical and neuropathological distinctions have been made between multiple system atrophy with autonomic failure (Shy-Drager syndrome) and idiopathic Parkinsonism which may sometimes be associated with autonomic failure.^{5,6}

Patients and methods

We have studied the electromyographic (EMG) activity of the interarytenoid muscle, posterior crico-arytenoid muscle and in some cases the cricopharyngeal sphincter as well, in 14 patients with different neurological syndromes and in 18 normal adult controls using a surface electrode. All the patients with autonomic failure had been studied physiologically to confirm the postural hypotension and the defects of baroreflexes necessary to make this diagnosis. Cases 1 to 3 had in addition multiple system atrophy with extrapyramidal and pyramidal signs. Case 4 had multiple system atrophy with extrapyramidal signs only, and case 5 had multiple system atrophy with pyramidal and cerebellar signs. Cases 6 and 7 had idiopathic Parkinsonism with autonomic failure. The remaining cases had idiopathic Parkinsonism alone except for case 14 which was atypical in that there were also mild bilateral pyramidal signs.

The EMG surface electrode consists of two stainless steel plates within a silicone rubber tablet of rectangular shape. Two adult sizes are available, 1 × 1.5 cm and 1 × 2 cm, for slender and broad necks respectively, so as to fit snugly in the post-cricoid region. It is connected by 2 mm diameter plastic tubing to a standard electromyograph. The electrical signal is filtered, amplified and displayed on a cathode ray oscilloscope as well as by a loudspeaker. The latter allows recognition of EMG activity by listening without looking at the oscilloscope during the introduction of the electrode. After application of a suitable local anaesthetic, the electrode is easily swallowed and the position checked by the distance from the lips. The tubing is marked arbitrarily at 15, 16 and 17 cms.

The three muscles that can be examined electromyographically in this way are:

Address for reprint requests: Mr GM Guindi, The Royal National Throat, Nose and Ear Hospital, Gray's Inn Road, London WC1X 8DA.

Accepted 31 August 1980

Table LEMG findings in individual patients

No	Age	Sex	Diagnosis	Laryngeal dysfunction	IA	PCA	CPS	Remarks
1	59	M	Multiple system atrophy and autonomic failure	Present	Normal	Neuropathic	Neuropathic with giant potentials	Crico-pharyngeal sphincter patulous
2	53	F	Multiple system atrophy and autonomic failure	Present	Normal	Neuropathic with giant potentials	Normal	
3	57	M	Multiple system atrophy and autonomic failure	Present: tracheostomy required	Neuropathic with fibrillations	Neuropathic with fibrillations	Not done	Tracheostomy with speaking valve
4	56	M	Multiple system atrophy and autonomic failure	Minimal	Normal	Neuropathic with fibrillations	Not done	Mild dementia
5	58	M	Multiple system atrophy and autonomic failure	Minimal	Neuropathic with fibrillations	Neuropathic with giant potentials	Neuropathic	Multiple system atrophy with olivo-ponto-cerebellar degeneration
6	69	F	Idiopathic Parkinsonism with autonomic failure	Minimal	Normal	Normal	Normal	
7	64	M	Idiopathic Parkinsonism with autonomic failure	Absent	Normal	Normal	Normal	
8	68	F	Idiopathic Parkinsonism	Respiratory abnormalities at times of dyskinesia	Normal	Not done	Not done	Patient too weak to swallow the electrode
9	68	M	Idiopathic Parkinsonism	Absent	Normal	Normal	Normal	Postural hypotension secondary to stereotaxic thalamic lesions
10	72	F	Idiopathic Parkinsonism	Present	Normal	Bizarre high frequency discharges	Not done	Postural giddy spells suggesting mild postural hypotension
11	67	F	Idiopathic Parkinsonism	Absent	Neuropathic with giant potentials	Normal	Not done	Blood pressure normal
12	84	M	Idiopathic Parkinsonism	Absent	Normal	Normal	Not done	Blood pressure normal. Dementia
13	66	M	Idiopathic Parkinsonism	Absent	Normal	Not done	Not done	Blood pressure normal. Patient too weak to swallow the electrode
14	75	M	Idiopathic Parkinsonism	Present	Activity increased	Activity decreased	Normal	Hypertension for 10 years. Now controlled with Propanolol and diuretics. Bilateral pyramidal signs.

(1) The inter-arytenoid (IA), (2) The posterior crico-arytenoid (PCA), (3) The cricopharyngeal sphincter (CPS). All these muscles are supplied by the recurrent laryngeal nerve. The characteristic phasic changes in activity with respiration and the effects of breath-holding and phonation by saying "E" can be studied. During quiet respiration the IA is not usually active but its activity is increased on breath-holding and still more during phonation and so it has little importance in quiet respiration. The PCA is maximally active during inspiration and is the main abductor of the glottis. This activity decreases during expiration and to a greater extent during relaxed breath-holding, yet it is never completely abolished and during phonation its activity varies according to the pitch of the voice. By swallowing the electrode a little further and then gradually withdrawing it, the CPS is easily recognised by the resistance it provides to the passage of the electrode and so can be sampled. By this method the normal amplitude of the laryngeal motor unit potentials (MUPs) is 50–250 μv .

CASE REPORTS (see table)

Case 1 Multiple system atrophy with autonomic failure

Laryngeal dysfunction was present in the form of weakness of the voice for four years, stridor occasionally at night, but no sleep apnea. Slight dysphagia for fluids only, with occasional choking. Difficulty in coughing due to air escape through the glottic chink.

Indirect Laryngoscopy (IL): vocal cords mobile and although abducting to the full extent, sluggish in abduction and lax during coughing, allowing air to escape. *LEMG:* IA—normal, PCA—neuropathic pattern with decreased number of MUPs, some increase in amplitude but no giant potentials (fig 1). A normal trace is shown for comparison (fig 2). CPS—neuropathic pattern with decreased number of MUPs, increased amplitude and some giant potentials (fig 3). The electrode could be passed easily down into the oesophagus, without swallowing and subsequently withdrawn without any resistance from the CPS, indicating that it was patulous.



Fig 1 Neuropathic pattern in PCA with decreased number of MUPs




Fig 2 Normal trace of PCA for comparison with fig 1.

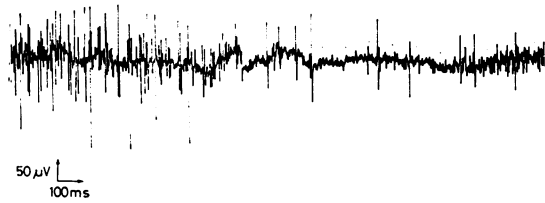

Fig 3 Neuropathic pattern in CPS with giant potentials in same patient as in fig 1.

Case 2 Multiple system atrophy with autonomic failure

Laryngeal dysfunction was present in the form of extreme weakness of the voice, with episodic aphonia but no sleep apnea and no stridor at night. There was dysarthria and dysphagia. The mouth was difficult to open and the base of the tongue showed increased resistance to passive stretch.

IL: good abduction of the vocal cords. *LEMG:* IA—there was decreased amplitude of the MUPs. PCA—neuropathic pattern with decreased number and increased amplitude and duration of MUPs with giant polyphasic potentials. The pattern was obvious during inspiration, less so during expiration and disappeared on breath-holding and phonation. CPS—normal.

Case 3 Multiple system atrophy with autonomic failure

Laryngeal dysfunction with periods of expiratory stridor and apnea, dysarthria, dysphagia for liquids, irregular breathing with respiratory rate varying between seven and 24 per minute.

IL: no abduction of the vocal cords. A tracheostomy was necessary and a No 34 tracheostomy tube with a speaking valve inserted. *LEMG:* IA—although an interference pattern could be recorded with difficulty on maximal phonation, on ordinary phonation there were almost no MUPs, while numerous fibrillation potentials appeared on respiration, with an amplitude of 30–40 μv and a duration of less than 1 ms (fig 4). PCA—MUPs completely absent with intermittent trains of fibrillation potentials with an amplitude of 20–30 μv . CPS—not done.

Case 4 Multiple system atrophy with autonomic failure

Minimal laryngeal dysfunction with soft voice and quiet slurred speech, varying from day to day, minimal dysarthria and no dysphagia. No stridor but snoring recently became louder. Poor memory, slight




Fig 4 Fibrillation potentials in IA during respiration.



Fig 5 Bizarre high frequency discharges in PCA.

impairment of intellect and mild dementia.

IL: normal. *LEMG:* IA—normal. PCA—MUPs were almost absent, with occasional fibrillation potentials on breath-holding. CPS—not done.

Case 5 Multiple system atrophy with autonomic failure

The patient had pyramidal and cerebellar signs. Cerebellar dysarthria with slow monotonous and slurred speech. No dysphagia, no stridor, no apnea.

IL: limited abduction of vocal cords on full inspiration. Otherwise normal. *LEMG:* IA—fibrillation potentials during respiration with a few slow negative potentials. PCA—neuropathic pattern with decreased number and increased amplitude of MUPs and numerous giant potentials on phonation. CPS—neuropathic pattern with decreased number of MUPs.

Cases 6–9 (see table)

Case 10 Idiopathic Parkinsonism

Blood pressure within normal limits. Laryngeal dysfunction in the form of involuntary episodic weakness of the voice, becoming squeaky and husky, without stridor or sleep apnea.

IL: normal. *LEMG:* IA—normal. PCA—bizarre high frequency discharges more evident during inspiration than expiration, appearing and disappearing suddenly with a more or less steady amplitude and frequency (fig 5). CPS—not done.

Case 11 Idiopathic Parkinsonism

Blood pressure within normal limits. No laryngeal dysfunction, no stridor.

IL: normal. *LEMG:* IA—neuropathic pattern on phonation and breath-holding with decreased number and increased amplitude of MUPs and giant potentials which were not polyphasic. PCA—normal. CPS—not done.

Cases 12 and 13 (see table)

Case 14 Idiopathic Parkinsonism with pyramidal signs

Extra-pyramidal rigidity with increased tone in all limbs and with mild bilateral pyramidal signs. Hypertension for 10 years, controlled with Propranolol and diuretics. Cerebral atrophy on CT. Laryngeal dysfunction causing episodic loss of voice for a few minutes, without actual hoarseness. No stridor at night. No sleep apnea.

IL: not done because of patient's inability to co-

operate. *LEMG:* IA—increased activity during quiet respiration but normal on phonation. PCA—decreased activity during respiration. CPS—normal. There was no evidence of denervation but a redistribution of activity in favour of the adductors.

Discussion

Marked EMG abnormalities were present in all five patients with multiple system atrophy and autonomic failure, while minor EMG abnormalities were present in only three cases with other extra-pyramidal syndromes. The intrinsic laryngeal muscles differ from the skeletal muscles in the smaller number of motor units. An average of only 140 units was present in the PCA and even less in the other laryngeal muscles.⁷ Their innervation ratio (the number of muscle fibres per unit) was also very small (average 15). By comparison in another study,⁸ 579 motor units were found in the gastrocnemius and 1934 fibres in each unit. This small number of units and fibres in the larynx is partly compensated for by their multiple innervation.⁷ As a result of this arrangement the interpretation of the recordings obtained by needle LEMG is often difficult. Surface LEMG, by comparison, gives much better results and is considered the method of choice for the delicate muscles of the throat and larynx.⁹ In all five patients with multiple system atrophy and autonomic failure, a denervation pattern was found in the PCA in each patient: fibrillation was present in two patients, one in the PCA only and the other in the PCA and IA. This patient required a tracheostomy. In the other three patients giant potentials were present in the PCA in two. One had partial denervation of the CPS and fibrillation potentials in the IA, while the third patient had partial denervation of the PCA and giant potentials in the CPS. In the nine patients with other forms of Parkinsonism, changes were only present in three cases and were much less marked. In the two patients with idiopathic Parkinsonism and autonomic failure, no EMG abnormalities were found. Of the six patients with idiopathic Parkinsonism only, one had bizarre high frequency discharges in the PCA, and another one had giant potentials, not polyphasic, in the IA during phonation and breath-holding. Finally one patient with, in addition to Parkinsonism, spasticity and pyramidal signs, had an increase of activity in the IA during respiration and a decrease of activity in the PCA, both of which were otherwise normal. This suggests a redistribution of tone in favour of the more powerful adductors and may be the result of pyramidal lesion.

The bizarre high frequency discharges found in one patient are still not understood. They were previously described as pseudomyotonic and thought to occur mainly in primary muscle disorders,¹⁰ yet they differ from those of myotonic dystrophy, since the latter occur after volition or mechanical irritation and wax and wane in frequency and amplitude. Recently Richardson and Barwick¹¹ have suggested that these bizarre discharges may occur in neurogenic disorders at anterior horn cell level.

The presence of EMG abnormalities in muscles, in addition to the PCA, is of interest since at first changes were found only in the PCA.³ These changes may result from severe metabolic disturbances due to repeated cycles of partial denervation alternating with collateral re-innervation.¹² It is possible that the changes in the PCA in the normal adult population and which may account for its selective vulnerability, are also of a similar nature.

It seems that in multiple system atrophy, a discrete focus of denervation, probably at nuclear level, occurs in some patients. This is not necessarily selective for the PCA but the PCA denervation is more likely to cause symptoms partly because of its more vital functions and partly because of some pre-existing degeneration previously reported by Guindi *et al*³ in apparently normal subjects.

Conclusion

A study using a new surface bipolar electrode to sample the posterior crico-arytenoid, inter-arytenoid and crico-pharyngeal sphincter, has revealed in all five patients with multiple system atrophy and autonomic failure unequivocal evidence of denervation of the posterior crico-arytenoid. This was partial in three, one of which showed also partial denervation in the crico-pharyngeal sphincter and another in the inter-arytenoid and crico-pharyngeal sphincter, and severe in the other two, one of which had respiratory obstruction requiring a tracheostomy. In this case, severe denervation was also present in the inter-arytenoid. The cause of the denervation is likely to be at the level of the nucleus ambiguus. By comparison only minor abnormalities were found in three out of the nine patients with idiopathic Parkinsonism, though in two cases there were abnormalities of a different kind from those found in multiple system atrophy. The use of surface LEMG represents a noninvasive method

of monitoring laryngeal function and in conjunction with the clinical picture can indicate when tracheostomy is needed to avoid episodes of respiratory obstruction which may be a cause of death.

We thank Dr C Greatorex, Department of Clinical Physics and Bio-Engineering, Guy's Hospital, for his co-operation, Dr L H Capel and Professor L Michaels, Dean of the Institute of Laryngology and Otolaryngology, for their support and encouragement, and Mr D J Connolly for the preparation of the photographs. Sir Roger Bannister wishes to thank the Parkinson's Disease Society for support.

References

- 1 Bannister R, Ardill L, Fentem P. Defective autonomic control of blood vessels in idiopathic orthostatic hypotension. *Brain* 1967; **90**:725-46.
- 2 Williams A, Hanson D, Calne DB. Vocal cord paralysis in the Shy-Drager syndrome. *J Neurol Neurosurg Psychiatry* 1979; **42**:151-3.
- 3 Guindi GM, Michaels L, Bannister R, Gibson W. Pathology of the intrinsic muscles of the larynx. *Clin Otolaryngol*. (In press).
- 4 Guindi GM, Higenbottam TW, Payne JK. A new method for laryngeal electromyography. *Clin Otolaryngol*. (In press).
- 5 Bannister R, Oppenheimer DR. Degenerative diseases of the nervous system associated with autonomic failure. *Brain* 1972; **95**:457-74.
- 6 Spokes EGS, Bannister R, Oppenheimer DR. Multiple system atrophy with autonomic failure. *J Neurol Sci* 1979; **43**:59-82.
- 7 Cathala HP, Chouard CH, Le Guerin J. Méthode d'analyse des tracés d'électromyographie laryngée. *J Fr Otorhinolaryngol* 1969; **1**:31-4.
- 8 Feinstein B, Lindegaard B, Nyman E, Wohlfart G. Morphologic studies of motor units in normal human muscles. *Acta Anat (Basel)* 1955; **23**: 127-42.
- 9 Guindi GM, Payne JK, Higenbottam TW. Clinical electromyography in ear, nose and throat practice. *J Laryngol Otol*. (In press).
- 10 Richardson AT, Barwick DD. Clinical electromyography. In: Walton JN, ed. *Disorders of Voluntary Muscle*, London: J & A Churchill, 1969: 822.
- 11 Richardson AT, Barwick DD. Clinical electromyography. In: Walton JN, ed. *Disorders of Voluntary Muscle*. Edinburgh: Churchill Livingstone, 1976: 1012.
- 12 Desmedt JE, Borenstein S. In: Rose FC, ed. *Motor Neurone Disease*. London: Pitman Medical, 1977: 114.