

Short report

The diagnostic value of H-index in S1 root compression

I AIELLO, G ROSATI, G SERRA, AND M MANCA

From the Neurological Clinic of the University of Ferrara, Ferrara, Italy

SUMMARY The H-index was studied in 42 healthy subjects and in 20 patients showing unilateral S1 root compression. When compared to the normal subjects, all patients showed a decreased H-index, or an increased difference in H-index between the sides or both. These results indicate that both parameters are valuable in the diagnosis of S1 root impairment due to intervertebral disc protrusion.

An increase in the latency of the H wave commonly is observed in conditions affecting the afferent or efferent fibres of the monosynaptic reflex. The H-reflex of the soleus muscle can be used to estimate S1 root compression. Measuring H-reflex latencies in spinal root injuries, Deschutere and Rosselle^{1,2} and Fisher *et al*³ have suggested that a difference in latency of 2 ms or more between the two sides can be considered as evidence of root lesions due to chronic compression, whereas a difference in latency of about 1 ms can be considered only as suggestive of such lesions. These data are not in our opinion conclusive, so we investigated the H-index and the difference in the H-index between the two sides in 20 patients suffering from unilateral S1 root compression, confirmed by both myelography and surgery. The values from these patients were compared with the normal values in 42 healthy subjects.

Methods

Patients Twenty patients (11 women, 9 men; mean age 46.5 years \pm 8, range 35-64) with clinical evidence of S1 spinal root compression were included in this study. No patient was suffering from other neurological disorders or general medical diseases which are known to cause peripheral nerve damage. The motor conduction velocity of the posterior tibial nerve was normal in all patients, ranging from 46.1 to 56.1

Address for reprint requests: Dr I Aiello, Clinica Neurologica dell'Universita, Corso Giovecca 203, 44100 Ferrara, Italy.

Accepted 26 August 1980

m/s. Intervertebral disc protrusion affecting S1 spinal root was subsequently confirmed by both myelography and surgery in all cases.

Electrophysiological examination The H-reflexes were detected with surface electrodes placed over the soleus muscle. The distance between electrodes was 3 cm, the cathode being placed proximally. Only triphasic waves were accepted. Rectangular electric pulses of 0.2-0.5 ms were applied in the middle part of the popliteal fossa to stimulate the posterior tibial nerve. The intensity of the stimulus was adjusted to obtain the maximum H-reflex amplitude. The frequency of stimulation was 0.2 Hz. The latency to the onset of the wave M and to that of the H-reflex was measured. The H-index was calculated as follows⁴:

$$\text{H-index} = \left(\frac{\text{height of subject in cm}}{\text{time interval H-M in ms}} \right)^2 \times 2$$

The normal values for both the H-index and the difference in the H-index between the sides were obtained from 42 healthy subjects (16 women and 26 men, mean age 37.3 years \pm 13, range 21-69).

Statistical evaluation Statistical analysis was performed using linear regression.

Results

The figure (A) shows the linear regression and the 95% confidence limits obtained in the 42 normal subjects comparing the H-index values (y) and the ages (x). The correlation coefficient (r) was 0.71. The normal values of the H-index are expressed by the following equation: $\hat{y} = -0.40x + 113.67$ (the standard error of the estimate (Syx) was 5).

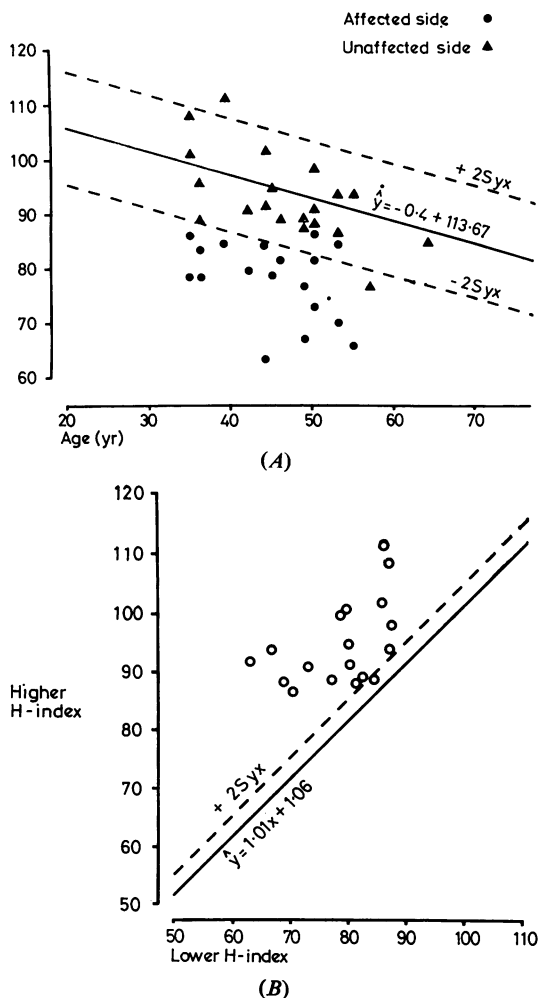


Figure A: Linear regression and 95% confidence limits comparing H-index and age in 42 normal subjects. The individual H-index values detected in 20 patients with unilateral S_1 root compression are indicated. B: Linear regression curve and 95% confidence limit comparing the higher H-index with the corresponding lower H-index in 42 normal subjects. Values corresponding to both higher (y) and lower (x) H-index in patients with unilateral S_1 root compression are indicated.

The H-index values detected in the 20 patients suffering from unilateral S_1 root compression also are shown in this figure. The H-index from the affected side (circles) was decreased in 18 patients, including two cases in which the H-reflex could not be recorded from the affected side. The two patients with a normal H-index on the affected side, however, showed an increased difference in

the H-index between the two sides. The H-index from the unaffected side (triangles) was normal in all the patients except one.

The figure (B) shows the linear regression obtained in the 42 normal subjects comparing the higher H-index value (y) with the corresponding lower value (x). The correlation coefficient (r) was 0.96. Using the equation of the linear regression $\hat{y} = 1.01x + 1.06$ (the standard error S_{yx} of estimate was 2), the \hat{y} for each x value (lower H-index) could be calculated. If y (higher H-index) was higher than $\hat{y} + 2S_{yx}$, the difference between the two sides was significant. In this figure, circles indicate both the lower (x) and the higher (y) H-index detected in each single patient. It can be seen that the difference in the H-index between the sides was increased in all the patients except one. This patient, however, showed decreased H-index value from the affected side.

Discussion

Studying both the absolute value of the H-index and the difference in the H-index between the two sides, abnormalities could be detected in all the patients suffering from unilateral S_1 root compression. Of the 20 patients included in the study, 17 showed abnormal values for both the H-index and the difference in the H-index between the sides, two showed only a difference in the H-index between the two sides, and one had only a decreased value of the H-index on the affected side. These results indicate that the combined estimation of both the H-index and the difference in the H-index between the sides is the most reliable method for the electrophysiological diagnosis of S_1 root compression due to disc protrusion.

References

- 1 Deschujtere J, Rosselle N. Electromyographic and neurophysiological investigation in root compression syndromes in man. *Electromyogr Clin Neurophysiol* 1970; **10**:339-40.
- 2 Deschujtere J, Rosselle N. Diagnostic use of monosynaptic reflexes in S_1 root compression. In: Desmedt JE, ed. *New Developments in Electromyography and Clinical Neurophysiology. Vol 1*. Basel: Karger, 1973; 497-511.
- 3 Fisher MA, Shivde AJ, Teixeira C, Grainer LS. The F response: a clinically useful physiological parameter for the evaluation of radicular injury. *Electromyogr Clin Neurophysiol* 1979; **19**:65-75.
- 4 Guiheneuc P, Ginet J. Le réflexe de Hoffman. Signification de l'intervalle entre les réponses H et M, et intérêt de sa mesure chez l'homme. *C R Soc Biol* 1971; **165**:1763-66.