

tasis and hepatocellular dysfunction (elevated alkaline phosphatase 1124 IU/l, elevated SGOT and SGPT and reversal of albumin globulin ratio). Immunoelectrophoresis showed raised IgG (26.10 g/l), IgM (1.95 g/l) and IgA 8.60 g/l). The chest radiograph was normal; skull radiographs showed a massive osteolytic lesion in the left parietal bone corresponding with the clinically palpable scalp swelling. On the basis of above findings a diagnosis of cirrhosis of liver with metastatic carcinoma of unknown origin was made. The patient lapsed into coma and died on the seventh day. At necropsy the positive findings included severe bronchopneumonia, diffuse micronodular cirrhosis of liver with antemortem portal vein thrombosis and total replacement of the right lobe of liver by a necrotic haemorrhagic tumour with microscopic features of undifferentiated hepatocellular carcinoma, along with multiple small separate foci of hepatocellular carcinoma. The skull vault deposit was not infiltrating but was compressing the underlying left fronto-parietal cerebral hemisphere, and had microscopic similarities to the hepatic primary. Additional tumour deposits were present in the left sixth rib and left adrenal gland.

The subject of elevated immunoglobulins in patients with hepatoma has been studied in detail by Ipp *et al.*³ Hepatic carcinoma can present with metastatic deposits, the common sites being lung, bones and lymph nodes. Al-Sarraf *et al.*⁴ reported that 30-70% of patients with liver cancer had metastasis at the time of clinical diagnosis, although it is unclear what percentage of these secondaries were symptomatic. Amongst the neurological complications reported are vertebral metastasis with cord compression⁵ and cerebral gigantism in a child.⁶ There has been a solitary case report in the literature⁹ of a 62-year-old lady, who repeatedly presented for nine years with multiple osteolytic deposits including an asymptomatic skull vault deposit and who at necropsy following cerebral bleeding due to hypertension, was shown to have metastatic hepatocellular carcinoma.

The syndromes of upper cranial nerve palsies as in our first patient and mild right hemiparesis in the second patient owing to metastases from hepatocellular carcinoma has not, to our knowledge, been previously reported. There has been no report of metastasis actually in the cerebral tissue, and in the case cited above

and in both our patients there was no infiltration of cerebral parenchyma, and it is possible that this reflects a peculiarity of this tumour. We suggest that, when investigating patients with suspected cranial secondaries particularly if there is a bony involvement, serum alpha foeto-protein and hepatic ultrasound should be carried out as screening procedures.

We thank Dr S Ward for providing details about the second patient and for her expert comments on the necropsy material.

JG PHADKE

*Department of Medicine (Neurology),
Aberdeen Royal Infirmary,
Aberdeen*

RC HUGHES

*Consultant Neurologist,
Newcross Hospital,
Wolverhampton*

References

- Byrne MJ, Scheinberg MA, Mavligit G, Dawkins RL. Hepatocellular carcinoma: presenting with vertebral metastases and radicular compression. *Cancer* 1972;30:202-5.
- Weekly clinicopathological Case No. 46231. *New Engl J Med* 1960;262:1182-8.
- Ipp T, MacNab GM, Geddes EW, Kew MC. Serum immunoglobulin levels in primary liver cancer; relationship to underlying cirrhosis and hepatitis-B (surface) antigenaemia. *Br J Cancer* 1975;32:509-11.
- Al-Sarraf M, Kithier K, Vaitkevics VK. Primary liver cancer. *Cancer* 1974;33(2):574-82.
- Kennedy JC, Stern WE. Metastatic neoplasms of the vertebral column producing compression of the spinal cord. *Am J Surg* 1962;104:155-68.
- Sugerman GI, Heuser ET, Reed WB. A case of cerebral gigantism and hepatocarcinoma. *Am J Dis Child* 1977;131:631-3.

Received 19 June 1981 and in revised form 9 September 1981
Accepted 26 September 1981

Muscular inhibitory and excitatory phenomena during spike-and-wave discharges: effect of posture

Sir: In 1886 Hughlings Jackson observed that an epileptic patient suffering from falling fits due to loss of tone during standing could also show sudden jerks of

the limbs while lying supine (cited in Janz 1969¹). Gastaut *et al* noticed that spike-and-wave discharges can cause both myoclonic jerks and atonic drops.² In an epileptic child we observed spike-and-wave discharges that had different clinical manifestations depending upon posture. Myoclonic jerks were present when the patient was at rest, whereas atonic fits without myoclonus were evident during maintenance of posture.

A nine-year-old boy born post-term by caesarean section, had a first tonic seizure at 11 months and three more similar attacks during the following months. He then remained seizure-free until aged two and a half years, when absences appeared several times a day. They lasted a few seconds and were often associated with myoclonic jerks of the head and arms. No falling fits were reported. Neurological examination and IQ were normal. A polygraphic recording was carried out which included electroencephalogram, electrooculogram, electromyogram of neck, chin and deltoid muscles, electrocardiogram and thoracic respirogram. The patient's clinical manifestations were monitored simultaneously with the polygraphic recording by means of an audio-visual videotape system. The EEG showed a normal background activity with generalised 3.5 Hz spike-and-wave discharges, each one lasting 2 to 5 s. Some discharges did not induce any clinical phenomena, whereas others had a clinical manifestation which depended upon the posture of the patient: (a) when the patient was at rest, sitting with his arms along his body, the spike-and-wave discharge was associated with myoclonic jerks of the head and upper limbs, which sometimes spread to the lower limbs as well. These jerks observed in the neck and deltoid muscles were synchronous with the spike of the spike-and-wave complexes (fig a). (b) When the patient held the arms outstretched, the spike-and-wave discharge was associated instead with a sudden drop of his head and arms. The drop was due to a loss of tone, recorded in the neck and deltoid muscles and synchronous with the wave of the spike-and-wave complex. It usually lasted 100 to 200 ms, the next spike marking then the re-appearance of the tonic muscular activity (fig b), with myoclonus now being absent.

This case demonstrates that, on the same pool of motoneurons, an excitatory influence related to the spike may prevail during muscular rest, whereas an inhibitory influence related to the wave

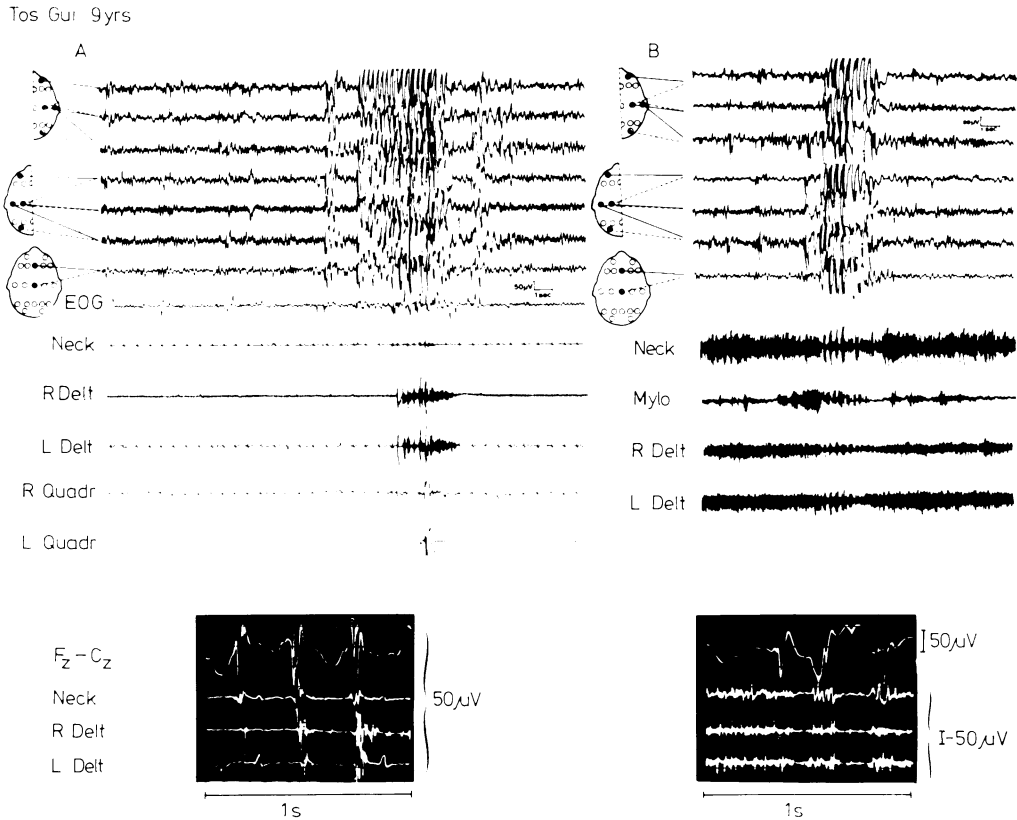


Figure Polygraphic (top) and oscilloscopic (bottom) recordings of: (A) seizure during rest: myoclonic jerks. The oscilloscopic recording shows the simultaneous occurrence of spike and myoclonic jerks. (B) seizure during posture with out-stretched arms: drop of the head and arms. The oscilloscopic recording shows the coincidence of loss of tone with the slow component of the spike-and-wave complex; the spike is synchronous with the reappearance of muscle tone.

prevails during the maintenance of posture. Therefore, posture can affect the clinical manifestation of absences not only by a simple "gravitatory" effect, but also by modifying the response of the spinal motoneurons to the spike-and-wave discharges.

² Gastaut H, Tassinari CA, Bureau Paillas M. Etude polygraphique et clinique des "effondrements atoniques épileptiques". *Rev Neurol* 1966;36:5-21.

showed muscular atrophy, and weakness of the right arm with marked fasciculation, mild atrophy and fasciculation of the tongue, hyperreflexia especially on the right side, but no sensory abnormality. Amyotrophic lateral sclerosis was the diagnosis. Two years later the patient was admitted to hospital with a weight of 30 kg and a total lack of motor power as well as involvement of the 7th to the 12th cranial nerves. A month later the patient died and necropsy demonstrated extensive and diffuse muscle atrophy and moderate atrophy of the spinal cord (especially in the mid-thoracic region) and of the anterior spinal nerve roots. Histological changes consisted in loss of the large motor cells in the anterior and lateral column with secondary diffuse gliosis in the thoracic spinal cord as well as in the

FABIO CIRIGNOTTA
PASQUALE MONTAGNA
ELIO LUGARESI
Clinica Neurologica-Università di Bologna
Via Foscolo 7-40123
Bologna, Italy

Angiofibrosis of the brainstem in a woman with motor neuron disease

Sir,—Vascular tumours and malformations of the brainstem are rare and only some of them produce neurological symptoms.¹⁻³ We found an atypical vascular lesion in the right of the medulla oblongata, pons and mesencephalon in a patient with amyotrophic lateral sclerosis. She was a 72-year-old woman with progressive weakness in the right arm and leg and difficulty of speech. Examination

References

¹ Janz D. *Die Epilepsien Spezielle Pathologie und Therapie*. Stuttgart: Georg Thieme Verlag, 1969.