

'Sneeze syncope,' basilar invagination and Arnold-Chiari type I malformation

J. J. CORBETT, A. B. BUTLER, AND B. KAUFMAN

From the Departments of Neurology and Neurosurgery, Naval Hospital, Portsmouth, Virginia, and Department of Radiology, University Hospitals of Cleveland, Case-Western Reserve University, Cleveland, Ohio, USA

SYNOPSIS Syncope precipitated by sneezing in an adult male associated with an Arnold-Chiari type I malformation and basilar invagination presents a clinical problem in the differential diagnosis and pathological anatomy of Valsalva-related syncope. An abnormally acute clivoaxial angle, small foramen magnum, and type I Arnold-Chiari malformation appear to be a combination of features intolerant of Valsalva-induced changes in cerebral volume, brain-stem position, CSF fluid dynamics, or blood vessel relationships. Proposed mechanisms of pressure transmission to the area of intracranial pathology are discussed.

Sneezing, or any other brief Valsalva manoeuvre may, in rare instances, result in syncope (Engel, 1962). 'Sneeze syncope' was the presenting symptom of an adult male who had both basilar invagination and type I Arnold-Chiari malformation. The relationship between these craniovertebral structural anomalies and the physiological events of the Valsalva manoeuvre is the subject of this report.

¹ Reprint requests: Dr Albert B. Butler, Department of Neurological Surgery, University of Virginia, Charlottesville, Virginia 22901, U.S.A. (Accepted 4 December 1975.)

CASE REPORT

A 29 year old man (PNH221862) was seen in consultation at the Naval Hospital, Portsmouth, Virginia, with the chief complaint of dizziness associated with sneezes, which had been occurring for the preceding 15 years. Each episode was essentially identical, beginning with a sneeze (although not all sneezes produced the dizziness) and followed immediately by a 'crick' sensation in the back of the neck (the patient could not characterize this sensation more specifically). Severe vertigo then occurred lasting 45 to 60 seconds, followed by nausea which would persist for up to 15 minutes. Nausea,

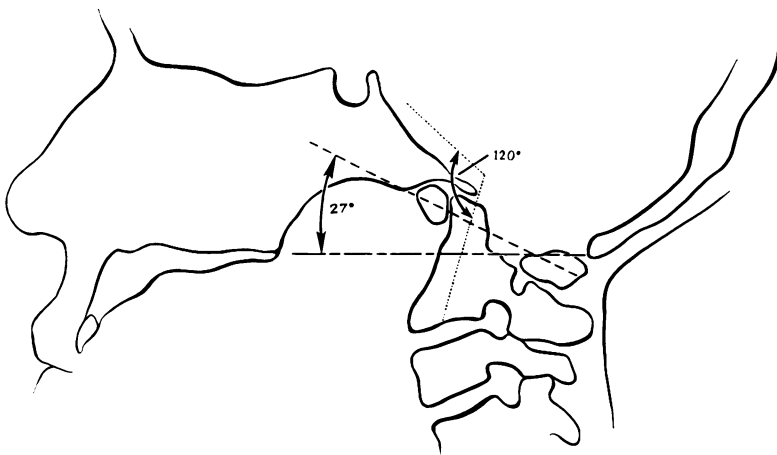


FIG 1 Line drawing of the skull and upper cervical spine showing the clivoaxial angle (the angle formed by the plane of the clivus and the axis of the odontoid) to be 120 degrees. Basilar invagination is present with Bull's angle being 27 degrees and Chamberlain's line passes through the body of C2 vertebra.

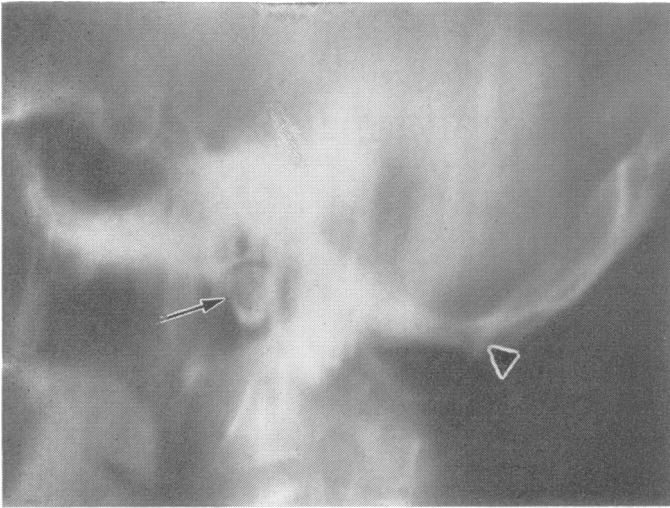


FIG. 2 Lateral laminagram of the skull and cervical spine shows the unfused anterior neural arch (right side) of C1 beneath the basioccipital bone (arrow). The posterior edge of the foramen magnum (opisthion) is indicated by the arrowhead (▶).

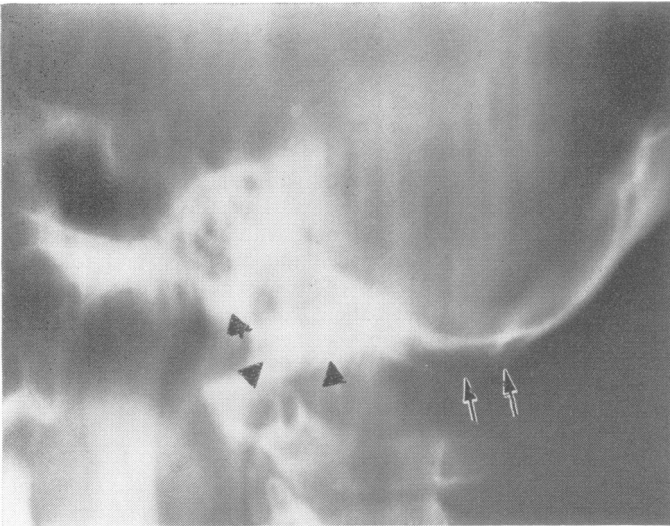


FIG. 3 Lateral laminagram shows the classical appearance of 'occipitalization' of the left side of the posterior neural arch of C1 vertebra (arrows). The anterior neural arch of C1 vertebra, occipital condyle, and lateral mass of C1 vertebra present as a non-segmented mass (▶).

present for only the last three years, was a relatively new feature of the symptom complex. In addition to sneezing, more recently the patient noted that straining during bowel movements and isometric exercises could produce an identical sequence of events. The symptoms were sequentially invariable but the complex occurred unpredictably, in a ratio of about one sneeze (or other Valsalva manoeuvre) in three. Two weeks before his hospitalization while shaving one morning, he sneezed and suffered a typical attack which progressed rapidly from the 'sneeze-and-vertigo phase' to an abrupt, brief loss of con-

sciousness of three to four seconds. For 15 minutes after this episode, any attempt at walking was attended by a tendency to drift to the right 'as though drunk'. Headache, diplopia, dysphagia, hoarseness, weakness of arms or legs were not present then or later. A history was elicited of occasional brief 'electric shock sensations' radiating into both arms on flexion of his head consistent with Lhermitte's phenomenon.

Physical examination revealed a short (170.1 cm), stocky (79.5 kg) man with a thick, short neck. No abnormalities of any of the cranial nerves, strength,

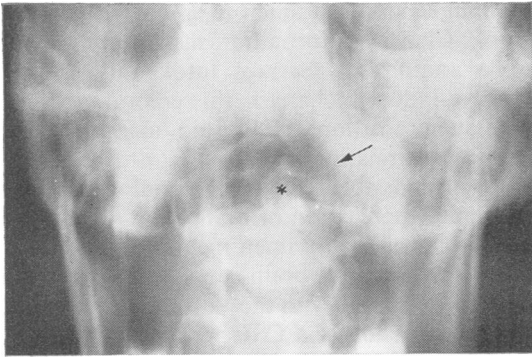


FIG. 4 The AP laminogram of the craniocervical junction documents the segmentation error, 'occipitalization', of C1 vertebra on the left side (arrow). The odontoid process is seen in the centre (*).

tone or reflexes, cerebellar or sensory function were found on repeated examinations.

Radiographic examination of the skull and cervical spine revealed partial occipitalization of C1 vertebra, a clivoaxial angle of 120 degrees, and basilar invagination (impression) (Fig. 1). Laminography showed the unfused neural arch of C1 vertebra on the right to be closely applied under the basioccipital bone anteriorly (Fig. 2). On the left side, the lateral mass and neural arch had not segmented from the occipital bone, giving the classical appearance of 'occipitalization of C1' (Figs 3 and 4). A pneumoencephalogram showed only slight filling of the lateral ventricles. A complete evaluation of the posterior fossa was not accomplished. Arteriography was not performed because of a prior anaphylactic reaction to iodized contrast material.

At operation an Arnold-Chiari type I malformation with herniation of the cerebellar tonsils to the level of C3 vertebra was found. A suboccipital craniectomy and decompressive laminectomy of the first and second cervical vertebrae was performed with alleviation of all symptoms.

DISCUSSION

This patient presents a clinical problem in the differential diagnosis of Valsalva-related syncope (Engel, 1962). The Valsalva manoeuvre, a forcible expiration of air against closed glottis, has different effects on cerebrospinal fluid, venous, and arterial pressures. Sudden increase in intrathoracic and intra-abdominal pressure with the Valsalva manoeuvre causes an instantaneous

increase in cerebrospinal fluid pressure equal to the intrathoracic pressure. This increased pressure is due to engorgement of valveless veins in the epidural Batson's plexus and invagination of spinal sleeves into the intervertebral foramina (Hamilton *et al.*, 1944; Martins *et al.*, 1972). Jugular venous pressure increases more slowly and never quite equals intrathoracic or CSF pressure (Hamilton *et al.*, 1944). The sequence of events in the arterial system consists of a brief increase in systolic blood pressure beginning immediately at the onset of increased airway pressure. Mean blood pressure then drops rapidly to very low levels and rises slowly with a narrow pulse pressure until the glottis opens. Once the manoeuvre ends, the pulse pressure suddenly increases and a mild bradycardia ensues (Gorlin *et al.*, 1957).

True Valsalva-related 'sneeze syncope' is rare and is said to require several sneezes in rapid sequence (Engel, 1962). The multiple rapid drops in arterial pressure associated with decreased blood return to the right ventricle, decreased effective cardiac filling pressure, as well as a drop in stroke volume output and mean arterial pressure produce temporary cerebral ischaemia and at times loss of consciousness. This is truly a cardiovascular event. In contrast, our patient never needed to sneeze in rapid succession to produce the symptom complex. In addition, he was able to produce identical symptoms with other rather modest Valsalva manoeuvres. It then appears that some other mechanism may be related to his loss of consciousness.

Williams (1972) has measured the CSF pressure in both spinal canal and ventricles of patients with Arnold-Chiari malformation. He found a definite time differential between the pressure increase in the lumbar sac and the pressure increase in the ventricles during Valsalva manoeuvres. The CSF pressure wave in the lumbar theca is generated by increased intrathoracic and intra-abdominal pressure. This is reflected instantaneously in dilatation of the valveless Batson's plexus. The increase in venous pressure around the lumbar theca is then reflected in the raised cerebrospinal (CSF) pressure. The resulting pulse pressure generated propagates upward in a wave through the foramen magnum and increases pressure in the posterior fossa. The pressure is then distributed

within the intracranial compartment. In the patient with Arnold-Chiari malformation, this pressure increase presumably results in further herniation of the cerebellar tonsils (Williams, 1972). This phenomenon has been observed during surgery on patients with Arnold-Chiari malformation when cough has produced further herniation of the cerebellar tonsils (Mullan and Raimondi, 1962). Williams's hypothesis, although appealing, was not verified in studies performed by Martins *et al.* (1972). Patients undergoing myelography were asked to perform a Valsalva manoeuvre when the dye column was at the craniocervical junction and the dye failed to move into the intracranial vault.

Larson *et al.* (1974) have reported two patients with cough syncope and herniated cerebellar tonsils who were studied with CSF pressure recordings. The authors concluded from limited studies of CSF lumbar pressures that cerebellar herniation was secondary to expansion of cerebral blood volume during cough. Evoked somatosensory potentials were performed before and after coughing. Amplitude suppression during cough and recovery of amplitude after return of CSF pressure to normal suggests that compression of the medulla by herniated tonsils may also contribute to syncope.

The possibility of a strictly mechanical anatomical explanation should also be considered. It has been reported that flexion of the neck in patients with Arnold-Chiari malformation at the time of surgery may result in respiratory arrest (List, 1941; Mullan and Raimondi, 1962). Perhaps other cardiovascular events resulting in syncope could be produced as the result of percussion of the ventral medulla on the clivus or temporary vascular occlusion causing brain-stem ischaemia. An abnormally acute clivo-

axial angle, small foramen magnum, and type I Arnold-Chiari malformation in concert appear to be anatomical features intolerant of brief Valsalva-induced changes in cerebral volume, brain-stem position, CSF fluid mechanics, or blood vessel relationships.

It is not possible to say with certainty whether mechanical percussion of brain-stem against the anterior lip of the foramen magnum, temporary occlusion of ventral brain-stem vessels, increase in cerebral volume with the Valsalva manoeuvre, or the succussion of a CSF pressure wave into a small posterior fossa was responsible for our patient's symptoms. Any or all of these mechanisms may have been operative.

The opinions expressed are those of the authors and not necessarily those of the Department of the Navy.

REFERENCES

- Engel, G. L. (1962) *Fainting*. Thomas: Springfield, Ill.
- Gorlin, R., Knowles, J. H., and Storey, C. F. (1957). The Valsalva maneuver as a test of cardiac function. *American Journal of Medicine*, **22**, 197-212.
- Hamilton, W. F., Woodbury, R. A., and Harper, H. T. (1944). Arterial, cerebrospinal and venous pressures in man during cough and strain. *American Journal of Physiology*, **141**, 42-50.
- Larson, S. J., Sances, A., Baker, J. B., and Reigel, D. H. (1974). Herniated cerebellar tonsils and cough syncope. *Journal of Neurosurgery*, **40**, 524-528.
- List, C. F. (1941). Neurologic syndromes accompanying developmental anomalies of occipital bone, atlas and axis. *Archives of Neurology and Psychiatry*, **45**, 577-616.
- Martins, A. N., Wiley, J. K., and Myers, P. W. (1972). Dynamics of the cerebrospinal fluid and the spinal dura mater. *Journal of Neurology, Neurosurgery, and Psychiatry*, **35**, 468-474.
- Mullan, S., and Raimondi, A. J. (1962). Respiratory hazards of the surgical treatment of the Arnold-Chiari malformations. *Journal of Neurosurgery*, **27**, 675-678.
- Williams, B. (1972). The valvular action of the Arnold-Chiari malformation. In *Intracranial Pressure*, pp. 338-442. Edited by M. Brock and H. Dietz. Springer: Berlin.