

Prolonged conduction block with axonal degeneration

An electrophysiological study

W. TROJABORG¹

From the Laboratory of Clinical Neurophysiology, Rigshospitalet, University Hospital, Copenhagen, Denmark

SUMMARY Serial electrophysiological studies were performed in a case of 'tourniquet paralysis' of the upper limb after the application of an Esmarch bandage above the elbow. Three months after onset of paralysis, nerve conduction was reduced to a quarter of normal between elbow and axilla along the few fibres still conducting through the lesion, but was normal distal to the block. Seven months after nerve damage, EMG showed evidence of reinnervation after Wallerian degeneration, and half the nerve fibres had recovered from the conduction block. Thirteen months after nerve injury clinical examination and nerve conduction were normal, but EMG still showed evidence of partial denervation.

The characteristic clinical dissociation between motor and sensory symptoms which may follow the application of a tourniquet is well known (Eckhoff, 1931; Moldaver, 1954). Information about the electrophysiological aspects of the syndrome in man is limited and mainly restricted to the motor function. In a recent study, serial conduction tests were applied to proximal and distal motor nerve segments in a patient with paralysis of about three months' duration after the use of a pneumatic tourniquet (Rudge, 1974). However, sensory nerve conduction was investigated only distal to the damaged segment of the nerve.

This paper describes serial conduction studies in proximal and distal motor and sensory nerve segments in a case of tourniquet paralysis with prolonged conduction block. In addition, on the basis of electromyographic criteria, the presence of axonal degeneration is suggested. Furthermore, recovery of transected digital median nerve fibres was followed longitudinally.

Case report

A man aged 40 years sustained wounds on the volar aspect of his left hand. On admission to a local hospital he was found to have impaired flexion of the index and middle fingers due to division of the flexor

tendons at the level of the finger base. No other abnormalities were encountered. The flexor tendons were sutured, and the forearm, hand and fingers were put in plaster of paris, leaving only the distal phalanx of the thumb free. When he recovered from the general anaesthetic, he observed that the thumb was numb, and he was unable to move the distal joint. The plaster was removed six days after the operation because of oedema, and the patient was unable to move any part of the left arm below the elbow. All sensory modalities were impaired in descending order of severity: touch, pressure, vibration, and position sense more than pain. There was no paraesthesia or tingling. Three months after the onset of palsy, the forearm muscles were severely wasted and the hand was oedematous with a dystrophic appearance (Fig. 1). All muscles distal to the elbow were paralysed except the abductor pollicis brevis (Table 1).

On request the hospital provided the information that an Esmarch bandage had been used during the operation, but the duration of application was not given. According to the patient, the operation lasted about two hours.

Methods

The patient was examined three, seven, and 13 months after the onset of paralysis.

ELECTROMYOGRAPHY

The criteria used were (1) the pattern of activity at full effort, (2) the amplitude of its envelope curve, (3) the

¹ Address for correspondence: Blegdamsvej 9, DK 2100 Copenhagen Ø, Denmark.

Accepted 15 September 1976

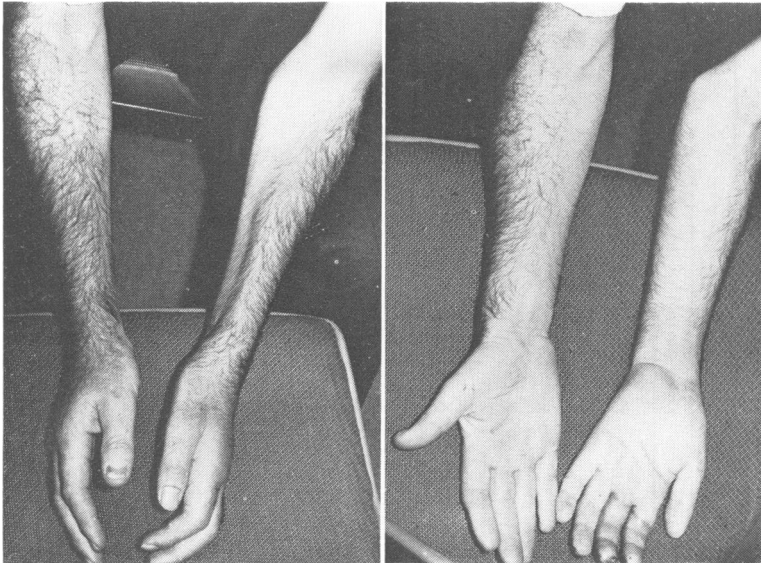

Fig. 1 The forearms and hands of the patient three months after nerve injury.

Table 1 Muscle testing*

Muscle	Months after onset of palsy		
	3	7	13
Brachioradialis	0	4	5
Extensor digitorum communis	0	3	5
Flexor digitorum sublimis	0	2	5
Flexor digitorum profundus	0	2	5
Abductor pollicis brevis	0-1	2-3	5
Abductor digiti quinti	0	3	5

* Graded according to Medical Research Council (1943).

number of sites at which fibrillation potentials and positive sharp waves were recorded outside the endplate zone, (4) the mean potential duration and amplitude of at least 20 randomly sampled motor unit potentials, and (5) the incidence of polyphasic potentials. Findings were evaluated by comparison with normal muscles matched for age (Buchthal, 1957; Rosenfalck and Rosenfalck, 1975).

CONDUCTION STUDIES

Motor and sensory conduction in the median and radial nerves was determined according to methods previously described (Buchthal and Rosenfalck, 1966; Trojaborg and Sindrup, 1969). In short, the median and radial nerves were stimulated by needle electrodes placed at the wrist, elbow, and axilla. Muscle responses were evoked in the abductor pollicis brevis, flexor digitorum sublimis, extensor digitorum communis, brachioradialis, and brachial triceps muscles by supramaximal stimulation. Sensory fibres of the median nerve were stimulated by surface electrodes

placed around digits I and III, and sensory fibres of the radial nerve were stimulated by needle electrodes placed at the wrist. Sensory potentials were recorded over the median and radial nerves at wrist, elbow, and axilla.

Findings were evaluated by comparison with normal values matched for age (Rosenfalck and Rosenfalck, 1975).

Results

ELECTROMYOGRAPHY

The electromyographic findings are presented in Table 2. In all muscles tested there was discrete activity of reduced amplitude (<0.8 mV) on volitional innervation three months after the onset of palsy. There were fibrillation potentials and positive sharp waves at every insertion, and too few motor unit potentials could be voluntarily evoked to determine a mean duration and amplitude. The few present were of normal shape, duration, and amplitude.

Seven months after the onset of paralysis, muscle force had improved although in most muscles the force was graded as 3 or less (Table 1). Similarly, on electromyography there was more activity during full effort and the pattern had attained a normal amplitude. There was no spontaneous activity. The mean potential duration and amplitude was considerably increased in the brachioradialis, extensor digitorum communis, and abductor pollicis brevis muscles as was the incidence of polyphasic potentials (Table 2, Fig. 2).

About a year after the onset of nerve damage, the

Table 2 *Electromyographic findings*

	<i>Muscle investigated</i>														
	<i>Ext. dig. com.</i>			<i>Abd. poll. br.</i>			<i>Brachioradialis</i>			<i>Flexor dig. subl.</i>			<i>Abd. dig. V.</i>		
	3	7	13	3	7	13	3	7	3	7	13	3	7	3	7
Months after onset	DA	DA-RR	RR	DA	DA-RR	RR	DA	DA-RR	DA-RR	RR	RR	DA	RR	DA	RR
Pattern at full effort*	0.05	3	3	0.6	3	3	0.8	3	3	3	3	0.4	2	0.7	6
Amplitude at full effort (mV)	+++++	0	+	+++++	+	+	+++++	0	+++++	+	+	+++++	0	+++++	0
Denervation potential†	X	99	51	X	46	19	X	38	X	38	19	X	—	X	—
Mean potential duration (% increase)	X	74	36	X	32	11	X	40	X	40	11	X	—	X	—
Incidence of polyphasic potentials (%)	X	670	760	X	1100	675	X	370	X	370	675	X	—	X	—
Mean amplitude of motor unit potentials (μV)	X	27	33	X	20	20	X	20	X	20	20	X	—	X	—
Number of potentials															

* DA = discrete activity, RR = reduced recruitment.

† Fibrillation potentials and positive sharp waves, + + + + + = in five or more places, + = in one place of the muscle, 0 = absent. X = 100 few potentials for statistical evaluation, — = not determined.

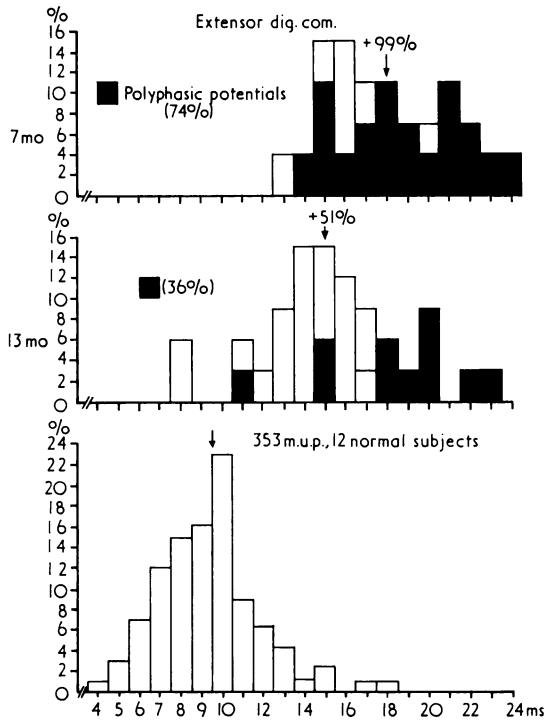


Fig. 2 Histograms of action potential duration in the extensor digitorum communis seven and 13 months after onset of palsy. Bottom, from 12 normal subjects aged 33–47 years. The arrow above each diagram denotes mean duration.

patient had made a complete recovery. There was no muscle wasting and all previously affected muscles had force 5 (Table 1). Electromyography was performed in the extensor digitorum communis and abductor pollicis brevis muscles only. In spite of normal force there was a reduced recruitment pattern

in both muscles. The mean motor unit potential duration was only moderately increased, and the incidence of polyphasic potentials had decreased again (Table 2, Fig. 2).

MOTOR CONDUCTION

Three months after nerve injury, muscle responses evoked by stimulating the median nerve at the elbow and wrist were normal in spite of severe muscle weakness and wasting. However, when stimulating proximal to the elbow the amplitudes of the potentials in the abductor pollicis brevis and flexor digitorum sublimis muscles were only 2–3% of those evoked by stimulation distal to the elbow. Similarly, the responses from the brachioradial and extensor digitorum communis muscles, evoked by stimulating the radial nerve in the axilla, were one-eighth of those evoked by stimulating at the elbow. In contrast, the response evoked in the brachial triceps was of normal amplitude and latency. Moreover, the conduction velocity in the median nerve from axilla to elbow was a quarter of that from elbow to wrist. In the radial nerve a motor velocity could not be calculated as the responses evoked by stimulation proximal and distal to the elbow were not identical (Table 3, figures in brackets).

Seven months after onset of palsy, the degree of recovery of conduction was 25% for fibres to the abductor pollicis brevis, as estimated from the amplitude of the response to stimulation proximal to the block, compared with that evoked by stimulation distal to it.

About half of the fibres to the flexor digitorum sublimis and extensor digitorum communis had recovered. The conduction velocity in motor fibres across the block was 64% of the normal value (Table 3).

Thirteen months after the onset of palsy, there was no difference in amplitude of muscle responses

Table 3 Motor and sensory conduction velocity in the median and radial nerves and amplitude of evoked motor and sensory potentials

		Months after onset of palsy											
		Median nerve						Radial nerve					
		3		7		13		3		7		13	
		S	M*	S	M*	S	M*	S	M†	S	M†	S	M†
Conduction velocity (m/s)	Digit I–wrist	54		53		53							
	wrist–elbow	65	58	61	57	64	60	63		61		61	
	elbow–axilla	32	21	47	40	54	62	36	(29)	53	43	63	64
Amplitude of responses recorded (S, μ V) or evoked (M, mV) at	wrist	20	6	22	6	25	9						
	elbow	6	4	11	4	11	8	39	8	33	12	51	10
	axilla	0.5	0.1	1.5	1	3	7	0.7	1	4.6	6	18	9

S=sensory, M=motor, * with abductor pollicis brevis as indicator † with extensor digitorum communis as indicator.

evoked by stimulation proximal and distal to the elbow, neither in the abductor pollicis brevis nor in the extensor digitorum brevis muscles, and motor conduction velocities were normal throughout.

SENSORY CONDUCTION

Three months after nerve injury, sensory conduction velocities in the median and radial nerves were normal distal to the elbow, and the amplitude of sensory action potentials was within the normal range. However, the potentials recorded at the axilla were markedly reduced in amplitude and delayed. The conduction velocity in the segment from elbow to axilla was half of that in the segment from wrist to elbow (Fig. 3, Table 3).

Four months later, the conduction velocity between elbow and axilla in the radial and median nerves was slightly slower than the velocity between wrist and elbow (8 and 14 m/s respectively). The amplitude of the sensory potentials recorded over the median and radial nerves at the axilla had increased three and six times respectively.

Thirteen months after the onset of palsy, the conduction velocity in the radial nerve was the same in the segments above and below the elbow; in the median nerve the velocity above the elbow was 10 m/s slower than the velocity below. However, the amplitude of sensory potentials was within the normal range (Fig. 4, Table 3).

DIGITAL NERVE FIBRES

When the patient was first seen three months after the onset of paralysis, there was anaesthesia and analgesia corresponding to the index and middle fingers. When stimulating digit III with surface electrodes, a severely desynchronised and prolonged potential of reduced amplitude (about $0.3 \mu\text{V}$) was recorded over the median nerve at the wrist. The fastest fibres conducted at 18 m/s and the slowest component at 2 m/s (Fig. 5). At subsequent examinations seven and 13 months after nerve injury, the velocity of the fastest conducting fibres increased to 37 and 43 m/s respectively, the slowest components conducted at 5 and 9 m/s respectively.

Discussion

In the patient presented here, as in other reported cases (Eckhoff, 1931; Bruner, 1951; Moldaver, 1954; Rudge, 1974), the application of a tourniquet resulted in damage to the median, radial, and ulnar nerves. Rudge's (1974) and my patient showed a considerable delay in recovery in contrast to previous reported cases. Three months after nerve damage they both still had paralysis of all muscles distal to the elbow. Although there was severe muscle weak-

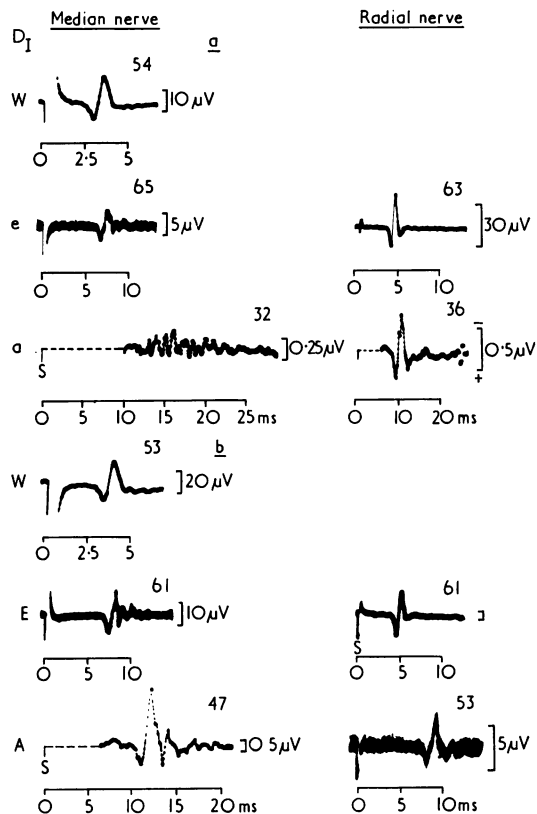


Fig. 3 Sensory action potentials over the median and radial nerves recorded at wrist (w), elbow (e), and axilla (a) evoked by stimulating sensory fibres at Digit I (median nerve) and wrist (radial nerve) (a) three and (b) seven months after onset of palsy. The figures above each trace indicate the conduction velocity in the segment distal to the recording site. The potentials at the elbow are recorded by photographic superimposition of 15–20 responses, as is the potential recorded over the radial nerve at the axilla (lowermost trace to right). The potentials at the axilla are recorded by electronic averaging of 500–1000 stimuli.

ness and wasting, and profuse fibrillation indicating degeneration of nerve fibres, muscle and nerve potentials evoked by stimulation distal to the site of compression were of normal amplitude and shape. These findings are compatible with a conduction block as the cause of paralysis (Denny-Brown and Brenner, 1944; Trojaborg, 1970; Fowler *et al.*, 1972); a type of pressure palsy that was originally attributed to restricted demyelination caused by local nerve ischaemia with or without axonal interference.

The number of cases of tourniquet paralysis has decreased since the introduction of the pneumatic cuff. This by itself led Moldaver (1954) to suggest that ischaemia is probably not the cause of paralysis but

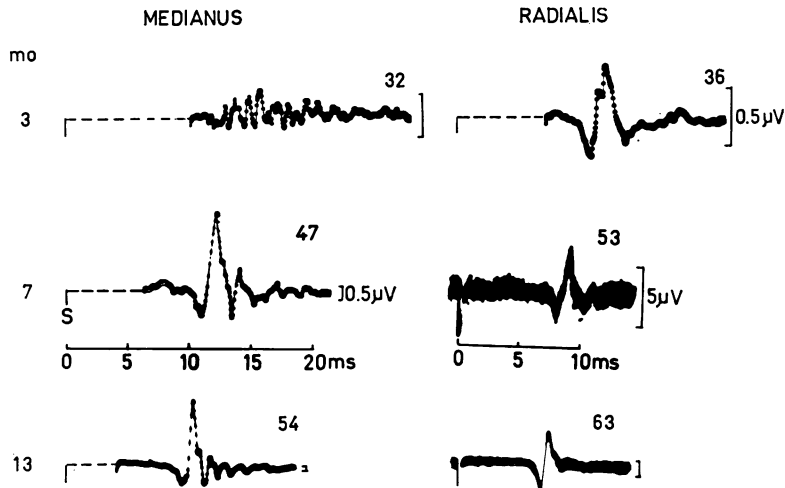


Fig. 4 Sensory action potentials recorded at the axilla over the median and radial nerves, three, seven, and 13 months after onset of tourniquet paralysis. The figures above each trace indicate the conduction velocity from elbow to axilla. Sensory median nerve fibres were stimulated by surface electrodes placed around the thumb, sensory radial nerve fibres were stimulated by needle electrodes placed at the wrist. The potentials in upper line three months after injury are recorded by electronic averaging of 500–1000 stimuli. The two lower right traces are recorded by photographic superimposition of 15 traces.

that the mechanical pressure plays a greater role, if not the only one, in the aetiology. The findings of Fowler *et al.* (1972) and of Ochoa *et al.* (1972) confirmed Moldaver's suggestion. Application of a pneumatic cuff inflated to 1000 mmHg round the knee for one to three hours produced a nerve conduction block of several weeks or months duration in the baboon. In teased nerve fibre preparations, they found a displacement of the node of Ranvier confined to the large myelinated fibres and accompanied by stretching of paranodal myelin on one side of the node, and invagination of the myelin sheath on the other. Moreover, it appeared that damaged nerve fibres developed intramyelin and periaxonal oedema which resulted in localised swelling of the myelin. It was suggested that the persistence of these swellings was responsible for the delayed recovery of conduction rather than a defect in remyelination.

If muscle weakness or paralysis is a consequence of a conduction block due mainly to demyelination, peripheral sprouting does not occur to an extent that can be detected by available electrophysiological methods. In short-lasting cases of conduction block, such as the Saturday-night palsy, there was no change in motor unit potential duration, amplitude, or shape at the time when recovery was completed six to eight weeks after onset (Trojaborg, 1970). When recovery is prolonged, as in the present case, the conduction block is likely to be a combination of demyelination

and Wallerian degeneration (Denny-Brown and Brenner, 1944; Fowler *et al.*, 1972; Ochoa *et al.*, 1972). Consequently, there are changes in motor unit parameters during recovery compatible with the occurrence of peripheral sprouting.

In the case reported by Rudge (1974), as in my patient, there was pronounced wasting of paralysed muscles. Atrophy as such need not necessarily indicate denervation. It could also be a consequence of disuse due to a longstanding conduction block, although this is less likely in view of the findings recently reported by Harrison (1976) in a case of pressure palsy of the ulnar nerve with prolonged conduction block. In my patient, the findings of a decreased number of motor units, even at a time when recovery was completed clinically, an increased mean action potential duration and amplitude, as well as an increased number of polyphasic potentials, indicate reinnervation after axonal damage. These findings were present seven months after the tourniquet injury. In the extensor digitorum communis muscle, the changes may in part be explained by regrowth of fibres from the site proximal to the lesion. The high incidence of polyphasic potentials in this muscle (74%) would favour such an assumption. This is a common finding in muscles recovering from denervation where there might be competition between reinnervation due to peripheral sprouting and regrowth of nerve fibres from a site proximal to the

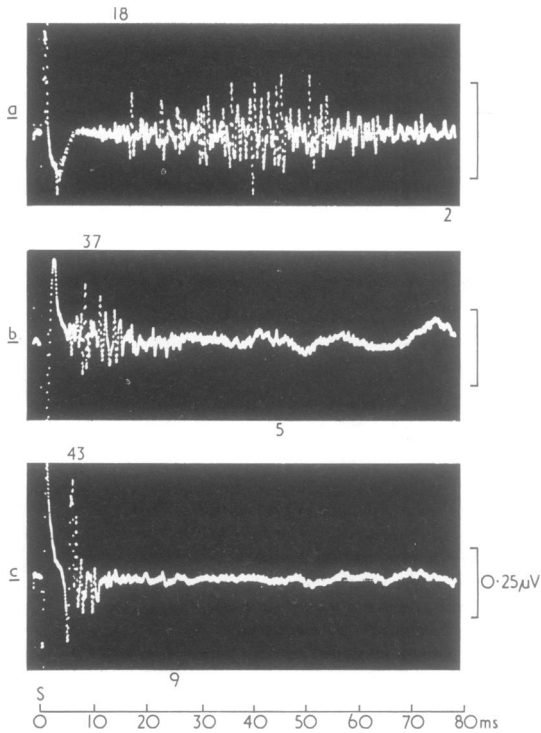


Fig. 5 Sensory potentials recorded over the median nerve at wrist by stimulating the middle finger, three, seven, and 13 months after transection of digital nerve fibres at base of the middle finger. The potentials were recorded by electronic averaging of 4000 (a) and 2000 stimuli (b and c). Slower components were identified as they increased proportional with the calibration signal. The figure above the trace denotes the maximal conduction velocity (m/s) in the segment of nerve distal to the point of recording; the figure below the trace gives the minimal conduction velocity (m/s) from the stimulating surface electrode on digit III (S).

lesion (Trojaborg, 1976a). On the other hand, in partially denervated muscles, where reinnervation can be attributed to peripheral sprouting only, recovery is rarely accompanied by a rise in the incidence of polyphasic potentials to more than about 30%, as occurred in the abductor pollicis brevis seven months after nerve injury (Table 2).

When both demyelination and Wallerian degeneration are part of the conduction block, the question arises whether peripheral sprouts originate from blocked or unblocked surviving fibres. There is some clue as to this question although it can not be answered with certainty. In my patient, most of the fibres to forearm and hand muscles were still blocked three months after the onset of nerve damage and there was

no evidence of peripheral sprouting, although electrophysiological signs of sprouting can be expected as early as three weeks after onset of partial denervation (Olsen, 1975; Trojaborg, 1976a). Thus, the blocked fibres seemed unable to generate sprouts. Four months later, when a quarter of nerve fibres had recovered, there was electrophysiological evidence suggesting peripheral sprouting. The increase in motor unit potential duration can be attributed to an increase in size of the motor unit due to incorporation of denervated muscle fibres. As recovery progressed, the temporal dispersion of the individual components of the motor unit potential became less pronounced and the mean potential duration decreased, whereas the mean amplitude remained increased (Table 2).

Similarly, at the onset of recovery, there was an increased amount of polyphasic potentials as a consequence of an increase in temporal dispersion compatible with slow impulse transmission along nerve sprouts and a greater dispersion of the endplate zone. With advancing maturation of nerve fibres, the temporal dispersion of the individual components of the motor unit potential diminishes, and the amount of polyphasic potentials decreases.

Thus, the changes in the motor unit parameters in my patient during recovery are compatible with axonal damage, in addition to the conduction block caused by the tourniquet. The presence of axonal damage was not obvious from the conduction studies. The amplitudes of evoked potentials, whether motor or sensory, are insensitive indicators of axonal loss due to the great variation in normal subjects. The amplitude of motor unit potentials recorded by concentric needle electrodes, whether evoked voluntarily or by nerve stimulation, deviates about 40% from the mean (Buchthal and Rosenfalck, 1963; Trojaborg, 1964), and evoked sensory action potentials showed a similar variation between individuals (Buchthal and Rosenfalck, 1966) as well as within the same individual (Trojaborg, 1970). Therefore only large differences in average voltage can be considered significant. When the conduction velocity in motor and sensory fibres is normal, the average amplitude must deviate by more than 40% from normal to be statistically significant. Thus, a substantial number of axons may be lost and amplitude of evoked responses still be within the normal range.

It is interesting that when the patient was first seen three months after nerve injury, sensory deficit was negligible compared to the severe motor involvement (except for the anaesthesia and analgesia corresponding to the index and middle fingers due to local damage of digital nerve fibres). The relative sparing of sensation which is a common feature of acute nerve compression in man is most probably explained by the fact that the nodes on the small myelinated fibres are

normal whereas the nodes on the large myelinated fibres are affected (Gilliat, 1975).

It is likely that the digital nerve fibres of my patient's index and middle fingers were transected at the same time as the flexor tendons of these two fingers. The velocity along the fastest conducting fibres from digit III to wrist (18 m/s) three months after nerve injury is compatible with conduction along regenerating nerve fibres as is the rate of conduction of the slowest components (2 m/s, Buchthal *et al.*, 1975; Trojaborg, 1976b). The rate of recovery is also consistent with the time interval, considering the 8–9 cm length of the fingers from the site of transection. The amplitude of the sensory response was a quarter of a microvolt, indicating regrowth of only a few fibres from proximal to the site of injury. The amplitude of the response did not increase over the following four months, although the velocity of the fastest conducting fibres increased from 18 to 37 m/s. One year after the transection of digital nerve fibres, the conduction velocity was 80% of normal and the amplitude of the sensory potential was only half a microvolt. The increase in amplitude can be accounted for by the decrease in temporal dispersion. From the relation of conduction velocity, amplitude of sensory potentials, and number of fibres in the sural nerve, Buchthal *et al.* (1975) suggested that a sensory potential of 0.1 μ V conducted at a normal rate originates from five to 10 fibres of 10 μ m or more in diameter. Thus, in the patient presented here, it is likely that no more than about 50 digital median nerve fibres had recovered one year after the transection—that is, about one-tenth of the total number of digital median nerve fibres (Buchthal and Rosenfalck, 1966).

References

- Bruner, J. M. (1951). Safety factors in use of pneumatic tourniquet for hemostasis in surgery of the hand. *Journal of Bone and Joint Surgery*, **33-A**, 221–224.
- Buchthal, F. (1957). *An Introduction of Electromyography*, pp. 43. Gyldendal: Copenhagen.
- Buchthal, F., and Rosenfalck, P. (1963). Electromyographical aspects of myopathy with particular reference to progressive muscular dystrophy. In *Muscular Dystrophy in Man and Animals*, pp. 193–262. Edited by G. H. Bourne and M. N. Golarz. Karger: Basel.
- Buchthal, F., and Rosenfalck, A. (1966). Evoked action potentials and conduction velocity in human sensory nerves. *Brain Research*, **3**, 1–119.
- Buchthal, F., Rosenfalck, A., and Behse, F. (1975). Sensory potentials of normal and diseased nerves. In *Peripheral Neuropathy*, vol. 1, pp. 442–464. Edited by P. J. Dyck, P. K. Thomas, and E. H. Lambert. Saunders: Philadelphia.
- Denny-Brown, D., and Brenner, C. (1944). Paralysis of nerve induced by direct pressure and by tourniquet. *Archives of Neurology and Psychiatry (Chic.)*, **51**, 1–26.
- Eckhoff, N. L. (1931). Tourniquet paralysis. *Lancet*, **2**, 343–345.
- Fowler, T. J., Danta, G., and Gilliat, R. W. (1972). Recovery of nerve conduction after a pneumatic tourniquet: observation on the hindlimb of the baboon. *Journal of Neurology, Neurosurgery, and Psychiatry*, **35**, 638–647.
- Gilliat, R. W. (1975). Peripheral nerve compression and entrapment. In *11th Symposium on Advanced Medicine. Proceedings of the Royal College of Physicians*, pp. 143–163. Edited by A. F. Lant. Pitman: London.
- Harrison, M. I. G. (1976). Pressure palsy of the ulnar nerve with prolonged conduction block. *Journal of Neurology, Neurosurgery, and Psychiatry*, **39**, 96–99.
- Medical Research Council (1943). *Aids to the Investigation of Peripheral Nerve Injuries*, pp. 48. HMSO: London.
- Moldaver, I. (1954). Tourniquet paralysis syndrome. *Archives of Surgery*, **68**, 136–144.
- Ochoa, I., Fowler, T. I., and Gilliat, R. W. (1972). Anatomical changes in peripheral nerves compressed by a pneumatic tourniquet. *Journal of Anatomy*, **113**, 433–455.
- Olsen, P. Z. (1975). Prediction of recovery in Bell's palsy. *Acta Neurologica Scandinavica*, suppl. 61, 1–121.
- Rosenfalck, A., and Rosenfalck, P. (1975). *Electromyography, Sensory and Motor Conduction. Findings in Normal Subjects*, pp. 49. Rigshospitalets forlag: Copenhagen.
- Rudge, P. (1974). Tourniquet paralysis with prolonged conduction block. An electro-physiological study. *Journal of Bone and Joint Surgery*, **56-B**, 716–720.
- Trojaborg, W. (1964). Motor nerve conduction velocity in normal subjects, with particular reference to the conduction in proximal and distal segments of ulnar and median nerves. *Electroencephalography and Clinical Neurophysiology*, **17**, 314–321.
- Trojaborg, W. (1970). Rate of recovery in motor and sensory fibres of the radial nerve. Clinical and electrophysiological aspects. *Journal of Neurology, Neurosurgery, and Psychiatry*, **33**, 625–638.
- Trojaborg, W. (1976a). Changes in motor unit parameters during reinnervation. In *Annual Report of the Institute of Neurophysiology of the University of Copenhagen*, pp. 15–16. Universitetsforlaget: Copenhagen.
- Trojaborg, W. (1976b). Motor and sensory conduction in the musculocutaneous nerve. *Journal of Neurology, Neurosurgery, and Psychiatry*, **39**, 890–899.
- Trojaborg, W., and Sindrup, E. H. (1969). Motor and sensory conduction in different segments of the radial nerve in normal subjects. *Journal of Neurology, Neurosurgery, and Psychiatry*, **32**, 354–359.