

Motor neurone disease and exposure to lead

A. M. G. CAMPBELL, E. R. WILLIAMS, AND D. BARLTROP

From the Royal Infirmary, Bristol, and The Paediatric Unit, St. Mary's Hospital Medical School, London

SUMMARY Disease of the lower motor neurone is a recognized hazard of lead toxicity, but the importance of contact with lead in the causation of motor neurone disease has not previously been ascertained. In 74 cases of motor neurone disease, 15% had a history of extensive exposure to lead, compared with 5.4% of a control group. The five year survival rate of these patients was 54%, compared with 16% in the remainder. The more benign course of the disease in some of these cases may be due to treatment with chelating agents. A history of either disease of the axial skeleton or previous fracture was obtained in 25% of patients compared with 9.4% of controls. There may be a relationship between skeletal demineralization and the development of motor neurone disease. The lead content of iliac crest bone biopsy specimens in 25 patients with motor neurone disease was no greater than that of a control group, but this does not exclude the possibility that lead liberated from bone might affect the motor neurone.

Toxic effects of lead on the nervous system are well recognized. Acute exposure to lead may cause either an acute, asymmetrical motor neuromyopathy with spontaneous recovery ('painters' wrist-drop') or, particularly in children or where the exposure has been severe (Barltrop, 1968), encephalopathy.

A third variant of neurological system disease, associated with chronic lead toxicity, was described by Kinnier Wilson in 1907. In his cases, a distal symmetrical wasting and weakness of muscles was present, there was evidence of pyramidal tract disturbance in some, and fasciculation was recorded. In 1940 Wilson cited other cases described by earlier authors, and reported two or three other examples. Other instances of motor system disease, associated with lead contact, with varying degrees of upper or lower motor neurone involvement have been reported by Campbell (1955); Simpson, Seaton, and Adams (1964); Livesley and Sissons (1968); and Campbell and Williams (1968). In Aran's original description of the progressive muscular atrophy form of motor neurone disease (MND) in 1850, three of his 11 cases had been in contact with lead and two of these had previously suffered from lead poisoning. He drew a distinction between his cases and the 'paralysies saturnines' with which he was familiar. Lead poisoning was common in the 19th century: 1,217 cases of lead poisoning were seen in one year in Paris (Tanquerel des Planches, 1839). Aran did not consider that lead was an aetiological factor in

his cases, though he cited a case recorded in the previous century by Van Sweiten in which there was generalized muscular wasting and weakness related to contact with lead. This was probably the first recorded instance of generalized motor system disease associated with lead contact.

In spite of recognition of the hazard to health caused by excessive exposure, lead and its compounds are widely distributed. It has been estimated that the mean adult intake of lead as a result of environmental contamination is 300 $\mu\text{g}/\text{day}$ (Kehoe, 1961) as opposed to an estimated natural background intake of 20 $\mu\text{g}/\text{day}$. The reasons for this, together with evidence of increasing contamination have been summarized by Barltrop (1969). A recent study (Crawford and Crawford, 1969) has shown that the mean bone lead content was higher in a soft-water than a hard-water area, and, although the levels found had been considered harmless, they emphasized that there was little information about long-term exposure to lead or the later effects of a large dose. While the use of lead for water pipes and pigments is decreasing, occupational contact with lead is present in a surprisingly wide variety of pursuits. Gowers (1893) included cases of poisoning from colouring matter in paper, glazing on cards, hair dyes, and cosmetics in a list of causes of lead poisoning. In the series to be described significant lead contact was discovered in diverse occupations including a labourer in a plastics factory, an

analytical chemist, and the domestic fermentation of wine in a lead-glazed vessel. Cases of overt lead poisoning usually occur in hazardous occupations such as the smelting of lead ore, making or burning battery plates, mixing lead pigments, and burning lead paint—for example, in shipyards (Barltrop, 1969). Sporadic cases from the contamination of food and beverages still occur (Power, Barnes, Nash, and Robinson, 1969).

After absorption from the gut, lead is deposited initially in the soft tissues such as liver, kidney, and the erythrocytes, but is transferred ultimately to bone. Lead is stored in bone in a biologically inactive form (Kehoe, Thamann, and Cholak, 1933), and increasing bone lead levels with age have been demonstrated (Minot, 1938; Horiuchi, Horiguchi, and Suekane, 1958). The biological half-life of lead in skeletal tissues is probably at least 12 years (Jaworowski, 1967), so that prolonged exposure results in increased bone lead concentration which will persist after the original exposure has ceased and the blood lead concentration has returned to normal.

In 1966, Professor Dent drew our attention to the resemblance between conditions associated with hyperparathyroidism and some that we had found to be associated with MND including peptic ulceration, sarcoidosis, bone disease, and a liability to fracture. We have previously reported motor system disease associated with skeletal deformity consequent upon previous poliomyelitis (Campbell, Williams, and Pearce, 1969). In this study we have ascertained the incidence of bone disease and of exposure to lead in MND and have investigated various aspects of tissue lead concentration.

METHODS

One hundred patients presenting with wasting, weakness, and fasciculation of muscle, with or without physical signs of an upper motor neurone lesion and with no sensory loss, were studied. Full clinical details are to be reported in another communication. Seventy-four patients attending two centres (Bristol and Bath) after June 1965 in whom a diagnosis of motor neurone disease had been made were seen by one of us (E.R.W.) and a full clinical, occupational, and environmental history obtained by means of a standardized questionnaire; a control series, matched for age and sex, was obtained from consecutive admissions to a general medical ward, and these patients were interviewed in an identical manner. A further 26 patients, who had presented at Bath after January 1960, died before 1965 and were studied retrospectively.

Bone biopsies were obtained from the iliac crest in 25 patients. A small incision was made over the anterior superior iliac spine under local anaesthesia, the periosteum reflected, and a core of tissue perpendicular to the surface obtained with a stainless steel trephine (Byers and Smith, 1967). The biopsy thus contained a constant

proportion of compact and cancellous bone. The specimen was placed, dry, in a lead-free polystyrene container without further handling, and the incision closed with interrupted sutures. A total of 31 biopsies have been performed without complication. Specimens were obtained from a control series at necropsy on cases of sudden death, using similar techniques. The principal cause of death (65%) in the control series was cardiovascular accident. The two groups comprised individuals from the same region who were of comparable age, although the mean age of the motor neurone group was slightly less (54.8 years) than of the controls (62.9 years). The specimens were stored at -20°C pending analysis. In 16 patients, two specimens were taken from adjacent sites and the second placed in formalin for histological examination.

The samples were wet-ashed with nitric acid until the residue was colourless. The ash was dissolved in normal hydrochloric acid and the lead concentration determined by polarography after suppression of interference due to ferric ions with hydroxylamine hydrochloride or with ascorbic acid. The calcium content of the same specimen was determined by atomic absorption spectroscopy. Within the limits used, the methods had coefficients of variation of 6.1% for lead and 3.6% for calcium. By expressing the lead contents in terms of bone calcium, errors due to variations in sampling technique and in the mineralization of the bones were avoided.

RESULTS

LEAD CONTACT In the first 26 patients, studied retrospectively, a record of lead contact was found in two patients, one of whom had had lead poisoning 14 years before the onset of the disease, the source being lead paint in an old house.

Twenty-three of the 74 patients (32%) who were interviewed gave a history of lead contact and the details of this group are given in Table 1. The cases have been divided into two groups. The first group (11 patients) had had severe exposure to lead (contact in a situation previously reported to cause lead poisoning); the remainder had apparently slight exposure. Only two women gave a history of lead contact, although the male-female ratio of the series was 2.2 : 1.

The control group contained 23 women and 51 men. The mean age was 56.2 years compared with the mean age (at onset of disease) of 55 years in the group under study. The incidence of lead contact in the control group is compared with the patient group in Table 2.

Slight exposure seemed to be equally common in patients and controls, but there was a marked difference in the incidence of severe exposure. The difference between these proportions (15% as against 5.4%) was statistically significant ($P < 0.05$).

NATURAL HISTORY OF DISEASE In the group as a

TABLE 1
LEAD CONTACT IN MND

| MND* | | Lead contact | |
|------------------------|---------------|---|---------------|
| Type | Duration (yr) | Nature | Duration (yr) |
| <i>Severe exposure</i> | | | |
| Male | | | |
| LMN (slow) | 20 | Paint grinder | 35 |
| LMN (slow) | 10 | Printer using lead type | 36 |
| LMN (slow) | 7 | Molten lead in panel beating | 13 |
| LMN (slow) | 5½ | Marine engineer: red lead submarine batteries | 15 |
| LMN | 2½ | Lead poisoning from home-made wine 32 years previously | |
| Bulbar | 1½ | Painting, plumbing, window-leading | 37 |
| LMN | 1½ | Plumber | 5 |
| UMN | 1 | Burnt car batteries occasionally | |
| LMN | ½ | Mixed plastics powder containing lead oxide | 14 |
| <i>Slight exposure</i> | | | |
| Female | | | |
| LMN (slow) | 15 | Pipetted lead solutions | 12 |
| LMN | 5 | Lead pigments and glazes | 51 |
| Male | | | |
| LMN | 8 | Decarbonized engines occasionally | |
| LMN | 5 | Airgun pellet in neck | 55 |
| UMN | 3½ | Electrical engineer, handled lead-lined cables occasionally | |
| UMN | 2½ | Paint retailer, D.I.Y. painting occasionally | |
| LMN | 2 | Lead shot in arm | 64 |
| Bulbar | 2 | Licked lead paper weight on desk | 38 |
| Bulbar | 2 | Decarbonized aero-engines occasionally | |
| Bulbar | 2 | Clergyman painted his church 3 times with white lead | |
| LMN | 1½ | Builder, strips and lays lead sheet occasionally | |
| LMN | 1½ | Oil-painting (hobby) | 10 |
| LMN | ¾ | Shipyard worker; occasional red lead | 6 |
| Female | | | |
| LMN | 2½ | Washed her painter husband's overalls by hand | 30 |

*Type of MND: UMN, predominant upper motor neurone involvement; LMN, predominant lower motor neurone involvement; Bulbar, predominant bulbar involvement; Atypical (slow LMN), predominant lower motor neurone involvement with slow progression.

TABLE 2
LEAD CONTACT IN MND

| | Cases (no.) | Severe exposure | Slight exposure | Mean age (yr) |
|----------|-------------|-----------------|-----------------|---------------|
| Patients | | | | |
| Males | 51 | 9 | 11 | 56.5 |
| Females | 23 | 2 | 1 | 57.5 |
| Total | 74 | 11 | 12 | 56.8 |
| Controls | | | | |
| Males | 51 | 4 | 10 | 56.0 |
| Females | 23 | — | 2 | 56.8 |
| Total | 74 | 4 | 12 | 56.2 |

whole, the age at onset, mean duration, survival rate, and the ratio between predominantly upper motor neurone, lower motor neurone, and bulbar disease, was similar to other published studies (Partington, 1962; Vejjajiva, Foster, and Miller, 1967). In contrast, of the 11 patients with major lead contact, six have survived for more than five years and of these five show a similar clinical picture with symmetrical, predominantly lower motor neurone involvement. The five-year survival rate of this group of 11 patients was 54%, but was only 16% in the 89 without major contact with lead. The difference between these two groups was significant ($P < 0.05$).

DISEASE OF BONE A fracture had been sustained by 22 of the 74 patients questioned, at some time before the onset of their neurological disease, and in nine of these the fracture had occurred in the five years preceding onset. Disorders of the axial skeleton were present in 10 other patients (Table 3).

TABLE 3
DISORDERS OF AXIAL SKELETON IN MND

| Diagnosis | Patients (no.) |
|--|----------------|
| Scoliosis and kyphosis | 3 |
| Osteoporosis antedating neurological disorder | 3 |
| Spinal disease treated by immobilization or manipulation under general anaesthesia | 2 |
| Paget's disease | 1 |
| Osteochondritis, collapse of vertebrae, and spondylolisthesis | 1 |
| Osteomyelitis (staphylococcal) | 1 |

The incidence of gastrectomy, previous peptic ulcer, and poliomyelitis was determined, since these conditions have all previously been implicated in the causation of MND and could have affected bone metabolism. The results obtained from the patients and controls are given in Table 4.

TABLE 4
MND AND POTENTIAL DISORDERS OF BONE CALCIUM METABOLISM

| Diagnosis | MND (%) | Control group (%) |
|--------------------------------|---------|-------------------|
| History of fracture | 31 | 28.4 |
| Fracture in preceding 5 years | 12 | 4 |
| Disease of axial skeleton | 13 | 5.4 |
| Upper gastrointestinal disease | 6 | 8.1 |
| Second world war P.o W. | 3 | 0 |
| Poliomyelitis | 5 | 0 |
| Sarcoidosis | 1.3 | 0 |

There was no significant difference between the two groups in the percentage of previous fractures,

but fracture in the preceding five years (excluding fractures occurring after the first symptom of MND) was significantly more frequent in the patient group ($P = 0.05$). Disease of the axial skeleton was also more common in the patient group: if the occurrence of either fracture in the last five years or bone disease are considered together, the preponderance in the patient group is highly significant ($P < 0.01$). The presence of three ex-prisoners of war in the patient group may have been due to chance, but they are known to have suffered a period of severe malnutrition for two to three years with an estimated daily calcium intake of less than 200 mg, which may have affected bone metabolism.¹

Histological examination of the 16 bone biopsy specimens was carried out by Dr. O. G. Lloyd (Department of Pathology, Bristol University). In 15 of these, osteoporosis graded slight to severe was demonstrated. It may be that this was a skeletal response to muscle wasting (Foyle, Brown, and Lachance, 1970), but in three patients osteoporosis was demonstrated radiologically before the onset of their MND.

PILOT LEAD STUDIES To explore possible environmental influences on tissue lead concentration, blood lead levels were estimated on 12 patients and were compared with those from husband, wife or (in one case) brother.

¹Recommended daily minimum Ca requirement 500 mg (H.M.S.O. (1969) C.M.O. Report, report on Public Health N.120.)

Although one patient and one control had levels above the upper limit of normal of 40 $\mu\text{g}/\text{ml}$. (Lane, 1968), there was no significant difference between the means of the two groups.

BONE LEAD In a preliminary study of bone lead concentrations, iliac crest bone biopsies from five patients and four age- and sex-matched control specimens obtained at necropsy were ashed and analysed for lead content at another centre, but the results were equivocal. An extended study of bone lead concentration in later patients was therefore instituted with the determinations made at St. Mary's Hospital Medical School by one of us (D.B.).

The values ranged from 8 to 3,500 $\mu\text{g}/\text{g}$ calcium in the MND group, contrasting with the control group which ranged from 9 to 1,800; the populations were markedly skewed, however, so that the upper limits were represented by few observations in either case and the mean values were almost identical (415 and 410 $\mu\text{g}/\text{g}$ calcium respectively) (Fig. 1). There was no significant correlation between bone lead concentration and previous exposure in individual cases, although in one case (A.A.) there was an unexpected high bone lead concentration and clinical improvement with chelating agents. Of the six patients in the severe exposure group who were biopsied, four had had previous treatment with chelating agents which might have lowered their bone lead concentration.

URINE LEAD EXCRETION AFTER CHELATING AGENTS In 1955, two patients discussed in this paper (A.B.

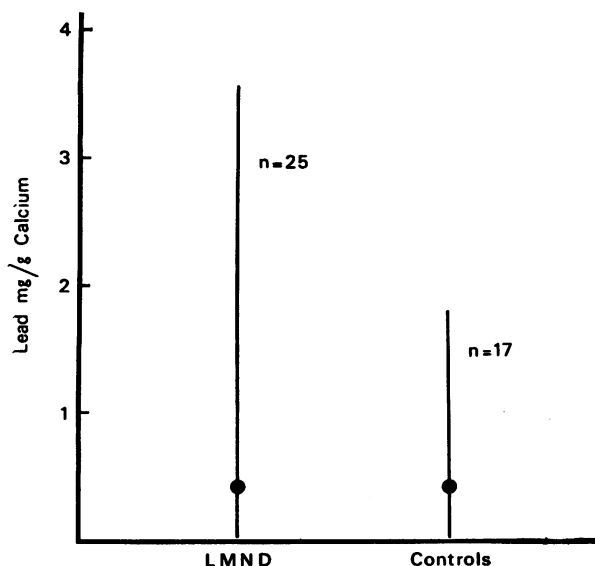


FIG. 1. Bone (iliac crest) lead concentration/g calcium in patients with motor neurone disease and in a control group.

and R.P.) were treated with the chelating agent calcium EDTA (calcium disodium edetate). Four other cases of MND were treated at that time with no clinical improvement. Urine lead excretion before and after the chelating agent was measured in some patients at that time, using a polarographic method (Dr. M. Plaice and Dr. P. Warren, Bristol University Department of Chemistry) (Fig. 2).

We have estimated urinary lead excretion after the administration of chelating agents in three patients (R.P., A.A., and C.E.B.) who had major contact with lead but who have survived for more than five years. Two of these three excreted greater than normal amounts of lead after treatment. These cases may be contrasted with those previously reported in that symptoms of systemic lead toxicity were absent. If exposure to lead were related to motor system disease in these patients, it would seem that neither the duration nor the severity of exposure was critical in the development of the disease.

Seven of our cases appear to form a clinical variant of MND characterized by symmetrical predominantly lower motor neurone weakness, slow progression, and a history of major contact with lead. Treatment with chelating agents seemed to have altered the course of disease in five of these seven patients, and their case histories may be of interest.

CASE 1

C.E.B. presented seven years ago aged 60 years with a three year history of increasing weakness of the limbs commencing in the legs. This had resulted in several falls in one of which he had dislocated his left elbow. He had worked for 40 years as a compositor in a printing works, during which he had handled and cleaned lead type. Initial examination revealed widespread fasciculation and wasting, most marked in the small muscles of the hand. The tendon reflexes were diminished but there were no sensory abnormalities. The urine coproporphyrin concentration was low and it was not thought necessary at that time to determine the blood lead concentration. In view of the strong history of contact with lead he was given 9g of calcium EDTA intravenously during an 11 day period. Urinary lead concentration before therapy was 1.65 $\mu\text{g/l.}$; this increased to 58 $\mu\text{g/l.}$, 24 hours after the first infusion. There was some subjective improvement, and when seen again after 12 months, no progression had taken place. At that time the blood haemoglobin, ESR, serum calcium and phosphate were within normal levels and the serum creatinine phosphokinase was 1.9 units (normal less than 1.5). The blood lead was 28.3 $\mu\text{g/100 ml.}$

He has been followed-up regularly since, and no objective increase in weakness has been demonstrated during a four year period. When reassessed six years after onset he still had wasting and weakness of muscle with fasciculation and normal reflexes. Electromyography showed a normal motor nerve conduction velocity

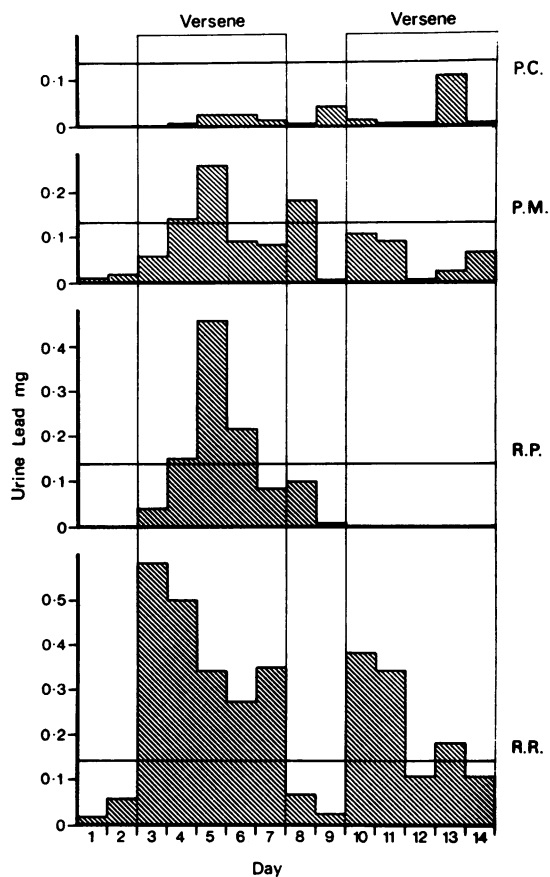


FIG. 2. Excretion of lead in urine of four patients given EDTA

P.C. aged 35 was a classical rapidly progressive case of MND with no history of lead contact, and this is confirmed by the low lead excretion indicated.

P.M. was a case of cervical spondylosis, who lived in a lead-bearing area of the Mendip hills with a local water supply. Marked excretion of lead after EDTA therapy.

R.P. had MND and a history of contact with lead. Marked excretion of lead after EDTA rising to 400 μg during the third day.

R.R. had frank lead poisoning due to the ingestion of lead arsenite, with basophilia, colic, vomiting, and severe polyneuritis which may have been partly due to arsenic and partly due to lead. A marked excretion of lead for several days after EDTA with complete recovery.

through the forearm (50 m/sec) and a remarkably good interference pattern.

CASE 2

V.P. presented five years ago aged 36 years with a nine

month history of weakness and wasting of muscles, starting in the right hand and spreading to the left hand and the legs five months later. She had worked with lead pigments and glazes during four years at an art college from the age of 18, and admitted to sucking her paint brushes to keep a fine point on them. She had had no contact with lead since that time. In 1960 she developed erythema nodosum and hilar gland lymphadenopathy. A lymph gland biopsy confirmed sarcoidosis. She was treated conservatively and her signs disappeared after six months. She was then well until the onset of motor system disease in 1964.

In 1965 examination revealed predominantly distal wasting and weakness of the upper limbs, right more than left, and slight weakness of the lower legs. There was generalized scanty fasciculation, brisk tendon reflexes, flexor plantar responses, and no bulbar involvement. No impairment of sensation was found.

INVESTIGATIONS The blood haemoglobin, film, ESR, urea, electrolytes, serum calcium, phosphorus and alkaline phosphatase were normal. Serum creatine phosphokinase levels on two occasions were 0.25 and 5.4 units (normal 1.5 units). The serum vitamin B₁₂ level was 800 µg/l. A muscle biopsy showed the appearances of denervation, and electromyography (Dr. G. Rushworth) suggested pathology of the lower motor neurone and central motor pathways, compatible with the diagnosis of motor neurone disease. The blood lead was 50.9 µg/100 ml.

She was given a three-month course of penicillamine 300 mg q.d.s. During the next 18 months she improved subjectively. Her reflexes became brisker and the plantar responses extensor, however, although objective measurements of grip showed only slight deterioration in the right hand and none in the left. Impaired muscular power in cold weather with improvement after sitting in a warm room was noted.

In 1966 she became pregnant, and during the last trimester of pregnancy her condition deteriorated slightly. In the six months after delivery (of her seventh child) she noticed, for the first time, impairment of speech and swallowing and was noted to have wasting and fasciculation of the tongue and impaired palatal strength. In the last six months, however (up to December, 1969) there has been no subjective deterioration and only slight impairment of palatal strength.

CASE 3

A.B. presented 16 years ago aged 48 years with a gradually progressive wasting of the hands and arms, right more than left, wrist-drop being the predominant feature. Initial examination revealed a generalized wasting and weakness of muscles with widespread fasciculation. The reflexes were present but not increased. The weakness was most marked in the extensor muscles of the wrists and ankles.

During the first year her disease had progressed steadily and she had noted increased generalized fasciculation. In 1955 she was given her first course of calcium EDTA and had altogether four courses in that year, a total of 40 g in all. After each course she noted a subjective improvement and between 1956 and the present

date has noticed no significant deterioration, except that in 1959 she had thought that her fasciculation was increasing; she was given another 20 g course of calcium EDTA intravenously and has remained unchanged to the present date.

Between 1926 and 1938 she worked as an analytical chemist in a large food company and pipetted lead acetate daily; she admitted that small quantities of this substance were frequently ingested accidentally.

CASE 4

R.P. presented 19 years ago aged 58 years with a history of one year's weakness and wasting of muscles affecting mainly the proximal limb musculature. There was also an extensor plantar response on the right, scanty generalized fasciculation, and slight involvement of the small muscles of the hand. There was no sensory abnormality. He had worked as a paint maker, grinding lead compound, for 14 years.

INVESTIGATIONS Blood haemoglobin concentration was 13.9 g%, film normal, CSF protein 40 mg%, blood and CSF WR negative. Blood lead concentration was 80 µg/100 ml., bone lead concentration (tibial biopsy) 64 p.p.m. wet weight. Electromyographic studies suggested denervation.

He was given alternative employment by his company so that he no longer came in contact with lead, but his condition steadily deteriorated over the next three years. In 1955 he was readmitted and at this time he had difficulty in climbing stairs, and wasting of the distal muscles was more marked; fasciculation persisted.

He was given a total of 10 g calcium EDTA by intravenous infusion, followed by an oral dose of 4 g daily for five weeks. Urine lead excretion after treatment is shown in Fig. 2. Within three months of discharge the patient was convinced that his deterioration had been halted. In 1956 he was given a further 10 g calcium EDTA intravenously which resulted in subjective improvement. In the last 13 years there has been no deterioration, although he has suffered two myocardial infarctions. When reassessed in 1969 he had generalized wasting, weakness, and fasciculation of muscle, but his grip strength was still 50% of normal. The iliac crest bone lead concentration was 23 µg/g Ca.

CASE 5

A.A. presented a year ago aged 44 years with a six month history of weakness and wasting of the hands, and with slight difficulty in walking during the preceding three months. His symptoms were worse in cold weather. Two years previously he had dropped a weight on his foot and fractured a metatarsal bone. For 14 years he had worked as a labourer in a plastics factory and stated that he had regularly handled and swept up dust containing a lead compound used in the manufacturing process. This is a substance containing 8% lead by weight but for most of the process it is used in a wetted form.

He had wasting and weakness of the small muscles of the hand, slight weakness of the distal muscles of the lower limbs, depressed tendon reflexes, flexor plantar

responses, and scanty generalized fasciculation. There was no sensory loss.

INVESTIGATIONS Blood haemoglobin concentration was 15 g%, film normal. Blood urea, electrolytes, calcium, phosphate and alkaline phosphatase were normal. Serum creatinine phosphokinase was 4.1 units. Iliac crest bone biopsy showed osteoporosis.

The clinical picture was that of the progressive muscular atrophy type of MND and over the next five months there was moderate deterioration, with a 20% decrease in grip strength. Bone lead concentration (from an iliac crest biopsy) was found to be very high, however (3,540 $\mu\text{g}/\text{Ca}$), and he was readmitted. The blood lead concentration was only 39 $\mu\text{g}/100\text{ ml}$. but he was given calcium EDTA by intravenous infusion. A resting urinary lead excretion was 50 $\mu\text{g}/24\text{ hours}$ and excretion after 1 g calcium disodium edetate was 492 μg in the first 24 hours and 141 μg in the next 48 hours. He was given a total of 5 g calcium EDTA. A month later his grip had improved by 15% but after a further two months it had deteriorated to the same value as before his course of chelating agents.

CLASSICAL MND AND LEAD EXPOSURE Some patients whose motor neurone disease followed a typical course had impressive histories of lead contact but no evidence of present increased burden of lead was found. During the last 15 years one of us (A.M.G.C.) has treated 10 patients in this category with chelating agents without influence on the course of the disease.

CASE 6

S.M. presented two years ago aged 52 years with a year's history of progressive dysphagia and dysphonia. Five years previously he had suffered multiple fractures after a fall. For a total of 37 years until the onset of his disease he had worked with lead, initially as a decorator and later as a plumber. He had worked with molten lead making ornamental window panes and, since 1962, as a lecturer in a building trades' college, had demonstrated experimentally the manufacture of lead pigments from metallic lead.

He had severe bulbar palsy with wasting and fasciculation of the tongue, slight wasting and weakness of distal limb muscles, widespread fasciculation, pathologically brisk reflexes, and extensor plantar responses. Urine lead excretion after administration of calcium EDTA was not raised (excretion in three 24 hour periods after EDTA treatment with 1 g intravenously daily was 191, 135, and 139 μg compared with pretreatment levels of 63 and 25.7 $\mu\text{g}/24\text{ hours}$). Bone lead content was 55 $\mu\text{g}/\text{g}$ calcium. He was given 10 g calcium EDTA in all, but his disease progressed inexorably, and he died 18 months after the first symptom of MND.

In only one case in the present series was there a past history of frank lead poisoning, and his disease followed a typical course.

CASE 7

T.A. aged 58 years, developed wasting, weakness, and fasciculation of the small muscles of the left hand, which spread rapidly to the other limbs. He had farmed all his life, and had no history of industrial lead contact. Thirty-two years previously he and his wife had suffered an acute attack of lead poisoning after drinking home-made sloe and plum wine which had been fermented in an earthenware lead-glazed vessel. Both had severe abdominal colic, constipation, and anaemia but no neurological symptoms, and had made an apparently complete recovery.

When first seen, he presented the typical picture of MND of the progressive muscular atrophy type. The bone lead concentration fell within the middle range of the values obtained in our study (188 $\mu\text{g}/\text{g}$ Ca). His muscular weakness was rapidly progressive, although the bulbar muscles were spared until the terminal stage of the disease. He died in respiratory failure 30 months after his first symptom.

This case history is similar to one recorded by Kinnier Wilson (1940). His patient developed typical MND eight years after an episode of lead poisoning with wrist-drop (left more than right) from which he made a partial recovery.

DISCUSSION

In the search for aetiological factors in motor neurone disease, the role of lead and other heavy metals has frequently been discussed. Lead has a potent inhibitory effect on the activity of some enzyme symptoms, particularly those with -SH groups, and also affects the metabolism of deoxyribonucleic acid, proteins, and pyruvate (Bartrop, 1969). In a chronic toxicity study in guinea-pigs (Fullerton, 1966), it was shown that, while large doses of lead caused death from cerebral oedema, small doses produced chronic wasting and weakness, with widespread motor-nerve demyelination. The only detailed investigation so far reported of heavy metal metabolism in motor neurone disease (Currier and Haerer, 1968) did not demonstrate any increase in urinary lead excretion in a series of 31 patients, nine of whom had had possible lead exposure. Urine lead excretion may be affected by many factors other than the total body lead content, however, and these authors accept that past exposure to toxic metals might initiate a process of neuronal degeneration which might become evident when pathological concentrations of such substances are no longer detectable in the body fluids.

Lead excretion bears only an indirect relationship to the physical signs in cases of lead toxicity, and there is individual variation in tolerance. Previous

reports of patients with motor system disease and lead contact treated with chelating agents have been made. Simpson *et al.* (1964) described a patient in whom the previous symptoms suggested acute lead toxicity and who excreted large amounts of lead after calcium EDTA administration. Livesley and Sissons (1968) reported a case in which there had been episodes of colicky abdominal pain before his neurological symptoms and in whom urinary lead excretion was high (136 μg and 170 μg per 24 hours). This patient was treated with oral penicillamine, but the lead excretion during treatment was not measured.

Brown and Tompsett (1945) reported a case of generalized acute peripheral neuritis occurring in a type-setter who had developed lymphatic leukaemia. Death was due to lead poisoning, and it was thought that lead had been mobilized from the skeletal deposits. Brown (1946) in Glasgow reported 22 cases who had had no industrial lead contact but in whom the blood lead was high, associated with various diseases causing rarefaction of bone, particularly skeletal metastatic carcinoma and widespread reticulosis. He suggested that lead stored in bone might be liberated by an osteolytic process. Mobilization of calcium from the skeleton has been shown to occur with immobilization (Deitrick, Whedon, and Shorr, 1948), after fracture (Howard, Parson, and Bigham, 1945; Bauer and Carlsson, 1955), in osteoporosis (Heaney, 1962), and after poliomyelitis (Whedon and Shorr, 1957). Lead, or some other toxic heavy metal, might be assumed to behave in a similar manner (Brown, 1946). In a study of bone loss in ageing, Newton-John and Morgan (1968) showed that this commences between 45 and 65 in men; this is of interest in view of the peak age of incidence of MND of around 55 years.

In this study a statistically significant relationship between antecedent bone disease or fracture and the development of MND has been demonstrated, which supports a relationship between skeletal demineralization and the development of MND. Impaired absorption of bone mineral, which might occur in the post-gastrectomy state or intestinal malabsorption, was not statistically related to the subsequent onset of MND in our patients. This mechanism would fit the hypothesis, however, and the occurrence of MND in three ex-prisoners of war and one case of sarcoidosis is of interest in this respect.

Although our study of bone lead concentration is too small to draw any final conclusions, there is no evidence that the total body burden of lead in patients with MND is abnormal. This does not refute the hypothesis that lead may be an aetiological agent, since a transient intense exposure may be

responsible and yet would contribute little to the bone lead concentration.

This study has demonstrated a clinical variant of disease of the motor neurone characterized by symmetrical predominantly lower motor neurone weakness, slow progression, and a history of major contact with lead, and seven of our cases fell into this group. It is suggested that this lead motor neurone damage is the same condition as Kinnier Wilson's amyotrophy of chronic lead poisoning. Treatment with chelating agents has been reported to result in improvement in motor system disease (Livesley and Sissons, 1968) and this would seem to have occurred in at least five of these seven patients. In some of these, the exposure to lead was not immediately apparent, and the clinical features of this group as a whole did not seem to differentiate these cases from those of classical MND. In the absence of any present therapeutic measures likely to improve MND, therapeutic trial of chelating agents in patients with major lead contact is justifiable.

We thank Dr. F. Page and Dr. G. Wakefield for allowing us to study patients under their care; Dr. G. Rushworth who performed electromyographic studies, and Dr. A. Smith and Miss E. Thonger who assisted with the bone analyses. We acknowledge with gratitude the financial assistance of the Muscular Dystrophy Group of Great Britain. This work forms part of an M.D. thesis to be submitted by one of us (E.R.W.) to the University of Cambridge.

REFERENCES

- Aran, F. A. (1850). R ch rches sur une maladie non encore d crite du syst me musculaire (atrophie musculaire progressive). *Arch g n. M d.*, **24**, 4-35, 172-214.
- Barltrop, D. (1968). Lead poisoning in childhood. *Postgrad. med. J.*, **44**, 537-542.
- Barltrop, D. (1969). Lead poisoning. *Brit. J. Hosp. Med.*, **2**, 1567-1573.
- Bauer, G. C. H., and Carlsson, A. (1955). Post-fracture bone salt resorption studied in rats. *Acta orthop. scand.*, **25**, 83-88.
- Brown, A., and Tompsett, S. L. (1945). Poisoning due to mobilization of lead from the skeleton by leukaemic hyperplasia of bone marrow. *Brit. med. J.*, **2**, 764-765.
- Brown, A. (1946). The lead content of the blood and its relation to rarefying processes in bone. *Quart. J. Med.*, **39**, 77-90.
- Byers, P., and Smith, R. (1967). Trephine for full-thickness iliac crest biopsy. *Brit. med. J.*, **1**, 682-683.
- Campbell, A. M. G. (1955). Calcium versenate in motor neurone disease. *Lancet*, **2**, 376-377.
- Campbell, A. M. G., and Williams, E. R. (1968). Chronic lead intoxication mimicking motor neurone disease. *Brit. med. J.*, **4**, 582.
- Campbell, A. M. G., Williams, E. R., and Pearce, J. (1969). Late motor neurone degeneration following poliomyelitis. *Neurology (Minneapolis)*, **19**, 1101-1106.
- Crawford, M. D., and Crawford, T. (1969). Lead content of bones in a soft and a hard water area. *Lancet*, **1**, 699-701.

- Currier, R. D., and Haerer, A. F. (1968). Amyotrophic lateral sclerosis and metallic toxins. *Arch. environm. Hlth*, **17**, 712-719.
- Dietrick, J. E., Whedon, G. D., and Shorr, E. (1948). Effects of immobilization upon various metabolic and physiologic functions of normal men. *Amer. J. Med.*, **4**, 3-36.
- Doyle, F., Brown, J., and Lachance, C. (1970). Relation between bone mass and muscle weight. *Lancet*, **1**, 391-393.
- Fullerton, P. M. (1966). Chronic peripheral neuropathy produced by lead poisoning in guinea-pigs. *J. Neuropath. exp. Neurol.*, **25**, 214-236.
- Gowers, W. R. (1893). *Diseases of the Nervous System*, vol. 2. p. 944. Churchill: London.
- Heaney, R. P. (1962). Radiocalcium metabolism in disuse osteoporosis in man. *Amer. J. Med.*, **33**, 188-200.
- Howard, J. E., Parson, W., and Bigham, R. S., Jr. (1945). Studies on patients convalescent from fracture III; the urinary excretion of calcium and phosphorus. *Bull. Johns Hopk. Hosp.*, **77**, 291-313.
- Horiuchi, K., Horiguchi, S., and Suekane, M. (1959). Studies on the industrial lead poisoning 1. Absorption, transportation, deposition and excretion of lead. 6. The lead contents in organ-tissues of the normal Japanese. *Osaka Cy med. J.*, **5**, 41-70.
- Jaworowski, Z. (1967). Stable and radioactive lead in environment and human body. *Nuclear Energy Information Center, Review Report No. 29*, Warsaw.
- Kehoe, R. A., Thamann, F., and Cholak, J. (1933). On the normal absorption and excretion of lead. *J. individ. Hyg. Toxicol.*, **15**, 257-289.
- Kehoe, R. A. (1961). The metabolism of lead in man in health and disease, 3. Present hygienic problems relating to the absorption of lead. *J. roy. Inst. publ. Hlth.*, **24**, 177-203.
- Lane, R. E. (1968). Diagnosis of inorganic lead poisoning. *Brit. med. J.*, **4**, 501.
- Livesley, B., and Sissons, C. E. (1968). Chronic lead intoxication mimicking motor neurone disease. *Brit. med. J.*, **4**, 387-388.
- Minot, A. S. (1938). The physiological effects of small amounts of lead: an evaluation of the lead hazard of the average individual. *Physiol. Rev.*, **18**, 554-577.
- Newton-John, H. F., and Morgan, D. B. (1968). Osteoporosis: Disease or senescence. *Lancet*, **1**, 232-233.
- Partington, T. (1962). Motor neurone disease. *Postgrad. med. J.*, **38**, 383-395.
- Power, J. G. P., Barnes, R. M., Nash, W. N. C., and Robinson, J. D. (1969). Lead poisoning in Gurkha soldiers in Hong Kong. *Brit. med. J.*, **3**, 336-337.
- Simpson, J. A., Seaton, D. A., and Adams, J. F. (1964). Response to treatment with chelating agents of anaemia, chronic encephalopathy, and myelopathy due to lead poisoning. *J. Neurol. Neurosurg. Psychiat.*, **27**, 536-541.
- Tanquerel des Planches, L. (1839). *Traité des maladies de plomb ou saturnines*. Ferra, Libraire—Editeur, Paris.
- Vejajiva, A., Foster, J. B., and Miller, H. (1967). Motor neurone disease: a clinical study. *J. neurol science*, **4**, 299-314.
- Whedon, G. D., and Shorr, E. (1957). Metabolic studies in paralytic acute anterior poliomyelitis II. Alterations in calcium and phosphorus metabolism. *J. clin. Invest.*, **36**, 966-981.
- Wilson, S. A. K. (1907). The amyotrophy of chronic lead poisoning: Amyotrophic lateral sclerosis of toxic origin. *Rev. Neurol. Psychiat.*, **5**, 441-455.
- Wilson, S. A. K. (1940). *Neurology*. p. 730. Edward Arnold: London.