

Fungal infections of the small and large intestine

R J Prescott, M Harris, S S Banerjee

Abstract

Aims: To study the pathological features of fungal infections affecting the lower intestinal tract (duodenum, small and large bowels).

Methods: Between mid-1981 and mid-1991, 14 cases of deep mycotic infections affecting the lower intestinal tract were found among 890 consecutive necropsies on patients with malignant disease treated in a regional cancer centre (incidence 1.6%). These 14 cases accounted for 54% of all gastrointestinal fungal infection detected. The relevant clinical, necropsy, histological and microbiological data were reviewed.

Results: *Candida* spp and *Aspergillus* spp accounted for all infections. The macroscopic appearances included ulcers of varying configuration, mucosal flecks, sloughed mucous membranes, polypoid masses and segmental lesions. Either organism could produce this range of lesions, but *Candida* tended to have a mucosal location and *Aspergillus* was associated with transmural invasion. Combined infections showed *Candida* in the surface mucosa and *Aspergillus* hyphae in submucosal vessels with spread into the bowel wall in a radiating pattern. During the final illness, gastrointestinal symptoms and signs were often slight and microbiological investigations were unhelpful.

Conclusions: Variable gross appearances are relevant for endoscopists, particularly lesions which resemble pseudomembranous colitis. Endoscopic biopsy specimens may have a role in antemortem diagnosis. Failure to diagnose these infections during life emphasises the importance of necropsy in the clinicopathological audit of deaths in this group of patients.

Fungal infections are increasingly reported as aetiological agents in man, and are associated with increased use of immunosuppressive treatment regimens for malignant diseases and in connection with organ transplantation. Several reviews have emphasised the importance of fungal infections in such patients.¹⁻⁴ With the advent of AIDS the incidence of common and uncommon infective pathogens, including fungi which may affect the gastrointestinal tract⁵ has correspondingly risen.

In routine necropsy practice the incidence of systemic mycotic infections was reported as

being 1-2%⁶; however, in studies based on selected "high risk" patients who were immunocompromised the incidence was about 20%.⁷ A recent review of invasive aspergillosis revealed an incidence of 1.4% in 2315 consecutive necropsies, but in the immunocompromised group it approached 11%.⁸ A necropsy study of 54 immunocompromised patients with mycotic infection (as a result of chemotherapy or bone marrow transplantation) showed either localised upper and lower gastrointestinal tract or respiratory tract infection, or disseminated infections including both these sites; the principal organisms were *Candida* and *Aspergillus* species.³

Because histopathological reviews of mycotic infections of the alimentary tract, particularly the lower intestinal tract, are sparse, we decided to review all the necropsy cases between mid-1981 and mid-1991 at the Christie Hospital and Holt Radium Institute, which specialises in the treatment of malignant neoplasms, to catalogue these lesions.

Methods

Between mid-1981 and mid-1991, 64 cases of deep mycotic infections were found in 890 consecutive necropsies (incidence 7.2%). Among these there were 26 gastrointestinal infections, with 12 cases affecting the upper gastrointestinal tract (mouth, oesophagus, and stomach) alone, seven the lower intestinal tract (duodenum, jejunum, ileum and colon) alone, and seven both sites. These last 14 cases are the subject of this report.

In the lower intestinal group the following variables were assessed from the clinical records: the age and sex of the patient; the underlying neoplastic condition; and the treatment administered. During the final illness any gastrointestinal symptoms and signs, drug intake, including antibiotics and steroids, the white cell count, results of fungal serological tests and blood and stool cultures were recorded. The degree of the clinician's awareness of an intestinal infection was assessed as well as the clinically perceived mode of death.

The necropsy reports revealed information about the gross appearance and distribution of the lesions together with the extent of other organ disease. An assessment of the degree to which the intestinal disease contributed to death was made. Necropsy stool cultures were sent in three cases. Microscopic examination was undertaken on formalin fixed, paraffin wax embedded sections stained with haematoxylin and eosin, periodic-acid Schiff (PAS) with and

Department of
Histopathology,
Christie Hospital and
Holt Radium Institute,
Manchester M20 9BX
R J Prescott
M Harris
S S Banerjee

Correspondence to:
Dr M Harris

Accepted for publication
24 February 1992

Table 1 Clinical details of presenting condition and treatment

Case No	Age	Sex	Underlying condition	Treatment
1	73	F	Breast carcinoma and nodular sclerosing Hodgkin's disease	Mastectomy, CVPP
2	18	M	Seminoma	CVPP, e, cis
3	15	F	Hodgkin's disease mixed cellularity	VAP MVPP
4	58	F	Breast carcinoma	Mastectomy, Radiation, VAC, pred
5	63	F	Myelodysplasia	DAT
			Refractory anaemia with excess blasts in transformation	
6	62	F	Myelodysplasia	DAT
			Acute myeloid leukaemia	
7	43	M	Chronic myeloid leukaemia and blast crisis	Bone marrow transplant 4 years prior to methotrexate and 6-mercaptopurine
8	58	F	Non-Hodgkin's lymphoma, centroblastic/centrocytic Diabetes mellitus	e, a, i, h, Pred
9	60	M	Non-Hodgkin's lymphoma, lymphoblastic Diabetes mellitus	CHOP, EVAM, pred
10	66	F	Signet ring adenocarcinoma of stomach	e, a, cis
11	67	F	Non-Hodgkin's lymphoma, centroblastic/centrocytic	VAP, CVPP
			Abdominal irradiation	
12	50	M	Non-Hodgkin's lymphoma, lymphoblastic	CHOP, B
13	69	M	Non-Hodgkin's lymphoma, T cell pleomorphic large cell subtype	VAPECB
14	69	M	Non-Hodgkin's lymphoma, diffuse centroblastic of thyroid Diabetes mellitus	VAPECB

Key:

CVPP = chlorambucil, vinblastine, procarbazine, prednisolone; e = etoposide; cis = cisplatin; VAP = vincristine, adriamycin, cyclophosphamide; MVPP = mustine, vinblastine, procarbazine, prednisolone; VAC = vincristine, adriamycin, cyclophosphamide; pred = prednisolone; DAT = daunorubicin, cytosine arabinoside, 6-thioguanine; a = adriamycin; i = ifosfamide; h = hydroxyurea; CHOP = cyclophosphamide, adriamycin, vincristine, prednisolone; EVAM = etoposide, vincristine, adriamycin, methotrexate; B = bleomycin; VAPECB = vincristine, adriamycin, prednisolone, etoposide, cisplatin, bleomycin.

without diastase, Grocott's methenamine silver stain, and the Gram stain. The sections were seen by two pathologists without prior knowledge of the clinical or necropsy data. The fungi were all classified confidently on morphological grounds as either *Candida* or *Aspergillus* sp.

Because of the high degree of agreement between the pathologists, it was not felt necessary to confirm the findings by immunohistochemical or lectin histochemical techniques. *Candida* organisms were characterised by blastospores and pseudohyphae with budding forms and *Aspergillus* organisms by regular septate hyphae which exhibited dichotomous branching.⁹

Results**CLINICAL DATA**

Table 1 shows the relevant clinical details. All patients had advanced malignant disease; eight had malignant lymphoma (two Hodgkin's dis-

ease, and six non-Hodgkin's lymphoma), three cases had leukaemia and four cases had non-haematological malignancies (case 1 had a double malignancy). The time span from diagnosis to death ranged from two months to eight years. All patients had received more than one course of an appropriate chemotherapeutic regimen. Steroids were administered to 11 patients in high doses during the final illness. Two patients had received radiotherapy, with abdominal irradiation in one case (case 11).

Table 2 shows relevant details of the final illness which took no more than 16 days. Gastrointestinal symptoms and signs were variable and ranged from non-existent in one case, mild in seven cases, and severe in six cases. Oral thrush was seen in four cases and alerted the clinician to the possibility of a more serious intestinal infection. All the patients were feverish, although the causes of this were multifactorial. Various antibiotics were given and six patients received specific antifungal

Table 2 Clinical details of final illness

Case No	Gastrointestinal symptoms/signs	Antibiotics	Lowest WCC	Microbiology cultures	
				Blood	Faeces
1	Melaena	n, p, v, me	0.5	NG	NG
2	Tenderness/pain/diarrhoea and vomiting/melaena	n, ceft	0.5	Gram negative bacilli	NG
3	Oral thrush/herpes/abdominal distension	cefu, g, co, ac, mi	0.1	<i>S viridans</i>	NG
4	Slight diarrhoea	n, p	0.1	<i>Ps aeruginosa</i>	NG
5	Melaena	n, v	0.1	<i>E coli</i>	<i>Ps maltophilia</i>
6	Tenderness/distension/diarrhoea and vomiting	me, am	0.2	Coagulase negative <i>Staphylococcus</i> species	NG
7	None	n, p, v, e, ceft, co, am	0.1	NG	NG
8	Mild diarrhoea	n, ci, k	0.1	<i>E coli</i>	NG
9	Tenderness/diarrhoea/melaena	n, p, ci	0.1	NG	<i>S faecalis</i>
10	Oral thrush	n, p, f	0.2	<i>E coli</i> , <i>S aureus</i> , <i>S mitis</i>	NG
11	Tenderness/distension/melaena/abdominal mass	n, ceft, ci	0.1	NG	<i>Proteus</i> species
12	Oral thrush	n, v, i, ceft	0.1	NG	<i>Klebsiella aerogenes</i>
13	Tenderness/mild diarrhoea	n, p	0.1	NG	NG
14	Oral thrush/mild diarrhoea	f, g, ny, k	0.5	<i>E coli</i>	NG

Key: WCC = white cell count ($\times 10^9/l$); n = netilmicin; p = piperacillin; v = vancomycin; me = metronidazole; ceft = ceftazidime; ceftu = cefuroxime; g = gentamicin; co = cotrimoxazole; ac = acyclovir; mi = miconazole; e = erythromycin; am = amphotericin; ci = ciprofloxacin; k = ketoconazole; f = flucloxacillin; i = itraconazole; ny = nystatin; NG = No growth.

Table 3 Necropsy findings

Case No	Other organs affected	Macroscopic findings		Microscopic findings	
		Small bowel	Large bowel	Transmural infarction	Angioinvasion
<i>Candida</i> organisms:					
1	Lungs Oesophagus	Mucosal flecks Irregular ulcers	Mucosal flecks resembling pseudo-membranous colitis Irregular ulcers	-	-
2	None	Matted ileal loops forming bloody mass Peritonitis	Normal	+	+
3	Stomach	<i>Jejunum and ileum</i> segmental infarction with ulcers and bloody masses	Right side colon segmental infarction with polypoid masses	+	+
4	Lungs	<i>Jejunum</i> small ulcers and haemorrhagic nodules <i>Ileum</i> 2 segmental lesions (20 and 6 cm long) with ulcers and bloody membranes	Normal	-	-
<i>Aspergillus</i> organisms:					
5	Lungs Liver Spleen	<i>Jejunum</i> multiple segmental lesions with haemorrhagic ulceration	Normal	+	+
6	None	<i>Distal ileum</i> shallow ulcers of varying shape and size including linear ulcers	Similar lesions with infarction and pelvic peritonitis	+	+
7	Lungs Oesophagus	<i>Jejunum</i> mucosal flecks	Transverse colon mucosal flecks resembling pseudo-membranous colitis	-	-
8	Lungs	<i>Proximal ileum</i> necrotic mucosal plaques with matted ileal loops	Normal	+	+
9	Oesophagus	<i>Jejunum</i> extensive mucosal sloughing. <i>Ileum</i> oval ulcers in longitudinal axis	Right sided colon mucosal sloughing and oval ulcers	(No fungi seen in colonic lesions)	
Combined <i>Candida</i> and <i>Aspergillus</i> organisms:					
10	Lungs Spleen	Normal	Transverse colon segmental infarction	+	+
11	Lungs	Multiple ulcers of linear and serpiginous type Pseudomembranes	Normal	+	+
12	Lungs Liver Brain	<i>Jejunum</i> tumour-like ulcerated intraluminal polypoid mass (4 × 5 cm)	Normal	+	+
13	Oesophagus Oesophagus Stomach	Scattered oval ulcers in transverse axis, some circumferential	Surface bloody exudate	+	+
14	Lungs Stomach	<i>Duodenum</i> multiples small ulcers <i>Jejunum</i> segmental lesion (30 cm long) with ulceration	Normal	+	+

treatment. The rationale for giving these agents included evidence of a systemic mycosis at other sites, notably the lungs in two cases, a high degree of clinical suspicion in two cases, and the use of a standard protocol in febrile patients with acute leukaemia (two cases). During the final illness all patients had severe neutropenia with leucocyte counts generally below $0.1 \times 10^9/l$. The clinical impression of the mode of death included septicaemia in 12 cases of which one was thought to contain a fungal component (case 7).

PATHOLOGICAL DATA

Table 3 shows the necropsy details. Other organ pathology was seen in 12 cases; five cases involved the lungs alone or with other organs except the gastrointestinal tract, three cases involved the upper gastrointestinal tract alone, and four cases both these sites. Of the 14 lower intestinal tract infections, nine cases affected the small bowel alone, one case involved the colon alone, and four both sites. In four cases *Candida* alone was found, in five *Aspergillus* alone, and in five both organisms were identified in the same lesions.

Macroscopically the lesions comprised ulcers, mucosal flecks, sloughed mucous membranes, polypoid masses and segmental lesions (fig 1). The ulcers were of variable configura-

tion including elliptical forms transverse and longitudinal to the bowel axis, serpiginous ulcers, linear ulcers and extensive ulcers with irregular margins (fig 2). Segmental lesions were found in five cases: of these, four cases showed transmural infarction, and one case was due to *Candida* infection limited to the mucosa alone (case 4). In the four cases of segmental infarction, two involved the small bowel alone, one the colon alone, and one both sites. One case was due to *Candida* alone, one to *Aspergillus* alone, and two to both organisms in the same lesions (fig 3). Mucosal flecks were seen in two cases; one was associated with *Candida* and the other with *Aspergillus* organisms admixed with fibrinous exudate.

Of the nine cases with *Candida* infection, five had coexistent infections in the upper gastrointestinal tract. Of the four pure *Candida* lesions, two were limited to the surface mucosa and submucosa, the other two showed extensive angioinvasion with transmural infarction including one with peritonitis producing an inflammatory ileal mass (case 2). In the five cases of combined infection the *Candida* organisms were located only in the surface necrotic debris.

Of the 10 cases with *Aspergillus* infection, seven had coexistent lung lesions. Nine of the *Aspergillus* infections showed transmural

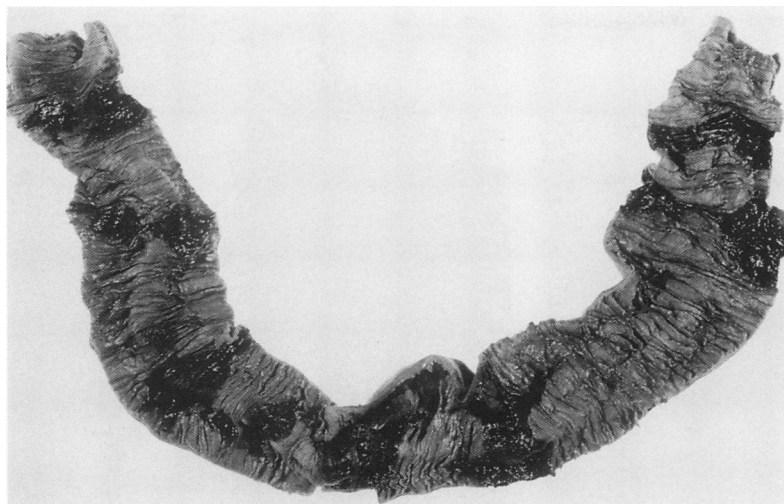


Figure 1 Small bowel showing several short segmental necrotic lesions with irregular margins (case 5).



Figure 2 Large bowel mucosa showing several round/oval shaped ulcers (arrows) and a linear ulcer (arrowhead) (case 6).

infarction characterised by numerous hyphal elements, admixed with fibrin thrombi located in the submucosal vessels, with spread into the surrounding tissues in a radial manner (fig 4). The remaining case showed hyphal elements limited to the mucosal surface alone with no evidence of angioinvasion (case 7).

In keeping with the impaired immune competence of the patients, there was a poor, if any, mixed inflammatory cell response. No granulomas were seen. The Splendore-Hoeppli phenomenon,¹⁰ an immunological reaction, was seen in two cases of *Aspergillus* infection (fig 5). It is characterised by the deposition of an eosinophilic proteinaceous precipitate, believed to be antigen-antibody complexes, outlying the hyphal walls. These deposits have been described before in *Aspergillus* infections.¹¹

MICROBIOLOGICAL DATA

None of the antemortem blood cultures grew fungi and eight cases grew bacterial organisms, mostly of Gram negative species. Specific serological tests for fungi were performed in

four cases but none showed significant rising titres. None of the antemortem faecal cultures grew fungi, but four cases confirmed pathogenic Gram negative organisms (table 2). Three necropsy faecal samples were submitted for analysis and two grew fungal organisms which corresponded with the histological morphology (cases 1 and 6).

Discussion

In 64 immunocompromised patients with deep fungal infections we found that 41% had gastrointestinal infection, with 22% affecting the lower part of the tract. Other studies have reported a much lower overall gastrointestinal infection rate of 9–17% in such patients,^{12 13} but others have found comparable figures including a similar high proportion of lower gastrointestinal tract disease.^{8 14} In agreement with other studies^{3 8 14} 12 of our 14 cases had fungal infections with similar organisms elsewhere, either in the upper gastrointestinal tract or lungs. In our study the lower intestinal tract was affected in 54% of all gastrointestinal tract fungal infections, emphasising how commonly affected this site is.

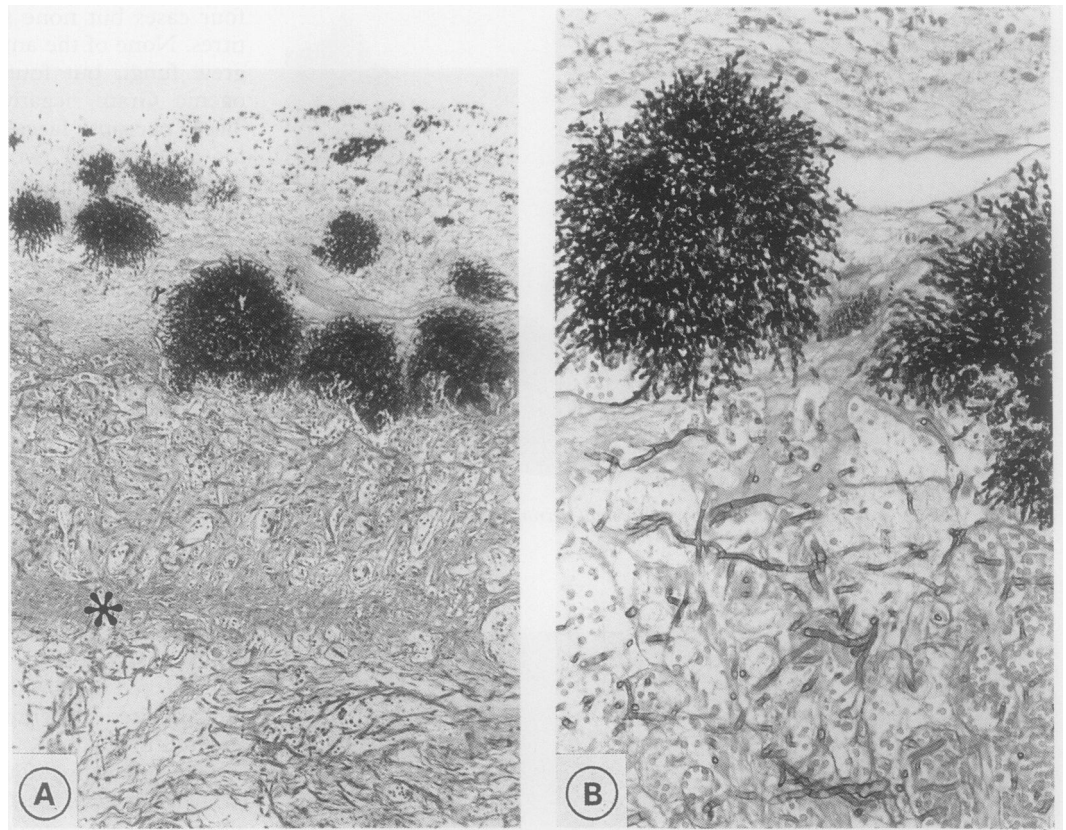
The organisms found in our study were either *Aspergillus* or *Candida*. In a review of alimentary tract mycoses published in 1969, *Candida* and *Mucor* were considered the major pathogens and *Aspergillus* a minor pathogen,⁶ but a more recent review agrees with our findings.³ Infections with *Candida* and *Aspergillus* organisms at differing anatomical sites including the lungs, brain, liver and gastrointestinal tract are well recognised,^{15 16} but combined infections affecting the intestine at the same site in the manner we have described are only mentioned in one review of the subject.¹⁴

Intestinal pathology in disseminated aspergillosis has been reported,^{8 14 15 17 18} but the morphological descriptions of the lesions are scanty and none describes solitary or multifocal infarcted bowel segments with the well demarcated margins that we observed. All of the infarcted lesions, irrespective of gross morphology, were associated with vascular occlusion, mostly by *Aspergillus* organisms, apart from two cases involving *Candida*. This is clearly important in the pathogenesis of the infarction but it is uncertain if the vascular colonisation is embolic from a distant site (such as the lungs) or is due to local invasion following mucosal infection. The latter mechanism most probably applies to *Candida* infections.

Intestinal *Candida* infections were mostly limited to the mucosa/submucosa, particularly in the combined infections where the organisms probably preferentially colonise the previously infarcted bowel. Previous descriptions of pure intestinal *Candida* lesions are similar to our own observations^{15 19} including bowel wall perforation and peritonitis.¹⁹

The macroscopic appearances fell into five categories: ulcers; mucosal flecks; sloughed mucous membranes; polypoid masses; and segmental lesions, none of which was specific

Figure 3 (A–B): *Candida* organisms on the surface of the infarcted bowel mucosa with *Aspergillus* hyphae in the underlying mucosa and submucosa (Grocott's methenamine silver) (case 12). The asterisk shows muscularis mucosae.



for either organism. These findings may be diagnostically important to endoscopists as well as pathologists. Discrete ulcers may resemble those described in typhoid fever, tuberculosis, and inflammatory bowel disease. The mucosal flecks could be mistaken for pseudomembranous colitis and could present a diagnostic trap because this group of patients is prone to develop this condition because of the frequent administration of antibiotics.

The diagnosis of deep mycotic infections during life is notoriously difficult²⁰ and pre-

vious reports quote detection rates of 3.5%²¹ and 25%.²² In our study antemortem microbiological investigations failed to detect intestinal fungal growth in any case. A high index of clinical suspicion is therefore needed. Endoscopic examination with biopsy specimens or brushings of lesions should theoretically yield diagnostic information. Brushings for cytology could detect *Candida* and, in some cases, *Aspergillus* organisms as both can be superficially located in the lesions. However, in those cases where *Aspergillus* organisms are present in

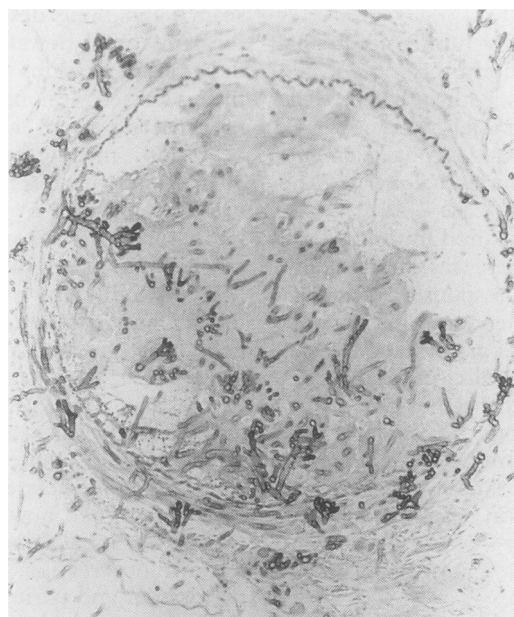


Figure 4 *Aspergillus* organisms showing angioinvasion (Grocott's methenamine silver).

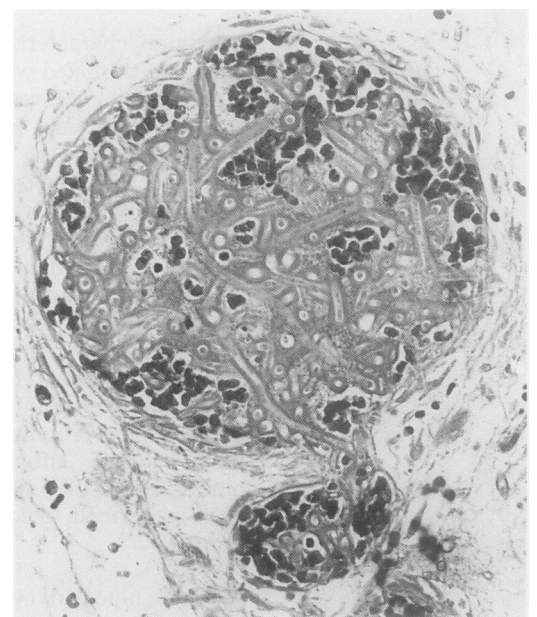


Figure 5 *Aspergillus* organisms demonstrating the Splendore-Hoeppli phenomenon. Note thickened hyphal walls produced by the deposition of immunological complexes.

deeper tissues, a biopsy specimen is more likely to be diagnostic.

In 12 cases the clinical diagnosis of sepsis was deemed contributory to death, but only in one case was a fungal agent recognised. The pathologist agreed that sepsis played a major part in the cause of death and that fungaemia was contributory in 10 cases. In case 11 fatal gastrointestinal haemorrhage was caused by an unsuspected combined *Candida* and *Aspergillus* jejunal infection.

Our findings emphasise the value of necropsy in studying such infections, and dissection of the bowel at necropsy, although unpleasant, should be carried out routinely especially in immunocompromised patients. Submitting specimens for fungal culture in suspected cases is recommended because correlation with histology and a more precise classification of the organism can be achieved. We found the use of histological special stains valuable in demonstrating the presence of fungi, particularly in the infarcted zones where necrotic debris may obscure the underlying pathology. Failure to perform these procedures will result in an underestimation of the incidence of intestinal fungal infections and hamper further study of the pathology of these infections.

- 1 Scroggs MW, Wolfe JA, Bollinger RR, *et al.* Causes of death in renal transplant recipients. A review of autopsy findings from 1966 through 1985. *Arch Pathol Lab Med* 1987;111:983-7.
- 2 Stein DK, Sugar AM. Fungal infections in the immunocom-

- promised host. *Diagn Microbiol Infect Dis* 1989;12(Suppl):221S-8S.
- 3 Brocheriou C, Badillet G, Gluckman E, *et al.* Mycotic infection in immunosuppressed patients. An anatomopathologic study. *Ann Pathol* 1990;10:99-108.
- 4 Brown AE. Overview of fungal infections in cancer patients. *Semin Oncol* 1990;17(Suppl 6):2-5.
- 5 Rotterdam H, Sommers SC. Alimentary tract biopsy lesions in the acquired immune deficiency syndrome. *Pathology* 1985;17:181-92.
- 6 Smith JMB. Mycoses of the alimentary tract. *Gut* 1969;10:1035-40.
- 7 Pedraza MA. Mycotic infections at autopsy. A comparative study of 162 cases. *Am J Clin Pathol* 1969;51:470-6.
- 8 Boon AP, O'Brien DO, Adams DH. Ten year review of invasive aspergillosis detected at necropsy. *J Clin Pathol* 1991;44:452-4.
- 9 Anthony PP. A guide to the histological identification of fungi in tissues. *J Clin Pathol* 1973;26:828-31.
- 10 Smith JH, von Lichtenberg F. The Hoeppli phenomenon in Schistosomiasis: II. Histochemistry. *Am J Pathol* 1967;50:993-1007.
- 11 Spencer H. Pulmonary aspergillosis. In: *Pathology of the Lung*. 2nd edn. New York: Pergamon Press, 1968:280-90.
- 12 Atkinson JB, Connor DH, Robinowitz M, McAllister HA, Virmani R. Cardiac fungal infections: Review of autopsy findings in 60 patients. *Hum Pathol* 1984;15:935-42.
- 13 Mangham DC, Lucas SB. Abstract: Deep fungal infections in malignant disease. *J Pathol* 1991;163:158^A.
- 14 Young RC, Bennett JE, Vogel CL, Carbone PP, DeVita VT. Aspergillosis. The spectrum of the disease in 98 patients. *Medicine (Balt)* 1970;49:147-73.
- 15 Rosen PP. Opportunistic fungal infections in patients with neoplastic diseases. *Pathol Annu* 1976;11:255-315.
- 16 Hutter RVP, Lieberman PH, Collins HS. Aspergillosis in a cancer hospital. *Cancer* 1964;17:747-56.
- 17 Case Record of the Massachusetts General Hospital No 37. *N Engl J Med* 1976;293:608-14.
- 18 Tan KK, Sugai K, Leong TK. Disseminated aspergillosis. *Am J Clin Pathol* 1966;45:697-703.
- 19 Eras P, Goldstein MJ, Sherlock P. Candida infection of the gastrointestinal tract. *Medicine* 1972;51:367-79.
- 20 Maksymiuk AW, Thongprasert S, Hopfer R, *et al.* Systemic candidiasis in cancer patients. *Am J Med* 1984;77:20-7.
- 21 DeGregorio MW, Lee WM, Linker CA, *et al.* Fungal infections in patients with acute leukaemia. *Am J Med* 1982;73:543-8.
- 22 Myerowitz RL. *The pathology of opportunistic infections with pathogenetic, diagnostic and clinical correlations*. New York: Raven Press, 1983.