

A case of striatal hemiplegia

D. R. OPPENHEIMER

From the Department of Neuropathology, Radcliffe Infirmary, Oxford

In man, pure lesions of the striatum (putamen and caudate nucleus) are rare. Diseases which affect the striatum preferentially (Huntington's chorea, Wilson's disease, encephalopathy of the Jakob-Creutzfeldt type, some forms of arterial disease) almost always involve other basal nuclei, cerebral cortex, or white matter to some extent, and the clinical picture is more or less complicated (Martin, 1959). In experimental animals, it is very difficult to achieve extensive destruction of the striatum without involving other structures, in particular the pallidum and the internal capsule.

In the case to be described here, a vascular accident in childhood resulted in a massive unilateral necrosis of the striatum, with only slight involvement of neighbouring structures. The clinical state of the patient, which remained fairly static, was described, at various times, as a pyramidal syndrome, an extra-pyramidal syndrome, and hysterical hemiplegia.

CLINICAL HISTORY

The patient was a woman aged 66 at the time of her death. Development seems to have been normal until the age of 8, when she had scarlet fever. A few months after this, she lost consciousness, and on waking up some hours later had difficulty in using the left arm and leg. There were no sensory disturbances, no abnormal movements, and no difficulty with speech. From that time onwards the left arm and leg were stiff, and walking was difficult at first. Another symptom, present from this time, consisted in recurrent spasms, unaccompanied by pain, of the left arm and leg. These occurred several times a day, and lasted for two to 30 seconds. The spasms could be provoked by mechanical or emotional stimuli, or occurred spontaneously. In the early years, the patient could move her fingers and her feet between spasms; but the distal joints had subsequently become very stiff, and she had not been able to move them for some years. There was no evident intellectual or sensory impairment, and from the time of leaving school the patient had worked as a children's nurse.

She was investigated in the National Hospital, Queen Square, at the age of 64, on account of a recent increase in stiffness of the left arm. At this time, the general examination showed nothing abnormal; intelligence and speech were normal, and there were no neurological findings in the cranial nerves or on the right side of the body. Sensation was normal on the left. The positive findings

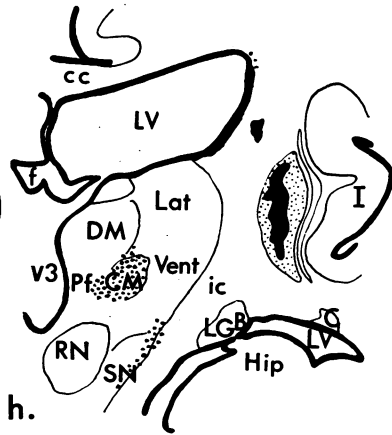
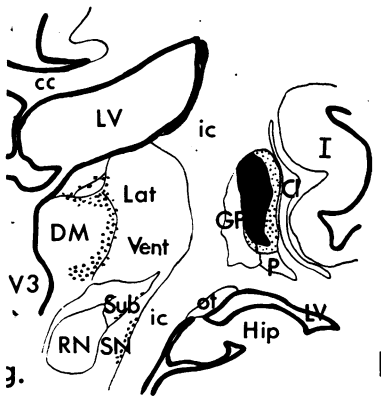
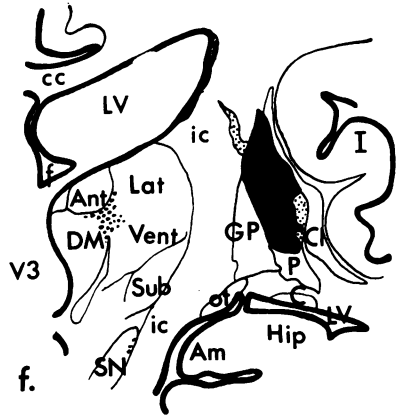
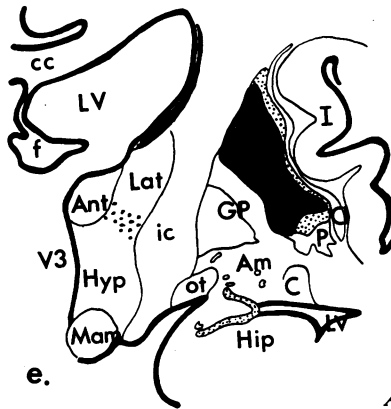
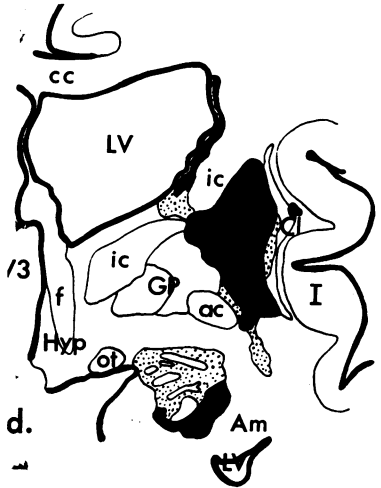
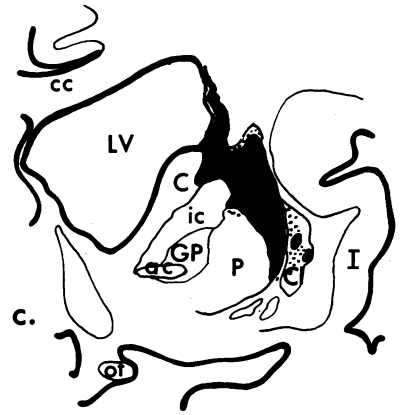
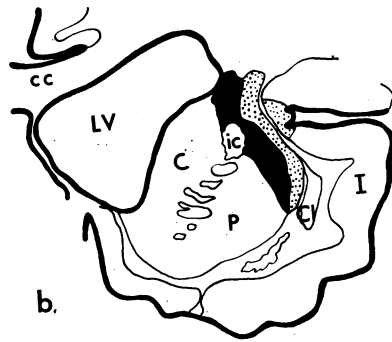
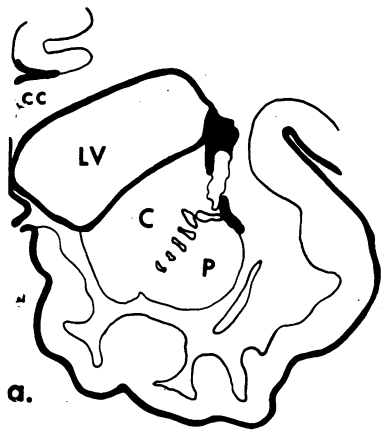
were: (1) half an inch of relative shortening of the left arm, with wasting of the fingers; (2) increased resistance to passive movement at all joints on the left and tendon reflexes were hard to elicit because of stiffness. The left plantar response was indeterminate; (3) absence of voluntary movement of the left fingers and toes and at the left ankle, the power at the more proximal joints being well preserved; (4) recurrent painless 'spasms', during which the left arm was either flexed or extended at the shoulder, the elbow was extended, the wrist dorsiflexed and the fingers flexed into a fist; (5) slight dragging of the left leg in walking; (6) a bruit heard over the right common carotid artery.

A right carotid arteriogram revealed a small angiomatous malformation, drained by an enlarged venous channel, near the origin of the posterior cerebral artery. A left carotid arteriogram was normal. Electroencephalography showed bilateral abnormalities. Surgical intervention, for treatment of the dystonia, was considered but decided against, because of the danger of haemorrhage from the angioma.

The subsequent history is not relevant to the subject of this paper. Briefly, the patient developed steatorrhoea, went into heart failure, and died suddenly, two years after her neurological investigation, from an embolus in the superior mesenteric artery.

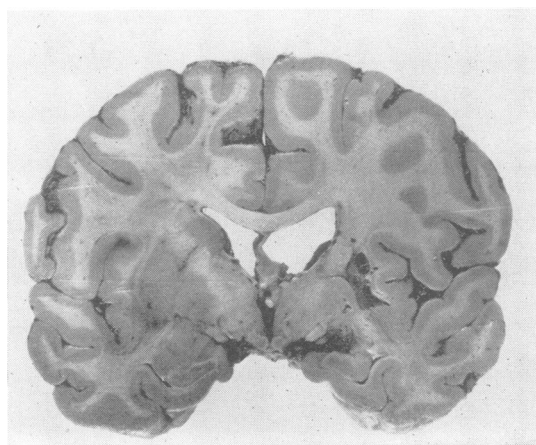

FIG. 1. *Coronal slice (level of amygdaloid nuclei), showing destruction of right putamen and caudate nucleus, and abnormal vessels in the right amygdaloid region.*



Abbreviations:

ac	Anterior commissure
Am	Amygdaloid nucleus
Ant	Anterior nucleus of thalamus
C	Caudate nucleus
cc	Corpus callosum
Cl	Clastrum
CM	Centrum medianum of thalamus
DM	Dorsomedial nucleus of thalamus
f	Fornix
GP	Globus pallidus
Hip	Hippocampus
Hyp	Hypothalamus
I	Insula
ic	Internal capsule
Lat	Lateral nucleus of thalamus
LGB	Lateral geniculate body
LV	Lateral ventricle
M	Mammillary body
ot	Optic tract
P	Putamen
Pf	Parafascicular nucleus of thalamus
RN	Red nucleus
SN	Substantia nigra
Sub	Subthalamic nucleus
Vent	Ventral nucleus of thalamus
V3	Third ventricle.

FIG. 2a-h. Camera lucida tracings from sections of the right basal nuclei, at intervals of approximately 3 mm. $\times 1.5$. Solid black; areas of tissue destruction. Stipple: areas of partial or secondary damage.

PATHOLOGY

The necropsy was performed by Dr. Gerald Manley, to whom I am indebted for the brain, at the Radcliffe Infirmary, Oxford (R.I. P.M. No. 1036/63). For the present purpose, the general post-mortem findings can be ignored.

The brain (1,265 g.) was externally normal, with healthy vessels. Coronal slices showed an old destructive lesion in the right corpus striatum, and a cluster of abnormal vessels in the right amygdaloid nucleus and in the neighbouring part of the Sylvian fissure (Fig. 1). The putamen was largely destroyed, but its anterior border was preserved. The body of the caudate nucleus, and the posterior part of the head, had disappeared, and there was compensatory dilatation of the lateral ventricle. The globus pallidus and claustrum were spared, and the internal capsule was intact except for a narrow band of destruction in the dorsal part of the anterior limb. The rest of the brain, including the brain-stem and cerebellum, appeared normal.

HISTOLOGY

Figure 2 shows the distribution of the lesions, the interval between consecutive tracings being approximately 3 mm. The vascular malformation in the amygdaloid nucleus (Fig. 2d) consists for the most part of large, thick-walled veins, with a few normal-looking small arteries. A few similarly enlarged veins are seen in the substantia innominata. Around some of these there are small accumulations of old blood pigment; otherwise there are no signs of previous haemorrhage in the meninges or in the brain.

CEREBRAL CORTEX The cortex appears to be intact, except for a small area of shrinkage and cell loss in the insula, shown in Figure 2b. Apart from this area, the insular U-fibres (capsula extrema) are preserved.

CLAUSTRUM This appears intact except for a few spots of destruction anteriorly (Fig. 2b, c, and d). The external capsule, on the other hand, is almost completely degenerate.

PUTAMEN The anterior part is largely spared (Fig. 2a, b and c). Behind this, there is almost complete destruction, with sparing of a small ventral strip. The resulting cavity contains a little spongy glial and connective tissue.

GLOBUS PALLIDUS The lesion in the putamen stops sharply at the lateral medullary lamina, and the globus pallidus is preserved. There is no obvious cell loss, even in the external segment; but there is considerable loss of myelinated fibres throughout, and a corresponding fibrous gliosis, which is also seen in the ansa lenticularis.

INTERNAL CAPSULE The band of destruction in the anterior limb is shown in Figure 2a to 2d. Much of this appears to be the result of Wallerian degeneration rather than of direct necrosis.

CAUDATE NUCLEUS The caudate head is largely preserved (Fig. 2a to 2c). The body has entirely disappeared, leaving a thin rim of subependymal glia. There is a sharp line of division between the destroyed tissue and the surviving tissue, which shows neither cell loss nor gliosis, and contains normal myelinated bundles.

THALAMUS Of the principal nuclei, only the dorso-medial and ventral nuclei show any changes. There is a band of partial cell loss and gliosis along the lateral margin of the anterior part of the dorsomedial nucleus, and a similar loss in ventralis anterior and the anterior part of ventralis lateralis. The dorsal and lateral parts of the intralaminar nuclei, including paracentralis and centralis lateralis, show almost complete cell atrophy, with heavy gliosis (Fig. 3), and most of centrum medianum,

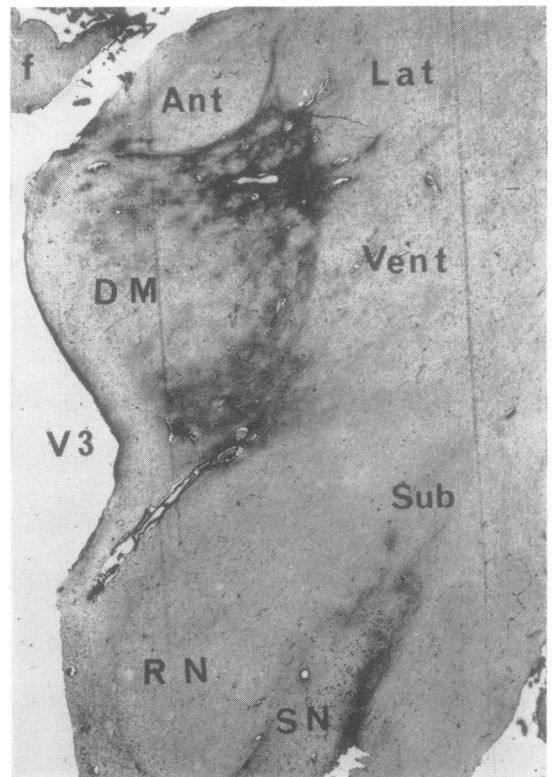


FIG. 3. Holzer preparation, showing gliosis in right thalamus. Level, and abbreviations, as in Fig. 2g \times 4.

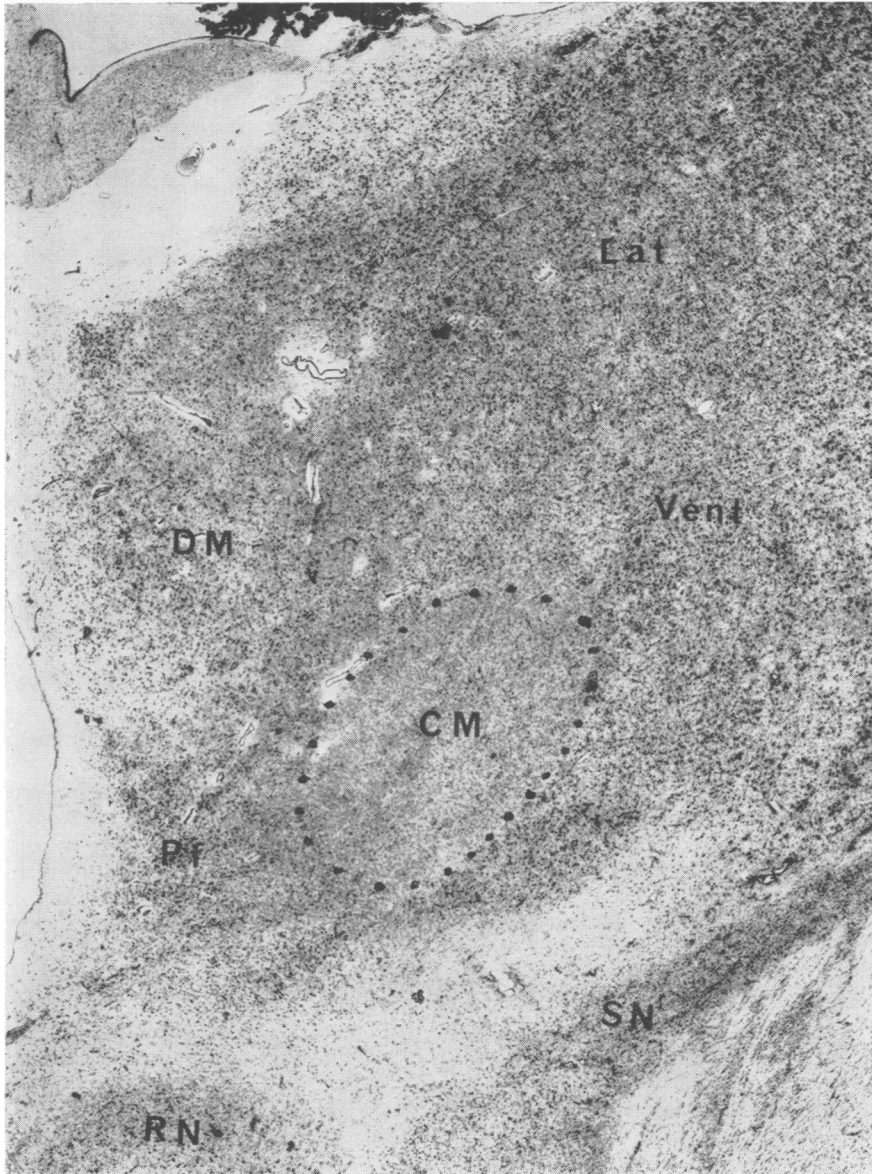


FIG. 4. Nissl preparation of right thalamus, showing cell loss in centrum medianum. Level, and abbreviations, as in Fig. 2h $\times 11$.

and the lateral half of nucleus parafascicularis, are similarly affected (Fig. 4). The medial half of parafascicularis appears normal, and some cells are preserved in the ventrolateral part of centrum medianum.

HYPOTHALAMUS All parts appear normal.

SUBTHALAMIC NUCLEUS This shows slight gliosis, but no apparent cell loss.

RED NUCLEUS This appears normal.

SUBSTANTIA NIGRA The pigmented cells are generally smaller on the right than on the left, and there is probably some cell loss in the lateral part. There is well-marked gliosis in the zona reticulata (Fig. 3).

AMYGDALOID NUCLEUS This is partially destroyed, apparently by direct pressure from the angioma. The lesion is not continuous with that in the putamen.

BRAIN-STEM AND CEREBELLUM These look entirely normal. In particular, there is no sign of wasting or myelin loss in the right pyramidal tract.

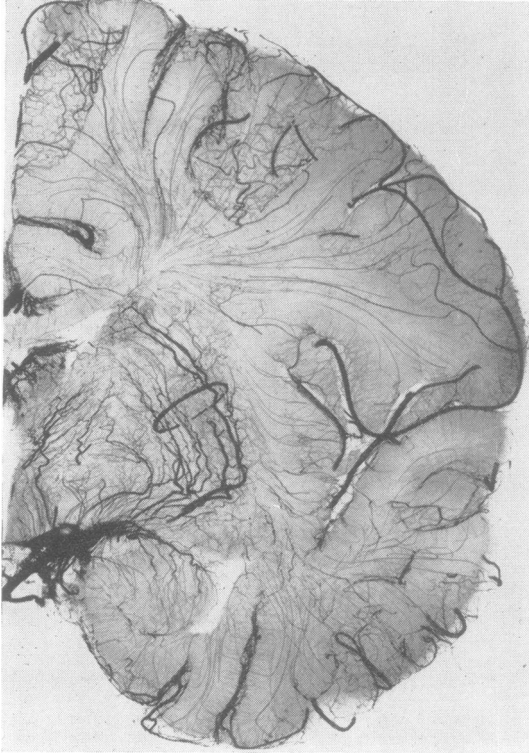


FIG. 5. Radiograph of a coronal slice, 1 cm. thick, at the level of the amygdaloid nucleus, from a normal brain after arterial injection with Micropaque. A ring has been drawn around the lateral striate group of arteries. Medial to these are branches of the anterior choroidal artery.

COMMENT ON THE PATHOLOGICAL FINDINGS

The vascular lesion in the right amygdala has the characters of an arteriovenous malformation, fed by the anterior choroidal or lateral striate arteries, or both. It is hard to be certain of the cause of the vascular accident which occurred in childhood; but the most probable explanation is a transient ischaemia in the lateral striate group of arteries, sufficient to cause necrosis of the rather vulnerable nerve cells of the putamen and caudate nucleus, but insufficient to infarct more than a small area of the internal capsule or to cause appreciable damage to the cells in the lateral segment of the globus pallidus, which is also partially supplied by these vessels. The course of the lateral striate arteries, which arise from the proximal part of the middle cerebral artery, is indicated in Figure 5. The cause of the ischaemia can only be guessed at, but could have been a small haemorrhage from the angioma, followed by constriction of neighbouring arteries.

The changes observed in the thalamus and other basal nuclei are almost certainly secondary to the striatal damage. The centrum medianum and intralaminar nuclei are generally believed (Powell and Cowan, 1956; Mehler, 1966) to project to the putamen and caudate nucleus, and undergo retrograde degeneration following striatal lesions. The minor changes in the ventral and dorsomedial nuclei are also presumably retrograde, possibly from the lesion in the anterior limb of the internal capsule. Gliosis in the pallidum and substantia nigra may be attributed to Wallerian degeneration of striato-pallidal and striato-nigral fibres (see Nauta and Mehler, 1966).

DISCUSSION

The clinical picture in this case was primarily one of rigidity. Paralysis of hand and foot movements was probably due, in part at least, to muscular rigidity, and was incomplete in the earlier period. It is a pity that more is not known of the earlier clinical state, and that we cannot now tell to what extent the final picture was affected by chronic structural changes in the affected muscles and joints. Even so, there can be little doubt that the disability was caused by a non-progressive lesion in the striatum, and that the clinical state can justly be termed 'striatal hemiplegia'.

Denny-Brown (1962) defines the striatal syndrome as 'athetosis proceeding to fixed hemiplegic dystonia'; and if we can regard the 'spasms' in the present case as being athetoid in character, this is a fair description of it. Denny-Brown draws his conclusions mainly from cases in which the striatum is damaged on both sides, and is not the only structure to be affected. As a rare instance of unilateral striatal damage, he quotes the case, examined both clinically and anatomically by Dr. Paul Yakovlev, of an epileptic whose fits dated from a hemiplegic stroke at the age of 6 and who died aged 25. Denny-Brown writes:

'Up to 10 years before death, he had exhibited a right-sided dystonia with spastic contracture of the right arm in flexion, the right leg in extension. The right hand had exhibited mobile spasm, with pronation and opening and closing of the fingers. There was severe spastic dysarthria. During the last six years of life the mobile spasm gradually lessened, the fingers of the hand remained extended in athetoid posture, the right foot plantar flexed and inverted. There was torsion of the trunk to the right. During all this last period, the plantar responses were repeatedly found to be flexor, though the tendon reflexes were brisk. The brain showed an old cystic infarction of the rostral two-thirds of the left

putamen, and about one-third of the caudate nucleus. The thalamus was greatly shrunken on the left side. The posterior half of the island of Reil and the opercular part of the superior temporal gyrus had also been destroyed.'

The anatomical damage in Denny-Brown's case appears to have been more extensive than in the present one, and to have involved the striatum more anteriorly. Involvement, if any, of the internal capsule is not mentioned. Clinically, this case had the additional features of trunk dystonia, dysarthria, and epilepsy.

As our patient was at one time thought to be suffering from a pyramidal lesion, it is worth stressing that the pyramidal tract was found to be intact. It is also worth pointing out that some of the clinical features of 'upper motor neurone' paralysis almost certainly arise not from pyramidal lesions, but from damage to other components of the motor system, including the basal ganglia and their descending pathways, which are almost invariably involved both in the usual cerebral vascular accidents and in spinal cord compression. From the evidence of Bucy, Keplinger, and Siqueira (1964) it would seem that a complete lesion of the pyramidal tract (by cerebral pedunculotomy) produces a picture very different from that of either the classical spastic hemiplegia or the rigid hemiplegia described here. After recovery from the operation, their patient was left with only slight weakness of the opposite limbs, and quickly regained useful control of fine finger movements. Reflexes were slightly brisker on the affected side, and Babinski's sign was positive, but there was no increased resistance to passive movement.

It would, of course, be an oversimplification to suppose that the clinical effect of a hemiplegic stroke is merely the sum of the effects of damage to various components of the motor system—cortex, capsule,

striatum, pallidum, and so on. We are still profoundly ignorant of the way in which these structures act and interact, and of the extent to which activity of one structure can compensate for the failure of another. The present case, in which muscular rigidity was the only clinically demonstrable effect of a massive striatal lesion, serves to emphasize the difficulty of these problems.

SUMMARY

A case is described in which a vascular accident in childhood resulted in destruction of the greater part of the putamen and caudate nucleus of one side, with minimal damage to neighbouring structures, and secondary degeneration in the thalamus and elsewhere. The clinical picture consisted of paralytic stiffness of the crossed extremities, especially of the hand and foot, with recurrent 'spasms' of the arm and leg.

Thanks are due to Dr. William Gooddy, under whose care the patient was investigated; to Dr. T. P. S. Powell for his invaluable help and advice on anatomical points; and to Mr. Ronald Beesley for the histological preparations.

REFERENCES

- Bucy, P. C., Keplinger, J. E., and Siqueira, E. B. (1964). Destruction of the 'pyramidal tract' in man. *J. Neurosurg.*, **21**, 385-398.
- Denny-Brown, D. (1962). *The Basal Ganglia* (Oxford Neurological Monographs). Oxford University Press, London.
- Martin, J. P. (1959). Remarks on the functions of the basal ganglia, *Lancet*, **1**, 999-1005.
- Mehler, W. R. (1966). Further notes on the center median nucleus of Luys. In *The Thalamus*, edited by D. P. Purpura and M. D. Yahr, pp. 109-127. Columbia University Press, New York and London.
- Nauta, W. J. H., and Mehler, W. R. (1966). Projections of the lentiform nucleus in the monkey. *Brain Research*, **1**, 3-42.
- Powell, T. P. S., and Cowan, W. M. (1956). A study of thalamo-striate relations in the monkey. *Brain*, **79**, 364-390.