

Dural arteriovenous malformations of the posterior fossa

G. C. NICOLA AND V. NIZZOLI¹

From the Department of Neurosurgery, University of Milan, Italy

In the last 10 years very few observations on dural angiomas of the posterior fossa have been published (Ciminello and Sachs, 1962; Laine, Galibert, Lopez, Delahousse, Delandtsheer, and Christiaens, 1963; Cortes, Chase, and Leeds, 1964; Van Wijngaarden and Vinken, 1966; Newton, Weidner, and Greitz, 1968). They are nevertheless sufficient to highlight the common and peculiar attributes that seem to assign to this particular malformation a relatively unique position, not only in the broad field of intracranial vascular malformations but in the more restricted one of the malformations of the posterior fossa.

Three more cases that we had recent opportunity to observe confirm these characteristic aspects.

CASE 1

G.G., a man aged 61, had always been well in the past except for a malarial infection when he was young.

Two months before coming to our observation, he complained of progressive headache in the right parietal region. The pain was so severe that he asked for admission to our hospital.

On admission the results of general examination appeared normal. The neurological examination disclosed no evident alterations, except hyposthenia of unknown origin in the right limbs. Papilloedema was present with stasis in the right eye at the fundus oculi examination. Auscultation of the cranium was negative. Laboratory examinations were completely negative. The electroencephalogram was characterized by instability of alpha rhythm and showed some slow waves at low voltage in the occipital regions, more on the right side than on the left. Radiographs of the cranium showed several vascular signs of diploic aspect in the parieto-occipital region. Ventriculography appeared normal; the ventricles were of normal size. The cerebrospinal fluid pressure was normal, as were cytological and chemical examination of the fluid. Sequential arteriographs of left carotid, right carotid, and left vertebral arteries were within normal limits. Right brachial arteriography (Fig. 1) disclosed a dural arteriovenous malformation lying in the posterior cranial fossa. The malformation

was fed by an arterial branch which originated directly from the right occipital artery, which showed an increased size.

The malformation was situated near Herophilus's torcular and drained into the straight sinus and the transverse sinus. It is noteworthy that it did not receive blood either from intracranial branches or from the carotid or vertebral tree.

Because of the patient's drowsiness, slight confusion, and disorientation, operation was performed to tie both occipital arteries and thereafter the right external carotid artery. The post-operative course was unfavourable; the patient became more confused and drowsy; hyperpyrexia and bilateral broncho-pneumonia supervened. Tracheostomy was performed and the patient was kept in an automatic respirator, but he died six days after operation. Necropsy was not performed.

COMMENT The patient had a hypertrophy of arterial branches of the external carotid artery which supplied the malformation, whereas the blood supply from the internal carotid and vertebral arteries was insignificant. Serial angiography showed rapid filling of the transverse sinus and of the right lateral sinus which appeared to be the direct drain for the malformation. This condition is very probably responsible for papilloedema due to venous hypertension at sinus level with the same mechanism that produces papilloedema in the course of venous thrombosis of cerebral sinuses and veins. In fact neither hydrocephalus nor CSF hypertension was found. One should not be surprised to find an anatomical and functional hypertrophy of the vessels deriving from the external carotid artery. The malformation was at intradural level and it is known that the dura mater is supplied by the vessels deriving from the external carotid artery. Therefore the 'sucking action' of the angioma is exerted through the territory of the external carotid artery.

CASE 2

D.L., a woman aged 52, had always been well in the past except for a slight coronary trouble from which she recovered after adequate treatment. Three months before her admission to hospital she began to complain of persistent and diffuse headache. She also had diplopia, phosphenes, tinnitus, etc. As the headache persisted, she was admitted to our Institute for cerebrovascular investigations.

¹Present address: Istituto Paolo Pini, via Ippocrate 45, 20161 Milano, Italy.

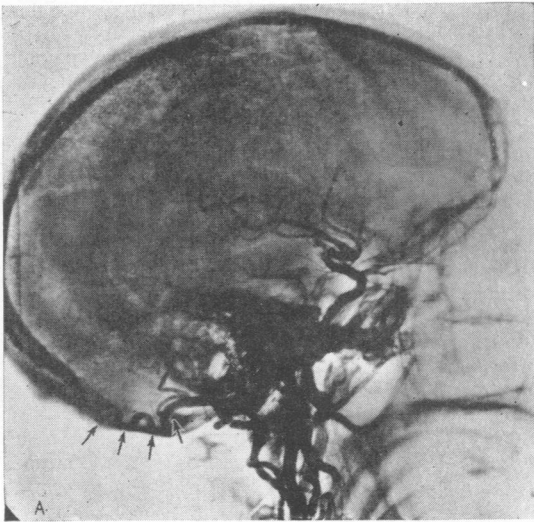


FIG 1a.

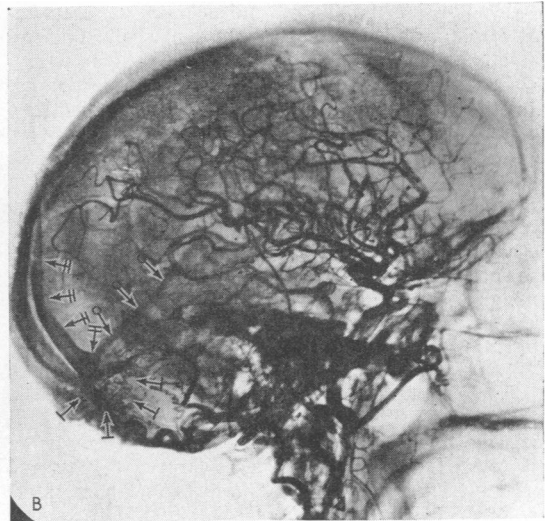


FIG. 1b.

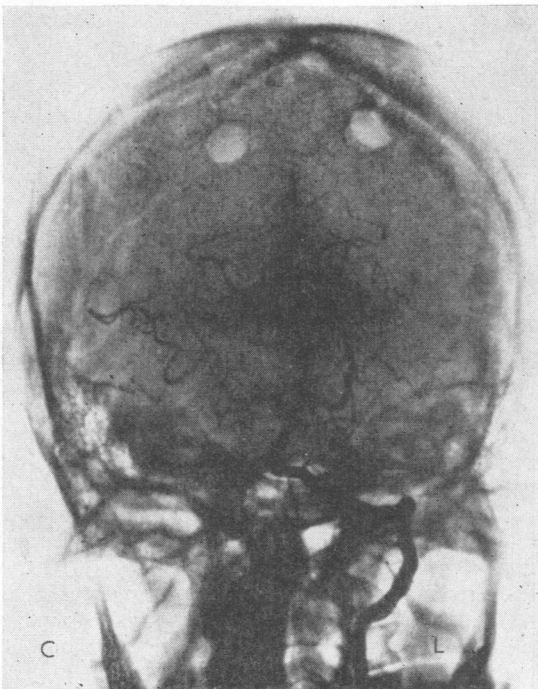


FIG. 1c.

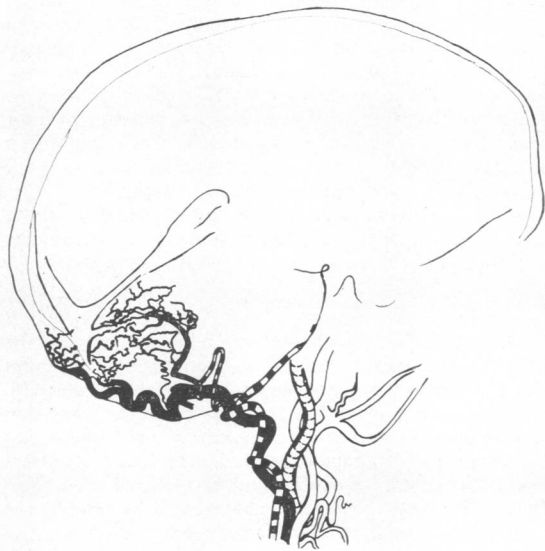

FIG. 1d.

FIG. 1. Case 1. a. Right brachial arteriogram: Lateral projection showing early opacification of enlarged occipital (→) artery feeding the dural malformation. b. Later, the angioma and straight (O→) sinus, as well as torcular and longitudinal (H→) sinus are visualized in the arterial phase. c. Few vessels from vertebral vascular tree to the angioma are opacified. d. Sketch summarizes the serial angiographic films.

On admission the general and neurological examinations were negative, except for the presence of bilateral papilloedema. Auscultation of the skull was negative.

The results of laboratory examinations were normal. The electroencephalogram showed slight irritative anomalies evident in the left fronto-temporal region. A carotidography (Fig. 2) performed on the two sides disclosed the presence of an arteriovenous aneurysm of the posterior cranial fossa supplied by an enlarged occipital artery and by a large meningeal branch deriving from the carotid siphon (Bernasconi and Cassinari's artery). The malformation was situated in the region of Herophilus's torcular and drained to the transverse sinus. The intracranial carotid circle did not seem to supply blood to the malformation.

The patient underwent an exploratory operation of the supra—and infra—occipital region by a combined surgical approach which allowed demonstration of the integrity of the occipital cortex on both sides and of the cerebellar area. Large vessels crossed the falx and tentorium, and the congested dura clearly confirmed the presence of an arteriovenous malformation. The operation was ended by ligature of the largest vessels supplying the malformation.

The patient is in excellent health many years after the operation.

COMMENT The hypertrophy of the external carotid circle and the presence of the meningeal branch deriving from the carotid siphon had directed the diagnosis pre-operatively to the intradural site of the malformation. The exploratory operation which showed the presence of a diploic angioma and the presence of large arterial venous vessels in the falx and tentorium region and the integrity of the cerebellar area and of both occipital lobes confirmed the initial hypothesis.

Papilloedema was due to venous hypertension at the level of Herophilus's torcular: in fact, the ventricular exploration did not show signs of CSF hypertension.

CASE 3

F.M.O., a woman aged 60, was admitted because for three to four years she had had confusional episodes characterized by apparent temporo-spatial disorder with an aphasic component. Four months before her admission to our Institute she had paresis of the right limbs with disturbance of language function. She had a transient slight loss of consciousness, and was treated in another hospital with satisfactory results. Nevertheless, the confusional condition did not resolve and she was therefore admitted to our Institute.

The results of a general examination were negative except for coronary trouble evidenced by the ECG. Neurological examination showed a confusional condition and severe mental decay, and receptive and expressive dysphasia. Other praxis and gnosis functions were impaired. There was paresis of the right limbs and face. Auscultation of the skull was negative. The fundus oculi were normal. The patient was unable to walk.

Routine examinations were negative, as well as those concerning the CSF. The EEG showed evidence of a left hemisphere lesion.

Left carotid and left vertebral angiography showed that the external carotid circle was of an abnormal size (Fig. 3). The occipital artery supplied a dural angioma situated in the region of Herophilus's torcular. An enlarged Bernasconi and Cassinari's artery also supplied the malformation. The circle of Willis virtually did not supply the malformation. The angioma drained into the transverse and straight sinus. There was also a leptomeningeal varicosity which constituted a large covering of all the cortex (phlebectasia?). The blood passed with abnormal speed from the arterial to the venous bed.

The patient died suddenly from a myocardial infarction. At necropsy besides the cardiac lesion there was a venous angiomatosis spread over the whole cerebral cortex. The occipital and cerebellar areas of both sides were free. It was not possible to carry out a histological examination of the dural angioma.

COMMENT In this case also hypertrophy of the arterial tree of the external carotid was evident and a large meningeal vessel deriving from the carotid siphon could be seen. Necropsy confirmed that the occipital and cerebellar areas were free from localized angiomatic malformations. This case appeared difficult to diagnose because of the concurrent presence of diffuse cerebral phlebectasia.

DISCUSSION

The cases reported present the following characteristic elements:

1. Presence of a vascular malformation in the confluent region of the venous sinuses.
 2. Preponderance of the external carotid circle and of the meningeal branches in the blood supply of the malformation.
 3. Presence in two cases of a large meningeal branch deriving from the carotid siphon and supplying the malformation (Bernasconi and Cassinari's artery).
 4. Lack of or moderate blood supply from the cortical-meningeal circle of internal carotid or vertebral branches.
 5. Presence of early filling of transverse or straight sinus which drain the malformation (arteriovenous shunt).
 6. Presence of papilloedema (in two cases) due to venous hypertension at Herophilus's torcular level, whereas there was no hypertension of cerebrospinal fluid.
- In our cases no associated or concurrent malformations of the scalp or the underlying cerebral cortex were found.

When we compare these aspects of our cases with those previously published a fairly clear picture is given which may be summarized as follows. The malformation is always situated in the region of

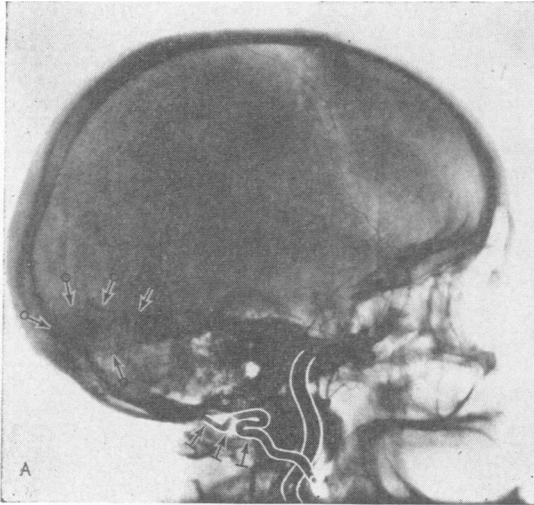


FIG. 2a.

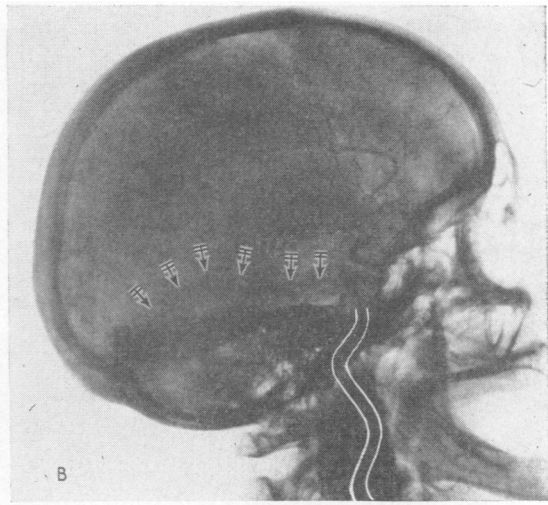


FIG. 2b.

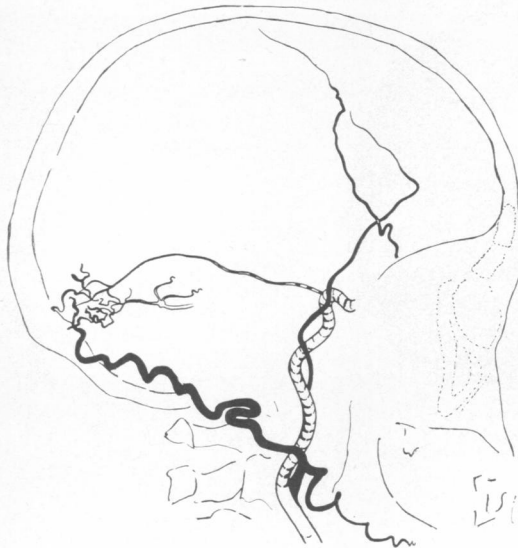


FIG. 2c.

FIG. 2. Case 2. a. Selective right external carotid angiogram showing the hypertrophied occipital (\rightarrow) artery and early visualization of the dural malformation ($\circ\rightarrow$). b. Selective right internal carotid angiogram showing early opacification of a tentorial ($H\rightarrow$) artery (of Bernasconi and Cassinari) to the angioma. c. Sketch summarizes the channels feeding the malformation.

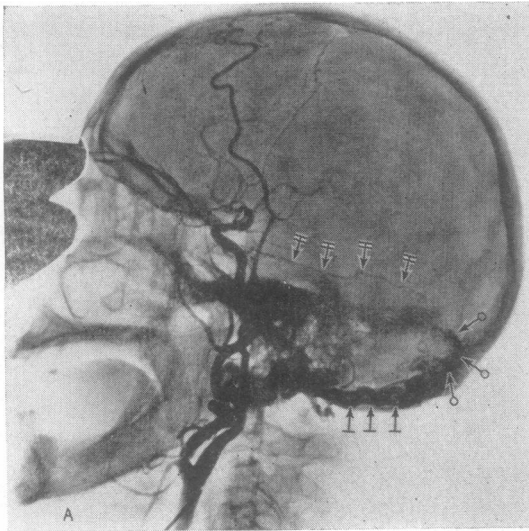


FIG. 3a.

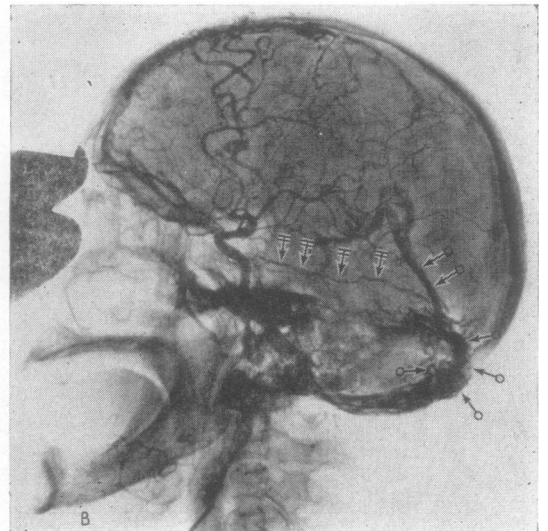


FIG. 3b.

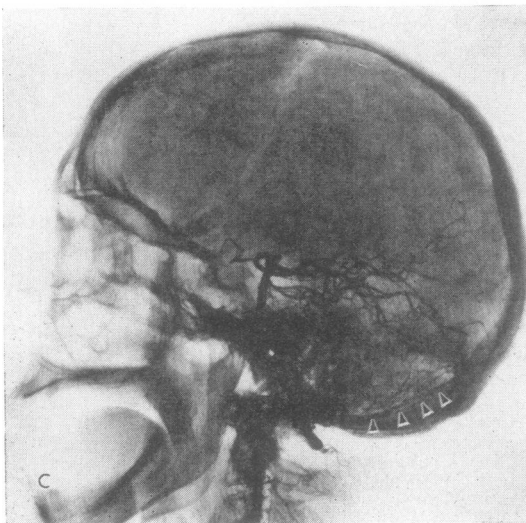


FIG. 3c.

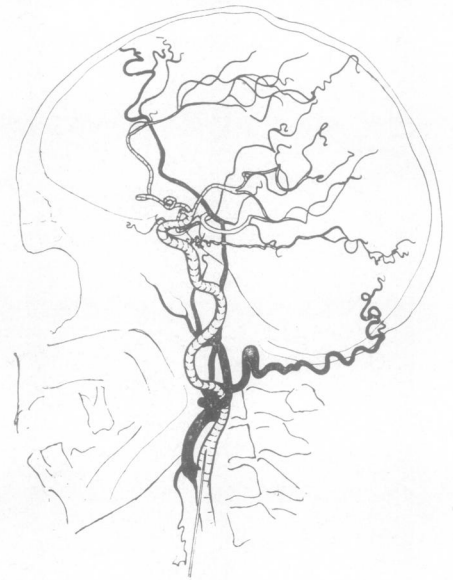

FIG. 3d.

FIG. 3. Case 3. a. Left common carotid angiogram: dural angioma (O→) fills early: the occipital (|→) artery is enlarged. b. Straight sinus (□→) is visualized in arterial phase; the artery of Bernasconi and Cassinariis early visible (H→); many branches of the external carotid artery are hypertrophied and tortuous. c. The contribution of vessels from vertebral tree to the malformation is poor; a posterior meningeal artery (▷) (from the vertebral artery)—slightly enlarged—is visible. d. Sketch summarizes the circulation along the external carotid artery.

Herophilus's torcular (Verbiest, 1951; Dilenge, David, Simon, and Morice 1964; Pecker, Bonnal, and Javelet, 1965) even if there are some additional features in other sites (Kipfer, Kaplan, and Teman, 1963). There are nevertheless no strict territorial limitations in the context either of the dura mater or of the falx or tentorium, and the few cases published in the literature possess very similar characteristics (radiological or anatomopathological). From the point of view of the blood circulation the malformation appears to be like an angiomatous stroma, generally not very extended, which effects an arteriovenous communication between the external carotid artery (especially by the occipital artery) and the transverse sinus (in most cases) or the straight sinus, or directly to the torcular or other minor venous formations, which become rapidly filled in the arteriograms. The arterial afferent channels which supply the malformation are mostly derived from the external carotid system (often occipital artery, posterior meningeal artery or vessels which normally vascularize the dura mater). On this account it is interesting to note that in two of our patients the arterial branch described by Bernasconi and Cassinari (1956), which supplies blood from the carotid siphon to the tentorium and which normally is rarely outlined, was hypertrophic and well visualized. On the other hand there is total or partial absence of arterial supply to the malformation from the internal carotid system or the vertebral artery (except for the artery of Bernasconi and Cassinari). For these reasons one can understand how the malformation may be missed at arteriographic investigation if the external carotid system does not fill.

From a clinical point of view it is interesting to note that our cases, though few, permit recognition of two types of onset and course of the syndrome: (1) the malformation presents with the typical clinical form of subarachnoid haemorrhage; (2) it is characterized by a pseudo-tumour symptomatology—for instance, the papilloedema—which usually occurs in old age and is not associated with subarachnoid haemorrhage. In these cases, therefore, there is no anatomical predisposition to vascular rupture and the malformation leads only to increased venous pressure due to the direct arterial affluents into the venous sinuses. This distinction is confirmed by the large and recent series of Newton *et al.* (1968).

Failure of arteriographic visualization and the pseudo-tumour aspects of the syndrome may cause diagnostic error because there are not

sufficient clinical characteristics in the cases that can be classified as above to permit diagnosis.

The pathogenesis is part of the general problem of vascular malformation.

Nevertheless, some points seem peculiar to these malformations—namely: (1) these malformations are entirely intradural or there are mixed forms; (2) the different signs observed—haemorrhagic, pseudo-tumoural, unclassifiable forms—have a different anatomical substratum; (3) the origin of these malformations is related, as in Laine's opinion, to embryogenic causes which are not yet sufficiently known. The dural arteriovenous malformations undoubtedly have a distinct anatomoclinical picture which needs further study.

SUMMARY

Dural arteriovenous malformation in the posterior fossa represents a rare but specific clinical entity. Three patients in whom the malformation was not recognized clinically are presented.

The clinical picture is discussed and the importance of angiographic study of the brain or of the afferent vessels to it is stressed for an exact evaluation of the lesion.

We are indebted to Dr. M. Parma (University of Parma, Italy) and to Dr. T. H. Newton (University of California, San Francisco, U.S.A.) for their criticisms of this paper. Dr. Newton revised the manuscript.

REFERENCES

(A bibliography is available on request.)

- Bernasconi, V., and Cassinari, V. (1956). Un segno carotidografico tipico di meningioma del tentorio. *Chirurgia (Milan)*, **11**, 586-588.
- Ciminello, V. J., and Sachs, E. Jr. (1962). Arteriovenous malformations of the posterior fossa. *J. Neurosurg.*, **19**, 602-604.
- Cortes, O., Chase, N. E., and Leeds, N. (1964). Visualization of tentorial branches of the internal carotid artery in intracranial lesions other than meningiomas. *Radiology*, **82**, 1024-1028.
- Dilenge, D., David, M., Simon, J., and Morice, J. (1964). Valeur sémiologique des branches méningées de l'artère carotide interne et de l'artère vertébrale. *Neuro-chirurgie*, **10**, 265-274.
- Kipfer, M., Kaplan, J., and Teman, R. (1963). A propos de deux cas d'angiome de la dure-mère. *Gaz. med. Fr.*, **70**, 1981-1984.
- Laine, E., Galibert, P., Lopez, C., Delahousse, J., Delandtsheer, J. M., and Christiaens, J. L. (1963). Anévrysmes artérioveineux intradurales (développés dans l'épaisseur de la dure-mère) de la fosse postérieure. *Neuro-chirurgie*, **9**, 147-159.
- Newton, T. H., Weidner, W., and Greitz, T. (1968). Dural arteriovenous malformation in the posterior fossa. *Radiology*, **90**, 27-35.
- Pecker, J., Bonnal, J., and Javelet, A. (1965). Deux nouveaux cas d'anévrysmes artérioveineux intradurales de la fosse postérieure alimentés par la carotide externe. *Neuro-chirurgie*, **11**, 327-332.
- Van Wijngaarden, G. K., and Vinken, P. J. (1966). A case of intradural arteriovenous aneurysm of the posterior fossa. *Neurology (Minneapolis)*, **16**, 754-756.
- Verbiest, M. H. (1951). L'anévrysmes artérioveineux intradural. *Rev. neurol.*, **85**, 189-199.