

The intramuscular nerve action potential

L. GUTMANN

From the Department of Neurology, West Virginia University, Morgantown, West Virginia, U.S.A.

The muscle action potential (MAP) evoked by nerve stimulation is often preceded by a small negative wave which has been interpreted to represent a nerve action potential (NAP) (Simpson, 1964; Buchthal and Rosenfalck, 1966). This potential is seen only at high gain amplification. When recording at such a gain it may be misinterpreted as representing the initial deflection of the evoked muscle action potential.

The origin of this initial negative potential has not been completely delineated, although Buchthal and Rosenfalck (1966), using concentric recording electrodes, suggested that it was derived from motor axons. This paper describes the intramuscular NAP in normal nerves and nerves in which there has been a selective loss of motor axons.

MATERIAL AND METHODS

Nerve stimulation was performed percutaneously using a Grass S4 stimulator. The evoked muscle action potential was recorded using surface disc electrodes. The recording electrode was placed over the motor point of the muscle and the reference electrode over the tendon. The potentials were amplified and displayed using Tektronix amplifier type 3A74, differential amplifier type 2A61, time base type 2B67, and cathode ray oscilloscope type 561A. Data were recorded on Kodak TRI-X-Pan 35 mm film.

Motor conduction velocities were determined for the segment of the nerve between elbow and wrist (the sites of stimulation). MAP was recorded from thenar muscles when stimulating the median nerve. Distal sensory latencies were determined by stimulating the second finger and recording from the median nerve at the wrist. The distal sensory latency was measured from the onset of the shock artefact to the peak of the NAP. The latency of the intramuscular NAP and MAP was measured from the onset of the shock artefact to the initial negative deflection of the action potential. Latencies reported are the mean of at least six sample recordings.

Four patients were studied as part of this report. Case 1 (R.N.; WVUH No. 17-83-79) and case 2 (D.G.; WVUH No. 18-18-60) both had complete unilateral brachial plexus root avulsions of roots C5 through T1. This diagnosis was confirmed by the presence of complete paralysis and anaesthesia of the left upper extremity in each case in C5 to T1 distribution. In addition, they showed typical electromyographic and myelographic

findings (Warren, Gutmann, Figueroa, and Bloor, 1969). In both patients, the results of the median nerve studies performed several months after injury in the involved and the normal extremities are reported.

Case 3 (O.J.; WVUH No. 12-13-02) and case 4 (C.S.; WVUH No. 18-31-35) both had amyotrophic lateral sclerosis. This diagnosis was based on typical clinical and electromyographic findings in each case. The studies to be reported in both patients were carried out in median nerves in which a very small MAP was evoked and marked atrophy was present in the thenar muscles.

RESULTS

In both patients with brachial plexus root avulsions, stimulation of the median nerve in the involved extremity failed to evoke a MAP. In each case, however, a small intramuscular NAP was recorded from the thenar muscles when the nerve was stimulated at either the wrist or elbow (Fig. 1). In patient 1 (R.N.) stimulation of the median nerve at the wrist evoked a potential which had a mean latency of

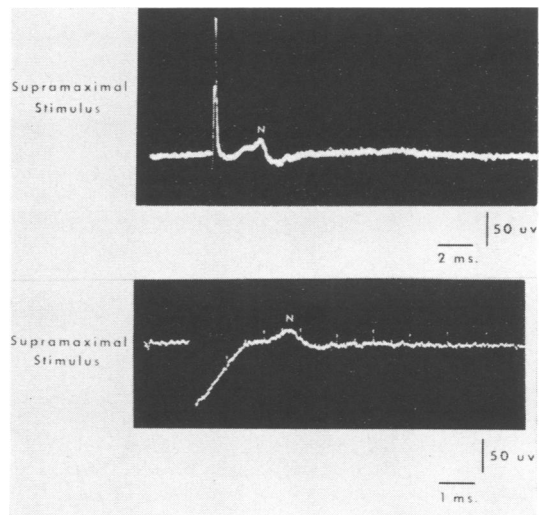


FIG. 1. (Top) case 1 (R.N.) left median nerve. (Bottom) case 2 (D.G.) left median nerve. Intramuscular NAP (N) in presence of brachial plexus root avulsion.

2.1 ms over a distance of 10.4 cm and mean amplitude of $24 \mu\text{V}$. In patient 2 (D.G.) the potential had a mean latency of 2.1 ms over a distance of 7.6 cm and an amplitude of $16 \mu\text{V}$.

In the normal extremity of each patient the median nerve motor and sensory conduction studies were normal. The motor conduction velocity and amplitude of evoked MAP was 56.1 m/sec and 13.8 mV respectively in patient 1 (R.N.) and 54.3 m/sec and 11.5 mV respectively in patient 2 (D.G.). In each case subliminal stimulation of the median nerve could evoke the intramuscular NAP without a subsequent MAP. In these circumstances the mean amplitude was $16 \mu\text{V}$ in case 1 and $13 \mu\text{V}$ in case 2. As the strength of the stimulus was increased an evoked MAP appeared. At supramaximal stimulation the amplitude of the intramuscular NAP was $36 \mu\text{V}$ in case 1 (Fig. 2) and $39 \mu\text{V}$ in case 2 (Fig. 3). The mean latency of the intramuscular NAP in case 1 was 1.5 ms for a distance of 6.9 cm, and in case 2 was 1.9 ms for a distance of 5.7 cm.

In the two patients with amyotrophic lateral sclerosis (cases 3 and 4) the evoked MAP was small ($90 \mu\text{V}$ and $80 \mu\text{V}$ respectively) on median nerve stimulation and this was related to the marked loss of motor neurones and the resultant muscular atrophy. Motor conduction velocities were slow (39 m/sec and 28 m/sec respectively). This was felt

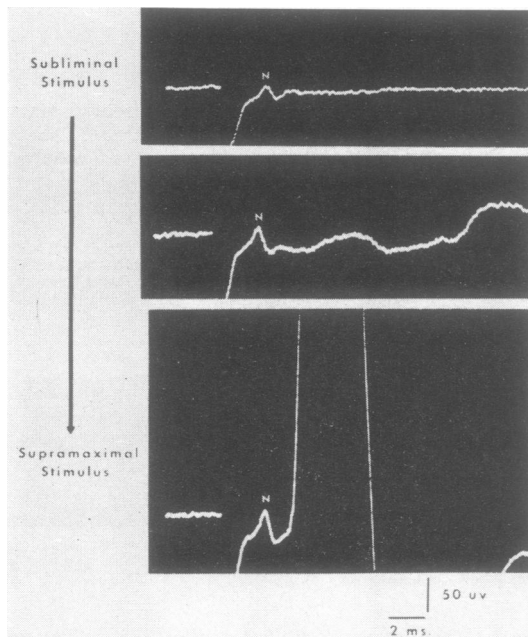


FIG. 2. Case 1 (R.N.) right median nerve. Intramuscular NAP (N) and MAP in normal nerve.

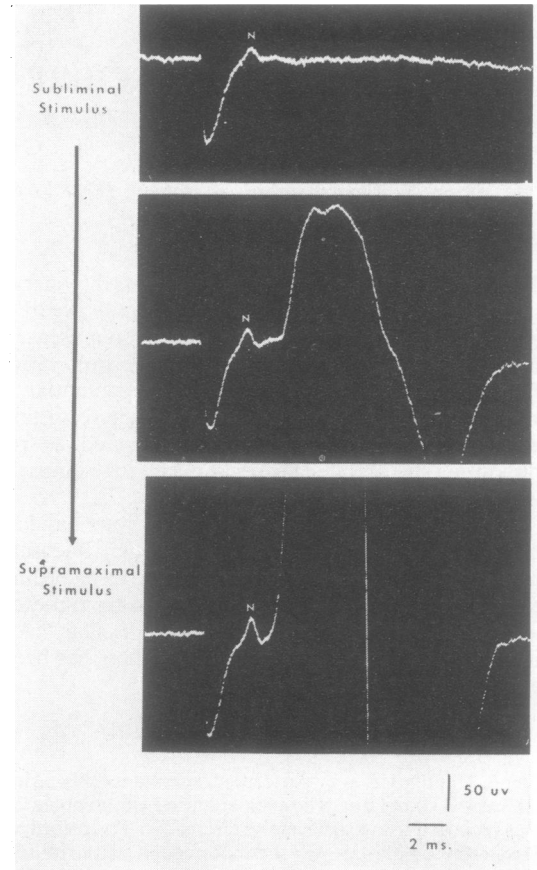


FIG. 3. Case 2 (D.G.) right median nerve. Intramuscular NAP (N) and MAP in normal nerve.

to reflect primarily loss of the fastest conducting axons rather than a neuropathy, since distal sensory latencies were still within the normal range (Table I).

TABLE I
MEDIAN NERVE CONDUCTION STUDIES

Case no.	Motor conduction velocity (m/sec)	Amplitude MAP (mV)	Distal sensory latency (ms)	Distance (cm)	Amplitude sensory NAP (μV)
Brachial plexus root avulsion					
1 (left median)	—	—	2.8	13.2	10
2 (left median)	—	—	3.1	13.0	16
ALS					
3 (right median)	39.0	0.09	3.3	13.0	14
4 (left median)	28.0	0.08	3.5	13.0	16
Normal					
1 (right median)	56.1	13.8	3.0	13.2	20
3 (right median)	54.3	11.5	3.1	13.2	26

The mean latency of the intramuscular NAP and MAP (supramaximal stimulation) was 2.6 ms and 7.6 ms respectively over a distance of 9.0 cm in case 3 (O.J.) and 2.1 ms and 7.3 ms respectively over a distance of 9.0 cm in case 4 (C.S.). The intramuscular NAP could be evoked in each case with subliminal stimulation which failed to evoke the muscle action potential. In these circumstances the mean amplitude of the intramuscular NAP was 17 μ V in case 3 and 14 μ V in case 4. With supramaximal median nerve stimulation the mean amplitude of the intramuscular NAP was slightly larger—20 μ V in case 3 and 18 μ V in case 4 (Fig. 4).

DISCUSSION

The results of these studies indicate that a significant portion of the intramuscular NAP preceding the evoked MAP is derived from sensory axons conducting antidromically. This is based on four lines of evidence.

1. The intramuscular NAP persists without a subsequent MAP in the situation where there is complete degeneration of motor axons and preservation of sensory axons (brachial plexus root avulsion).

2. In the situation of the small MAP due to muscular atrophy of motor neurone disease, the

intramuscular NAP is much larger than would be anticipated if only motor axons contributed to this potential. In the normal median nerves of cases 1 and 2 the ratio of the amplitude of the NAP to MAP (NAP : MAP) was 1 : 380 and 1 : 300 respectively on supramaximal stimulation (Tables I and II). In cases 3 and 4 this ratio was 1 : 4.5 and 1 : 4.4 respectively, indicating that the intramuscular NAP was approximately 75 times larger than would be anticipated were motor axons the sole contributors to this potential.

TABLE II
INTRAMUSCULAR NAP

Case no.	Amplitude NAP (μ V)				Distance (cm)
	Subliminal* stimulation	Supramaximal stimulation	Distal latency NAP (ms)	Distal latency MAP (ms)	
Brachial plexus root avulsion					
1 (left median)	—	24	2.1	—	10.4
2 (left median)	—	16	2.1	—	7.6
ALS					
3 (right median)	17	20	2.6	7.6	9.0
4 (left median)	14	18	2.1	7.3	9.0
Normal					
1 (right median)	16	36	1.5	2.9	6.9
2 (right median)	13	39	1.9	3.1	5.7

*Strength of nerve stimulation which evokes an intramuscular NAP but just fails to evoke a MAP.

3. Subliminal stimulation of nerve will evoke the intramuscular NAP at a threshold below that needed to evoke the MAP. This was the case in the two normal median nerves reported in cases 1 and 2 and in the two median nerves reported in cases 3 and 4. This would further suggest that the intramuscular NAP is derived from Group I sensory axons which have the greatest diameter and the lowest threshold.

4. The difference between the onset of the intramuscular NAP and MAP was 5.2 ms in both cases 3 and 4. This is quite prolonged compared with 1.4 ms and 1.2 ms respectively in the normal median nerves of cases 1 and 2. The long delay in the appearance of the small MAP probably reflects the loss of the fastest conducting motor axons. This delay suggests that the intramuscular NAP is not derived from motor axons.

In both normal median nerves of cases 1 and 2 the amplitude of the intramuscular NAP is significantly larger when the stimulus is supramaximal for the MAP as compared with when the MAP just first appears (Table II). This increase in amplitude could be derived from either motor or sensory axons with higher thresholds. In cases 3 and 4 only a slight increase in the amplitude of the intramuscular NAP

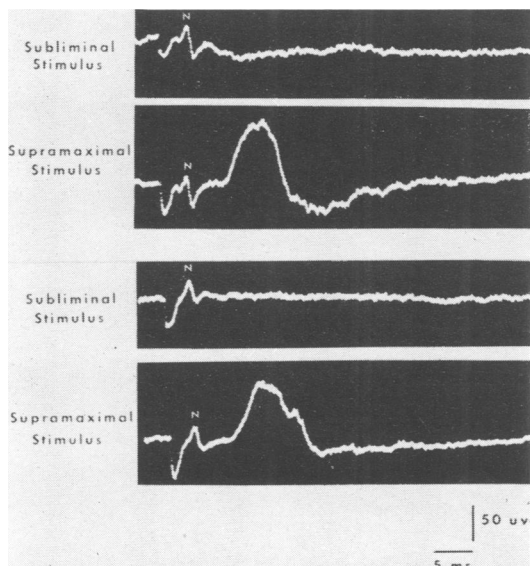


FIG. 4. (Top) case 3 (O.J.) right median nerve. (Bottom) case 4 (C.S.) left median nerve. Intramuscular NAP (N) and MAP in presence of severe muscular atrophy due to amyotrophic lateral sclerosis.

occurred in the same circumstances. This suggests that the much greater increase in the amplitude of the intramuscular NAP of the normal median nerves is derived from motor axons.

These results and conclusions are different from those of Buchthal and Rosenfalck (1966) who, in studying normal nerves, favoured the possibility that the intramuscular NAP was derived from motor axons. This may well reflect a difference in technique. Buchthal and Rosenfalck (1966) carried out their studies using concentric needle recording electrodes. The present study utilized surface disc electrodes which record from a larger area.

SUMMARY

The initial intramuscular NAP which precedes the MAP in conduction studies was studied in normal median nerves and in median nerves in which there has been a selective loss of motor axons (brachial

plexus root avulsion and amyotrophic lateral sclerosis). The results indicate that a major portion of this intramuscular NAP is derived from sensory axons conducting antidromically. Motor axons may also make a contribution. The fact that this NAP may occur without a subsequent MAP in certain clinical states indicates the need to be aware of the significance of this potential so that it will not be misinterpreted as reflecting intact motor axons.

Margaret Blosser provided technical assistance.

REFERENCES

- Buchthal, F., and Rosenfalck, A. (1966). The intramuscular nerve action potential. *Brain Res.*, **3**, 72-73.
- Simpson, J. A. (1964). Fact and fallacy in measurement of conduction velocity in motor nerves. *J. Neurol. Neurosurg. Psychiat.*, **27**, 381-385.
- Warren, J., Gutmann, L., Figueroa, A. F., and Bloor, B. M. (1969). Electromyographic changes of brachial plexus root avulsions. *J. Neurosurg.*, in press.