

Atresia of the lateral ventricle

RALPH B. CLOWARD¹

From Honolulu, Hawaii

Large fluid-filled intracranial cavities which displace or replace the brain are often misdiagnosed as neoplasms. The lesions include extracerebral cysts (arachnoidal) and the intracerebral cavities (porencephaly, unilateral, and localized hydrocephalus).

The most frequently encountered lesion is the leptomeningeal or cerebral arachnoidal cyst, first described by the renowned physician, Richard Bright, in 1831 (Locksley and Afifi, 1964). These lesions occur most frequently in children, causing head growth, sutural widening, vomiting, and convulsions, which lead to investigation for hydrocephalus or neoplasm. The cyst does not communicate with the ventricle or with the subarachnoid space and is not associated with cerebral loss as in porencephaly.

Cavities within the brain substance (porencephaly) may be congenital or acquired (LeCount and Semerak, 1925). They always communicate either with the ventricle or the subarachnoid space and are, therefore, demonstrated by pneumoencephalography. The congenital lesions are thought to result from hypoplasia, agenesis or germ-plasm defect (Cohn and Neumann, 1946). Acquired intracerebral cavities follow brain trauma (birth), causing intracerebral haemorrhage or cerebral infarction from embolism of a major cerebral vessel, or from trauma with direct loss of brain substance. Cavities remain after removal of a neoplasm, radiation of a radio-sensitive tumour, and after encephalitis (Pendergrass and Perryman, 1946).

Unilateral ventricular dilatation may be interpreted as an intracerebral cystic cavity. It can be obstructive or non-obstructive. Only a dozen or so non-obstructive cases have been described. These are due to unilateral cortical agenesis with hydrocephalus *ex vacuo*, or following intrauterine encephalitis causing temporary closure of the foramen of Monro. Obstructive unilateral hydrocephalus from occlusion of the foramen of Monro by neoplasm is a common condition.

The following case is reported because an enormous intracranial fluid-filled cavity was demonstrated which did not fit any of the above-described clinical entities.

¹Present address: 388 Alexander Young Building, Honolulu, Hawaii 96813.

CASE REPORT

T.C., an 8-year-old boy, had had convulsions since 5 weeks of age. There was a history of birth injury; he was delivered with forceps and the mother recalled a large bruise on the right side of his head. The seizures, probably of traumatic origin, continued at infrequent intervals. When he was 7 the parents noted a progressive enlargement of the right side of the head. He was examined by a neurosurgeon who operated and informed the mother that he found a cyst which he drained and 'that was all that could be done'. The boy continued to have petit mal attacks, with an occasional major seizure. He occasionally complained of headache, and numbness of the left arm and leg and he insisted that he could not see with the left eye. He did average school work in the second grade. The mother observed that he was 'small for his age' being not much larger than his 5-year-old sister.

EXAMINATION He was a bright, alert, intelligent child, weight 54 lb. (24.5 kg), height 45½ in. (115.6 cm) which was 3½ in. (9 cm) below normal for an 8-year-old male. The head measured 54 cm with marked asymmetry due to pronounced bulge in the right inferior temporal region (Fig. 1A). There was a 4 cm vertical scar over the bulge, but no palpable cranial defect.

NEUROLOGICAL EXAMINATION There was mild right exophthalmos. The right eye was displaced forward and downward. He was partially blind in this eye, vision being limited to finger counting at 5 ft (1.5 m). He could read with the left eye. There was marked horizontal nystagmus on left lateral gaze and the right eye turned upward. There was no nystagmus on looking to the right, but the right eye rotated downward (Fig. 1A). Ophthalmoscopic examination showed fine spontaneous horizontal nystagmus to the left. The right optic disc was pale yellow, indistinct, and the nasal half elevated one dioptre; retinal vessels were increased in number, tortuous, and enlarged. The left disc was flat, pink, and vessels normal. Visual fields were full and other cranial nerves normal. Strength and coordination of extremities were symmetrical except for a slightly diminished left arm swing in walking. Heart, lungs, and genitals were normal.

Radiographs of the skull showed marked asymmetry, the right half being larger with localized outward projection and thinning of the temporal bone. The orbit was depressed, accounting for the unilateral exophthalmos. The right sphenoidal ridge was also depressed

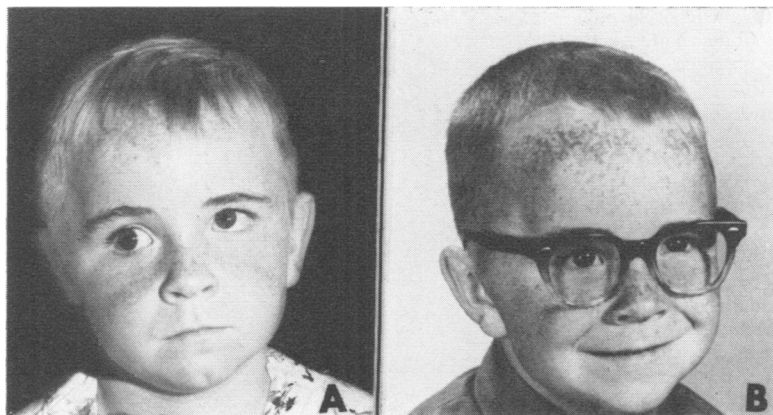


FIG. 1. A. The patient, aged 8, showing asymmetry of skull, exophthalmos, and skew deviation of eyes. B. At 9½ years, post-operative appearance.

with marked deepening of the middle fossa. There was evidence of long-standing pressure with separated sutures (Fig. 2). Radiographic studies of long bones indicated bone age at 4 years according to Greulich and Pyle (*Atlas of Skeletal Development*).

FIRST PNEUMOENCEPHALOGRAPH (Q.H. no. 303104) This was carried out on 11 August 1966. Initial spinal fluid pressure in the upright position rose 100 cm above the cisterna magna. All spinal fluid was removed (only 75 ml.) and replaced with sterile oxygen (100 ml.). Radiographs disclosed no gas in the right lateral ventricle, the left was dilated, and the third ventricle shifted 8 mm to the left. As a large subarachnoid cyst or a unilateral hydrocephalus was suspected, a needle was inserted through a twist drill hole in the right temporal bone one week later. Sixty-five millilitres of clear, colourless CSF was removed and replaced with air. Radiography (Fig. 2) disclosed a large cavity measuring 10 cm in

diameter occupying the temporal and occipital regions which apparently did not communicate with the ventricular system. A diagnosis of arachnoid cyst was made.

FIRST OPERATION On 23 August 1966, a large scalp flap was raised exposing a single trephine opening, as the cranial defect of the previous 'exploratory' operation. The bulging, paper-thin temporal bone was removed and dura opened. There was no cyst in the subdural or subarachnoid space. The exposed cerebral cortex was pale and smooth. It was incised and found to be only 2 to 4 mm in thickness anteriorly, increasing posteriorly and medially. The fluid was evacuated, exposing an enormous cavity identified as the ventricle by the choroid plexus. The cavity was thought to be a dilatation of the entire lateral ventricle, and the pathology, an obstruction of the foramen of Monro.

An area was chosen in the medial anterior floor of

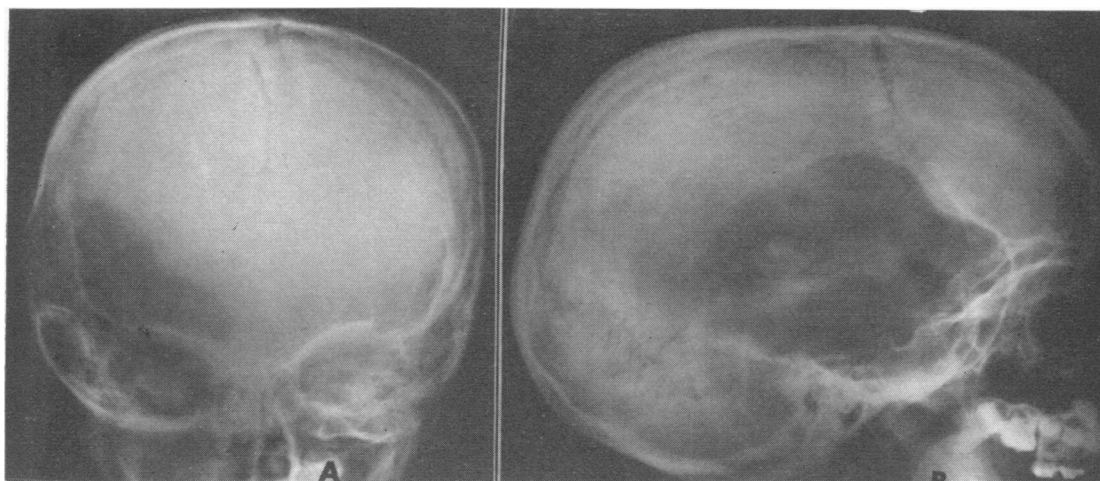


FIG. 2. 'Cystic' cavity partially filled with 65 ml. of air injected through thin temporal bone. Cavity occupies inferior temporal and occipital region. Note deformity of skull, right orbit, sphenoid, and temporal bones.

the cavity where the foramen was thought to be located and a small opening made in the white matter with cautery and suction until CSF was obtained. A silver clip was applied as a marker (Fig. 3a). The dura was closed, water tight, and a tantalum plate inserted to cover the cranial defect. Post-operative radiographs showed the silver clip located posterior and inferior to the normal position of the foramen of Monro indicating that no intraventricular communication had been established.

The patient was discharged from hospital on 4 September 1966, but readmitted six weeks later because of several major seizures, usually preceded by complaints of headache and vomiting. He exhibited over-active behaviour, talked constantly, and was reported to be doing poorly in school because of short attention span. Examination showed a right VI nerve palsy and increased elevation of the right optic disc.

SECOND PNEUMOENCEPHALOGRAM (Q.H. no. 308712) This was performed on 25 November 1966. Spinal fluid pressure was again increased markedly. A complete exchange of fluid for air (90 ml. vs 100 ml.) was made. Anteroposterior radiographs showed the frontal region of both ventricles to be well filled and markedly shifted to the left (Fig. 3A). The large 'cyst' on the right contained no air. The 'cyst' was tapped by passing a needle through a hole in his tantalum plate; 80 ml. of fluid was then removed and replaced with air. The radiograph showed the previously displaced ventricles in normal position following evacuation, and release of pressure within the 'cyst'. The gas-filled lesion demonstrated its relationship with the ventricular system (Fig. 3B).

It was apparent from the radiographic studies and findings at operation that the large cavity represented a condition in which the posterior parts of the right lateral ventricle were isolated from the frontal horn and the

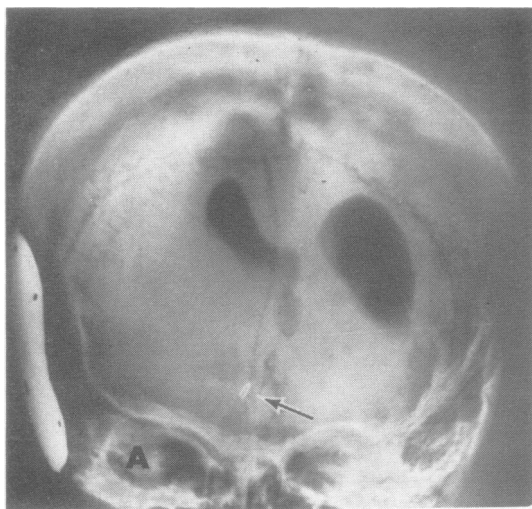


FIG. 3A.

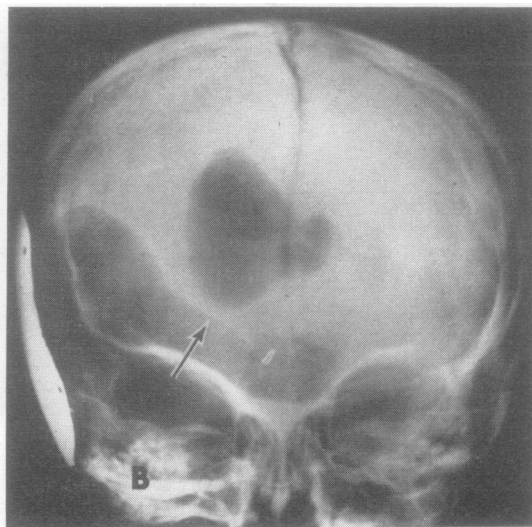


FIG. 3B.

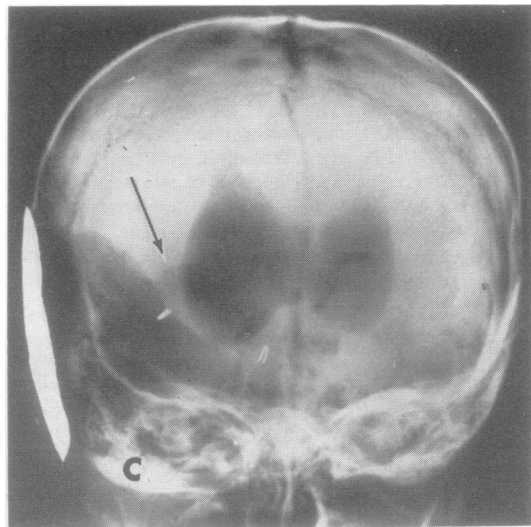


FIG. 3C.

FIG. 3. A. Second pneumoencephalogram. Both frontal horns filled, markedly shifted to left. Silver clip marks site of attempted surgical communication.

B. After evacuation of 'cyst' ventricular system assumes normal position. (Arrow: 'thin membrane' between 'cyst and ventricle—see Handa and Bucy's case).

C. Post-operative interventricular communication (second silver clip—arrow) between enlarged temporal and frontal horns.

foramen of Monro, probably by an atresia of the body of the ventricle (Fig. 4). It could not be determined whether the lesion was congenital or acquired. The treatment required was to establish communication between the enlarged part of the ventricle and the frontal horn.

SECOND OPERATION (Q.H. no. 309407) On 8 December 1966 the wound was reopened, the huge cavity emptied of fluid and re-explored; the choroid plexus curved around the neural structures in the posterior and inferior region of the cavity, but the landmarks could not be

identified. The cavity appeared to extend to the tentorium (Fig. 2b). Its size, determined by filling it with measured saline solution, was 236 ml.

A needle was passed through the medial wall anteriorly and fluid recovered from the frontal horn. The needle tract was enlarged with cauterization and suction to 1 cm in diameter and 2 cm deep, creating an ample communication. All visible choroid plexus was blanched and destroyed with the cauterization. A small dural graft was required for a water-tight closure and the tantalum plate replaced.

THIRD PNEUMOENCEPHALOGRAPHY (Q.H. no. 311476) This was done on 18 January 1967 before his discharge from hospital. After 200 ml. of spinal fluid had been exchanged for oxygen, the radiographs demonstrated the communication to be functioning, the ventricular system including the entire right ventricle being well visualized (Fig. 3c).

In February 1967, the family moved to Alabama where the patient was followed up by Dr. Exum Walker of Atlanta, Georgia. In August 1967 the mother reported absence of seizures, improvement in learning, he had grown $2\frac{1}{2}$ in. (6.3 cm) taller and his bone-age showed 6 years (the patient now being $9\frac{1}{2}$ years old). He still has all his baby teeth. Except for slight elevation of one edge of the tantalum plate he was doing well and presumably cured of his cerebral lesion.

FOLLOW-UP In November 1968, the patient was operated on again, by Dr. Walker, to replace the thin tantalum plate which had become detached from the skull. The pneumoencephalogram was repeated at this time. The ventricles did not fill, so a ventriculogram was done by tapping the large right temporal horn at the time of the cranioplasty. This radiograph demonstrated a complete filling of the ventricular system and, for the first time, the location of the atresia at the junction of the middle and posterior third of the body of the lateral

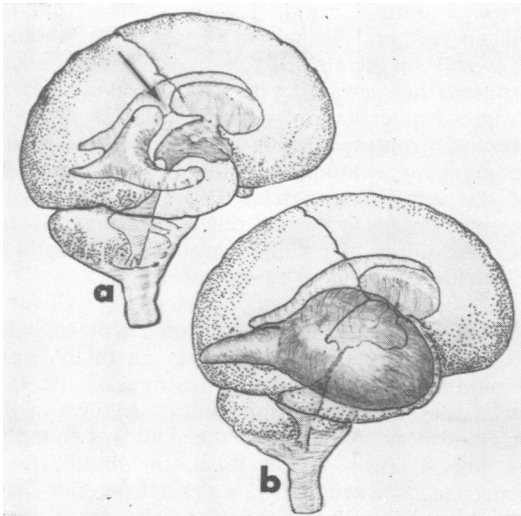


FIG. 4. Drawing to illustrate: (a) atresia of body of right lateral ventricle (arrow), resulting in: (b) gross dilatation of temporal and occipital horns.

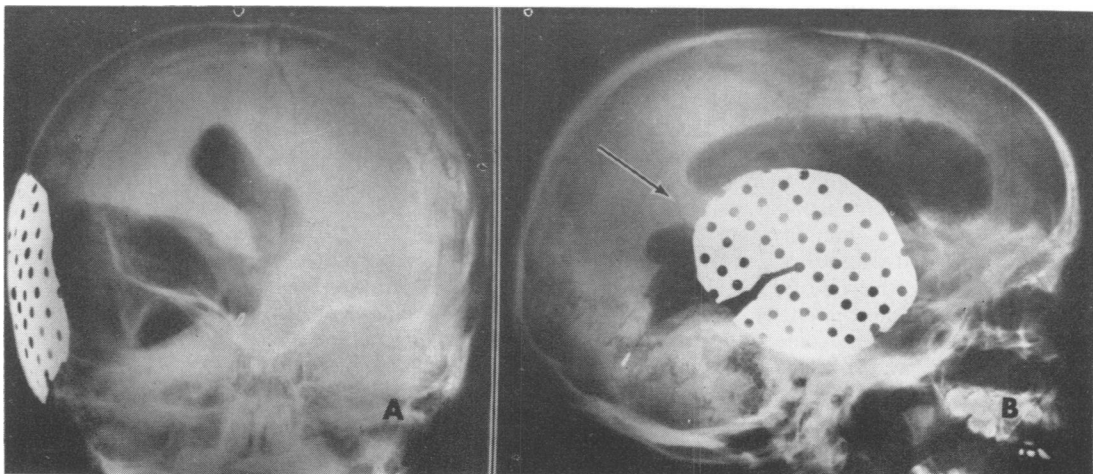


FIG. 5. A. Right ventriculogram two years after operation shows functioning ventriculostomy. B. Site of atresia (arrow). Ventricles not decreased in size.

ventricle was well visualized (Fig. 5b). The dilated ventricle had not decreased in size and the intraventricular pressure was slightly elevated. The patient was entirely symptom free. It was decided to repeat the studies in six months. If any change occurred in the neurological status and/or the ventricles were larger, a shunting procedure would be considered (Fig. 1b).

DISCUSSION

A localized form of hydrocephalus after penetrating wounds of the lateral ventricle was described by Cairns, Daniel, Johnson, and Northcroft (1947). In their large series of war wounds to the brain, three cases were described with localized hydrocephalus of the inferior horn of the lateral ventricle as a complication of penetrating wounds involving the body of the ventricle. These lesions were thought to be due to obliteration of the body of the ventricle by scar tissue. Healing of the ventricular wound resulted in obstruction of the outflow of cerebrospinal fluid from the temporal horn forming a 'cyst' which behaved as a space-occupying lesion.

Another lesion producing a similar clinical picture was described by Northfield and Russell (1939). Two cases of chronic internal hydrocephalus were recorded in which there developed a localized cortical space-occupying lesion causing hemiplegia, interpreted as a neoplasm. At necropsy a false diverticulum of the ventricle was found which apparently resulted from spontaneous rupture of the ependyma permitting escape of cerebrospinal fluid into the surrounding brain tissue, producing a large cyst. Both of these cases had severe chronic obstructive hydrocephalus due to leptomeningitis, traumatic in one case and infective in the other. Since our patient had had no penetrating head wound or infection, his lesion could have been comparable to these cases.

Two cases have been found in the literature in which the intracerebral pathology seems to be the same as our case. The first case reported by Handa and Bucy (1956) was a 25-year-old female with convulsions, headache, and tremors of the right hand. There was a right hemiparesis, hypaesthesia and lower quadrant homonymous hemianopia. Ventriculography disclosed an enormous cavity, $10 \times 7 \times 6\frac{1}{2}$ cm, in the right temporal and occipital region which was interpreted as 'an intracerebral cyst which did not communicate with the ventricular system'. The body and frontal horn of the ventricle and the cyst were completely filled with air which was introduced into both occipital horns. The space between the large cavity and the ventricle was interpreted as a thin membrane separating the two. The protein content of the fluid removed from the large cavity was 95.5 mg/100 ml. compared

with 21.8 mg/100 ml. in the ventricular fluid. The patient was not operated upon, so the large 'intracerebral cyst' was not identified as a part of the ventricular system. The cavity was treated by tapping and evacuation on three occasions, at four and eight year intervals. The patient was followed for over 24 years, during which time her symptoms and neurological findings remained stationary. The ventriculogram illustrations in this case are identical with those of our patient. The lateral view shows an enormous dilatation of the temporal and occipital horns of the ventricle. The anteroposterior view shows a normal frontal horn separated from the dilated temporal horn by a very thin 'membrane'. This may be the clue as to why the lesion became arrested, thus permitting the long period of survival. Progressive dilatation of the isolated ventricle eventually ruptured the 'thin membrane' establishing spontaneous communication with the remainder of the ventricular system. This is a more likely reason for the patient's relief of symptoms for 24 years than the simple tapping procedure to which it was attributed by the authors.

The second case was described by Dorothy Russell in her monograph on hydrocephalus (Russell, 1966). Case no. 29 was an infant, aged 7 months, who died of septicaemia of the face and right cerebral hemisphere after cellulitis of the face and neck. At necropsy the skull was found to be conspicuously asymmetrical, the middle fossa being greatly extended while the left anterior fossa was only slightly larger than the right. There was a great cystic dilatation of the left temporal lobe without visible alteration of the left leptomeninges. On section this was found to be due to gross expansion of the left temporal and occipital horns. At the inferior part of the body of the ventricle the roof was glued down to the fimbria by dense adhesions through which the choroid plexus passed by a pinhead meatus. The anterior part of the left ventricle and the remainder of the ventricular system appeared normal. The ependyma everywhere was smooth and white. Microscopically the adhesions in the left ventricle were composed of collagenous and glial tissue. There was no inflammatory reaction and the choroid plexus appeared normal. The author concluded that the conspicuous unilateral hydrocephalus was due to occlusion of the body of the left ventricle by adhesions which appear to have had their basis in a focus of antecedent haemorrhage. The site of the haemorrhage corresponded with the area in which lesions of the vein of the corpus striatum are sometimes observed in the newborn. Since the infant was born prematurely, this case is comparable with ours, whose lesions may have been of traumatic origin, but it

seems more likely that the lesion was congenital atresia of the embryonic neural tube.

SUMMARY

A rare and interesting case of atresia of the body of one lateral ventricle, probably congenital in origin, is reported. The lesion resulted in a partial or localized unilateral hydrocephalus misdiagnosed as a subarachnoid or intracerebral cyst. Only two similar cases were found in the literature. The lesion caused localized clinical signs, increased intracranial pressure, and marked impairment of skeletal growth. Relief of signs and symptoms was obtained after surgical interventricular communication.

REFERENCES

- Cairns, H., Daniel, P., Johnson, R. T., and Northcroft, G. B. (1947). Localized hydrocephalus following penetrating wounds of the ventricles. *Brit. J. Surg., War Surgery Suppl. No. 1*, 187-197.
- Cohn, R., and Neumann, M. A. (1946). Porencephaly. Clinicopathological study. *J. Neuropath. exp. Neurol.*, 5, 257-270.
- Handa, H., and Bucy, P. C. (1956). Benign cysts of the brain simulating brain tumor. *J. Neurosurg.*, 13, 489-499.
- LeCount, E. R., and Semerak, C. B. (1925). Porencephaly. *Arch. Neurol. Psychiat. (Chic.)*, 14, 365-383.
- Locksley, H. B., and Afifi, A. (1964). Leptomeningeal cysts of the brain simulating tumor. *Trans. Amer. neurol. Ass.*, 89, 218-220.
- Northfield, D. W. C., and Russell, Dorothy S. (1939). False diverticulum of a lateral ventricle causing hemiplegia in chronic internal hydrocephalus. *Brain*, 62, 311-320.
- Pendergrass, E. P., and Perryman, C. R. (1946). Porencephaly. *Amer. J. Roentgenol.*, 56, 441-463.
- Russell, Dorothy S. (1966). Observations on the pathology of hydrocephalus. *Spec. Rep. Ser. med. Res. Coun. (Lond.)*, No. 265, 3rd edn. Fosh and Cross: London.

The October 1969 Issue

THE OCTOBER 1969 ISSUE CONTAINS THE FOLLOWING PAPERS

Regional blood flow in the normal cerebral hemisphere
I. M. S. WILKINSON, J. W. D. BULL, G. H. DU BOULAY, JOHN MARSHALL, R. W. ROSS RUSSELL, and LINDSAY SYMON

A feasibility study of a screening test for abnormalities of carotid blood flow using Technetium-99m
K. E. BRITTON

Intracranial thrombosis of the internal carotid artery after closed head injury
F. L. MASTAGLIA, S. SAVAS, and B. A. KAKULAS

Interhemispheric subdural haematoma: a case report
L. J. CLEIN and C. F. BOLTON

Impairment of pyridoxal phosphate dependent metabolic reactions in a child with subacute necrotizing encephalopathy
M. S. EBADI, R. BOSTAD, and R. J. PELLEGRINO

A case of leucine-induced hypoglycaemia
J. BICKNELL and L. CROME

Perinatal telencephalic leucoencephalopathy
FLOYD H. GILLES and SEAN F. MURPHY

Endocrine function in multiple sclerosis
P. MILLAC, D. B. COOK, and KENNETH CHASE

A procedure for the determination of thresholds in impaired sensory fields
M. E. WILSON

Reversal of the glabellar reflex in Parkinsonism by L-Dopa
HAROLD L. KLAWANS, JR. and JAMES A. GOODWIN

An unusual case of neuroma of the median nerve
R. KANAGASUNTERAM and W. C. WONG

Post-mortem arteriography of cerebral arteriovenous malformations
R. A. RODDA and G. D. CALVERT

Human skeletal muscle fibre type grouping and collateral re-innervation
C. J. MORRIS

Haemangiopericytoma of the pineal body
J. R. OLSON and M. R. ABELL

Clinical features of the epidermoids of the basal cisterns of the brain
S. OBRADOR and J. J. LOPEZ-ZAFRA

Childhood and adolescent forms of Huntington's disease
JACK OLIVER and KENNETH DEWHURST

L-Dopa and the negative symptoms of Parkinsonism
HAROLD L. KLAWANS, JR and MICHAEL ERLICH

The effects of hypoxia on the excitability of the isolated peripheral nerves of alloxan-diabetic rats
K. N. SENEVIRATNE and O. A. PEIRIS

Intracranial ventricular haemorrhage as a first presentation of haemophilia
ADELOLA ADELOYE, O. SERIKI, L. LUZZATTO, and E. M. ESSIEN

The clinical diagnosis and treatment of microgliomatosis: report of a case
D. FISHER, B. S. MANTELL, and H. URICH

Clinical investigation of lesions of the visual pathway: a new objective technique
D. REGAN and J. R. HERON

Thermography in vascular disorders affecting the brain
MAURICE GROSS and MARY POPHAM

Book Reviews

Copies are still available from the PUBLISHING MANAGER,

BRITISH MEDICAL ASSOCIATION, TAVISTOCK SQUARE, W.C.1, price 21s.