

Review article

# Bone biopsy in haematological disorders

R BURKHARDT,\*† B FRISCH,† R BARTL‡

*From the \*Abteilung für Knochenmarksdiagnostik an der Medizinischen Klinik Innenstadt der Universität München, Munich, West Germany, the †Abteilung Haematomorphologie am Institut für Hämatologie der Gesellschaft für Strahlen- und Umweltforschung mbH, Munich, West Germany and the ‡Institute of Haematology Tel Aviv Medical Center and the Sackler School of Medicine Tel Aviv University, Israel*

**SUMMARY** Bone marrow biopsies are now widely used in the investigation and follow-up of many diseases. Semi-thin sections of 8216 undecalcified biopsies of patients with haematological disorders were studied. Observations were made on the cytopenias and the myelodysplastic syndromes, the acute leukaemias and the myeloproliferative disorders, Hodgkin's disease and the malignant lymphomas including multiple myeloma, hairy cell leukaemia and angioimmunoblastic lymphadenopathy. Bone marrow biopsies are essential for the differential diagnosis of most cytopenias and for the early recognition of fibrosis which most frequently occurred as a consequence of megakaryocytic proliferation in the myeloproliferative disorders. Different patterns of bone marrow involvement were found in the lymphoproliferative disorders and both their type and extent constituted factors of prognostic significance. A survey of the literature is given and the conclusion is drawn that bone marrow biopsies provide indispensable information for the diagnostic evaluation and the follow-up of patients with haematological disorders.

During the past decade there have been major advances in the understanding of disorders of the blood accompanied by increasing recognition of the complex structural and hormonal interrelations between the cellular and tissue elements in the bone and marrow. Consequently, bone and bone marrow biopsies are now being taken routinely at many centres normally together with, but occasionally instead of bone marrow aspirates.<sup>1-8</sup> Improvements in biopsy technique,<sup>4 9-11</sup> as well as technical progress in their preparation<sup>12-17</sup> have provided additional impetus to the study of bone marrow as an organ with its architecture and components intact and in their natural spatial context. This offers a broader basis for comprehension of its function in health and disease.

The indications for biopsy have widened to include many conditions in haematology, in internal medicine, and in oncology (Table 1). In haematology, a bone biopsy is indicated in the differential diagnosis of cytopenias and for a more precise prognostic classification of the myelo- and lymphoproliferative disorders. A bone biopsy is also valuable in the research into basic problems relating to immunology, to mesenchymal, vascular, haematopoietic and osteogenic tissues and their regulatory mechanisms.

Table 1 *Diagnostic value of bone marrow biopsy in patients with unexplained cytopenia: 441 patients*

| <i>Diagnosis by bone marrow biopsy</i> | <i>No of patients</i> | <i>% of total</i> |
|--|-----------------------|-------------------|
| Refractory anaemia                     | 141                   | 32                |
| Aplastic anaemia                       | 60                    | 14                |
| Malignant lymphomas (non-Hodgkin)      | 58                    | 13                |
| Acute leukaemia                        | 50                    | 11                |
| Hairy cell leukaemia                   | 45                    | 10                |
| Agnogenic myeloid metaplasia           | 40                    | 9                 |
| Hodgkin's disease                      | 14                    | 3                 |
| Multiple myeloma                       | 10                    | 2                 |
| Preleukaemia (sequential biopsies)     | 5                     | 1                 |
| Systemic mastocytosis                  | 4                     | 1                 |
| Malignant histiocytosis                | 3                     | 1                 |
| Angioimmunoblastic lymphadenopathy     | 2                     | 1                 |

The purpose of this review is to present a synopsis of the observations made on 8216 bone marrow biopsies of patients with haematological disorders, excluding congenital conditions, together with a survey of the literature.

### Biopsy site

Bone marrow biopsies are taken from the anterior (with Burkhardt's drill or Bordier's trephine) or the posterior iliac crests (Jamshidi needle). The former provide biopsy cores with maximum sizes of 4 mm × 22 mm, and 5-8 mm × 10 mm respectively.

Both are employed for histomorphometric measurements. The cores may also be halved longitudinally and one half used for plastic embedding and the other for histochemistry and electron microscopy.<sup>18</sup> Biopsies taken with the Jamshidi needle have maximum dimensions of 2 × 30 mm but frequently much shorter ones are obtained. Bone biopsies are routinely performed under local anaesthesia except in children when general anaesthesia is preferred. Special attention must be paid to all increased risks of bleeding or infection. Bone biopsies should never be considered in patients suffering from bleeding disorders of the haemophilic type.

### Technical procedures

Plastic embedding is the preferred method for cellular identification and for quantitative studies. The undecalcified cores are fixed, dehydrated and impregnated with synthetic resin. A major advantage of plastic embedding is greatly reduced overall shrinkage, with a decrease of only approximately 5% of the volume of the fresh tissue.<sup>4 15</sup>

The original observations reported here were made on 3 μm sections of methyl-methacrylate-embedded bone marrow biopsies, the majority of which were taken with the myelotomy drill, the rest with the Jamshidi needle. The following stains were routinely employed:<sup>4</sup> gallamine blue-Giemsa for cytological detail, Gomori's stain for reticulin fibres, the PAS stain for glycoproteins, the Berlin blue stain for iron, Ladewig's and Goldner's stains for osteoid, calcified bone and connective tissue. A modification of the Giemsa stain<sup>4</sup> is especially recommended, as it produces a picture similar to that of stained smears of aspirates, and enables identification of cells and comparison between sections and smears. Gomori's

stain for reticulin is also of particular value in the assessment of sections of bone marrow biopsies and for this the best results are obtained with 3 μm plastic sections.

### Normal bone and bone marrow

The normal distribution of bone and bone marrow components is shown in Table 2 and illustrated in Fig. 1. The structure of the iliac cortical and cancellous bones is taken as representative of that of the axial skeleton,<sup>19</sup> though there are differences: the cortices of the vertebral bodies are narrower and the trabeculae are somewhat thinner than the corresponding structures in the ilium. In adult life, remodelling occurs primarily on the subcortical endosteal trabecular surfaces, which are covered by a continuous layer of endosteal lining cells, including the osteoblasts and osteoclasts.<sup>20</sup> There is also a close relation between the endothelia of the trabecular sinuses and osteogenic precursor cells which requires further investigation. A layer of osteoid of varying thickness covers the trabecular surface except at points of resorption<sup>21</sup> though with *in vivo* tetracycline studies about 27% coverage is taken as normal.<sup>20</sup> Osteoid is also susceptible to resorption by osteoclasts.

The pelvic bones enclose red haematopoietic marrow and alterations in haematopoiesis are usually reflected in this site. The significance of unusual and selective changes in this region needs clarification.<sup>22-24</sup> The existence of an inductive haematopoietic micro-environment is no longer disputed.<sup>27</sup> This includes the concept of specific anatomical areas and cells which direct a stem cell to a particular line of differentiation. It has been shown that marrow sinusoids have a unique structure,<sup>28</sup> and that the

Table 2 *Histomorphometry of normal bone and bone marrow from 158 biopsies of normal healthy individuals*

|                      | <i>Dimension and units</i>       | <i>Mean ± SD</i> |
|----------------------|----------------------------------|------------------|
| Hematopoietic tissue | Volume (%)                       | 40 ± 9           |
| Fatty tissue         | "                                | 28 ± 8           |
| Trabecular bone      | "                                | 26 ± 5           |
| Osteoid              | "                                | 0.3 ± 0.2        |
| Sinuses              | "                                | 4.5 ± 2.1        |
| Edema                | "                                | 0.2 ± 0.8        |
| Megakaryocytes       | number/100 mm <sup>2</sup>       | 759 ± 73         |
| Mast cells           | bone marrow area                 | 160 ± 53         |
| Plasma cells         | "                                | 2114 ± 1812      |
|                      | mm/100 mm                        |                  |
| Osteoblastic index   | trabecular circumference         | 5 ± 5            |
| Osteoclastic index   | /100 mm trabecular circumference | 4 ± 3            |
|                      | number/100 mm <sup>2</sup>       |                  |
| Arteries             | bone marrow area                 | 3 ± 2            |
| Arterioles           | "                                | 26 ± 21          |
| Capillaries          | "                                | 101 ± 58         |
| Sinuses              | "                                | 1700 ± 980       |

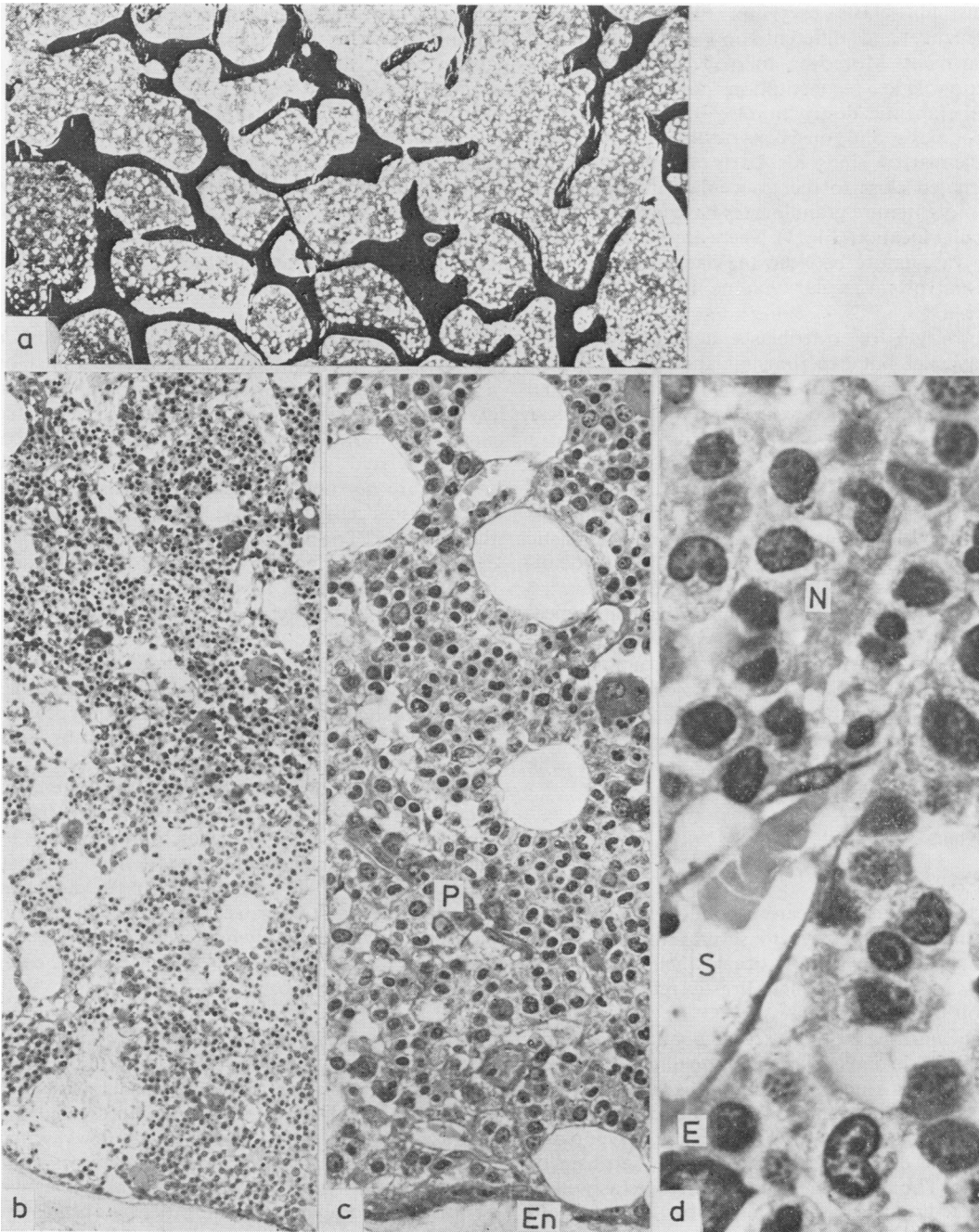


Fig. 1 \*Normal bone marrow; (a) normal distributions of trabecular bone, haematopoietic and fatty marrow (♀ 52 yr) × 10; (b) distribution and localisation of the three haematopoietic cell lines × 100; (c) from bottom to top: endosteal surface (En), immature granulocytes, sinusoids, mature granulocytes, erythroblasts and megakaryocytes; note arterial capillary with plasma cells (P) and promyelocytes × 250; (d) sinusoidal capillary (S) with neutrophilic granulocytes (N), and erythroblasts (E) × 960.

\*All figures in this and the following illustrations were taken from 3 μm sections stained with gallamine blue-Giemsa, if not stated otherwise.

marrow fibroblasts exert an influence on self-maintenance and differentiation of the stem cell compartment. Moreover, marrow fat cells support haematopoietic reconstitution and regeneration after therapeutic destruction.<sup>19-31</sup> Topographically, erythropoiesis and megakaryocytes are associated with the marrow sinusoids. Early myeloid precursors are situated close to the trabeculae and arterioles, while more mature granulocytes have a central intertrabecular location (Fig. 1). There are also differences in the vasculature between the haematopoietic and fatty marrow: vascular volume is greater in the former.<sup>25 26</sup>

The origin of osteoblasts and osteoclasts is controversial but experimental and clinical results indicate that osteoblasts originate from mesenchymal cells while osteoclasts develop from the mononuclear phagocyte system.<sup>32-34</sup> There is no proof for a common cell line that gives rise to both.<sup>35-38</sup> Bone marrow biopsies also show evidence indicating a general mesenchymal activation during early periods of life as well as during hormonal and neoplastic stimulation.<sup>39</sup> Unequivocal morphological identification of the stem cells has not yet been achieved.<sup>40</sup> The profound influence which haematological diseases will have on these spatially orientated functions is evident and helps to account for the extreme sensitivity of haematopoietic tissues to structurally disruptive processes. The close interrelation and interdependence of haematopoietic and osseous tissues have recently gained increasing recognition.<sup>41</sup>

## Cytopenias

### ANAEMIAS

Non-defective marrow can respond to stimuli by an expansion of its reserve to several times normal. Anaemia does not readily occur when all required factors are available unless drastic red cell loss or haemolysis has occurred.

Bone marrow biopsies reveal quantitative alterations in erythropoiesis as well as qualitative changes. Hyperplasia is seen in all conditions with increased or ineffective haematopoiesis, with and without haemolysis, including iron deficiency. Hypoplasia indicates a defect in haematopoiesis—intrinsic or extrinsic. Though local structural changes as well as age-related alterations must be taken into account,<sup>23 24 42</sup> a decrease in the erythropoietic compartment in iliac crest biopsies is a sign of a decreased marrow reserve.

Qualitative changes include the cytological features of the particular anaemia as well as dyserythropoiesis and erythrophagocytosis by histiocytes, increase in mast cells and megakaryocytes. Many of these

features, especially the occurrence of erythroblasts in the sinusoids and lymphocytic infiltration, are characteristic of haemolytic anaemias with an immunological pathogenesis. Bone marrow sections stained for iron depict accurately and reproducibly overload, depletion or normal storage.<sup>43</sup> There is generally a good correlation between serum ferritin concentrations, iron absorption and marrow stores<sup>44 45</sup> except in cases of sideroblastic anaemias, haemosiderosis, in some cases of neoplasia, in various infections and in hepatic diseases.

### *Aplastic anaemia*

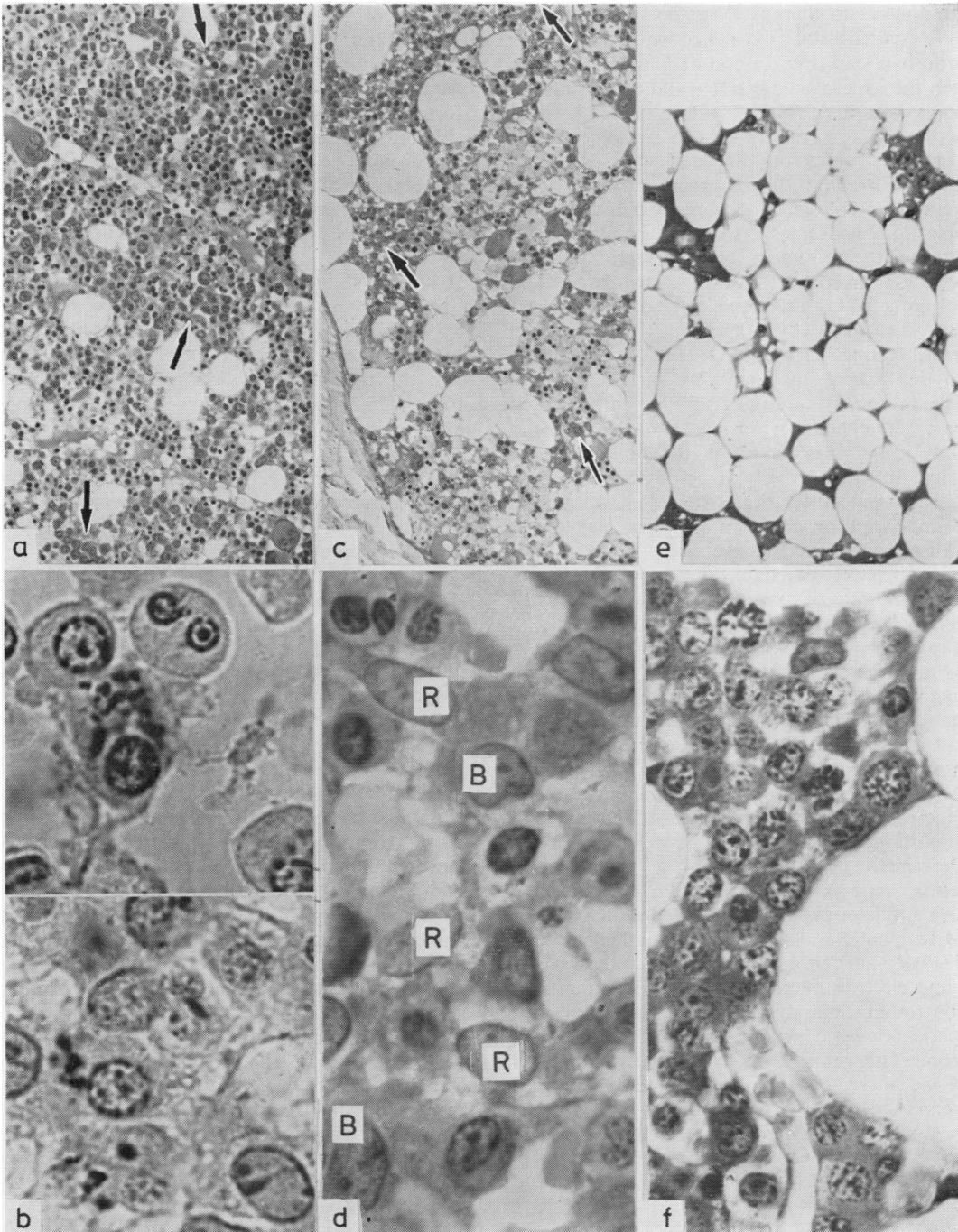
See Fig. 2e and f. In aplastic anaemia there is a reduction in erythropoietic tissue accompanied by a decrease in marrow sinusoids. The residual erythroblastic islands, so-called hot spots, are located close to sinusoids. In the remaining marrow spaces and correlated with the activity of the disease process are necrotic cells and capillaries. Lymphocytes, plasma cells and mast cells are scattered among the fat cells.<sup>46</sup> The numbers of arterioles and arterial capillaries may be normal or increased, the numbers of sinusoids decreased. This stromal reaction together with the vascular alterations is possibly a change specific for aplastic anaemia<sup>26</sup> which may have prognostic significance<sup>47 48</sup> though this is disputed.<sup>49</sup> Numerous factors cause aplastic anaemia and it has been postulated that there are various subtypes<sup>50-52</sup> due to disturbances in regulatory mechanisms. Sub-clinical hepatitis may be responsible for many of the cases of so-called idiopathic aplastic anaemia.<sup>53</sup> When aplasia is caused by starvation or radiation<sup>54</sup> there is replacement of the haematopoietic tissue by fat. Complete or partial restitution may occur in these conditions while it rarely happens in idiopathic aplastic anaemia.<sup>55</sup> There is no explanation for this but it is noteworthy that lymphocytic infiltration and capillary necroses are generally absent in those cases in which restitution occurs.

### *Pure red cell aplasia*

The bone marrow findings in this condition differ from those in aplastic anaemia. Erythroid precursors are absent but myelopoiesis is well represented; fat cells are only moderately increased and few vascular changes are noted. There is widespread siderosis and there are focal lymphocytic infiltrations. Anaemias occurring in combination with other cytopenias are considered below.

### REFRACTORY ANAEMIA AND MYELOYDYSPLASTIC SYNDROMES

The first of these terms refers to a syndrome of primary anaemia characterised by dyserythropoiesis and a variable degree of dysmyelopoiesis, and which



**Fig. 2** (a) *Refractory anaemia, note megaloblastic erythropoiesis (arrows) (♀ 81 yr) × 100*; (b) *as above, sideroblasts, Berlin blue stain × 1000*; (c) *preleukaemia, hypoplastic haematopoiesis with foci of immature cells (arrows) (♂ 65 yr) × 100*; (d) *as above, showing blasts (B) and reticulum cells (R) × 1000*; (e) *aplastic anaemia, note atrophic marrow with interstitial oedema and plasma cells (♀ 10 yr) × 100*; (f) *as above, showing erythroblasts round a sinus, a so-called "hot spot" × 500*.

is unresponsive to therapy.<sup>56</sup> In the bone marrow, there is increased cellularity, ineffective erythropoiesis and iron overload (Fig. 2a and b). This discrepancy between the hyperplastic marrow and the peripheral cytopenia was first pointed out by Block.<sup>57</sup> Two types of refractory anaemia have since been distinguished: (i) refractory anaemia with excess of blasts (RAEB), and (ii) refractory anaemia with proliferative dysplasia. The borders between myelodysplastic syndromes (so-called preleukaemic states) and the refractory anaemias are not well defined and overlap to some extent.<sup>56-60</sup> The preleukaemic states have been defined as "acquired diseases characterised by haematopoietic insufficiency and terminating in acute leukaemia." Factors identifying patients as high risk include: abnormalities in more than one cell line, discrepancy between peripheral cytopenia and hyperplastic marrow, raised blast count in the bone marrow, abnormal *in vitro* growth or colony-forming cells and chromosome aberrations. The latter two are the most important prognostic parameters suggesting transformation to overt leukaemia.

In the preleukaemic state the bone marrow may be hyper-, normo- or hypocellular. One or more cell lines may be hyperplastic or almost absent. A significant blast cell population is not present, but there may be transitions to the "smouldering leukaemias." The bone marrow in a case of preleukaemia which later terminated in acute leukaemia is illustrated in Fig. 2c and d. The marrow findings in chronic myelomonocytic leukaemia show hypercellularity of the neutro- and the monocytic series with increase in their precursor cells. There are, in addition, large histiocytic cells, as well as others of undetermined origin.<sup>61</sup> Rarely a typical preleukaemic state is found to be Ph chromosome-positive and later evolves into acute leukaemia,<sup>62</sup> or mixed lymphatic and myelomonocytic leukaemia.<sup>63</sup> Thiele *et al*<sup>64</sup> have provided a detailed analysis of the light and electron microscopic findings in the bone marrow in myeloid dysplasia and have described 195 patients with clinically suspected preleukaemic syndromes, of whom 93 had the typical findings in the bone marrow but only 27 later developed leukaemia. In our own retrospective study of the biopsies of 103 patients with suspected preleukaemia, overt leukaemia was later documented in 30 cases. Rarely, sideroblastic anaemia may terminate in acute myelofibrosis.<sup>65</sup>

#### GRANULOCYTOPENIA AND THROMBOCYTOPENIA

These occur as isolated forms or in combination, with or without anaemia. There are few studies of the acute forms, especially when caused by toxic or

allergic reactions. In other cases bone marrow biopsy will reveal the underlying cause(s) which may be any of the conditions listed in Table 1 and which are considered in the appropriate sections. Granulocytopenia, particularly in the older age groups, may be due to smouldering leukaemia. Similarly the immature form of megakaryocytic myelosis may be the underlying cause for a thrombocytopenia in the elderly in contrast to the more benign form which is more frequent in younger patients.

#### ACUTE LEUKAEMIAS (Table 3)

In acute leukaemia, most investigations over the past decade have been concerned with the characterisation and classification of leukaemic cells from the peripheral blood or bone marrow aspirates.<sup>66-80</sup> Only rarely have studies of bone marrow biopsies been reported,<sup>71-72</sup> except after chemotherapy.<sup>73</sup>

With deepening understanding of the role of the marrow microenvironment in haematopoiesis, bone marrow biopsies in acute leukaemia will be reported more frequently. The importance of the investigation of the bone marrow before and after transplantation has already been stressed. It has also been shown that bone marrow biopsies give earlier warning of imminent relapse. Small clusters and foci of blast cells were found in the marrow when peripheral blood and aspirate were negative.<sup>74 75</sup> The evaluation of bone marrow biopsies is a more effective way of checking induction of complete remission and monitoring the effects of therapy, than examination of peripheral blood or aspirates alone. In childhood acute leukaemia one of the most important prognostic criteria is the initial blast count in the peripheral blood,<sup>76</sup> and in a group of adult patients with acute myeloid leukaemia the long-term survivors also tended to have a lower total white cell count at presentation.<sup>77-79</sup> It may be that quantitative estimation of the volume percentage of the leukaemic infiltration in the bone marrow has equal importance.

Figure 3 illustrates some histological and cytological features in the bone marrow of acute leukaemias. Before treatment biopsies of early cases may show small islets of blast cells scattered among fatty tissue, more or less depleted of normal haematopoiesis. With progress of the disease, the marrow is replaced by sheets of leukaemic blast cells. In between, foci of normal haematopoiesis may be left: There is disintegration of the marrow sinusoids, but a fine fibre network supports the leukaemic tissues as well as the remainder of the marrow parenchyma. Macrophages may be increased containing nuclear debris. Large necrotic marrow areas are frequently found in the biopsy. Promyelocytic

Table 3 Acute leukaemias according to the proliferative cell type in the bone marrow from 131 cases receiving no treatment before initial biopsy

| Patients (n = 131)                                  | Lymphoblastic (15)<br>% | Myeloblastic (57)<br>% | Myelomonocytic (23)<br>% | Monocytic (10)<br>% | Promyelocytic (26)<br>% |
|---|-------------------------|------------------------|--------------------------|---------------------|-------------------------|
| Haemoglobin (g/dl) < 8                              | 29                      | 25                     | 32                       | 33                  | 24                      |
| 8-12  | 50                      | 66                     | 52                       | 67                  | 72                      |
| > 12  | 21                      | 9                      | 16                       | 0                   | 4                       |
| Leucocytes ( $\times 10^9/l$ ) < 4                  | 21                      | 11                     | 39                       | 22                  | 32                      |
| 4-10  | 29                      | 45                     | 9                        | 36                  | 48                      |
| > 10  | 50                      | 44                     | 52                       | 44                  | 20                      |
| Platelets ( $\times 10^9/l$ ) < 50                  | 36                      | 47                     | 52                       | 67                  | 33                      |
| 50-100  | 18                      | 26                     | 11                       | 22                  | 46                      |
| > 100   | 46                      | 27                     | 29                       | 11                  | 21                      |
| Leukaemic blood picture                             | 60                      | 52                     | 69                       | 50                  | 42                      |
| Percentage of blasts in blood picture $\pm$ SD      | 50 $\pm$ 36             | 32 $\pm$ 34            | 25 $\pm$ 29              | 18 $\pm$ 27         | 10 $\pm$ 17             |
| Bone marrow histology                               |                         |                        |                          |                     |                         |
| Infiltration volume (vol %) $\pm$ SD                | 58 $\pm$ 21             | 53 $\pm$ 25            | 59 $\pm$ 15              | 63 $\pm$ 12         | 41 $\pm$ 30             |
| Mitotic activity low                                | 13                      | 96                     | 81                       | 60                  | 100                     |
| intermediate  | 80                      | 4                      | 19                       | 40                  | 0                       |
| high  | 7                       | 0                      | 0                        | 0                   | 0                       |
| Proliferation pattern, interstitial "packed marrow" | 20                      | 38                     | 50                       | 10                  | 71                      |
|   | 80                      | 62                     | 50                       | 90                  | 29                      |
| Histotopography                                     |                         |                        |                          |                     |                         |
| Endosteal and paravascular                          | 0                       | 20                     | 18                       | 50                  | 88                      |
| Independent of structures                           | 100                     | 80                     | 82                       | 50                  | 12                      |
| Fibrosis reticular                                  | 100                     | 90                     | 90                       | 85                  | 100                     |
| coarse  | 0                       | 10                     | 10                       | 15                  | 0                       |

leukaemia, in contrast to the "blastic" forms, is characterised by a loose infiltration localised mainly in the peritrabecular and perivascular regions, the changes of the residual haematopoiesis being less pronounced. The bony trabeculae are also affected in the acute leukaemias in adults. However, in children there is the possibility of more severe changes, osteoporosis as well as osteomalacia, especially during the course of therapy.<sup>80-81</sup> In acute leukaemia in adults, an increase in the reticulin of the bone marrow may be associated with relapse.<sup>82</sup>

#### Chronic myeloproliferative disorders (MPD)

The concept of the chronic myeloproliferative disorders<sup>83</sup> has gained wide acceptance with a more uniform terminology and a more critical evaluation of the diagnostic criteria.<sup>84-86</sup> In chronic MPD, bone marrow biopsy, until recently performed only because of a dry tap, is now required in order to classify accurately the main groups and subgroups according to histological features.

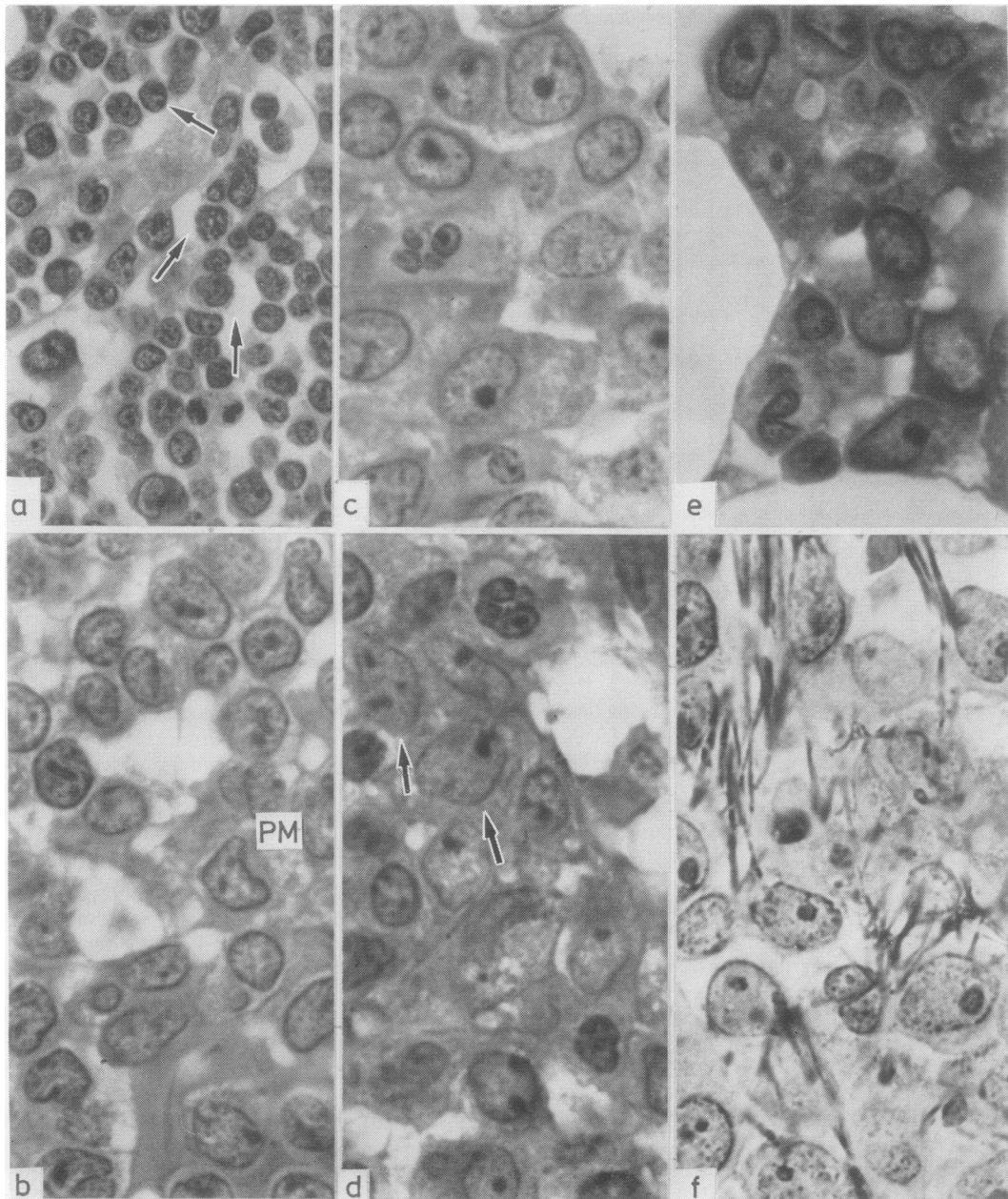
The MPD include polycythaemia vera (PV), chronic myelogenous leukaemia (CML), idiopathic thrombocythaemia (IT) myelofibrosis (MF) and osteomyelofibrosis (OMS) as well as variant transitional and intermediate forms which have characteristics belonging to two of the above syndromes.<sup>87-88</sup> Histological examination of the bone marrow in the MPD is essential in following the course of the disease, in monitoring treatment and in early recognition of transformation to an acute phase which may occur, sometimes, with a

change of phenotype.<sup>89</sup> Studies of glucose-6-phosphate dehydrogenase have shown that the MPD are neoplastic diseases, due to malignant transformation in a single clone.<sup>90</sup> However, there may well be some predisposing environmental, familial or genetic factors.<sup>91-92</sup> Our own studies of 1121 cases of myeloproliferative disorders, have led to the formulation of interrelations between them (Table 4).

#### POLYCYTHAEMIA VERA (PV)

The diagnosis is made by the recognition of the established criteria.<sup>93</sup> Polycythaemia vera may be divided into four groups (Tables 4 and 5), depending on the predominant proliferating cell line as seen in the bone marrow: (i) erythrocytic, granulocytic and megakaryocytic; (ii) erythrocytic (Fig. 4a); (iii) erythrocytic and megakaryocytic (Fig. 4b); (iv) erythrocytic and granulocytic. The classic form of PV is that in which all three cell lines are affected and the following features seen in the biopsies: there is hyperplasia of all three cell lines in those marrow regions where they normally proliferate with marked polymorphism and necrosis of megakaryocytes. In the stroma there is reduction in fat cells with hyperplasia of all vessels and hyperaemia of the sinusoids. Iron stores are depleted and the marrow is infiltrated with plasma cells. There is attenuation of the cancellous trabeculae and a diffuse slight reticulin fibrosis of the marrow.

Occasionally biopsies are seen which are of intermediate type. The separation of PV into four groups on the basis of the histological findings has prog-



**Fig. 3** (a) *Acute lymphoblastic leukaemia (ALL)*. Note dense infiltration in the marrow, with lymphoblasts in and around a sinus (arrows) (♀ 69 yr) × 500; (b) *Acute myeloid leukaemia (AML)*. Infiltration of myeloblasts and paramyeloblasts (PM) (♀ 42 yr) × 1000; (c) *promyelocytic leukaemia*. Note promyelocytes with irregular shapes and large nuclei (♂ 50 yr) × 1000; (d) *myelomonocytic leukaemia*, note atypical monoblasts (arrows) (♀ 50 yr) × 1000; (e) *incipient AML*, small focus of myeloblasts between fat cells (♂ 24 yr) × 1000; (f) *AML myeloblasts with coarse intercellular reticulin fibres* (♀ 54 yr) Gomori's stain × 1000.



Table 4 Interrelations of the myeloproliferative disorders based on bone marrow histology in 1121 patients

| Clinical entities (patients)    | % of MPD | Histological classification according to the proliferative cell line(s) |      | Predominant metamorphosis  |
|---------------------------------|----------|---|------|--|
| Polycythaemia vera (594)        | 2        | ERY   | —    |  |
|                                 | 3        | ERY   | GRAN |  |
|                                 | 22       | ERY   | —    | MEG  |
|                                 | 21       | ERY   | GRAN | MEG  |
| Megakaryocytic myelosis (78)    | 7        | —   | —    | MEG  |
| Chronic myeloid leukaemia (494) | 27       | —   | GRAN | MEG  |
|                                 | 18       | —   | GRAN | —  |
|                                 |          |   |      | → Myelofibrosis (58%)<br>→ Myelofibrosis (74%)<br>→ Myelofibrosis (61%)<br>→ Myelofibrosis (76%)<br>→ Blast crisis (79%) |

Table 5 Classification of chronic myeloproliferative disorders based on the predominant proliferating cell line(s) in the bone marrow. Polycythaemia vera in 232 cases receiving no treatment before initial biopsy

| Patients (n = 232)  | Polycythaemia vera      |   |   |                                      |
|---|-------------------------|---|---|--------------------------------------|
|   | Erythrocytic (n = 10) % | Erythrocytic-megakaryocytic (n = 109) % | Erythrocytic-megakaryocytic-granulocytic (n = 99) % | Erythrocytic-granulocytic (n = 14) % |
| Haemoglobin > 16 g/dl                                     | 60                      | 54                                      | 36  | 71                                   |
| Leucocytes > 10 ( $\times 10^9/l$ )                       | 40                      | 44                                      | 65  | 71                                   |
| Platelets < 400 ( $\times 10^9/l$ )                       | 0                       | 24                                      | 22  | 15                                   |
| Bone marrow histology                                     |                         |   |   |                                      |
| Haematopoietic tissue (vol %)                             | 56 $\pm$ 11             | 48 $\pm$ 19                             | 59 $\pm$ 17   | 64 $\pm$ 10                          |
| Fatty tissue (vol %)                                      | 8 $\pm$ 8               | 10 $\pm$ 9                              | 5 $\pm$ 7   | 4 $\pm$ 5                            |
| Trabecular bone (vol %)                                   | 27 $\pm$ 6              | 25 $\pm$ 9                              | 24 $\pm$ 8  | 23 $\pm$ 5                           |
| Sinuses (vol %)   | 9 $\pm$ 3               | 8 $\pm$ 3                               | 6 $\pm$ 3   | 8 $\pm$ 4                            |
| Megakaryocytes (per 100 mm <sup>2</sup> bone marrow area) | 975 $\pm$ 501           | 2048 $\pm$ 867                          | 7123 $\pm$ 17270                                    | 923 $\pm$ 542                        |
| Eosinophils, increased                                    | 20                      | 21                                      | 87  | 51                                   |
| Fibrosis, reticular                                       | 100                     | 56                                      | 31  | 100                                  |
| coarse  | 0                       | 44                                      | 69  | 0                                    |
| Siderin, missing  | 80                      | 73                                      | 72  | 93                                   |
| Lymphoid nodules  | 20                      | 13                                      | 8   | 0                                    |

nostic significance (Table 4) and is important in patient management. Median survival is highest in the erythrocytic type (115 months), and lowest for the classic type (79 months). Myelofibrosis develops most frequently in the megakaryocytic and myeloblastosis in the granulocytic varieties (Table 4). Similar results have been reported by others.<sup>94</sup> If the bone marrow histology is established early in the disease, these trends may be followed during treatment with early identification of those likely to develop a blastic crisis or myelofibrosis. The findings described are present in sections of iliac crest biopsies, but there may be extension of the haematopoietic marrow from the axial into the appendicular skeleton in PV.<sup>95</sup>

In secondary erythrocytosis, bone marrow biopsies do not show hyperplasia of all three cell lines, marked polymorphism of the megakaryocytes, marked reduction in fat cells or depletion of the iron stores. Examination of bone marrow biopsies is a valuable aid in the distinction between secondary erythrocytosis and PV. Moreover, these entities may also be distinguished on the basis of the cytologic aberrations of maturation found in PV.<sup>96</sup>

Rarefaction of the cancellous bone in PV is an example of myelogenous osteodysplasia and may be due to diversion of the capillary blood supply away from the bone,<sup>74</sup> but pressure exerted on the trabeculae by the expanded mass of the haematopoietic tissue (including the hypertrophied blood vessels) has been indicated as another factor.<sup>97</sup>

Some degree of fibrosis occurs in a certain percentage in PV (Table 5). This is now recognised as part of the natural course of the disease. However, whether particular forms of treatment may induce or accelerate its development has not yet been settled. This question may be investigated by serial bone marrow biopsies. Our own observations of sequential bone biopsies of 58 patients followed for periods of 2 to 5 years show that treatment with <sup>32</sup>P has no influence on fibrosis in the marrow.<sup>98</sup> Leukaemia may occur in some patients during the "natural" course of the disease.<sup>99</sup>

There is a higher incidence of malignant lymphomas and multiple myeloma in patients with chronic MPD than in the general population. This is particularly so for CLL.<sup>100</sup> Moreover there is an increased incidence of acute leukaemia in PV

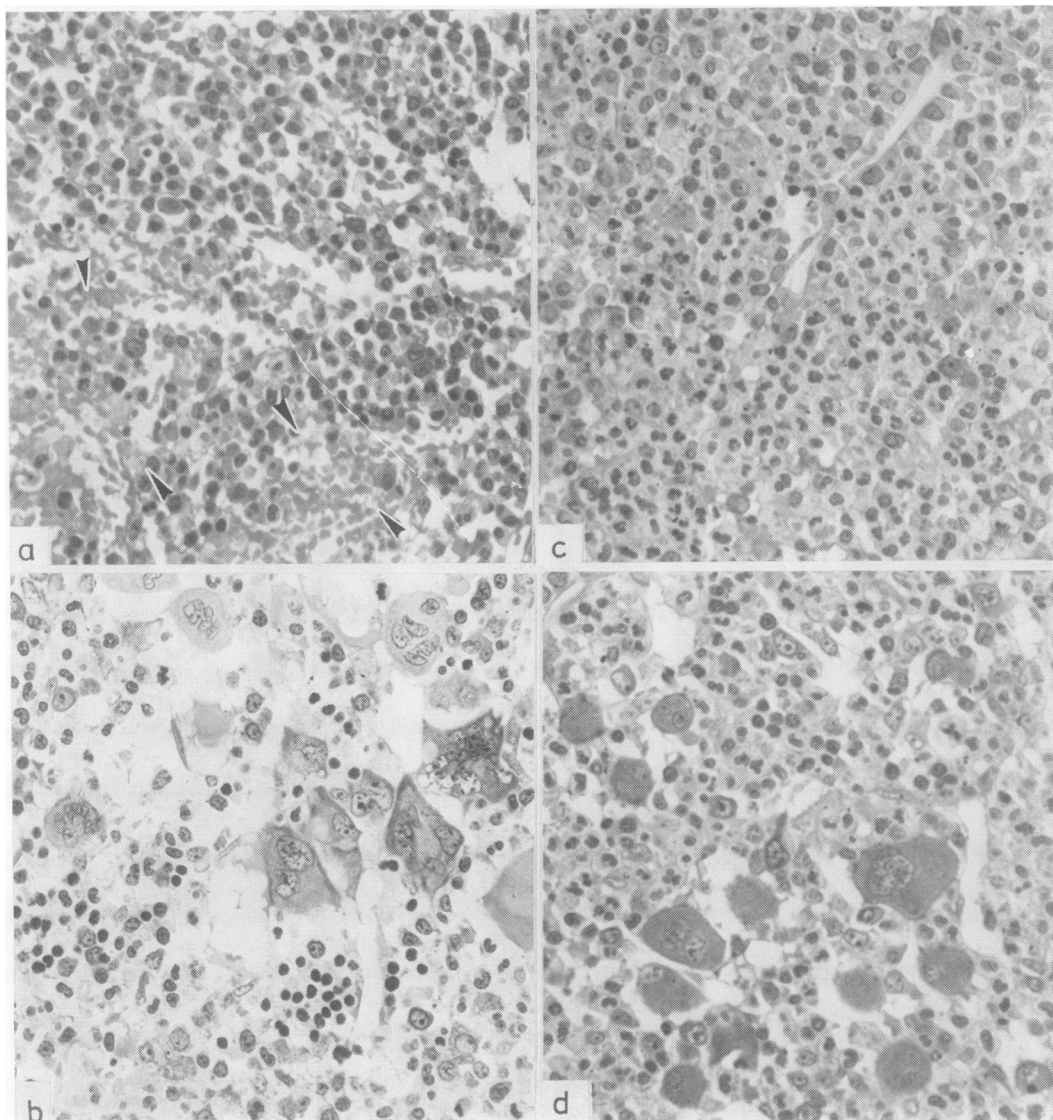


Fig. 4 (a) *Polycythaemia vera*, erythrocytic type; note erythroblastic and granulocytic proliferation, and hyperaemic sinusoids (arrows) ( $\delta$  30 yr)  $\times$  250; (b) *PV* erythrocytic and megakaryocytic type, note numerous polymorphic megakaryocytes ( $\delta$  58 yr)  $\times$  250; (c) *CML* granulocytic type, hypercellular marrow, mostly immature and mature granulocytes ( $\delta$  62 yr)  $\times$  250; (d) *CML*, mixed type, marrow shows both granulocytic and megakaryocytic proliferation ( $\delta$  41 yr)  $\times$  250.

associated with chlorambucil therapy.<sup>101</sup> These complications may be found in biopsy sections before they are evident clinically and haematologically.

#### CHRONIC MYELOID LEUKAEMIA

Recent studies indicate that *CML* is not a single entity, but may be classified into two categories according to the findings in the bone marrow

(Table 6). These are the granulocytic (Fig. 4c) and the mixed-granulocytic and megakaryocytic types (Fig. 4d). Though the neutrophilic cell line is the one most frequently involved, basophilic and eosinophilic forms also occur; the latter must be differentiated from the hyper-eosinophilic syndrome.<sup>102, 103</sup> The most differentiated neutrophilic form is rare.<sup>104</sup> In the granulocytic type the hyperplasia affects the

Table 6 Classification of chronic myeloproliferative disorders based on the proliferating cell line(s) in the bone marrow. Chronic myeloid leukaemia and megakaryocytic myelosis in 195 cases receiving no treatment before initial biopsy

| Patients (n = 195)  | Chronic myeloid leukaemia (CML) |   | Megakaryocytic myelosis (MM) |
|---|---------------------------------|---|------------------------------|
|   | Granulocytic (n = 66)<br>%      | Megakaryocytic-<br>granulocytic (n = 77)<br>% | Megakaryocytic (n = 52)<br>% |
| Haemoglobin < 10 g/dl                                     | 24                              | 34  | 31                           |
| Leukocytes ( $\times 10^9/l$ )                            |                                 |   |                              |
| 10-50   | 33                              | 47  | 50                           |
| > 50  | 57                              | 40  | 2                            |
| Platelets ( $\times 10^9/l$ )                             |                                 |   |                              |
| < 200   | 54                              | 35  | 8                            |
| 400-800   | 10                              | 25  | 15                           |
| > 800   | 0                               | 15  | 55                           |
| Bone marrow histology                                     |                                 |   |                              |
| Haematopoietic tissue (vol %)                             | 73 $\pm$ 12                     | 65 $\pm$ 17                                   | 54 $\pm$ 13                  |
| Fatty tissue (vol %)                                      | 2 $\pm$ 4                       | 5 $\pm$ 7                                     | 15 $\pm$ 10                  |
| Trabecular bone (vol %)                                   | 21 $\pm$ 5                      | 23 $\pm$ 5                                    | 23 $\pm$ 4                   |
| Sinuses (vol %)   | 2 $\pm$ 1                       | 6 $\pm$ 3                                     | 7 $\pm$ 3                    |
| Megakaryocytes (per 100 mm <sup>2</sup> bone marrow area) | 632 $\pm$ 410                   | 6364 $\pm$ 5637                               | 20410 $\pm$ 25430            |
| Eosinophils, increased                                    | 87                              | 88  | 44                           |
| Fibrosis, reticular                                       | 99                              | 55  | 37                           |
| coarse  | 1                               | 45  | 63                           |
| Siderin, missing  | 57                              | 69  | 47                           |
| Lymphoid nodules  | 0                               | 5   | 6                            |

} Means  $\pm$  SD

granulocytic cell line only.<sup>105</sup> In the mixed type there are also quantitative and qualitative alterations in the megakaryocytes, which are highly polymorphic. In both types, there is a decrease in fat cells and a variable increase in reticulin; prominent histiocytes, containing basophilic crystalloid material, are frequently found. These histiocytes are often located in close proximity to aggregates of eosinophilic and basophilic granulocytes and mast cells. Though the pathological significance of these groupings has not yet been clarified, an immunological aetiology has been postulated.<sup>106</sup> However, prominent or unusual macrophages in the bone marrow may be found in a large variety of different disease states,<sup>107-109</sup> and they are not specific to any condition except the hereditary disorders. Scattered or perivascular plasma cells and mast cells are also found in both types of CML.

Necrosis of bone marrow is seen occasionally in aggressive CML.<sup>110-111</sup> This may be associated with the development of a new neoplastic clone and heralds the onset of a blastic crisis. However, necrosis may be encountered in many other conditions.<sup>112-114</sup> In addition, studies on erythroid precursors have demonstrated ineffective erythropoiesis and maturation arrest in a large series of patients with myeloid leukaemias.<sup>115</sup>

As shown in Tables 4 and 7 histological classification of CML is of prognostic value. Cases with prominent megakaryocytosis showed a tendency to develop fibrosis. In contrast to PV, the fibrosis in these cases increases the survival times. Other studies of CML have not demonstrated a correlation between fibre content and duration of survival.<sup>116</sup>

Chronic myeloid leukaemia usually causes some degree of osteopenia. Osteolytic lesions, some associated with imminent blastic transformation have also been described.<sup>74 117-120</sup> In our own studies lytic osseous lesions were observed in association with focal accumulations of megakaryoblasts and megakaryocytes.<sup>74</sup> When the bone marrow histology shows a predominance of granulocyte precursors, there is a greater likelihood of transformation to a blast crisis. Histological studies of bone marrow regeneration after chemotherapy have indicated a significant role for fat cells in the process of haematopoietic repopulation of the marrow. As in PV there is lymphocytic infiltration in the bone marrow (Table 6) and lymphoid nodules have been observed.<sup>121</sup> Malignant lymphomas have also been reported in patients with CML. A classification system, which incorporates both categories of CML as well as myelofibrosis and osteomyeloclerosis has been proposed.<sup>94</sup>

#### MEGAKARYOBLASTIC AND MEGAKARYOCYTIC MYELOSES

These are now recognised as disease entities within the broader framework of the MPD (Table 4). Idiopathic thrombocythaemia corresponds to the mature form (Fig. 5b) of megakaryocytic myelosis, whereas the immature type (Fig. 5a) present initially with either thrombocytopenia, anaemia or pancytopenia (Table 6). In the later stages, the mature as well as the immature forms generally develop into MF or OMS (Table 4 and 7). At first, the bone marrow contains numerous clusters of polymorphic megakaryocytes. Since the production of platelets

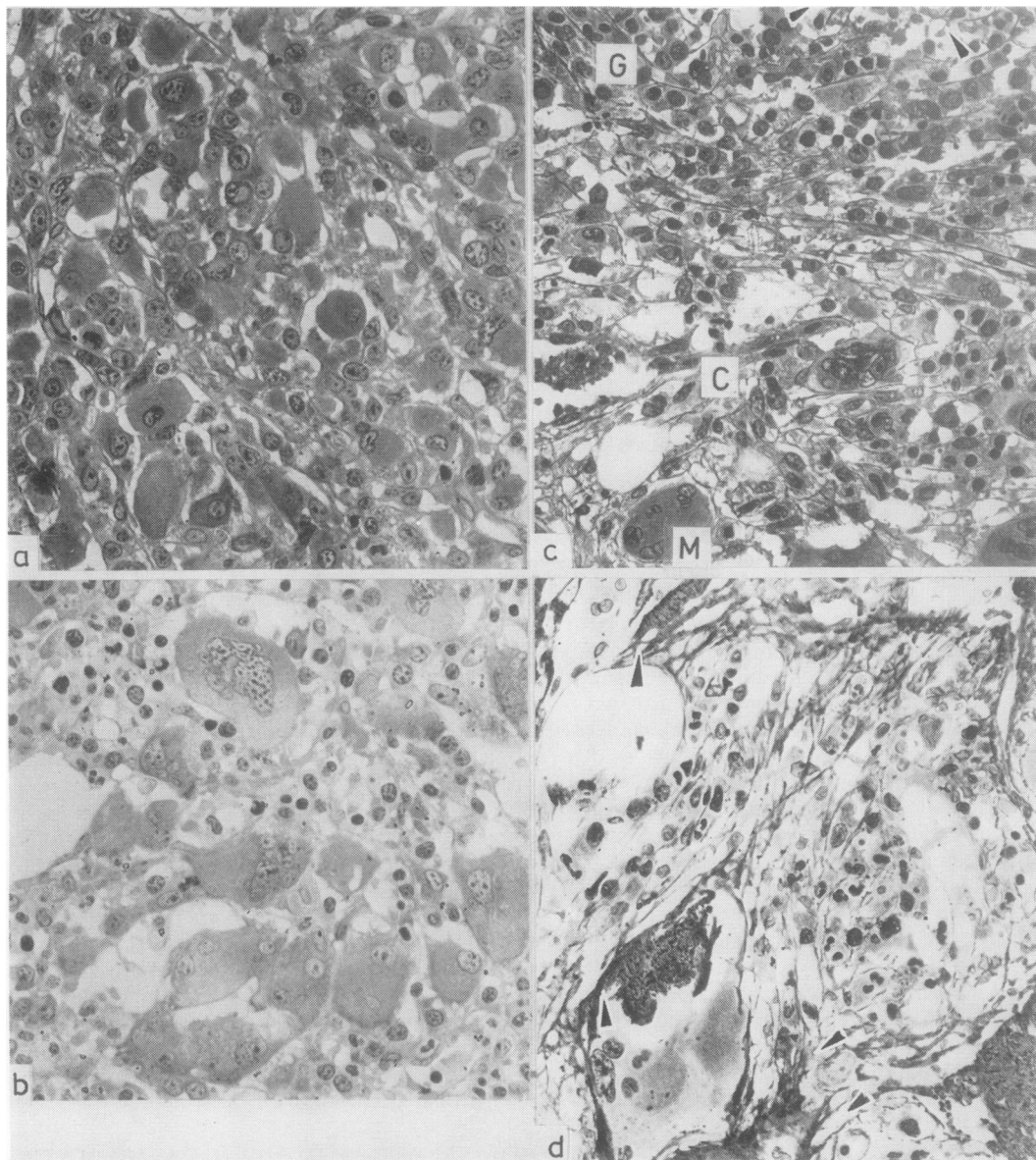


Fig. 5 (a) Immature megakaryocytic myelosis; the haematopoietic marrow has been replaced by megakaryocytes, note fibres and plasma cells (♂ 63 yr) Gomori's stain  $\times 250$ ; (b) mature megakaryocytic myelosis with numerous giant polymorphic megakaryocytes close to sinusoids (♀ 56 yr)  $\times 250$ ; (c) MF after megakaryocytic myelosis; note polymorphic megakaryocytes (M), immature granulocytes (G), lymphocytic infiltration (arrows) and reticular fibres in apposition to capillaries (C) (♂ 75 yr) Gomori's stain  $\times 250$ ; (d) OMS, note fibres and woven bone (arrows), leaving foci of megakaryocytes and granulocytes (♀ 58 yr) Gomori's stain  $\times 250$ .

is a function of the maturity of the megakaryocytes and not only of their number, the platelet count in the peripheral blood reflects the marrow histology. A low count characterises the immature and a high count the mature forms of megakaryocytic myelosis.

#### ACUTE OR MALIGNANT MYELOFIBROSIS

This is generally considered to correspond to the most immature form of megakaryoblastic myelosis (see above). However, there are highly malignant cases of megakaryoblastic myelosis without any

Table 7 Clinical and histological findings in myelofibrosis and osteomyelosclerosis (myeloid metaplasia)

| Patients (n = 184)                           | Myelofibrosis (n = 100)<br>% | Osteomyelosclerosis (n = 84)<br>% |
|--|------------------------------|-----------------------------------|
| <b>Basic myeloproliferative disorders</b>    |                              |                                   |
| Polycythaemia vera                           | 61                           | 54                                |
| Chronic myeloid leukaemia                    | 23                           | 16                                |
| Megakaryocytic myelosis                      | 8                            | 10                                |
| Unclear                                      | 8                            | 18                                |
| Therapy before biopsy: <sup>32</sup> P       | 12                           | 4                                 |
| Busulphan                                    | 8                            | 12                                |
| x-ray of bones: osteoporosis                 | 9                            | 9                                 |
| osteosclerosis                               | 2                            | 41                                |
| <b>Bone marrow histology</b>                 |                              |                                   |
| Haematopoietic tissue (vol %)                | 42 ± 19                      | 23 ± 18                           |
| Fatty tissue (vol %)                         | 9 ± 9                        | 13 ± 14                           |
| Fibrotic tissue (vol %)                      | 6 ± 10                       | 5 ± 4                             |
| Trabecular bone (vol %)                      | 25 ± 5                       | 40 ± 14                           |
| Osteoid (vol %)                              | 1.4 ± 1.7                    | 6.3 ± 7.2                         |
| Primitive bone (vol %)                       | 0 ± 0                        | 16 ± 17                           |
| Oedema (vol %)                               | 7 ± 11                       | 6 ± 6                             |
| Sinuses (vol %)                              | 8 ± 3                        | 7 ± 3                             |
| Megakaryocytes, increased                    | 82                           | 24                                |
| Megakaryocytes, polymorphic                  | 96                           | 89                                |
| Siderin, missing                             | 46                           | 67                                |
| Lymphoid nodules                             | 19                           | 10                                |
| Infiltration of lymphocytes and plasma cells | 85                           | 100                               |

} Means ± SD

fibrosis.<sup>122</sup> There has been some discussion as to whether this is indeed a separate disease entity, and considered with the MPD or with the acute leukaemias.<sup>123–125</sup> A set of strict diagnostic criteria (histological and clinical) for acute malignant myelofibrosis has now been proposed and this has been fulfilled by only a quarter of the cases previously published. These criteria include peripheral pancytopenia with reticulocytosis but without red cell morphology typical for MF; minimal or no splenomegaly, and clinically a rapid downhill course. The bone marrow histology shows hyperplasia and immaturity of all three cell lines and increased reticulin fibres. We have also observed cases of other myeloproliferative disorders, for example PV, in which a fatal pancytopenia developed due to a rapidly progressive bone marrow fibrosis.<sup>4</sup> Acute myelofibrosis may also end in acute myeloblastic leukaemia.<sup>126</sup>

#### MYELOFIBROSIS AND OSTEOMYELOSCLEROSIS (AGNOGENIC MYELOID METAPLASIA)

Fibrosis of the bone marrow is today widely regarded as secondary to a large number of diseases that may afflict the haematopoietic tissues. These include myelo and lymphoproliferative disorders, metastatic neoplasias, inflammatory and granulomatous reactions.<sup>86 127–129</sup> The immediate stimulus for fibrosis is unknown but among others, an immunological mechanism has been postulated. In addition, initiation of fibrosis has been attributed to disorganisation of megakaryopoiesis and venous stasis. Biochemical analysis and quantitative studies of

collagen fibres have shown a correlation between the deposition of collagen and the progression of the disease.<sup>130–132</sup> In the fibrotic marrow areas of MPD, abnormal deposition of platelets and accumulation of necrotic megakaryocytes have been observed.<sup>4 86</sup> This is in accordance with the recent demonstration of a growth factor stimulating fibroblasts, which is released by thrombocytes and megakaryocytes.<sup>133</sup> Whenever possible the presumptive primary cause of the fibrosis should be specified when the diagnosis of MF or OMS is made—for example, MF secondary to PV, to CML etc. The term “agnogenic myeloid metaplasia” would then be confined to those, probably late, cases, in which no putative aetiology is detected. Transformation to a blastic crisis has also been observed in MF.<sup>134</sup>

The data given in Table 7 are based on bone marrow biopsies of 184 patients with myeloproliferative disorders. In most cases of MF and OMS the underlying disease process was identified. Myelofibrosis itself may induce osteoporosis as well as osteolysis,<sup>135 136</sup> and may or may not later evolve into OMS. There are some cases which exhibit the typical picture of OMS from the start: strands of woven bone, attached to the surfaces of the trabeculae or to the perivascular fibre networks, are found intersecting the intertrabecular spaces.

The typical histological findings in early MF are illustrated in Fig. 5c. These include a network of reticular fibres, with bundles of collagen near the blood vessels, dividing the marrow into small compartments. There is hypercellularity with few or no fat cells, and many capillaries. Clusters of

polymorphic or necrotic megakaryocytes are located close to the sclerotic walls of the sinuses, with masses of platelets deposited in the interstitial spaces. Signs of inflammation are also present, and infiltration with lymphocytes, plasma cells and mast cells is always a feature. Mast cells in the bone marrow may be increased in many other conditions.<sup>137</sup> Myelopoiesis is considerably diminished as the disease progresses till finally the normal haematopoietic tissue is completely replaced by a network of interlacing fibre bundles.

Occasionally in MF the iliac crest biopsy shows the typical picture, while foci of haematopoietic hyperplasia with osteolytic lesions are found in other areas. In OMS, there is, in addition, formation of irregular spicules of woven bone as well as progressive thickening of the trabeculae with resultant narrowing of the marrow spaces (Fig. 5b). Though there is a close pathogenic relation between MF and OMS there are differences in the clinical course and the prognosis which is less favourable in OMS. This justifies an early distinction between them, best made by bone biopsy, as the osseous changes on x-ray are late. Early splenectomy may have a favourable influence on prognosis.<sup>138</sup> Whether myelofibrosis, once established, is reversible, is still open to question.<sup>139 140</sup> The occurrence of blastic crisis in MF has also been reported.<sup>134</sup>

Myelofibrosis due to other causes differs in histological appearances. In non-bacterial myelitis the marrow is characterised by a loose network of fibres accompanied by considerable oedema and lympho-

plasma- and mastocytosis. There is a marked reduction in haematopoietic tissue but few megakaryocytes are found and these are small and not in clusters. When fibrosis is the consequence of metastatic carcinoma, the neoplastic cells will generally be found. Difficulty may arise when none is detected and the picture of the fibrosis is then similar to that described above for MF. In these rare instances other parameters will provide the correct diagnosis. Medullary fibrosis in Hodgkin's disease and in malignant lymphoma is distinguished by its looser, more diffuse pattern of fibre bundles encircling groups of cells characteristic for the particular neoplasm.

### Lymphoproliferative disorders

Included under this heading in this review are the non-Hodgkin's malignant lymphomas (ML); multiple myeloma, Hodgkin's disease, and angioimmunoblastic lymphadenopathy. The non-Hodgkin's lymphomas considered are shown in Table 8. There is a good correlation between the frequency of bone marrow involvement in these categories of ML by different centres using the Kiel classification.<sup>141-143</sup> Bone marrow biopsy is an integral part of the investigation of patients with lymphoproliferative disorders.<sup>144</sup> The reported incidence of marrow involvement in non-Hodgkin's lymphomas varies between 16% and 73%. This disparity is due to variations in the size and preparation of biopsies as well as to differences in the progression of the disease at the time of biopsy.

Table 8 Classification of non-Hodgkin's malignant lymphomas according to the proliferating cell system in the bone marrow in 468 patients with bone marrow involvement receiving no treatment before biopsy

| Patients (n = 468)                            | Lymphocytic<br>(n = 167)<br>% | Hairy cells<br>(n = 111)<br>% | Lymphoplasmacytoid<br>(n = 112)<br>% | Centrocytic<br>(n = 28)<br>% | Centrocytic-<br>centroblastic<br>(n = 21)<br>% | Centroblastic and<br>immunoblastic (n = 29)<br>% |
|---|-------------------------------|-------------------------------|--------------------------------------|------------------------------|--|--|
| Lymphadenopathy                               | 69                            | 6                             | 32                                   | 72                           | 90   | 75   |
| Splenomegaly                                  | 55                            | 70                            | 47                                   | 52                           | 43   | 42   |
| Hepatomegaly                                  | 47                            | 47                            | 44                                   | 39                           | 33   | 62   |
| Leukaemic blood picture                       | 98                            | 41                            | 8                                    | 24                           | 0  | 36   |
| Anaemia (Hb < 12 g/dl)                        | 56                            | 83                            | 82                                   | 78                           | 56   | 75   |
| Thrombocytopenia<br>( $< 100 \times 10^9/l$ ) | 37                            | 86                            | 33                                   | 33                           | 22   | 36   |
| Paraproteinaemia                              | 4                             | 0                             | 89                                   | 0                            | 0  | 0  |
| <b>Bone marrow histology</b>                  |                               |                               |                                      |                              |  |  |
| Neoplastic infiltration<br>(vol %)            | 43 ± 20                       | 48 ± 15                       | 30 ± 22                              | 43 ± 26                      | 15 ± 10  | 49 ± 23  |
| Haematopoietic tissue<br>(vol %)              | 15 ± 12                       | 14 ± 11                       | 25 ± 14                              | 15 ± 14                      | 30 ± 13  | 8 ± 12   |
| Trabecular bone<br>(vol %)                    | 22 ± 6                        | 24 ± 6                        | 21 ± 6                               | 24 ± 6                       | 22 ± 4   | 25 ± 7   |
| Fatty tissue (vol %)                          | 13 ± 14                       | 9 ± 10                        | 17 ± 14                              | 13 ± 14                      | 31 ± 18  | 7 ± 10   |
| <b>Proliferation pattern</b>                  |                               |                               |                                      |                              |  |  |
| Diffuse                                       | 43                            | 28                            | 8                                    | 0                            | 0  | 14   |
| Diffuse and nodular                           | 26                            | 51                            | 28                                   | 0                            | 0  | 3  |
| Strictly nodular                              | 5                             | 1                             | 54                                   | 14                           | 100  | 10   |
| Strictly paratrabecular                       | 0                             | 0                             | 0                                    | 39                           | 0  | 0  |

} Means ± SD

Though positive bone marrow findings may be considered as part of the evolution of the disease,<sup>145</sup> the question of marrow involvement by lymphoid neoplasias is complicated because normal lymphocytes circulate through blood,<sup>146</sup> lymph, bone marrow and lymphoid tissues. Malignant cells may also be expected to circulate. There is now evidence for early and extensive lymphocyte circulation in lymphoid malignancies.<sup>147-148</sup> Moreover, the possibility that the bone marrow itself may be the site of origin of some lymphoid neoplasias cannot be excluded.

It is pertinent to remember that the bone marrow is one of the loci for lymphopoiesis in embryonic human development, and possibly also later in life.<sup>149-150</sup> Experimentally it is the source of lymphoid regeneration after destruction of the extramedullary lymphoid tissues. The incidence of normal lymphoid nodules in the bone marrow varies from 4% to 47% in the older age groups.<sup>42-151-152</sup> These nodules are characterised by their sharp borders; they consist of small, mature and slightly polymorphous lymphocytes with a loose network of reticular fibres and numerous capillaries (Fig. 6). They are found especially in patients with chronic myeloproliferative disorders, inflammatory reactions and haemolytic conditions.<sup>153</sup> Should these nodules undergo hyperplasia, differentiation from ML may not be possible on morphological grounds.

From an immunological point of view, B cell lymphomas are more frequently found in the bone marrow than those of T cell lineage.<sup>154-155</sup> Some malignant lymphomas may be detected in the bone marrow when other indications of spread are minimal or absent.<sup>156-157</sup> This is particularly so for hairy cell leukaemia and the immunocytomas (lymphoplasmacytoid lymphomas). In our series of 814 cases, bone marrow biopsy was positive in 96 cases when other indications of lymphoma were still lacking.<sup>158</sup> Cutaneous T cell lymphomas have not yet been reported in bone marrow biopsies.<sup>159</sup> Similarly, in our series of 62 cases with mycosis fungoides no spread of these lymphomas was found in the bone marrow.

The ML are diagnosed and classified according to the findings in an excised lymph node using histology, cytology, cytochemical and immunological markers.<sup>160-167</sup> The same diagnostic criteria may be applied to bone marrow biopsies for the identification of ML. In general, the criteria used are: cytological detail, demonstration of glycoprotein, fibre pattern, and the overall architecture. But though one type of lymphoid cell usually predominates and determines the overall morphology and behaviour, all neoplasms derived from lymphocytes must contain neoplastic cells in various stages of the cell

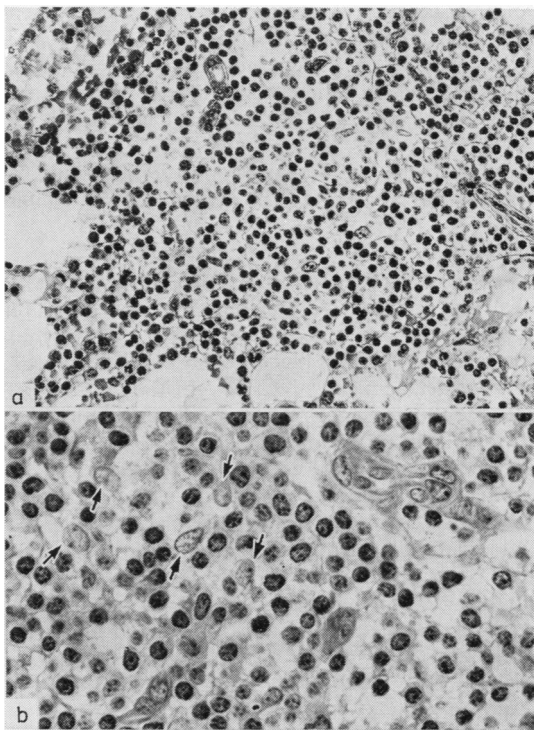


Fig. 6 Normal lymphoid nodule (♀ 47 yr) (a) note the clear demarcation from the surrounding tissues, the marked capillary proliferation and the net of reticulin fibres in the nodule. Gomori's stain  $\times 250$ . (b) as above; the mature slightly polymorphous small lymphocytes are loosely mixed with reticular cells (arrows), plasma- and mast cells, slight enlargement of the capillary endothelia. Giemsa stain  $\times 500$ .

cycle with varying morphological, immunological and behavioural characteristics.<sup>16</sup>

A series of clinical and histological criteria was evaluated in 468 patients with ML and the results are presented in Table 8. Patients with marrow involvement generally had a less favourable prognosis because bone marrow spread detected in a random biopsy means a more generalised disease process. The following variables were prognostic indicators: the type, the maturity, the atypia and the mitotic index of the lymphoid cells, as well as the extent and structural expression of the infiltration (that is, its spatial orientation, diffuse or nodular), the degree of fibrosis and the stromal reaction. Clinically, haemoglobin and platelet counts, reflecting the volume of infiltration (the tumour cell burden), sex and age were also prognostically significant in contrast to spread in lymph nodes and to hepatomegaly which were not. On the other hand, other investigators have not found the type of bone marrow involvement to be a significant prognostic indicator.<sup>168</sup> The frequency

of bone marrow involvement in our series is given in Table 9: there is an overall incidence of 82% in the ML of low grade malignancy and 38% in the ML of high grade malignancy. Bone marrow involvement as such has a different prognostic meaning for each lymphoma type—for example, favourable for the immunocytic, indifferent for the lymphocytic, and unfavourable for the centrocytic-centroblastic type.<sup>143</sup>

#### CHRONIC LYMPHOCYTIC LEUKAEMIA (CLL)

The diagnosis is usually based on persistent lymphocytosis in the peripheral blood, progressive lymphadenopathy, hepatosplenomegaly and absence of paraproteinaemia.<sup>169-173</sup> Early in the course of the disease the bone marrow may be diffusely infiltrated by small round lymphocytes, generally standing out against their normal counterparts by the rod-wheel pattern of the nuclear chromatin and monomorphic appearance (Fig. 7b). In addition there may be focal, mainly nodular, lymphocytic aggregates.<sup>171-173</sup> Both forms progress until finally there is complete obliteration of the normal marrow parenchyma and the intertrabecular spaces are packed with small lymphocytes (Fig. 7a). Osteolytic bone lesions are rare in CLL.<sup>174</sup> As the disease progresses, there is

increasing replacement of the haematopoietic tissues by the typical small lymphocytes, but CLL may also terminate as lymphoblastic, myeloblastic, myelomonocytic and monocytic leukaemia, as well as immunoblastic sarcoma.<sup>175 176</sup>

Statistical analysis of untreated patients has shown that the diffuse and nodular structural forms of CLL in the bone marrow have prognostic significance with a median survival of 34 months for the diffuse and of 115 months for the nodular. In both types there are varying numbers of prolymphocytes and lymphoblasts<sup>177</sup> dispersed among the small lymphocytes, as well as occasional mast cells. The distinction between early CLL and reactive lymphocytosis or normal lymphoid nodules in the bone marrow may not be possible on purely morphological grounds.<sup>178-179</sup> Surface markers then provide a sensitive demonstration of polyclonal or monoclonal B cells. In addition, well vascularised aggregates with clearly defined borders, germinal centres and pleomorphic cell types are more likely to be benign. Indeed, as pointed out by Aisenberg,<sup>180</sup> a bone marrow examination may be as sensitive as surface markers.

#### HAIRY CELL LEUKAEMIA (HCL)

The typical patient presents with anaemia or cyto-

Table 9 *Historical classification of multiple myeloma according to plasma cell maturity in the bone marrow in 220 untreated patients*

|   | Plasmacytic %                   | Plasmablastic % |                  |
|---|---------------------------------|-----------------|------------------|
| Haemoglobin (g/dl) < 8                          | 6                               | 17              |                  |
| 8-12  | 48                              | 81              |                  |
| > 12  | 44                              | 11              |                  |
| Platelets ( $\times 10^9/l$ ) < 200             | 53                              | 80              |                  |
| > 200   | 47                              | 20              |                  |
| Plasma cell mass (vol %)                        | 25 $\pm$ 19                     | 44 $\pm$ 22     | Mean $\pm$ SD    |
| Proliferation pattern: diffuse                  | 46                              | 9               |                  |
| diffuse and nodular                             | 41                              | 43              |                  |
| total   | 13                              | 38              |                  |
| Mitotic activity: low                           | 92                              | 50              |                  |
| intermediate                                    | 8                               | 33              |                  |
| high  | 0                               | 17              |                  |
| Plasma cell atypia: low                         | 99                              | 50              |                  |
| intermediate                                    | 1                               | 29              |                  |
| high  | 0                               | 10              |                  |
| Fibrosis: reticular                             | 92                              | 81              |                  |
| coarse  | 8                               | 19              |                  |
| Haematopoietic tissue (vol %)                   | 22 $\pm$ 13                     | 12 $\pm$ 11     | } Means $\pm$ SD |
| Fatty tissue (vol %)                            | 27 $\pm$ 14                     | 18 $\pm$ 15     |                  |
| Trabecular bone (vol %)                         | 20 $\pm$ 6                      | 20 $\pm$ 5      |                  |
| Osteolytic (< 10 vol %)                         | 8                               | 14              |                  |
| Osteoporotic (10-19 vol %)                      | 48                              | 53              |                  |
| Normal (20-30 vol %)                            | 40                              | 30              |                  |
| Osteosclerotic (> 30 vol %)                     | 3                               | 3               |                  |
| Bone remodelling: osteoclastic index, increased | 72                              | 94              |                  |
| osteoblastic index, increased                   | 49                              | 64              |                  |
|   | <i>Median survival (months)</i> |                 |                  |
| Patients overall                                | 32 (157 patients)               | 8 (63 patients) |                  |
| .. < 25 vol % plasma cell volume                | 36 (66 .. )                     | 21 (9 .. )      |                  |
| .. 25-50 vol % .. ..                            | 29 (65 .. )                     | 12 (33 .. )     |                  |
| .. > 50 vol % .. ..                             | 16 (26 .. )                     | 6 (21 .. )      |                  |



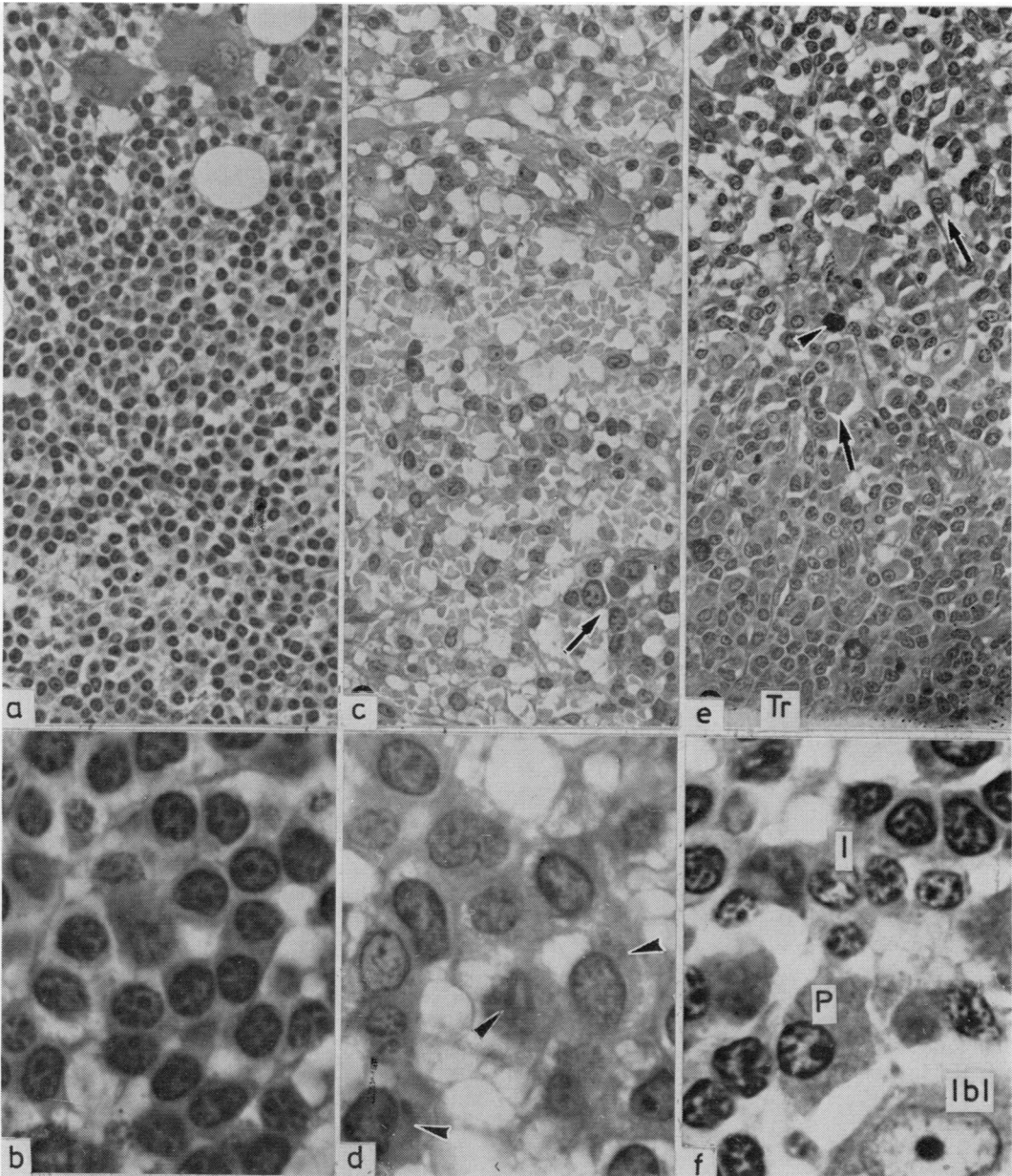


Fig. 7 (a) CLL, note dense infiltration of the marrow with small lymphocytes ( $\delta$  65 yr)  $\times$  250; (b) as above, note monomorphic small lymphocytes with compact nuclear chromatin and single small nucleolus  $\times$  1000; (c) hairy cell leukaemia, infiltration of the marrow by medium-sized lymphoid cells, separated by wide sinusoids and interstitial oedema, note residual erythroblasts (arrow) ( $\delta$  45 yr)  $\times$  250; (d) higher magnification of above, showing typical hairy cells with cytoplasmic inclusions (arrows), possibly the ribosomal lamellar structures seen on EM ( $\delta$  64 yr)  $\times$  1000; (e) immunocytoma, pleomorphic type, note seam of lymphoid cells with irregular nuclei apposed to the trabecular surface (Tr), and plasma cells and mast cells in the central area (arrows) ( $\delta$  58 yr)  $\times$  250; (f) as above, note immunocytes (I), plasma cells (P), and immunoblasts (Ibl)  $\times$  1000.

penia, a relative lymphocytosis and splenomegaly or, rarely, with paraproteinaemia.<sup>181</sup> A tartrate resistant positive acid phosphatase reaction in the peripheral blood lymphoid cells is highly suggestive of, but not specific for HCL.<sup>182</sup> Except in very early cases the bone marrow histology is quite typical, see Fig. 7c and d. The hairy cells have round or oval, coffee-bean or kidney-shaped nuclei whose chromatin, unlike that of small lymphocytes, shows little clumping. The cytoplasm is more abundant than that of the small lymphocyte and is frequently elongated into lateral processes, somewhat reminiscent of reticulum cells. There are usually multiple, poorly delineated foci which have a tendency to confluence with displacement of haematopoietic tissues. The hairy cells are loosely arranged in a network of reticulin fibres in which numerous erythrocytes as well as plasma cells and mast cells are also found. There is progressive loss of fat and haematopoietic tissues and eventually only isolated normal precursors are left. A typical bone marrow appearance is shown in Fig. 7c. Several reviews of HCL have recently appeared.<sup>183-186</sup>

#### IMMUNOCYTOMA (ML LYMPHOPLASMACYTOID)

This lymphoma is characterised in the bone marrow by a morphologically heterogeneous cell population consisting of lymphocytes, lymphoplasmacytoid cells and plasma cells (Fig. 7e and f) with a relatively high content of mast cells. The bone marrow distribution pattern may be diffuse or nodular. When multiple foci are found, these may be separated from the haematopoietic tissues by a band of fat cells. There is a moderate increase in reticulin fibres, but osseous remodelling is hardly affected. In about half of the cases there are PAS-positive inclusions in the cytoplasm, nucleus, or both the lymphoplasmacytoid cells. Three types of immunocytoma have been described: lymphoplasmacytic, which often has a diffuse pattern in the bone marrow, lymphoplasmacytoid, frequently exhibiting a nodular pattern, and the pleomorphic which has a tendency to the "packed marrow" type. There is some overlap between these categories. In addition an immunocytoma occasionally has to be distinguished from CLL with reactive plasmacytosis. A greater volume of infiltration in the bone marrow has a poorer prognosis than a lesser degree of involvement in untreated patients. The clinical and immunological features of this lymphoma have been summarised.<sup>187</sup>

#### CENTROCYTIC (ML FOLLICLE CENTRE CELL)

The almost exclusively paratrabeular accumulation of cleaved lymphoid cells constitutes the typical bone marrow feature of this lymphoma (Fig. 8a and b). As the disease progresses, the paratrabeular seams

widen till eventually the central marrow spaces are also occupied. In contrast to HCL these lymphoid cells have a narrow rim of cytoplasm and are more closely packed, and there is also a fibre network (Fig. 8a and b).

#### CENTROCYTIC/CENTROBLASTIC

In cases of marrow involvement, there are heterogeneous lymphoid aggregates of various sizes, most frequently with, but occasionally without, germinal centres. These aggregates are composed of a mixture of centrocytes, centroblasts and histiocytes, and are located centrally in the marrow spaces (Fig. 8c and d).

#### CENTROBLASTIC AND IMMUNOBLASTIC

These types are illustrated in Fig. 8e and f. In both cases, the bone marrow, when involved, shows a dense infiltration of fairly monomorphic cells, with no particular spatial predilection. Bone marrow involvement in these lymphomas is relatively infrequent and its prognostic significance is not yet established.

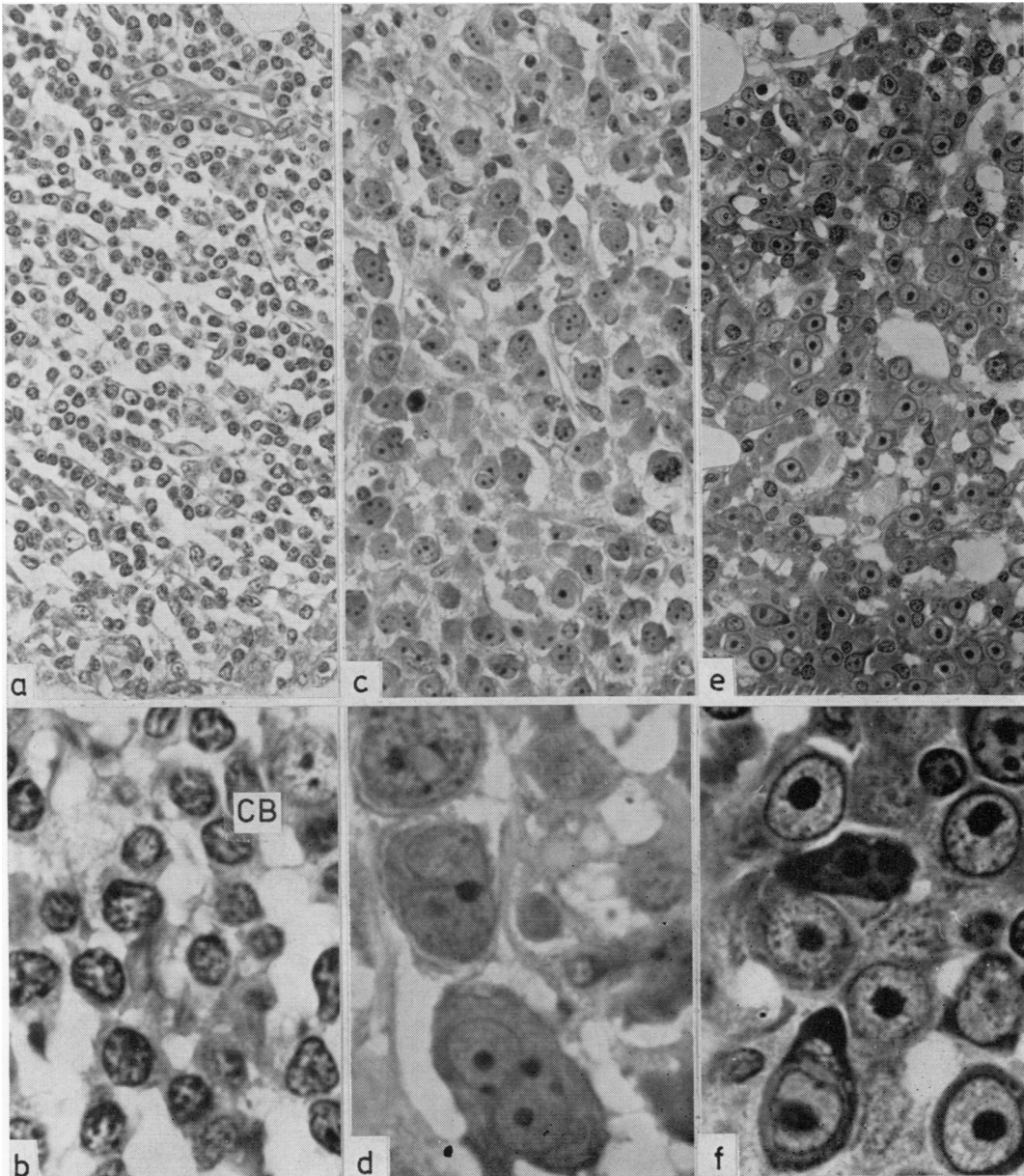
#### MULTIPLE MYELOMA (MM)

The plasma cell is the final end stage in the differentiation of the B lymphocyte. The neoplastic plasma cell frequently secretes immunoglobulins. It also settles in the bone marrow, as normal lymphocytes tend to do. In many cases it stimulates the osteoclasts to produce lytic lesions in the bones by the secretion of osteoclast activating factor.<sup>188</sup> Thus the classic diagnostic trilogy of multiple myeloma is established: there is a paraprotein in the blood, osteolytic lesions in the bones, and more than 30% plasma cells in smears of the aspirates.<sup>189</sup>

However, in many cases the clinical situation is not clear and the need arises to distinguish a reactive plasmacytosis, a benign monoclonal gammopathy<sup>190</sup> and early, atypical or non-secretory multiple myeloma.<sup>191</sup> In these cases marrow histology may establish the diagnosis, since the topographic distribution of the plasma cells is a decisive factor and not only their number. It has recently been shown that plasmacytosis of more than 50% may occur in benign reactive conditions.<sup>192 193</sup>

Numerous studies have been aimed at the cytological and cytochemical features of plasma cells, both benign and malignant. There is no single characteristic which is pathognomonic for a neoplastic plasma cell though a high incidence in any given population of plasma cells may be strongly indicative. It should be noted that circulating small lymphocytes may also be participants in the malignant process in MM.<sup>194</sup>

Few investigations on the histology of the bone marrow in MM have been reported.<sup>195</sup> The results



**Fig. 8** (a) Centrocyclic lymphoma, the bone marrow is infiltrated by small to medium sized lymphoid cells with irregular nuclei, interspersed with the larger centroblasts (♀ 66 yr)  $\times 250$ ; (b) as above, higher magnification showing typical centrocytes, note centroblast (CB)  $\times 1000$ ; (c) centroblastic lymphoma, replacement of normal marrow cells by centroblasts showing large nuclei with a fine chromatin pattern and several small nucleoli, often at the nuclear membrane (♀ 57 yr)  $\pm 250$ ; (d) as above, high magnification showing details of centroblasts  $\times 1000$ ; (e) immunoblastic sarcoma, paratrabeular infiltration by large cells with immature, round nuclei containing a single central nucleolus (♀ 32 yr)  $\times 250$ ; (f) as above, showing immunoblasts, with some variation in size and shape  $\times 1000$ .

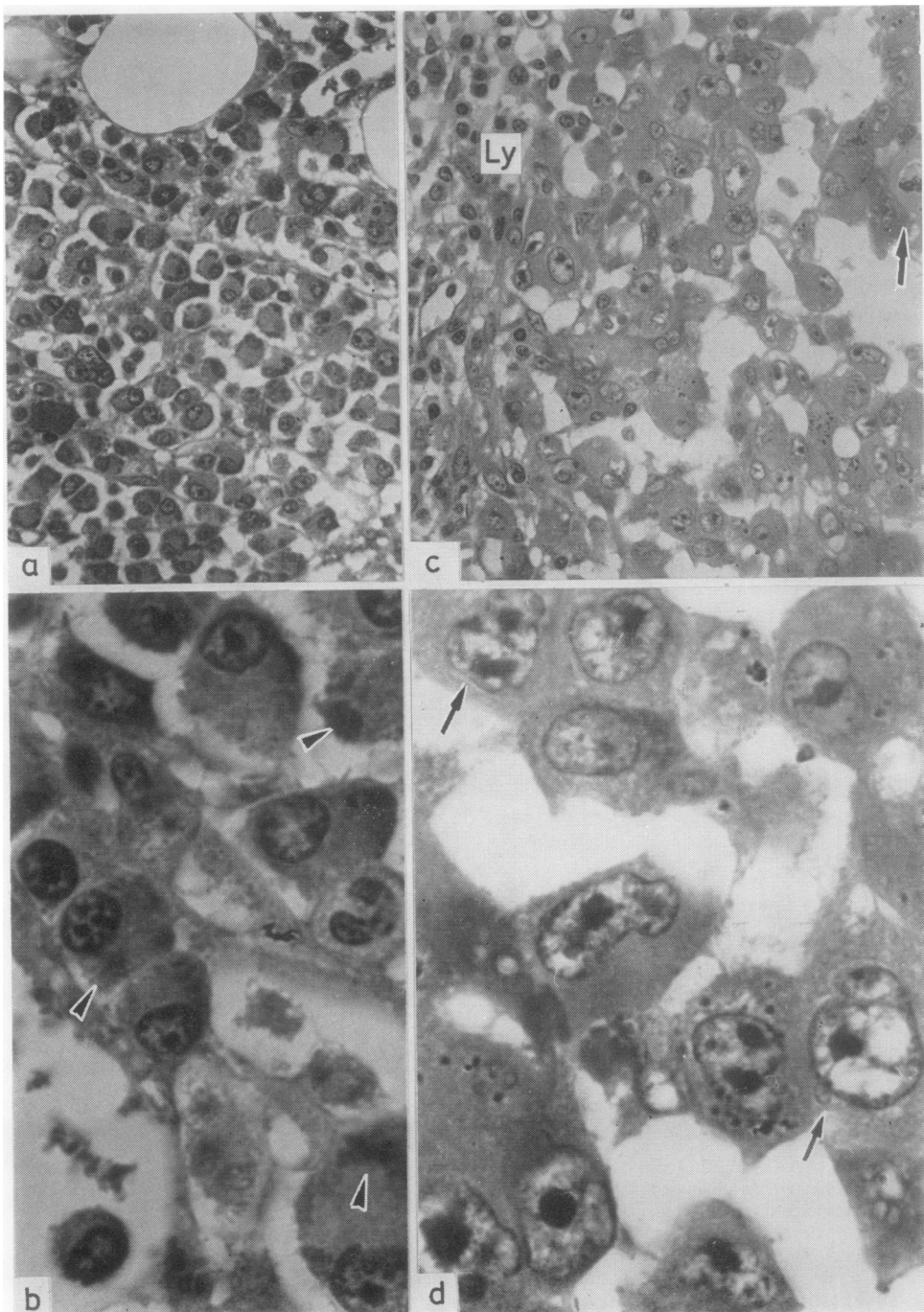


Fig. 9 (a) Multiple myeloma, paratrabecular (not shown) infiltration of typical, slightly polymorphic plasma cells ( $\delta$  74 yr)  $\times 250$ ; (b) as above, higher magnification to show details of the plasma cells, note protein droplets in the cytoplasm (arrows)  $\times 1000$ ; (c) plasmablastic sarcoma, the plasmablasts are large, polymorphic cells with abundant cytoplasm and have large nuclei and nucleoli, note mitotic figure (arrow), the infiltration is demarcated by a band of lymphocytes (Ly) ( $\delta$  52 yr)  $\times 250$ ; (d) as above, note plasmablasts with irregular and indented nuclei (arrows)  $\times 1000$ .

of a study of 220 cases are shown in Table 9 and illustrated in Fig. 9a-d. The following characters were found to indicate malignancy: (i) the arrangement of the plasma cells in small clusters in both perivascular and peritrabecular areas; (ii) the cytology of the plasma cells—such as a high nucleocytoplasmic ratio and asynchronism; (iii) evidence of increased osteoblastic and osteoclastic remodelling and (iv) monoclonality of the plasma cells when tested by means of immunohistology. Furthermore, it was found that the plasma cells could be classified into two major groups: the plasmablastic (Fig. 9c and d) and the plasmacytic (Fig. 9a and b) and the infiltration in the bone marrow into three stages (early, intermediate, advanced) according to the amount of space occupied in the bone marrow sections (Table 9). Both the classification and the staging systems had prognostic value, with a highly significant correlation between these parameters in untreated patients and their survivals (Table 9). The classification of the myeloma cells into plasmablasts and plasmacytes was made on purely cytological grounds. There is some analogy with the distinction drawn between lymphoblasts (or immunoblasts) and small lymphocytes.<sup>177</sup>

#### HODGKIN'S DISEASE (HD)

The pathogenesis of HD remains unclarified, despite the vast amount of research.<sup>176 196 197</sup> Lymphocytic and monocytic origins have been postulated for the specific Reed-Sternberg (R-S) cells and the mononuclear Hodgkin's cells. The balance has swung in favour of a derivation from the mononuclear phagocyte system, though this is by no means universally accepted.

The incidence of bone marrow involvement reported in the literature varies from 2-32%. The bone marrow biopsies from our series of 655 patients including 414 untreated were divided into three groups: negative (552); suspect (18); and involved (85) when R-S cells or mononuclear Hodgkin's cells, or both, were found in an appropriate morphological setting.<sup>198</sup> However, only 21% of the negative group had a normal bone marrow histology. The other pretreatment patients showed various aspects of a non-specific bone marrow reaction ranging from leukaemoid to exudative or "tumour myelopathy" or fatty marrow atrophy. The most frequently encountered was the reaction referred to as "tumour myelopathy."<sup>4 199</sup> This is characterised by maturation arrest of all three cell lines with an increase in numbers of megakaryocytes, plasma cells, eosinophils and mast cells. There is a variable lymphocytic infiltration, as well as increase in iron stores and in reticulin fibres. Other manifestations in the bone marrow, such as acute myelofibrosis and

massive phagocytosis have also been reported.<sup>200-202</sup> Suspect biopsies were characterised by small granulomatous foci in the endosteal regions, consisting of lymphocytes, plasma cells, histiocytes and mast cells within a network of reticular fibres and capillaries. The incidence of these sarcoid-like granulomatous foci was 2%. Positive biopsies were subdivided into four groups on the basis of the bone marrow histology: (i) single focus (found only in very small biopsies); (ii) multiple nodules of 1-4 mm; (iii) confluent areas; (iv) complete occupation of the marrow spaces (Fig. 10a-d).

The positive biopsies were also classified into two groups according to the lymphocyte population: depletion<sup>50</sup> and predominance.<sup>15</sup> Involvement of the bone marrow in the nodular sclerosis type of HD is extremely rare; and there were also too few cases of the mixed type in our series to form a separate group.

Occasionally, angioimmunoblastic lymphadenopathy, malignant histiocytosis and systemic mastocytosis present pictures similar to HD in the bone marrow, but in these cases the typical R-S and Hodgkin's cells are absent. The variability of histological findings in HD has led to the speculation that HD is not a single disease but possibly a number of different diseases or the different evolutionary stages of a disease entity with a very wide spectrum.<sup>203</sup>

#### ANGIOIMMUNOBLASTIC LYMPHADENOPATHY (AILD)

Involvement in the bone marrow is characterised by multiple foci with a heterogeneous cell population consisting of immunoblasts, plasma cells, lymphocytes and eosinophils;<sup>204</sup> there are hyperplastic capillaries, occasionally arborising, within a fine to coarse reticulin framework (Fig. 11a and b). The differentiation of these granulomatous reactions from those occurring in HD (without H or R-S cells) and in rheumatic and allergic conditions is not always possible.<sup>205</sup> Bone marrow involvement is associated with progression of the disease, and denotes an unfavourable prognosis.<sup>206-208</sup>

#### Conclusions

The experience of many centres over the past decade has demonstrated the wide range of conditions now recognised in which a bone biopsy may provide diagnostic and other information required for evaluation of the patient and for understanding of the disease process. The indications stem from many fields including haematology, immunology, oncology, internal medicine and rheumatology and this paper has only provided an overview of some of the haematological disorders.

The development and application of immuno-

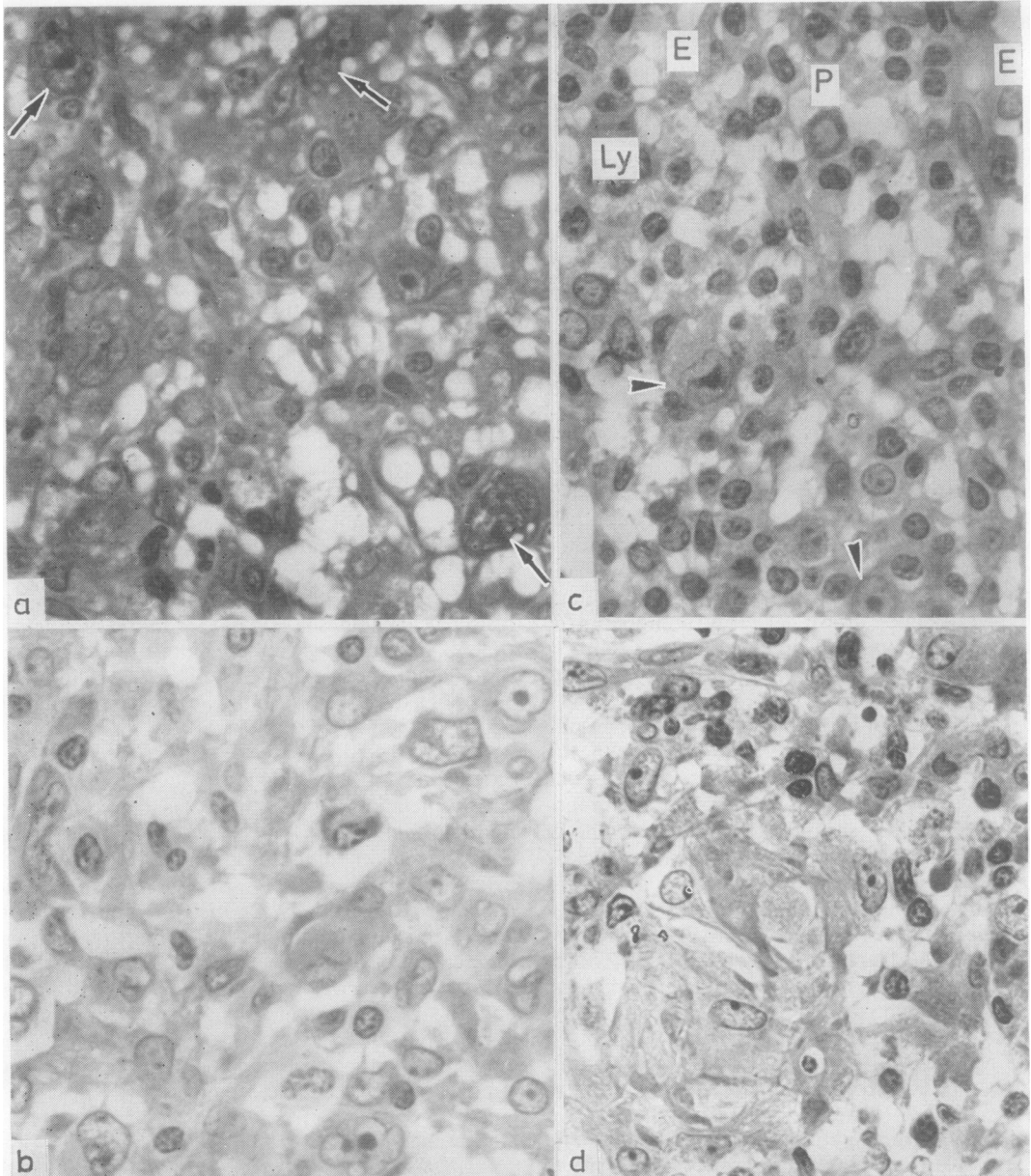


Fig. 10 (a) Hodgkin's disease. Typical bone marrow involvement with many R-S cells (arrows); note numerous capillaries and slight fibrosis ( $\delta$  69 yr)  $\times 500$ ; (b) HD, mixed type, with R-S cells and mononuclear Hodgkin's cells, note histiocytes and plasma cells ( $\delta$  50 yr)  $\times 500$ ; (c) HD, lymphocytic type, note small lymphocytes (Ly), plasma cells (P), endothelial cells with large nuclei (E) and Hodgkin's cells (arrows) ( $\delta$  19 yr)  $\times 500$ ; (d) HD, note small, epithelial foci within typical granulomatous tissue containing lymphocytes, histiocytes and capillaries ( $\delta$  36 yr)  $\times 500$ .

fluorescent, immunoperoxidase and other conjugated marker techniques to frozen sections for the demonstration of cellular constituents and cellular products—for example, surface glycoproteins,

enzymes, hormones and other secretory products, have served to underline the importance of structural and architectural interdependence between cells and cell groups. New insights into morphology and

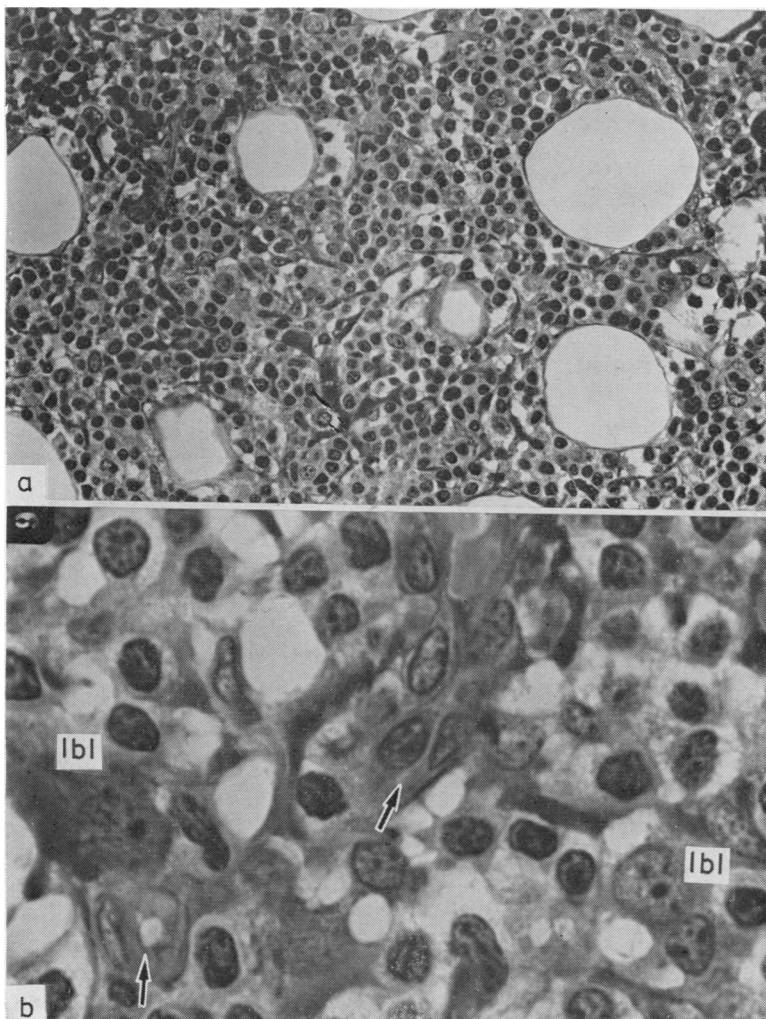


Fig. 11 (a) *Angioimmunoblastic lymphadenopathy, involving the central marrow areas by foci consisting of small lymphocytes, some immunoblasts, many capillaries, interstitial PAS-positive protein deposits and moderate fibrosis* (♀ 71 yr)  $\times 220$ ; (b) *as above, higher magnification showing lymphocytic infiltration, immunoblasts (lbi), and capillaries (arrows)*  $\times 1000$ .

cellular interrelations are emerging from these functional approaches and they require the highest degree of excellence attainable in histopathology. For bone and bone marrow this is undoubtedly obtained by the use of plastic embedding. A combination of these techniques in future should elucidate many processes whose mechanisms are not as yet clarified but which may be investigated in the human bone marrow. Among these are normal and abnormal haematopoiesis, osteogenesis and the production of the other elements of connective tissues.

Note: Pressure of space has not permitted the inclusion of tabulated bibliographies on bone biopsies in the conditions dealt with in this review. These are available from the authors.

#### References

- Byrnes RK, McKenna RW, Sundberg RD. Bone marrow aspiration and trephine biopsy. An approach to a thorough study. *Am J Clin Pathol* 1978;**70**:5:753-9.
- Delacretaz F, Schmidt PM. Combined cytological-histological examination of bone marrow experience with 200 patients. *Schweiz Med Wochenschr* 1979; **109**:13-8.
- Campuzano G, Bedoya MV, Restrepo MA, Maya LLM. Usefulness of bone-marrow biopsy in hematology. *Sangre (Barc)* 1978;**23**:138-48.
- Burkhardt R. Bone marrow and bone tissue. *Color atlas of clinical histopathology*. Berlin, Heidelberg, New York: Springer-Verlag, 1971.
- Duhamel G. *Histopathologie clinique de la moelle osseuse*. Paris: Masson, 1974.
- Block M. *Text-atlas of hematology*. Philadelphia: Lea and Febiger, 1976.
- Rywin AM. *Histopathology of the bone marrow*. Boston:

- Little, Brown and Company, 1976.
- <sup>8</sup> Dancy JT, Brubaker LH. Neutrophil marrow profiles in patients with rheumatoid arthritis and neutropenia. *Br J Haematol* 1979;**43**:607-17.
  - <sup>9</sup> Jamshidi K, Swaim WR. Bone marrow biopsy with unaltered architecture: a new biopsy device. *J Lab Clin Med* 1971;**77**:335-42.
  - <sup>10</sup> Landys R, Stenram V. Bone marrow biopsy of the posterior iliac crest with Gidlund instrument in malignant diseases. *Scand J Haematol* 1975;**15**:104-8.
  - <sup>11</sup> Helleberg-Rasmussen I, Sondergaard-Petersen H. Bone marrow biopsy with the Bordier trephine. *Scand J Haematol* 1975;**14**:123-8.
  - <sup>12</sup> Zambarnard J, Block M, Vatter A, Trenner L. An adaption of methacrylate embedding for routine histopathologic use. *Blood* 1969;**33**:444-50.
  - <sup>13</sup> Difford J. A simplified method for the preparation of methylmethacrylate embedding medium for undecalcified bone. *Med Lab Technol* 1974;**31**:79-81.
  - <sup>14</sup> Dancy JT, Deubelbeiss KA, Harker LA, Greenaway J. Section preparation of human marrow for light microscopy. *J Clin Pathol* 1976;**29**:704-10.
  - <sup>15</sup> TeVelde J, Burkhardt R, Kleiverda K, Leenheers-Binnendijk L, Sommerfeld W. Methyl-methacrylate as an embedding medium in histopathology. *Histopathology* 1977;**1**:319-30.
  - <sup>16</sup> Olah AJ, Simon A, Gandy J, Hermann W, Schenk RK. Differential staining of calcified tissues in plastic embedded microtome sections by a modification of Movats pentachrome stain. *Stain Technol* 1977;**52**:331-7.
  - <sup>17</sup> Beckstead JH, Ries CA, Bainton DF. Rapid processing of a single bone marrow biopsy specimen for 1  $\mu$ m plastic (JB-4) sections for staining with romanovsky-type dyes for enzyme histochemistry and subsequent electron microscopy (EM). *Am J Clin Pathol* 1979;**72**:649-50.
  - <sup>18</sup> Bartl R, Burkhardt R, Vondracek H, Sommerfeld W, Hagemeyer E. Rationelle Beckenkamm-Biopsie: Längsteilung der Proben zur Anwendung von mehreren Präparationsverfahren ohne Materialverlust. *Klin Wochenschr* 1978;**56**:545-50.
  - <sup>19</sup> Whitehouse WJ. Cancellous bone in the anterior part of the iliac crest. *Calcified Tissue Research* 1977;**23**:67-76.
  - <sup>20</sup> Nordin BEC, Peacock M, Aaron J *et al.* Osteoporosis and osteomalacia. In: Avioli LV, Raisz LG, eds. *Metabolic bone disease. Clinics in endocrinology and metabolism*. London, Philadelphia, Toronto: Saunders, 1980;**9**:177-206.
  - <sup>21</sup> Raina V. Normal osteoid tissue. *J Clin Pathol* 1971;**25**:229-32.
  - <sup>22</sup> Kerndrup G, Pallesen G, Melsen F, Mosekilde L. Histo-morphometrical determination of bone marrow cellularity in iliac crest biopsies. *Scand J Haematol* 1980;**24**:110-4.
  - <sup>23</sup> Robertson JH, Burnside P, Salmon DC. Marrow hypoplasia with splenomegaly in adolescence. *J Clin Pathol* 1980;**33**:730-4.
  - <sup>24</sup> Ferrant A, Rodhain J, Cordier A, Symann M, Michaux JL, Sokal G. Selective hypoplasia of pelvic bone marrow. *Scand J Haematol* 1980;**25**:12-8.
  - <sup>25</sup> Miller SC, Jee WSS. The microvascular bed of fatty bone marrow in the adult beagle. *Met Bone Dis Rel Res* 1980;**2**:239-46.
  - <sup>26</sup> Demmler K, Burkhardt R. Relations between fatty tissue, cancellous bone and vascular pattern of the iliac bone in aplastic anaemia. In: Haessig A, ed. *Bibl Haematol* 1978;**45**:109-17.
  - <sup>27</sup> Boggs DR. The hematopoietic microenvironment. *N Engl J Med* 1980;**302**:1359-60.
  - <sup>28</sup> Tavassoli M. The marrow-blood barrier. *Br J Haematol* 1979;**41**:297-302.
  - <sup>29</sup> Werts ED, Gibson DP, Degowin RL. Chronic inflammation suppresses bone marrow stromal cells and medullary erythropoiesis. *J Lab Clin Med* 1979;**93**:995-1003.
  - <sup>30</sup> Gordon MY, King JA, Gordon-Smith EC. Bone marrow fibroblasts fat cells and colony-stimulating activity. *Br J Haematol* 1980;**46**:151-2.
  - <sup>31</sup> Castro-Malaspina H, Gay RE, Resnick G *et al.* Characterisation of human bone marrow fibroblast colony forming cells (CFUF) and their progeny. *Blood* 1980;**56**:289-301.
  - <sup>32</sup> Ash P, Loutit JF, Townsend S. The versatile haematopoietic stem cell as source of osteoclasts. *Br J Haematol* 1980;**45**:172.
  - <sup>33</sup> Rave DJ, Hausmann E. Quantitative analyses of osteoclast changes in resorbing bone agar cultures. *Calcified Tissue Research* 1977;**23**:283-9.
  - <sup>34</sup> Coccia PF, Krivit, W, Cervenka J *et al.* Successful bone marrow transplantation for infantile malignant osteopetrosis. *N Engl J Med* 1980;**302**:701-8.
  - <sup>35</sup> Rasmussen H, Bordier P. *The physiological and cellular basis of metabolic bone disease*. Baltimore: Williams and Wilkins Co, 1974:8-70.
  - <sup>36</sup> Chambers TJ. Cellular basis of bone resorption. *Clin Orthop* 1980;**151**:283-93.
  - <sup>37</sup> Owen M. Origin of bone cells in the postnatal organism. *Arthritis Rheum* 1980;**23**:1073-80.
  - <sup>38</sup> Abramson S, Miller RG, Phillips RA. The identification in adult bone marrow of pluripotent and restricted stem cells of the myeloid and lymphoid systems. *J Exp Med* 1977;**145**:1567-99.
  - <sup>39</sup> Burkhardt R, Bartl R, Demmler K, Kettner G. Zwölf histobiologische Thesen zur Pathogenese der primären und sekundären Osteoporose. *Klin Wochenschr* 1981;**59**:5-18.
  - <sup>40</sup> Joffey JM. Transitional cells of hematopoietic tissues: origin, structure and development potential. *Int Rev Cytol* 1980;**62**:311-59.
  - <sup>41</sup> Raisz LG. What marrow does to bone. *N Engl J Med* 1981;**304**:1485-6.
  - <sup>42</sup> Burkhardt R, Bartl R, Jäger K, Ehret W, Schlag R, Demmler K. Histobiologische Knochenmarksbeurteilung im Senium. In: Böhnel J, Heinz R, Stacher A, eds. *Hämatologie im Alter*. München, Berlin, Wien: Urban & Schwarzenberg, 1982;20-8.
  - <sup>43</sup> Krause JR, Brubaker D, Kaplan S. Comparison of stainable FE in aspirated and needle biopsy specimens of bone marrow. *Am J Clin Pathol* 1979;**72**:68-70.
  - <sup>44</sup> Bezwoda WR, Bothwell Th, Torrance JD *et al.* The relationship between marrow iron stores plasma ferritin concentrations and iron absorption. *Scand J Haematol* 1979;**22**:113-20.
  - <sup>45</sup> Krause JR, Stoll V. Serum ferritin and bone marrow biopsy iron stores. *Am J Clin Pathol* 1980;**74**:461-4.
  - <sup>46</sup> Heidreich D, Charron D, D'Athis P, *et al.* Quantitative study of marrow adipocytes in marrow aplasia. *Pathol Biol (Paris)* 1979;**27**:215-7.
  - <sup>47</sup> TeVelde J, Haak HL. Histology of bone marrow failure, a follow-up study in aplastic anaemia. In: Heimpel H, Gordon-Smith EC, Heit W, Kubanek B, eds. *Aplastic anemia: pathophysiology and approaches to therapy*. Berlin, Heidelberg, New York Springer-Verlag, 1979;**24**:15-25.
  - <sup>48</sup> Ehret W, Schlag, R, Burkhardt R. The causative and prognostical bearing on the aplastic syndrome of inflammatory bone marrow changes. Sixth Meeting International Society Haematology European and



- African Division, Athens, Greece, August 30-September 4, 1981.
- <sup>19</sup> Duhamel G, Muratore R, Bryon P, Horechovsky N. Histologic prognosis in aplastic anemia. In: Haessig A, ed. *Bibl Haematol* 1978;**45**:87-95.
  - <sup>50</sup> Sullivan R, Quesenbury PJ, Parkman R *et al*. Aplastic anaemia: lack of inhibitory effect of bone marrow lymphocytes on in vitro granulopoiesis. *Blood* 1980; **56**:625-32.
  - <sup>51</sup> Silver BJ, Zuckerman KS. Aplastic anemia. Recent advances in pathogenesis and treatment. *Med Clin North Am* 1980;**64**:607-29.
  - <sup>52</sup> Fitchen JH, Cline MJ. Recent developments in understanding the pathogenesis of aplastic anemia. *Am J Hematol* 1978;**5**:365-72.
  - <sup>53</sup> Hagler L, Pastore RA, Bergin JA, Wrensch MR. Aplastic anaemia following viral hepatitis: report of two fatal cases and review of the literature. *Medicine* 1975;**54**: 139-64.
  - <sup>54</sup> Hill DR, Benak SB, Phillips TL, Price DC. Bone marrow regeneration following fractionated radiation therapy. *Int J Radiat Oncol Biol Phys* 1980;**6**:1149-55.
  - <sup>55</sup> Burkhardt R, Bartl R, Beil E, Kronseder A. Bone marrow and nutritional anemia. Indian German Symposium on Hematology, Hyderabad, India, 3-7 March 1975.
  - <sup>56</sup> Anonymous. Refractory anaemia. *Br Med J* 1980;**281**: 528-9.
  - <sup>57</sup> Block M, Jacobsen LO, Bethard WF. Preleukemic acute human leukemia. *JAMA* 1953;**152**:1018-28.
  - <sup>58</sup> Schmalz F, Hellriegel KP. *Preleukemia*. Berlin, Heidelberg, New York: Springer, 1979.
  - <sup>59</sup> Koefler HP, Golde DW. Human preleukemia. *Ann Intern Med* 1980;**93**:347-53.
  - <sup>60</sup> Streuli RA, Testa JR, Vardiman JW, Mintz U, Golomb HM, Rowley JD. Dysmyelopoietic syndrome: Sequential clinical and cytogenetic studies. *Blood* 1980;**55**: 636-44.
  - <sup>61</sup> Thiele J, Vykoupil KF, Georgii A. Chronic myelomonocytic leukemia light and electron-microscopy of the bone marrow. *Blut* 1979;**39**:177-90.
  - <sup>62</sup> Roth DG, Richman CM, Rowley JD. Chronic myelodysplastic syndrome (preleukemia) with the Philadelphia chromosome. *Blood* 1980;**56**:262-4.
  - <sup>63</sup> Hull MT, Griep JA. Mixed leukemia, lymphatic and myelomonocytic. *Am J Clin Pathol* 1980;**74**:473-5.
  - <sup>64</sup> Thiele J, Vykoupil KF, Georgii A. Myeloid dysplasia (MD): a hematological disorder preceding acute and chronic myeloid leukemia. A morphological study on sequential core biopsies of the bone marrow in 27 patients. *Virchows Arch [Pathol Anat]* 1980;**389**:343-68.
  - <sup>65</sup> Yeung K, Trowbridge AA. Idiopathic acquired sideroblastic anemia terminating in acute myelofibrosis. Case report and review of literature. *Cancer* 1977;**39**:359-65.
  - <sup>66</sup> Catovsky D, O'Brien M, Costello C. The value of ultrastructural cytochemistry in defining patterns of differentiation in blast cells. *Br J Haematol* 1980;**46**: 326-7.
  - <sup>67</sup> Tobelen G, Jacquillat C, Chastaing *Cet al*. Acute monoblastic leukemia: a clinical and biologic study of 74 cases. *Blood* 1980;**55**:71-6.
  - <sup>68</sup> Kana MB, Maurer HS, Ferenc C. Subclassification of acute lymphoplastic leukaemia in children: analysis of the reproducibility of morphologic criteria and prognostic implications. *Br J Haematol* 1980;**44**:383-8.
  - <sup>69</sup> Straus DJ, Mertelsman R, Kozimer B *et al*. The acute monocytic leukemias: multidisciplinary studies in 45 patients. *Medicine* 1980;**59**:409-25.
  - <sup>70</sup> van Rhenen DJ, Verhulst JC, Huijgens PC, Langenhuijsen MMAC. Maturation index: a contribution to quantitation in the FAB classification of acute leukaemia. *Br J Haematol* 1980;**46**:581-6.
  - <sup>71</sup> Islam A, Catovsky D, Goldman JM, Galton DAG. Histological study of chronic granulocytic leukaemia in blast transformation. *Br J Haematol* 1980;**46**:326.
  - <sup>72</sup> Sjogren U. Bone marrow morphology in acute eosinophilic monocytic leukemia. *Acta Haematol* 1979;**62**:17-9.
  - <sup>73</sup> Islam A, Catovsky D, Galton DAG. Histological study of bone marrow regeneration following chemotherapy for acute myeloid leukaemia and chronic granulocytic leukaemia in blast transformation. *Br J Haematol* 1980; **45**:535-40.
  - <sup>74</sup> Burkhardt R. Bone marrow histology. In: Catovsky D, ed. *The leukemic cell*. London, Melbourne, New York: Churchill Livingstone, 1981:49-86.
  - <sup>75</sup> Thiele J, Vykoupil KF, Hoffmann G, Perschke G, Georgii A. Myeloid dysplasia: follow-ups in histopathology of the bone marrow and clinical course of so called preleukemias. 5th Meeting International Society Haematology, Hamburg, FRG, 26-31 August 1979.
  - <sup>76</sup> Robinson LL, Sather HN, Coccia PF, Nesbit ME, Hammond GD. Pretreatment characteristics of 936 children with previously untreated acute lymphoplastic leukemia diagnosed from 1972-1975. *Am J Haematol Oncol* 1980;**2**:5-13.
  - <sup>77</sup> Mertelsmann R, Thaler HT, To L *et al*. Morphological classification, response to therapy and survival in 263 adult patients with acute non-lymphoblastic leukemia. *Blood* 1980;**56**:773-81.
  - <sup>78</sup> Whittaker JA, Reizenstein P, Callender ST *et al*. Long survival in acute myelogenous leukaemia: an international collaborative study. *Br Med J* 1981;**282**:692-5.
  - <sup>79</sup> Leimert JT, Burns CP, Wiltse CG, Armitage JO, Clarke WR. Prognostic influence of pretreatment characteristics in adult lymphoblastic leukemia. *Blood* 1890; **56**:510-5.
  - <sup>80</sup> Okita H, Block M. Osteomalacic new bone formation during chemotherapy of acute granulocytic leukemia. *Am J Pathol* 1979;**71**:645-50.
  - <sup>81</sup> Burkhardt R. Myelogene Osteopathien. In: Kuhlencordt F, Bartelheimer H, eds. *Erkrankungen der Knochen, Gelenke und Muskeln. Handbuch der Inneren Medizin* Vol 6, Teil I. Berlin, Heidelberg, New York: Springer-Verlag, 1980:1057-188.
  - <sup>82</sup> Manoharan A, Horsley R, Pitney WR. Reticulin content of bone marrow in acute leukemia in adults. *Br J Haematol* 1979;**43**:185-90.
  - <sup>83</sup> Dameshek W. Some speculations on the myeloproliferative syndromes. *Blood* 1951;**6**:372-5.
  - <sup>84</sup> Ward HP, Block MH. Natural history of agnogenic myeloid metaplasia AMM and a critical evaluation of its relationship with the myeloproliferative syndrome. *Medicine* 1971;**50**:357-420.
  - <sup>85</sup> Gilbert HS. The spectrum of myeloproliferative disorders. In: Rubin AD, ed. *Clinical signs of blood disease. The Medical Clinics of N America* Vol 57/2. Philadelphia, London, Toronto: WB Saunders, 1973:355-93.
  - <sup>86</sup> Burkhardt R, Bartl R, Beil E, *et al*. Myelofibrosis-Osteomyelosclerosis Syndrome. Review of literature and histomorphology. In: Burkhardt R, Conley CL, Lennert K, Adler SS, Pincus T, Till JE, eds. *Advances in the biosciences* Vol 16. Vieweg: Pergamon Press, 1975: 9-56.
  - <sup>87</sup> Reed RE. Polycythemia vera and agnogenic myeloid metaplasia. *Med Clin North Am* 1980;**64**:667-81.
  - <sup>88</sup> Petit JE, Lewis SM, Nicholas AW. Transitional myeloproliferative disorder. *Br J Haematol* 1979;**43**:167-84.
  - <sup>89</sup> Polliack A, Prokocimer M, Matzner Y. Lymphoblastic leukemia transformation (lymphoblastic crisis) in

- myelofibrosis and myeloid metaplasia. *Am J Hematol* 1980;**9**:211-20.
- <sup>90</sup> Adamson JW, Fialkow PJ. The pathogenesis of myeloproliferative syndromes. *Br J Haematol* 1978;**38**:299-303.
- <sup>91</sup> Ratnoff WD, Gress RE. Familial occurrence of PV: report of a father and son. *Blood* 1980;**56**:233-6.
- <sup>92</sup> Dodsworth H. Primary thrombocythaemia in monozygotic twins. *Br Med J* 1980;**280**:1506.
- <sup>93</sup> Brodsky I. The differential diagnosis of the polycythemic states. *Ann Clin Lab Sci* 1980;**10**:311-9.
- <sup>94</sup> Georgii A, Vykoupil KF, Thiele J. Chronic megakaryocytic myelosis—CMGM: a subtype of chronic myeloid leukemia. *Virchows Arch [Pathol Anat]* 1980;**389**:253-68.
- <sup>95</sup> Kurnick JE, Mahmood T, Napoli N, Block MH. Extension of myeloid tissue into the lower extremities in polycythemia. *Am J Clin Pathol* 1980;**74**:427-43.
- <sup>96</sup> Vykoupil KF, Thiele J, Stangel W, Krmptovic E, Georgii A. Polycythemia vera. I. Histopathology, ultrastructure and cytogenetics of the bone marrow in comparison with secondary polycythemia. *Virchows Arch [Pathol Anat]* 1980;**389**:307-24.
- <sup>97</sup> Roberts BE, Woods GG, Miles DW, et al. Bone changes in polycythemia vera and myelofibrosis. *J Clin Pathol* 1969;**22**:696-700.
- <sup>98</sup> Burkhardt R, Cirl C, Bartl R, Jäger K. 193 histobiopic case controls in 58 polycythemic patients in the course of 2-15 years. Fifth Meeting International Society Haematology, Hamburg FRG 26-31 August 1979.
- <sup>99</sup> Vykoupil KF, Thiele J, Stangel W, Krmptovic E, Georgii A. Polycythemia vera. II. Transgression towards leukemia with special emphasis on histological differential diagnosis, cytogenetics and survival. *Virchows Arch [Pathol Anat]* 1980;**389**:325-42.
- <sup>100</sup> Taberner DA, Chang J, Otridge BW. Coexistent chronic lymphatic leukemia with polycythemia vera. *Postgrad Med J* 1977;**53**:222-3.
- <sup>101</sup> Berk PD, Goldberg JD, Silverstein MN et al. Increased incidence of acute leukemia in polycythemia vera associated with chlorambucil therapy. *N Engl J Med* 1981;**304**:441-7.
- <sup>102</sup> Chusid MJ, Dale PC, West BG, Wolff SM. The hypereosinophilic syndrome: analysis of 14 cases with review of the literature. *Medicine (Baltimore)* 1975;**54**:1-27.
- <sup>103</sup> Presentey B, Jerushalmy L, Mintz U. Eosinophilic leukaemia: morphological cytochemical and electromicroscopic studies. *J Clin Pathol* 1979;**32**:261-71.
- <sup>104</sup> You WV, Weisbrot IM. Chronic neutrophilic leukemia report of 2 cases and review of literature. *Am J Clin Pathol* 1979;**72**:233-42.
- <sup>105</sup> Dancy JT, Vadnais-Metz LH. A quantitative assessment of neutrophil marrow in seven patients with chronic granulocytic leukaemia. *Br J Haematol* 1978;**39**:325-38.
- <sup>106</sup> Dosik H, Rosner F, Sawitsky A. Acquired lipidosis: Gaucher-like cells and "blue cells" in chronic granulocytic leukemia. *Semin Hematol* 1972;**9**:309-16.
- <sup>107</sup> Kitchens CS. Clinical observation of human bone marrow macrophages. *Medicine* 1977;**56**:503-14.
- <sup>108</sup> Milder MS, Cook JD, Stray S, Finch CA. Idiopathic hemochromatosis; an interim report. *Medicine* 1980;**59**:34-49.
- <sup>109</sup> Tachibana F, Hakozaiki H, Takahashi K, Kojima M, Enomoto S, Wada J. Syndrome of the sea-blue histiocyte—the first case report in Japan and review of the literature. *Acta Pathol Jpn* 1979;**29**:73-97.
- <sup>110</sup> Lee Ch, Morris TCM. Bone marrow necrosis and extramedullary myeloid tumour necrosis in aggressive chronic myeloid leukemia. *Pathology* 1979;**11**:551-6.
- <sup>111</sup> Bain B. Extensive bone marrow infarction followed by myelofibrosis in a patient with Ph<sup>+</sup> positive chronic granulocytic leukaemia. *J Clin Pathol* 1980;**33**:449-53.
- <sup>112</sup> Conrad ME, Carpenter JT. Bone marrow necrosis. *Am J Hematol* 1979;**7**:181-9.
- <sup>113</sup> Leysen MHJ, Verwilghen RL. Diagnosis of bone marrow necrosis. *Clin Lab Haematol* 1979;**1**:197-202.
- <sup>114</sup> Cowan JD, Rubin RN, Kies MS, Cerezo L. Bone marrow necrosis. *Cancer* 1980;**46**:2168-71.
- <sup>115</sup> Sjögren U. Morphologic studies on erythropoietic part of the bone marrow in myeloid leukemias. *Scand J Haematol* 1979;**22**:61-6.
- <sup>116</sup> Clough V, Geary CG, Hashmi K, Davson J, Knowlson T. Myelofibrosis in chronic granulocytic leukaemia. *Br J Haematol* 1979;**42**:515-26.
- <sup>117</sup> Habner CBA, Haskill CM, Canellos GP. Destructive bone lesions in chronic granulocytic leukemia. *Medicine (Baltimore)* 1969;**48**:401-10.
- <sup>118</sup> Rizzo SC, Fontana G, Ricevuti G, Baldini CL. Osteolytic lesions in chronic granulocytic leukemia: report of 4 cases. *Haematology* 1977;**62**:61-74.
- <sup>119</sup> Mora JJ, Heron JF, L'Hirondel JC, Loyau G. Lesion osteolytique au cours de la leucémie myéloïde chronique. *Nouv Presse Méd* 1979;**8**:3171.
- <sup>120</sup> Walther RM, Greenberg BR. Hypercalcemia in the accelerated phase of chronic myelogenous leukemia. *Cancer* 1980;**46**:1174-8.
- <sup>121</sup> Hernandez NL, Sureder MM, Granena A, et al. Bone marrow lymphoid follicles in MF compared with CML. *Nouv Rev Fr Hematol* 1979;**21**:251-6.
- <sup>122</sup> Demmler K, Burkhardt R, Prectel K. Megakaryoblastische Myelose. *Klin Wochenschr* 1970;**48**:1168-73.
- <sup>123</sup> Patel AR, Shah PC, Rhee HL. Acute myelofibrosis and acute myeloblastic leukaemia. *Br Med J* 1976;**2**:1232.
- <sup>124</sup> Bird T, Proctor SJ. Malignant myelosclerosis: myeloproliferative disorder or leukemia? *Am J Clin Pathol* 1977;**67**:512-20.
- <sup>125</sup> Bearman RM, Pangalis GA, Rappaport H. Acute (malignant) myelosclerosis. *Cancer* 1979;**43**:279-93.
- <sup>126</sup> Weisenberger DD. Acute myelofibrosis terminating as acute myeloblastic leukemia. *Am J Clin Pathol* 1980;**73**:128-32.
- <sup>127</sup> Anonymous. Myelofibrosis. *Lancet* 1980;**8160**:127-9.
- <sup>128</sup> Georgii A, Thiele J, Vykoupil KF. Osteomyelofibrosclerosis: a histological and cytogenetic study on core biopsies of the bone marrow. *Virchows Arch [Pathol Anat]* 1980;**389**:269-86.
- <sup>129</sup> Golde DW, Hocking WG, Quan SG, Sparkes RS, Gale RP. Origin of human bone marrow fibroblasts. *Br J Haematol* 1980;**44**:183-7.
- <sup>130</sup> Dumont J, D'Athis P. Quantitative study of the medullary fibrosis in 84 cases of idiopathic myeloid splenomegaly. *Pathol Biol (Paris)* 1979;**27**:221-6.
- <sup>131</sup> Goasguen J, Mignot J, Quennehen F et al. Quantitation of myelofibrosis in blood diseases by electronic image analysis. *Nouv Rev Fr Hematol* 1979;**21**:17-29.
- <sup>132</sup> Charron D, Robert L, Couty MC, Binet JL. Biochemical and histological analysis of bone marrow collagen in myelofibrosis. *Br J Haematol* 1979;**41**:151-61.
- <sup>133</sup> Groopman JE. The pathogenesis of myelofibrosis in myeloproliferative disorders. *Ann Intern Med* 1980;**92**:857-8.
- <sup>134</sup> Thiele J, Vykoupil KF, Georgii A. Ultrastructure of blastic crisis in osteomyelofibrosis. A report of 2 cases with some unusual features. *Virchows Arch [Pathol Anat]* 1980;**389**:287-306.
- <sup>135</sup> Leimert JT, Armitage JD, Dick FR. Myeloid metaplasia and osteolytic lesions. *Am J Clin Pathol* 1978;**70**:706-8.
- <sup>136</sup> Kosmidis PA, Palacos CG, Axelrod AR. Diffuse pure

- osteolytic lesions in myelofibrosis. *Cancer* 1980;**46**: 2263-5.
- <sup>137</sup> Lennert K, Parwaresch MR. Mast cells and mast cell neoplasia: a review. *Histopathology* 1979;**315**:349-65.
- <sup>138</sup> Silverstein MN, Re-Mine WH. Splenectomy in myeloid neutropenia. *Blood* 1979;**53**:515-18.
- <sup>139</sup> Ben-Bassat J, Pinchas S, Ugenski M. Splenectomy in patients with agnogenic myeloid metaplasia. *Br J Haematol* 1979;**42**:207-14.
- <sup>140</sup> Kelemen E, Kraznai G, Endes P, Szinay G. Chronic idiopathic myelofibrosis. A reversible disease? *Acta Haematol Pol* 1977;**57**:171-7.
- <sup>141</sup> Brittinger G, Bartels H, Burger A, et al. Grundlagen und bisherige Ergebnisse der prospektiven Studie der Kieler Lymphomgruppe über Non-Hodgkin-Lymphome. In: Stacher A, Höcker P, eds. *Lymphknotentumoren Pathophysiologie, Klinik und Therapie*. München, Wien, Baltimore: Urban und Schwarzenberg, 1979:103-200.
- <sup>142</sup> Georgii A. Classification of non-Hodgkin lymphomas from biopsies of the bone marrow with special emphasis to their spread. In: Crowther DG, ed. *Advances in medical oncology. Research and education VII: "Leukemia and non-Hodgkin lymphoma."* Oxford: Pergamon Press, 1979:179-88.
- <sup>143</sup> Burkhardt R, Bartl R, Zettl R, Hill W, Jäger J, Frisch B. The significance of single large scale bone marrow biopsies in malignant lymphoma, myeloma and metastatic growth. XII International Cancer Congress, Buenos Aires, Argentina, 5-10 October 1978.
- <sup>144</sup> Rosenberg AS. Non-Hodgkin's lymphoma—Selection of treatment on the basis of histologic type. *N Engl J Med* 1979;**301**:924-8.
- <sup>145</sup> Risdall R, Hoppe RT, Warake R. Non-Hodgkin's lymphomas. A study of the evolution of the disease based on 92 autopsied cases. *Cancer* 1979;**44**:529-42.
- <sup>146</sup> Garret JV, Scarffe JH, Newton RK. Abnormal peripheral blood lymphocytes and bone marrow infiltration in non-Hodgkin's lymphoma. *Br J Haematol* 1979;**42**: 41-50.
- <sup>147</sup> Engeset A, Bremer K, Froland SS. The cellularity of peripheral lymph in lymphomas. In: Mayall RC, White MH, eds. *Progress in lymphology*. New York: Plenum Press, 1977:245-50.
- <sup>148</sup> Ault KA. Detection of small numbers of monoclonal B lymphocytes in the blood of patients with lymphoma. *N Engl J Med* 1979;**300**:1401-5.
- <sup>149</sup> Griffiths DA. Radioautographic studies of the lymphocytic bone marrow. *Blood* 1969;**34**:696-700.
- <sup>150</sup> Pearl ER, Vogler JL, Okos AJ, et al. B lymphocyte precursors in human bone marrow: an analysis of normal individuals and patients with antibody-deficiency states. *J Immunol* 1978;**120**:1169-75.
- <sup>151</sup> Rywlin AM, Ortega RS, Dominguez CJ. Lymphoid nodules of the bone marrow: normal and abnormal. *Blood* 1974;**43**:389-400.
- <sup>152</sup> Brunning RD, McKenna RW. Bone marrow manifestations of malignant lymphoma and lymphoma-like conditions. In: Saumery SC, Rosen PP, eds. *Pathology annual*. New York: Appleton-Century Crofts, 1979: 1-57.
- <sup>153</sup> Burkhardt R, Zettl R, Bartl R. Significance of non-specific changes of the bone marrow tissues—from the bioptic viewpoint. Fourth Meeting International Society of Haematology, European and African Division, Istanbul, Turkey 5-9 September 1977.
- <sup>154</sup> Bloomfield CD, Kersey JH, Brunning RD, et al. Prognostic significance of lymphocytic surface markers and histology in adult non-Hodgkin's lymphoma. *Cancer Treat Rep* 1977;**61**:963-70.
- <sup>155</sup> Foucar K, McKenna RW, Frizzera G, Brunning RD. Incidence and patterns of bone marrow and blood involvement by lymphoma in relationship to the Lukes-Collins classification. *Blood* 1979;**54**:1417-22.
- <sup>156</sup> Staples WG, Gétaz EP. Bone marrow involvement in malignant lymphoma without peripheral lymphadenopathy. *S Afr Med J* 1977;**52**:60-63.
- <sup>157</sup> Reimer RR, Chalmer BA, Young RC, Reddick R, Johnson RE. Lymphoma presenting in bone: results of histopathology. Staging and therapy. *Ann Intern Med* 1977;**87**:50-5.
- <sup>158</sup> Bartl R, Burkhardt R. The expression of malignant lymphoma in the bone marrow biopsy. Post Congress Meeting International Academy of Pathology, Budapest, Hungary, 21-24 September 1980.
- <sup>159</sup> Safai B, Good RA. Lymphoproliferative disorders of the T cell series: a review. *Medicine* 1980;**59**:335-50.
- <sup>160</sup> Lennert K, Mohri N, Stein H, Kaiserling E, Müller-Hermelink HK. Malignant lymphomas. Other than Hodgkin's disease. Berlin, Heidelberg, New York: Springer-Verlag, 1978.
- <sup>161</sup> Lukes RJ, Parker JW, Taylor CR, Tindle BH, Cramer AD, Lincoln TL. Immunologic approach to non-Hodgkin lymphomas and related leukemias. Analysis of the results of multiparameter studies of 425 cases. *Semin Hematol* 1978;**15**:322-51.
- <sup>162</sup> Habeshaw JA, Carcley PF, Stansfield AG, Brearley RL. Surface phenotyping, histology and the nature of non-Hodgkin lymphoma in 157 patients. *Br J Cancer* 1979;**40**:11-34.
- <sup>163</sup> Mann RB, Jaffe ES, Berard CW. Malignant lymphomas a conceptual understanding of morphologic diversity: a review. *Am J Pathol* 1979;**94**:105-75.
- <sup>164</sup> Nathwani BN. A critical analysis of the classifications of non-Hodgkin's lymphomas. *Cancer* 1979;**44**:347-84.
- <sup>165</sup> Kossiga AL. Advances in adult non-Hodgkin's lymphoma: current concept of classification, diagnosis and management. *Arch Intern Med* 1980;**140**:1647-51.
- <sup>166</sup> Lennert K, Stein H. *Histopathology of non-Hodgkin's lymphomas (based on the Kiel classification)*. Berlin, Heidelberg, New York: Springer-Verlag, 1981.
- <sup>167</sup> Robb-Smith AHT, Taylor CR. *Lymph node biopsy*. London: Heyden & Son, 1981.
- <sup>168</sup> Leonard R. Haematological assessment and prognosis in non-Hodgkin's lymphomas. *Br J Haematol* 1980;**46**: 332.
- <sup>169</sup> Rai KR, Sawitsky A, Cronkite EP, Chanana AD, Levy RN, Pasternack BS. Clinical staging of chronic lymphocytic leukemia. *Blood* 1975;**46**:219-34.
- <sup>170</sup> Hernandez-Nieto L, Montserrat-Costa E, Muncunill J, Rozman C. Bone marrow patterns and clinical staging in chronic lymphocytic leukaemia. *Lancet* 1977;**1**:1269.
- <sup>171</sup> Binet JL, Leporrier M, Dighiero G, et al. A clinical staging system for chronic lymphocytic leukemia. Prognostic significance. *Cancer* 1977;**40**:855-864.
- <sup>172</sup> Gray JL, Jacobs A, Block M. Bone marrow and peripheral blood lymphocytosis in the prognosis of chronic lymphocytic leukemia. *Cancer* 1974;**33**:1169-78.
- <sup>173</sup> Lipshutz MD, Mir R, Rai KR, Sawitsky A. Bone marrow biopsy and clinical staging in chronic lymphocytic leukemia. *Cancer* 1980;**46**:1422-7.
- <sup>174</sup> McMillan P, Mundy G, Mayer P. Hypercalcaemia and osteolytic bone lesions in CLL. *Br Med J* 1980;**281**: 1107.
- <sup>175</sup> Villeneuve B. Termination of CLL-Richter's syndrome. *Union Med Can* 1976;**105**:255-7.
- <sup>176</sup> Taylor CR. Multiple myeloma and CLL-pathologic aspects. In: Horrobin DF, ed. *Hodgkin's disease and the lymphomas* Vol 3. Edinburgh: Churchill Livingstone,

- 1979:152.
- <sup>177</sup> Dubner HN, Crowley JJ, Schilling RF. Prognostic value of nucleoli and cell size in chronic lymphocytic leukemia. *Am J Hematol* 1978;**4**:337-41.
- <sup>178</sup> Mennemeyer RP, Kjeldsberg CR. Isolated lymphoid hyperplasia of the bone marrow stimulating malignant lymphoma. *Am J Clin Pathol* 1976;**65**:45-8.
- <sup>179</sup> Duhamel G, Najman A, Gorin NC *et al.* Lymphomas of the spleen and bone marrow lymphoid nodules. *Sem Hop Paris* 1979;**55**:35-6:1575-80.
- <sup>180</sup> Aisenberg AC. Current concepts in immunology: cell surface markers in lymphoproliferative disease. *N Engl J Med* 1981;**304**:331-6.
- <sup>181</sup> Cawley JC, Burns GF, Bevan A *et al.* Typical hairy cell leukaemia with IgGκ paraproteinaemia. *Br J Haematol* 1979;**43**:215-21.
- <sup>182</sup> Katayama I, Yang JPS. Tartrate resistant acid phosphatase reactions are not specific for HCL. *Am J Clin Pathol* 1979;**71**:482.
- <sup>183</sup> Hahner U, Burkhardt R. Knochenmarksdiagnostik bei Haarzell-Leukaemie. *Klin Wochenschr* 1977;**55**:933-44.
- <sup>184</sup> Turner A, Kjeldsberg CR. Hairy cell leukemia: a review. *Medicine* 1978;**57**:477-99.
- <sup>185</sup> Bouroncle BA. Leukemic reticulo endotheliosis: hairy cell leukemia. *Blood* 1979;**53**:417-36.
- <sup>186</sup> Noseda G, Reiner M, Scali G. Haarzell-Leukämie und Myelom. *Schweiz Med Wochenschr* 1980;**110**:1494-8.
- <sup>187</sup> Levine AM, Lichtenstein A, Gresik MV, Taylor CR, Feinstein DI, Lukes RJ. Clinical and immunologic spectrum of plasmacytoid lymphocytic lymphoma without serum monoclonal IgM. *Br J Haematol* 1980;**46**:225-34.
- <sup>188</sup> Mundy GR, Raisz LG, Cooper RA *et al.* Evidence for the secretion of an osteoclast stimulating factor in myeloma. *N Engl J Med* 1974;**291**:1041-6.
- <sup>189</sup> Nawab RA, Azar HA. Laboratory diagnosis of plasma cell myeloma and related disorders. *Orthop Clin North Am* 1979;**10**:391-404.
- <sup>190</sup> Carter A, Tatarski I. Physiopathologic significance of benign monoclonal gammopathy: a study of 64 cases. *Br J Haematol* 1980;**46**:565-74.
- <sup>191</sup> Joyner MV, Cassuto JP, Dujardin P, *et al.* Non-excretory multiple myeloma. *Br J Haematol* 1979;**43**:559-66.
- <sup>192</sup> Canale DD, Collins RD. Use of bone marrow particle sections in the diagnosis of multiple myeloma. *Am J Clin Pathol* 1974;**61**:383-92.
- <sup>193</sup> Hyun BH, Kwa D, Gabaldon H, Ashton JK. Reactive plasmacytic lesions of the bone marrow. *Am J Clin Pathol* 1975;**65**:921-8.
- <sup>194</sup> Holm G, Millstedt H, Pettersson D, Biberfeld P. Idiopathic immunoglobulin structures on blood lymphocytes in human plasma cell myeloma. *Transplant Rev* 1977;**34**:139-64.
- <sup>195</sup> Bartl R, Burkhardt R, Gierster P, Sandel P, Fateh-Moghadam A. Significance of bone marrow biopsy in the multiple myeloma. In: Haessig A, ed. *Bibl Haematol* 1978;**45**:38-49.
- <sup>196</sup> Stuart AE. Pathogenesis of Hodgkin's disease. *J Pathol* 1978;**126**:239-54.
- <sup>197</sup> Gutensohn N, Cole P. Childhood social environment and Hodgkin's disease. *N Engl J Med* 1981;**304**:135-40.
- <sup>198</sup> Lukes RJ. Criteria for involvement of lymph node, bone marrow, spleen and liver in Hodgkin's disease. *Cancer Res* 1971;**31**:1755-69.
- <sup>199</sup> Burkhardt R, Frisch B, Bartl R, Binsack T, Zettl R. Cellular and structural correlates of metastatic spread in human bone marrow. A study of 320 cases. XII Congress of International Academy of Pathology, Jerusalem, Israel 10-15 September 1978.
- <sup>200</sup> Morgan E, Pang KM, Goldwasser E. Hodgkin's Disease and red cell aplasia. *Am J Hematol* 1978;**5**:17-75.
- <sup>201</sup> Korman LY, Smith JR, Landau SA, Davey FR. Hodgkin's disease: intramedullary phagocytosis with pancytopenia. *Ann Intern Med* 1979;**91**:60-1.
- <sup>202</sup> Duhamel G, Stachowiak J, Monteiro M *et al.* Massive medullary foci of Hodgkin's disease and acute myelofibrosis. *Nouv Presse Med* 1979;**8**:1061-4.
- <sup>203</sup> Taylor CR. Immunopathology of Hodgkin's disease. In: van den Tweel, *et al.* eds. *Malignant lymphoproliferative diseases*. Leiden: Leiden University Press, 1980: 399.
- <sup>204</sup> Pangalis GA, Moran EM, Rappaport H. Blood and bone marrow findings in angioimmunoblastic lymphadenopathy. *Blood* 1978;**51**:71-83.
- <sup>205</sup> Schnaidt U, Vykoupil KF, Thiele J, Georgii A. Angioimmunoblastic lymphadenopathy. Histopathology of bone marrow involvement. *Virchows Arch [Pathol Anat]* 1980;**389**:369-80.
- <sup>206</sup> Bamberg M, Donhuijsen K, Höher PG, Holfeld H, Hossfeld DK. Malignant progression of angioimmunoblastic lymphadenopathy. *J Cancer Res Clin Oncol* 1979;**93**:255-64.
- <sup>207</sup> Ironside P, Cornell FN. Immunoblastic lymphadenopathy. A clinicopathological study of 16 cases. *Pathology* 1979;**11**:27-37.
- <sup>208</sup> Brearley RL, Chapman J, Cullen MH, Horton MA, Stansfeld AG, Waters AH. Haematological features of angioimmunoblastic lymphadenopathy with dysproteinaemia. *J Clin Pathol* 1979;**32**:356-60.

Requests for reprints to: Professor Dr R Burkhardt, Klinikpavillon, Ziemssenstr. 1, 8000 München 2, West Germany.