

Technical method

Nasal brushing for the study of ciliary ultrastructure

JONATHAN RUTLAND, ANN DEWAR,* THERESA COX, PETER COLE *Host Defence Unit, Department of Medicine, Cardiothoracic Institute, Brompton Hospital, Fulham Road, London SW3 6HP and the *Electron Microscopy Unit, Cardiothoracic Institute, Fulham Road, London SW3 6HP*

Examination of cilia for structure and function may be included in the investigation of patients with recurrent nasal or pulmonary disease or both. In recent years a number of defects of ciliary structure and function have been described. These may be hereditary (primary) as in Kartagener's syndrome¹ or acquired (secondary) as may follow local inflammation.² These findings have prompted a search for further defects and the need for quantification of the range of ciliary structure which may be found in normal subjects. Most previous studies have used nasal mucosal biopsies but the relative invasiveness of this procedure has limited the number of samples available for study in both normal subjects and patients. Rutland and Cole described a non-invasive technique employing nasal brushing suitable for the study of ultrastructure and ciliary beat frequency³ and we now report in detail the method used for electron microscopy.

Material and methods

Samples of ciliated epithelium were obtained from the deep surface of the inferior nasal turbinate under direct vision using a 2 mm diameter nylon brush.³ This procedure has been approved by the Brompton Hospital Ethics Committee and over 700 brushings have been performed without significant morbidity (three minor nose bleeds; one vasovagal faint). Tissue yield was increased by having the patient blow his nose to clear excess secretions and by wetting the brush in isotonic saline before the procedure. After brushing adherent epithelium was dislodged by brisk agitation directly into a round-bottomed plastic tube (internal diameter 9.2 mm, length 75 mm) containing 3 ml 2.5% glutaraldehyde in cacodylate buffer. Small strips of epithelium (up to 1 mm) were seen easily—an indirect light source and a black background were used where necessary. The procedure did not require local anaesthesia and could

be repeated immediately from the same or another site in the same area until sufficient tissue was visible in the tube—two or three brushings were frequently taken. Rinsing the brush after each brushing prevented nasal irritation from fixative remaining on the brush. Very occasionally a small amount of surface bleeding occurred in inflamed mucosa in which case the contralateral nasal cavity was sampled.

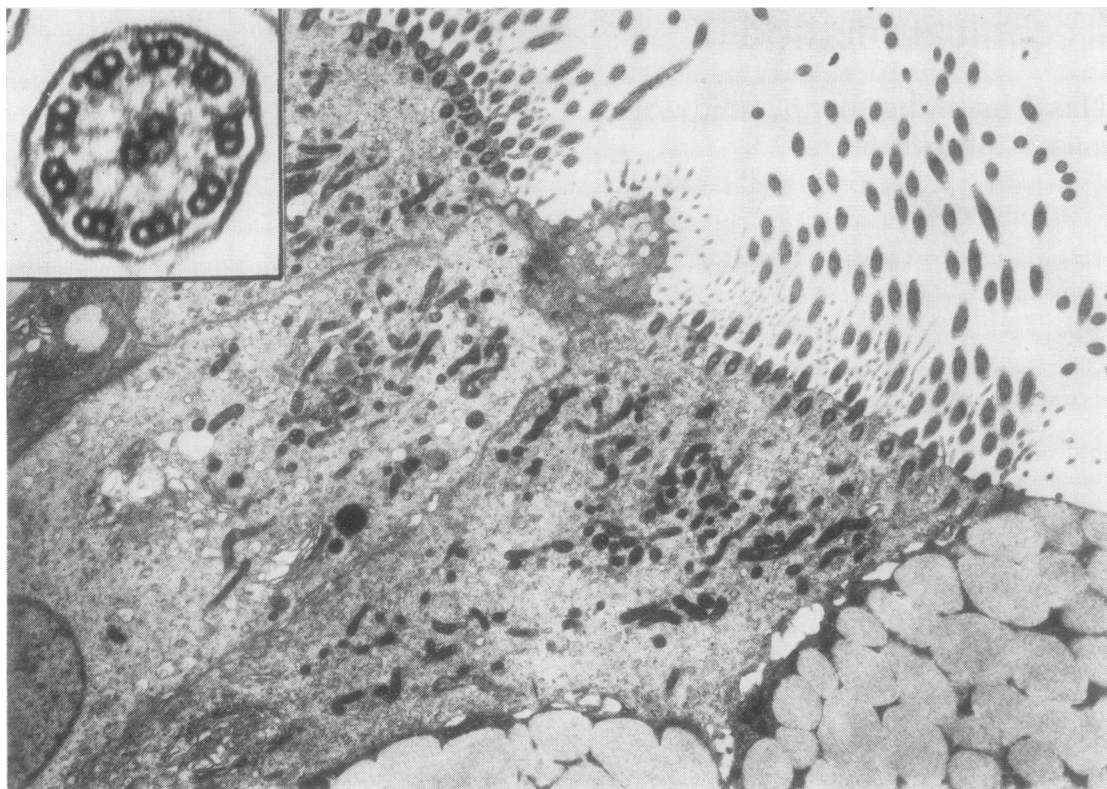
Specimens were fixed for 2-3 h at room temperature during which time the epithelial brushings settled to the bottom of the tube. Supernatant glutaraldehyde was removed and, after three changes of cacodylate buffer, the specimen was post-fixed with osmium tetroxide for 1 h followed by a water rinse. If settling was incomplete at any of these stages the tube was centrifuged gently.

After removal of the water (a small amount remained between the pieces of tissue) the tubes were wedged in a rack to prevent floating and placed in a water bath at 42°C. Using a Pasteur pipette one drop of liquid 2% agar at 42°C was mixed with the specimen and left to settle for 3 min before being solidified at 4°C. After removal of the agar-embedded specimen with a small cup-shaped spatula it was handled as a conventional piece of tissue with standard processing: dehydration, propylene oxide, propylene oxide and Araldite (1:1) and Araldite infiltration. Prior to Araldite-embedding any large areas of excess agar were trimmed and the remainder cut into two or three pieces to be embedded as usual. Subsequent handling and examination of the specimen was with standard methods.

Results and discussion

Use of the techniques described provides transverse and longitudinal sections of cilia with clear ultrastructural detail. We have found these specimens more satisfactory than nasal biopsies and fixation, as indicated by cell organelles, is not impaired (Figure). Tissue damage caused by forceps, such as crushing, does not occur with brushing.

We have studied 30 normal subjects and over 100 patients. Patient acceptance has been good and repeat studies have been performed in many instances (no patient has refused a second brushing). Adequate epithelial brushings are often more difficult to obtain in the presence of nasal suppuration, especially in patients with cystic fibrosis and Kartagener's syndrome. In this situation particular attention to nose blowing and nasal suction removes secretions allowing the epithelium to be brushed more effectively. The technique described is suitable for processing epithelial brushings from other parts of the respiratory tract. The use of a sheathed cytology



Electronmicrograph of epithelial cells obtained by nasal brushing showing ciliary profiles $\times 6150$. Inset shows ultrastructural detail of a normal cilium $\times 155\,000$.

brush at fibreoptic bronchoscopy allows sampling of tracheal and bronchial epithelium. In any patient with an endotracheal tube in situ tracheal brushings may be obtained without bronchoscopy. The use of a sinuscope permits the sampling of sinus epithelium.

A typical section contained approximately 50 ciliated cells with about 3000 ciliary profiles adequate for determining the incidence of compound cilia. About 300 were suitable for studying microtubular structure and, of these, approximately 5% were suitable for the study of dynein arms. A goniometer stage was not available for these studies. Where necessary, further sections may be cut from deeper levels of each block. Over 80% of our brushings produced satisfactory samples.

In sections being used for ultrastructural study of cilia only a minority of the ciliary profiles are ever cut at a suitable angle for optimal detail to be seen. The orientation of specimens is important with nasal biopsies. Nasal brushings, however, can be treated as a cell suspension while still providing as many cilia suitable for study. In any one section there are always some cilia cut at an angle suitable for examining

ultrastructural detail. Cell structure, as well as that of cilia, may be studied in epithelial brushings.

A variety of ultrastructural ciliary abnormalities have been described in the last decade but measurements of the incidence of such abnormalities in patient groups and in normal subjects are needed before the significance of such findings is clear.² Epithelial brushings obtained as described above are suitable for both ultrastructural studies to elucidate this problem and for the measurement of ciliary beat frequency in samples obtained at the same time from the same site.

In conclusion, we suggest that the technique of nasal brushing and agar embedding of the tissue obtained allows non-invasive sampling of ciliated epithelium which can be repeated if required. This method is a suitable screening technique, can be used for young children and facilitates quantification of the incidence of ciliary defects in normal and patient groups to an extent not previously possible.

We thank Dr Bernard Fox for reviewing the manu-

script and the Wellcome Trust for support. JR is supported by Berk Pharmaceuticals Limited and is in receipt of a travel grant from the Postgraduate Medical Foundation, University of Sydney.

References

- ¹ Eliasson R, Mossberg B, Camner P, Afzelius BA. The immotile-cilia syndrome. A congenital ciliary abnormality as an etiologic factor in chronic airway infections and male sterility. *N Engl J Med* 1977;**297**:1-6.
- ² Fox B, Bull TB, Arden GB. Variations in the ultrastructure of human nasal cilia including abnormalities found in retinitis pigmentosa. *J Clin Pathol* 1980;**33**:327-35.
- ³ Rutland J, Cole P. Non-invasive sampling of nasal cilia for measurement of beat frequency and study of ultrastructure. *Lancet* 1980;ii:564-5.

Requests for reprints: Dr J Rutland, Respiratory Unit, Concord Hospital, Sydney NSW 2139, Australia

Technical method

A new bone marrow biopsy needle with core securing device

ANWARUL ISLAM *MRC Leukaemia Unit, Royal Postgraduate Medical School, Hammersmith Hospital, Ducane Road, London W12 0HS*

The value of bone marrow biopsy in haematological as well as non-haematological malignant conditions is well established¹⁻⁴ but the problems of crushing and inadequate sample size remain the major limitations of most biopsy instruments. In order to obtain an adequate core of marrow tissue many instruments have been devised⁵⁻⁹ and the Jamshidi needle is the most recent addition to this group of instruments.⁹ It is widely used for core biopsy of the posterior iliac crest, but in about half the cases, the sample fractures while it is being extracted and only the outer portion is retrieved. Furthermore, in a small number of cases the core is not severed at its base and the whole specimen is left in situ as the needle is withdrawn, thus necessitating a second or third attempt to secure an adequate sample.

I have designed an instrument* with which it is possible consistently to obtain specimens of adequate size (2.1 mm in diameter and 18-20 mm in length) and unaltered architecture without the fear of damage or leaving the specimen in situ during extraction. This instrument has a device which makes it possible to secure the core while it is being extracted. The distal tip of the instrument has been designed for easy penetration of the cortex and has a sharp cutting edge. The proximal end of the instrument has been fitted with a large metal bar allowing firmer grip and has a smooth handle for operator comfort.

Material and methods

INSTRUMENT

The steel instrument (Fig. 1) consists of four parts. (a) *The needle* has an overall length of 122 mm, a uniform external diameter of 3.25 mm, and a constant internal diameter of 2.5 mm except for the 4.5 mm, distal portion where it is bevelled, grooved, and has a sharp cutting edge. The internal diameter of this portion (2.1 mm) is less than the overall internal diameter and ends in a short step of 0.2 mm. This

*Available from Downs Surgical Limited, Church Path, Mitcham, Surrey CR4 3UE.